



Geometric Morphometric Analyses on Radiographic Images of The Carpal Joint Region of English Setters

Yusuf ALTUNDAĞ^{1,a}, Ece OKTAY^{2,b*}, Ermiş ÖZKAN^{3,c}, Gülsün PAZVANT^{3,d}

¹Department of Surgery, Faculty of Veterinary Medicine, Istanbul University-Cerrahpasa, Istanbul, Türkiye

²Institute of Graduate Studies, Istanbul University-Cerrahpasa, Istanbul, Türkiye

³Department of Anatomy, Faculty of Veterinary Medicine, Istanbul University-Cerrahpasa, Istanbul, Türkiye

^a ORCID: 0000-0001-6364-7512

^b ORCID: 0000-0002-3117-7875

^c ORCID: 0000-0002-5000-5075

^d ORCID: 0000-0001-5986-3992

Received: 24.05.2023

Accepted: 31.08.2023

How to cite this article: Altundağ Y, Oktay E, Özkan E, Pazvant G. (2023). Geometric Morphometric Analyses on Radiographic Images of The Carpal Joint Region of English Setters. Harran Üniversitesi Veteriner Fakültesi Dergisi, 12(2): 134-140.
DOI:10.31196/huvfd.1301399.

***Correspondence:** Ece Oktay

Institute of Graduate Studies, Istanbul University-Cerrahpasa, 34320, Istanbul, Türkiye.

e-mail: vet.eceoktay@gmail.com

Available on-line at: <https://dergipark.org.tr/tr/pub/huvfd>

Abstract: This study aims to determine the morphological differences according to gender via radiographic images taken from the carpal bones of English setters. A total of 28 bone samples, 16 females and 12 males, were used in the study. The shape differences between males and females were evaluated by placing 27 landmarks on the X-ray images. Principal Component Analyses are used to measure the distribution of variance. In addition, these analyses take the mean shape variation and compare it to shape differences. As a result of this analysis, the value of PC1 explained 24.34% of the total variation. In addition, PC2 explained 16.24% of the total variation, and PC3 explained 10.45%. In addition, the results of PCA were also described in terms of the English setter samples used. Then, Discriminant Function analysis was performed using the same software program. With this analysis, it was tried to determine the differences between the genders. According to the discriminant function test, 13 of 16 female dogs were completely separated from male dogs. Also, all 12 male dogs were separated from female dogs according to the same test results. In short, because of this study, shape differences in the carpal bones of English setters were investigated according to gender.

Keywords: Carpal joint, English Setters, Geometric morphometry, Radiography, Veterinary anatomy.

İngiliz Setter Köpeklerinin Karpal Eklem Bölgesinin Radyografik Görüntüleri Üzerinde Geometrik Morfometrik Analizler

Özet: Bu çalışmada, İngiliz setter köpeklerinin karpal kemiklerinden alınan radyografik görüntüler aracılığıyla cinsiyete göre morfolojik farklılıkların belirlenmesi amaçlanmıştır. Çalışmada 16 dişi ve 12 erkek olmak üzere toplam 28 kemik örneği kullanılmıştır. Erkek ve dişiler arasındaki şekil farklılıkları, röntgen görüntüleri üzerinde toplam 27 adet işaretleme ile değerlendirilmiştir. Varyans dağılımını ölçmek için Principal Component Analysis (PCA) kullanılmıştır. Bu analizlerin kullanım amacı ortalama şekil varyasyonunu alıp şekil farklılıklarıyla karşılaştırmaktır. Bu analiz sonucunda PC1 değeri toplam varyasyonun %24,34'ünü açıklamıştır. Ayrıca PC2 toplam varyasyonun %16,24'ünü, PC3 ise toplam varyasyonun %10,45'ini açıklamıştır. Daha sonra örnekler Diskriminant Fonksiyon analizi üzerinden de test edilmiştir. Bu analiz ile cinsiyetler arasındaki farklılıklar belirlenmeye çalışılmıştır. Diskriminant fonksiyon testine göre 16 dişi köpeğin 13'ü erkek köpeklerden tamamen ayrılmıştır. Yine aynı testin sonuçlarına göre 12 erkek köpeğin tamamı dişi köpeklerden ayrılmıştır. Kısacası, bu çalışma sonucunda İngiliz setter köpeklerinin karpal kemiklerindeki şekil farklılıkları ve cinsiyete göre karpal kemiklerde oluşan değişimler araştırılmıştır.

Anahtar Kelimeler: Geometrik morfometri, İngiliz Setter, Karpal kemikler, Radyografi, Veteriner anatomi.

Introduction

The setter dog breeds are classified into seven groups, including 153 dog breeds determined by the American Kennel Club (AKC) (Evans and De Lahunta, 2012). These seven groups identified by the American Kennel Club (AKC) show genetic diversity as well as anatomically (Evans and De Lahunta, 2012; Irion et al., 2003). According to the American Kennel Club (AKC), these dog breeds are in the sporting dog group. Also, this dog breed is thought to have English ancestry (Evans and De Lahunta, 2012). In this study, the samples taken from the carpal bones of the setter dog breed were used. The setter dog breed has a broad scale including various dog types such as a pointer, Irish setter, British setter, and red setter. This dog breed has many uses, such as hunting, farm work, and show. For example, pointer setters are mainly used for hunting, and Irish setters are primarily used for the show. It is observed that English setters are used in almost every field (Pedersen et al., 2013). Also, according to the Norwegian Kennel Club, English Setters are one of the athletic dog breeds. This dog breed resists long- distance walks and rough terrain (Vatne et al., 2021). For this reason, it is aimed to examine the anatomical examination of such a mobile and athletic dog breed and to discuss the differences in the bones.

The carpal bones, or as it is named in veterinary anatomy, "*ossa carpi*", formed the first part of the forefoot bones (*skeleton manus*). The carpal bones compose eight bones in all domestic mammals, *proximal* and *distal* rows. These were named *os carpi radiale*, *os carpi intermedium*, *os carpi ulnare*, and *os carpi accessorium* from *medial* to *lateral* on the *proximal* row. The carpal bones on the distal side are called *os carpale 1*, *os carpale 2*, *os carpale 3*, and *os carpale 4*. The carpal bones of dogs differ in number and structure from those of other domestic mammals. In these animals, the carpal bones on the proximal row are 3 instead of 4. The bones of the *os carpi radiale* and the *os carpi intermedium* fused to form the *os carpi intermedioradiale*. In addition to these bones, *os carpi ulnare* and *os carpi accessorium* are also found in these animals. The dogs have all four carpal bones in the *distal* row. The articulations of the carpal bones are named as follows. The joint between the *antebrachium* and the carpal bones is called the *Articulatio antebrachio-carpea*. The articulations between the upper and lower rows of the carpal bones are called *Articulatioes mediocarpea*. The *Articulatioes intercarpea* are the joints made by the carpal bones located on the same row. The articulations of the carpal bones with the metacarpal bones are called *Articulatioes carpometacarpea* (Demiraslan and Dayan, 2021; Dursun, 2007; König et al., 2007; Nomina Anatomica, 2017).

Geometric morphometry is a statistical analysis type based on the shape analysis of the structure, revealing shape variations for groups. This analysis, frequently used in veterinary anatomy in recent years, enables gender analysis and taxonomy studies. In studies on skulls, gender, and breed analysis can be performed in birds, civets, and dogs (Jashari et al., 2022; Gundemir et al., 2023a; Gundemir et al., 2020b; Gundemir et al., 2023b; Gurbuz et al., 2022; Szara et

al., 2022). It has been reported that using geometric morphometry and gender analysis is effective in studies involving geometric shapes, such as the turtle's carapace layer (Duro et al., 2021). Gender analysis was investigated by applying geometric morphometry to the finger postures of birds (Demircioglu et al., 2022).

Fractures in the carpal bones can be observed frequently, and this may vary with variables such as the animal's mobility capacity, age, breed, and weight (Li et al., 2000; Rainbow et al., 2008). However, there is limited knowledge about the anatomical differences between the sexes of the carpal joints in carnivores. It was estimated that there were linear differences between the articular bones regarding gender in cats.

The previous studies revealed the differences between genders between joint measurements or shapes (Gundemir et al., 2021; Şenol et al., 2022). This study aimed to examine the carpal arrangement of the English setter dog species by geometric morphometry method and to reveal the difference between males and females in shape.

Material and Methods

Ethical Statement

Permission was obtained from the Ethics Committee of the Faculty of Veterinary Medicine, Istanbul University-Cerrahpaşa, to use the samples and conduct the study (Decision number: 2022/38)

Animals and radiographs

This study used 28 (16 female and 12 male dogs) English setters. Radiographic images of the right carpal bones of English setter dogs were used. The carpal bones of all dogs whose radiographic images were collected were healthy. No pathological findings were found in the images used. The female dogs used in the study were 1-6 years old and weighed 14-30 kg, and the male dogs were 1-8 years old and weighed 13-30 kg. Radiographic images were obtained from Istanbul University-Cerrahpaşa. Analysis was performed only on the dorso-palmar aspect of the right carpal bone. In addition, the distal of the radius and ulna bones and the proximal of the metacarpal bones were also visualized.

Radiographic landmarks and the abbreviations used in this Study

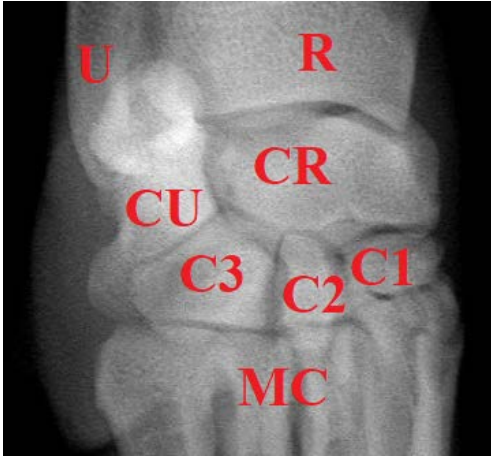
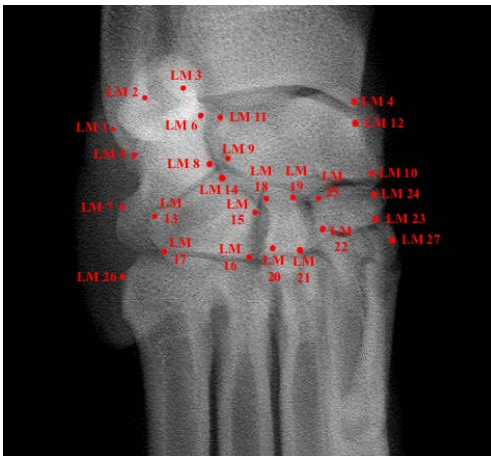The abbreviations used throughout this study and their meanings are given in Table 1. The locations of the abbreviations are shown in Figure 1 on the radiographic image. The places where the landmarks are marked are shown on the radiographic image in Figure 2. In addition, the meanings of the landmarks are explained as follows.

L1-L2: Both landmarks were located at the distal end of the *ulna* bone. It is marked to form the two furthest points of the *processus styloideus lateralis*.

L3-L4: Both landmarks were located at the distal end of the radius bone. A landmark was marked on the *trochlea radii* (L3). The other landmark was marked on the *processus styloideus medialis* (L4).

Table 1. Representation of the abbreviations used in this study.

Abbreviation	Places	Landmarks Placed on Bones
U	Ulna	L1-L2
R	Radius	L3-L4
CU	Os carpi ulnare	L5-L6-L7-L8
CR	Os carpi intermedioradiale	L9-L10-L11-L12
C1	Os carpi 1	L22-L23-L24-L25
C2	Os carpi 2	L18-L19-L20-L21
C3	Os carpi 3	L13-L14-L15-L16-L17
MC	Metacarpus	L26-L27

**Figure 1.** Representation of the abbreviations used in this study on the dorsopalmar radiographic image (U: Ulna, R: Radius, CU: Os carpi ulnare, CR: Os carpi intermedioradiale, C1: Os carpi 1, C2: Os carpi 2, C3: Os carpi 3, MC: Metacarpus)**Figure 2.** Dorsopalmar radiographic image of *carpal* bones showing location of landmarks (LM).

L5-L6-L7-L8: Each of the four landmarks were marked on the *os carpi ulnare*.

L9-L10-L11-L12: Each of the four landmarks were marked on the corners of the *os carpi intermedioradiale*.

L13-L14-L15-L16-L17: Each of the five landmarks were marked on the corners of *os carpi 3*.

L18-L19-L20-L21: Each of the four landmarks were marked on the corners of *os carpi 2*.

L22-L23-L24-L25: Each of the four landmarks were marked on the corners of *os carpi 1*.

L26-L27: Landmarks are marked as the furthest distance between the medial and lateral sides of the proximal end of the metacarpal bones visible on the radiographic image.

Geometric morphometry

The images of the carpal bones of the dogs taken from the X-ray device were converted to Jpeg format and transferred to the computer. The images in Jpeg format were converted to TPS files using the TPS Util (version 1.82) program. Then, they were marked on the images using the TPS Dig2 (version 2.31) program. All veterinary anatomy terms used in this study are taken from Nomina Anatomica Veterinaria (Nomina Anatomica Veterinaria, 2017).

Radiographic images were the view of the right carpal bones from the dorsopalmar position. The images also showed the distal section of the antebrachium bone (Radius-Ulna) and the proximal section of the metacarpal bones. These bones, which appear in the images, are also included in the markings.

Statistical analysis

In this study, shape analyses were performed using the MorphoJ (version 1.07a) software (Klingenberg, 2011). The carpal bones were grouped by gender, and then the differences between the sexes were investigated with the help of this software. The landmarks indicate anatomically specific points (Bookstein et al.,1991). Using this software, coordinate data were tested morphologically, and these data were tried to be interpreted in terms of geometric morphometry. Procrustes Fit was first applied to all the samples embedded in the software, and then Generalized Procrustes Analysis and Principal Component Analysis (PCA) were applied. The purpose of Procrustes Analysis is to display shape differences. Generalized Procrustes Analysis is used to reveal general shape differences. Principal Component Analysis (PCA) is used to measure variance distribution. The PCA is a coordination method that aims to reduce the dimensionality of the data from the samples. Discriminant Function analysis was applied to all groups to investigate the differences between the sexes. With this method, it was aimed to find variations between females and males.

Results

The results of five different principal component values of these landmarks determined according to the MorphoJ program are given in Table 2. According to this table, PC1 explained 24.34%, PC2 16.24%, and PC3 10.45% of the total variance.

Shape variation of PC values were given in Figure 3 with the Wire-frame warp plots. The placement of the PC values in the Variance Graph is shown in Figure 4. The blue frame represents the mean shape of all samples, and the red frame represents the positive limit. The red frames were compared with the blue frames, as the blue frames gave the mean shape.

A sharp curve was formed between LM2 and LM3, which remained between U and R at PC1 value. Carpal bones were evaluated according to the PC1 value. Accordingly, it

Table 2. Results of principal component analysis.

Principal Components	Eigenvalues	Variance %	Cumulative %
PC1	0,00152116	24,345	24,345
PC2	0,00101482	16,241	40,586
PC3	0,00065337	10,457	51,043
PC4	0,00052995	8,481	59,524
PC5	0,00045782	7,327	66,852

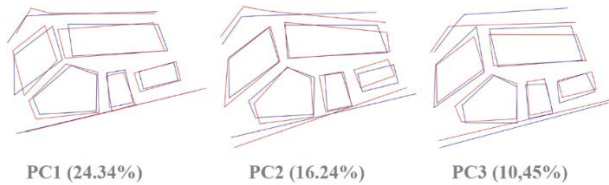


Figure 3. Variance Distribution for Principal Components. Blue outlines represent the mean shape configuration, while the red outlines show the shape changes associated with the positive extremes of the PC axes.

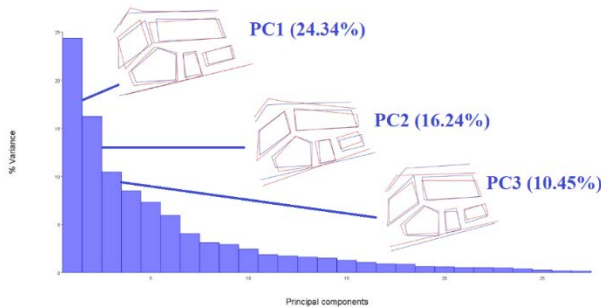


Figure 4. Representation of Principal Components on the variance graph. Blue outlines represent the mean shape configuration, while the red outlines show the shape changes associated with the positive extremes of the PC axes.

was seen that the CU was narrower but longer. The positive limit in the CR was transverse. In the lower row of carpal bones, the positive limit of C3 was observed to be both transverse and longitudinal. C2 followed a course closer to MC and showed a wider shape as it approached MC. Although C1 was almost the same size as the mean shape, it was wider than the mean shape. The landmarks on the MC were almost on the same course as the mean shape.

At PC2, landmarks at U and R showed a line that would cross the mean shape. Likewise, landmarks placed in the MC also crossed the mean shape. The edge where the LM7 was placed in the CU showed a sharper shape. However, other positive changes were almost identical to the mean shape. A positive limit was observed in the CR, which started broadly and narrowed horizontally. The positive limit of C3 was observed to be longer but narrower than the mean shape. C2 had a wider positive limit than the mean shape. The positive limit of C1 was located further upstream from the MC compared to the mean shape.

When the PC3 value was examined in general, it was observed that the positive limits of the bones were flatter than the mean shape. U and R are lower in PC3 than the

mean shape. The PC3 value represented a smaller CU value. The positive change in CR was more transverse but shorter in width. PC3 value was higher in all carpal bones in the lower row. It showed a wider shape in C3. It was narrower in shape in C2 and wider in C1. In MC, the positive change was located higher up.

The graphs of gender distribution in carpal bones depending on PC values are given in Figure 5. The red dots in these graphs represent female dogs, and the blue dots represent male dogs. Ellipses represent 95% confidence intervals around the means for sexes. Accordingly, less variation was observed in females. Male dogs showed more variation compared to females for both graphs.

According to the graph of PC1 and PC2, the highest PC1 value was measured to be the female sample. However, the highest PC2 value was observed in the male sample. According to the graph of PC1 and PC3, it was observed that the highest PC3 value was in the male sample. As a result, when all the graphics related to PC values were evaluated, no regional distribution was observed between female and male individuals. Female specimens and male specimens are scattered all over the graph.

The distinction of male and female individuals according to discriminant function analysis is given in Table 3. In addition, the discriminant scores, and the frequency graph, which were also shaped according to this analysis, are shown in Figure 6. According to these data, all 12 male samples were separated from females. In females, 13 out of 16 female samples were separated from males, while 3 of them did not show complete discrimination. However, according to Figure 6, an evident distance was observed between female and male samples. The differences between the sexes are shown in Figure 7 with the Wire-frame Wrap plot. In this graph, the mean values of female dogs are represented by a red frame and that of male dogs by a blue frame.

Table 3. Results of discriminant function analysis.

	Female	Male	Total
Female	13	3	16
Male	0	12	12

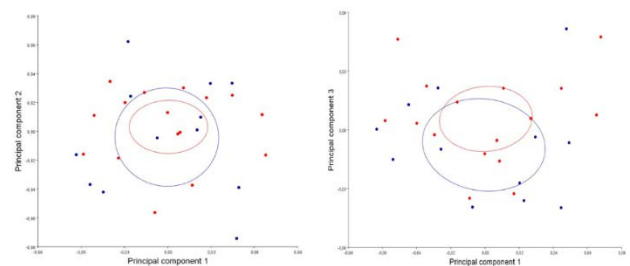


Figure 5. The Gender Distribution plot of carpal bones by the PC1 (24.34 %), PC2 (16.24 %) and PC3 (10.45 %). Ellipses represent 95% confidence intervals around the means for sexes (Male: blue; Female: red).

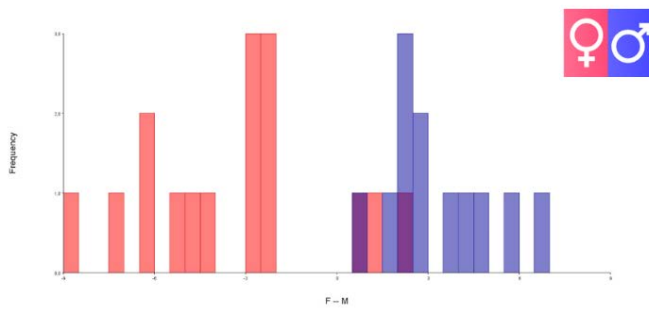


Figure 6. Discriminant scores and frequency for setter dogs carpal bones according to gender (Male: blue; Female: red).

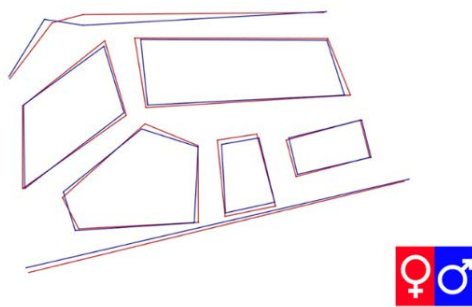


Figure 7. For female and male dogs carpal bones mean shape and difference between means (Male: blue; Female: red).

The frame between the signs on the U and R formed a sharper shape in males. On the contrary, it has been observed that female individuals form a more trapezoidal shape. When the carpal bones in the upper row were examined; CU was wider in female dogs. It was observed that the CR was horizontal or even shorter in males than in females. When carpal bones in the lower row were examined, C3 was wider in females. Only at the LM17 point the C3 of females was narrower than that of males. C2 showed a shorter and smaller shape in males. C1 was almost the same size in males and females, only at LM25 and LM22 points C1 of females was slightly larger in shape. Two landmarks were placed on the MC (LM26-LM27). While LM26 was separated into females and males, such a distinction was not observed in LM27. It was observed that the discrimination decreased as it approached the LM27 linearly.

The distance between the joint spaces between the carpal bones was greater in males. (*Articulationes mediocarpea* and *Articulationes intercarpea*). However, the distance between the upper carpal bones' U and R articular spaces was closer (*Articulatio antebrachioarpea*). Likewise, the spacing of the joints of the lower-order carpal bones with the MC was narrower in males (*Articulationes carpometacarpea*).

Discussion and Conclusion

This study aimed to investigate gender differences in carpal bones. The development of morphological and

anatomical studies needs to examine whether there is a distinction between carpal bones in female dogs and male dogs in English setters. It is also crucial for forensic medicine studies to determine whether these gender-related differences are specific to races. Such studies, it is aimed to increase the bones that can be evaluated instead of missing bones (Mastrangelo et al., 2011b). The diversity of these bones also provides the development of taxonomy (Bidmos-Steinberg et al., 2005; Introna Jr. et al., 1998; Giurazza et al., 2013; Gundemir et al., 2020a). For this purpose, radiographic images of carpal bones were taken from 28 English setter dogs. Twenty-seven landmarks were placed on these images. Principal Component Analysis (PCA) and Discriminant Function tests were applied to the visuals prepared. According to the result of PCA, the PC1 value explained 24.34% of the total variance. PC2 value explained 16.24% of the total variance. The PC3 value explained 10.45% of the total variance. Figure 5 shows the confidence intervals of both female and male individuals. According to this, female dogs showed a more conservative shape variation compared to male dogs.

According to discriminant function test results, all 12 male English setters were separated from the females. On the other hand, 13 out of 16 female English setters were completely separated from males, while 3 female English setters were not wholly separated from males. It was previously stated that the setter dogs whose images were taken in the study did not have any orthopedic disorders. In addition, the animals were selected from a certain weight and age range. For this reason, the three female English setters could not show complete separation from the male group, which may be caused by ossification (Myo et al., 2016).

Similar principal component values were found in another animal study on carpal bones. This study was done on horses. However, the comparison results between mean value and shape changes are close to this study. It was also studied on carpal bones as used in this study. In that study, the value of PC1 was 28.44%, also, the PC1 value was the highest variance percentage (Gundemir et al., 2021). The variation percentages were high when the principal component values were evaluated in this study. It was observed that the principal component value with the highest variance percentage was PC1 (24.34%) (Gundemir et al., 2021).

All 12 male dogs were completely separated from the female dogs in shape, while 3 out of 16 female dogs were not separated from the male dogs. Considering that samples from English Setter dog breeds were used in this study, the results may have been obtained this way (Evans et al., 2013; González-Rellán et al., 2022; Irion et al., 2003). It has also been reported that setters are used for tasks that rely on the strength of the musculoskeletal system, such as hunting and farm work, and for more comfortable purposes, such as dog shows (Evans et al., 2013; Irion et al., 2003). In other animals, it has been observed that the change in purpose of use can cause many problems and differences in the skeletal system (Bidmos et al., 2005; Li et al., 2000). In addition, the ages of the English setter specimens used in this study were

different from each other. This age difference may have affected bone development and size (Riggs et al., 2004). This may be the reason why 3 samples from female dogs were not separated from male dogs. Discriminant analysis has been previously applied to radiographic images and various bone measurements. This method has been applied to measurements of human and animal bones. It has also been used for gender dimorphism (Barnes et al., 2020; Gundemir et al., 2021; Mastrangelo, et al., 2011a; Mastrangelo et al., 2011b). In addition, the MorphoJ software program, used as a geometric morphometric method in this study, has been used for sex determination in other studies (Sarač-Hadžihalilović et al., 2022).

This study used radiographic images of the right carpal bones of 28 different setter dogs. The obtained images were transferred to MorphoJ software and analyzed in terms of change according to gender. For this purpose, 27 landmarks were added to all images. These landmarks were generally placed by targeting the end corners of the bones observed in the images. Principal component values were measured using the MorphoJ software system. It was tried to explain the visible changes according to the comparison results. In addition, the difference between male and female individuals was measured with the discriminant function test. The gender-related differences in the carpal bones in the setter dog breed were questioned. According to test results, landmark locations differed in male and female dogs (Figure 6). They were also separated from female dog samples of all 12 male dog samples. However, according to the test results, 3 out of 16 female dog samples did not differentiate from male individuals (Table 3).

Conflict of Interest

The authors stated that they did not have any real, potential, or perceived conflict of interest.

Ethical Approval

Permission was obtained from the Ethics Committee of the Faculty of Veterinary Medicine, Istanbul University-Cerrahpaşa, to use the samples and conduct the study (Decision number: 2022/38)

Funding

This work has received no financial support.

Similarity Rate

We declare that the similarity rate of the article is %7 as stated in the report uploaded to the system.

Data Availability

Any additional data supporting this study are available from the author (E.O.) upon reasonable request

Author Contributions

Motivation / Concept: YA, EO, EÖ, GP
 Design: YA, EO, EÖ, GP
 Control/Supervision: YA, EÖ, GP
 Data Collection and / or Processing: YA
 Analysis and Interpretation: YA, EO
 Literature Review: EO
 Writing the Article: EO

References

- Barnes AE, Case DT, Burnett SE, Mahakkanukrauh P, 2020: Sex estimation from the carpal bones in a Thai population. *Aust J Forensic Sci*, 52 (6), 665-680.
- Bidmos MA, Steinberg N, Kuykendall KL, 2005: Patella measurements of South African whites as sex assessors. *Homo*, 56 (1), 69-74.
- Bookstein FL, Grayson B, Cutting CB, Kim HC, McCarthy JG, 1991: Landmarks in three dimensions: reconstruction from cephalograms versus direct observation. *Am J Orthod Dentofacial Orthop*, 100 (2), 133-140.
- Demiraslan Y, Dayan MO, 2021: Veteriner Sistemik Anatomi. 1st ed., Nobel Tıp Kitabevleri, Ankara, Türkiye.
- Demircioglu I, Duro S, Gungoren G, Choudhary OP, Gundemir O, Demiraslan Y, Pazvant G, 2022: Digits angle and digits length ratio in japanese quail (*Coturnix coturnix japonica*). *Indian J Anim Res*, 56 (9), 1105-1109.
- Duro S, Gundemir O, Sönmez B, Jashari T, Szara T, Pazvant G, Kambo A, 2021: A different perspective on sex dimorphism in the adult Hermann's tortoise: geometric morphometry. *Zool Stud*, 60: e9.
- Dursun N, 2007: Veteriner Anatomi 1, Medisan Yayınevi, Ankara, Türkiye.
- Evans HE, De Lahunta A, 2012: Miller's anatomy of the dog-E-Book. 4th ed., Elsevier health sciences, Missouri, MO, USA.
- Giurazza F, Schena E, Del Vescovo R, Cazzato RL, Mortato L, Saccomandi P, Zobel BB, 2013: Sex determination from scapular length measurements by CT scans images in a Caucasian population. In 2013 35th Annual International Conference of the IEEE Engineering in Medicine and Biology Society, (EMBC) (pp. 1632-1635).
- González-Rellán S, Barreiro A, Cifuentes JM, Fdz-de-Trocóniz P, 2022: Anatomy of the PaLar Region of the Carpus of the Dog. *Animals*, 12 (12), 1573.
- Gundemir MG, Szara T, Spataru C, Demircioglu I, Turek B, Petrovas G, Spataru MC, 2023a: Shape differences of the Carina sterni in birds of various locomotion types. *Anat Histol Embryol*, 52 (2), 190-196.
- Gundemir O, 2022: Skull of the Asian (*Paradoxurus Hermaphroditus*) and the golden (*Paradoxurus Zeylonensis*) paL civet: Geometric morphometric analysis using palate, tooth and frontal landmarks. *Anat Histol Embryol*, 51 (6), 718-727.
- Gundemir O, Duro S, Jashari T, Kahvecioglu O, Demircioglu İ, Mehmeti H, 2020a: A study on morphology and morphometric parameters on skull of the Bardhoka autochthonous sheep breed in Kosovo. *Anat Histol Embryol*, 49 (3), 365-371.
- Gundemir O, Hadžiomerović N, Pazvant G, Erdikmen DO, 2021: Radiometric and geometric morphometric analysis of the carpal joint area in 2-year-old Thoroughbred horses. *Veterinaria*, 70 (2), 209-217.
- Gundemir O, Özkan E, Dayan MO, Aydogdu S, 2020b: Sexual analysis in turkey (*Meleagris gallopavo*) neurocranium using

- geometric morphometric methods. *Turk J Vet Anim Sci*, 44 (3), 681-687.
- Gundemir O, Szara T, Yalin EE, Karabagli M, Mutlu Z, Yilmaz O, Parés-Casanova PM, 2023b: Examination of Shape Variation of the Skull in British Shorthair, Scottish Fold, and Van Cats. *Animals*, 13 (4), 614.
- Gurbuz İ, Demiraslan Y, Rajapakse C, Weerakoon DK, Fernando S, Spataru MC, Gundemir O, 2022: Skull of the Asian (Paradoxurus Hermaphroditus) and the golden (Paradoxurus Zeylonensis) palm civet: Geometric morphometric analysis using palate, tooth and frontal landmarks *Anat Histol Embryol*, 51 (6), 718-727.
- Horst Erich König, Hans-Georg Liebich, 2007: Veterinary Anatomy of Domestic Mammals. 3rd ed., Schattauer, Stuttgart, Germany.
- International Committee on Veterinary Gross Anatomical Nomenclature (I.C.V.G.A.N.), 2017: Nomina Anatomica Veterinaria, 6th ed., Published by the Editorial Committee, Hanover, Germany, Ghent, Belgium, Columbia, MO, USA, Rio de Janeiro, Brazil.
- Introna Jr F, Di Vella G, Campobasso CP, 1998: Sex determination by discriminant analysis of patella measurements. *Forensic Sci Int*, 95 (1), 39-45.
- Irion DN, Schaffer AL, Famula TR, Eggleston ML, Hughes SS, Pedersen NC, 2003: Analysis of genetic variation in 28 dog breed populations with 100 microsatellite markers. *J Hered*, 94 (1), 81-87.
- Jashari T, Kahvecioglu O, Duro S, Gundemir O, 2022: Morphometric analysis for the sex determination of the skull of the Deltari Ilir dog (*Canis lupus familiaris*) of Kosovo. *Anat Histol Embryol*, 51 (4), 443-451.
- Klingenberg CP: MorphoJ, 2011: an integrated software package for geometric morphometrics. *Mol Ecol Resour*, 11 (2), 353-357.
- Li A, Bennett D, Gibbs C, Carmichael S, Gibson N, Owen M, Denny HR, 2000: Radial carpal bone fractures in 15 dogs. *J Small Anim Pract*, 41 (2), 74-79.
- Mastrangelo P, De Luca S, Alemán I, Botella MC, 2011b: Sex assessment from the carpals bones: discriminant function analysis in a 20th century Spanish sample. *Forensic Sci Int*, 206 (1-3), 216-e1.
- Mastrangelo P, De Luca S, Sanchez-Mejorada G, 2011a: Sex assessment from carpals bones: discriminant function analysis in a contemporary Mexican sample. *Forensic Sci Int*, 209 (1-3), 196-e1.
- Myo, N. Z, Po, SP, Soe, HY, Myint, HH, Khaing, KT, 2016: Comparison on Development of Ossification Centres of Radius and Ulna in Male and Female Dogs by Radiographically. *IJNRLS*, 3 (5), 18-29.
- Olusa TA, Akbar Z, Murray CM, Davies HM, 2021: Morphometric analysis of the intercarpal ligaments of the equine proximal carpal bones during simulated flexion and extension of cadaver limbs. *Anat Histol Embryol*, 50 (1), 151-160.
- Pedersen N, Liu H, Theilen G, Sacks B, 2013: The effects of dog breed development on genetic diversity and the relative influences of performance and conformation breeding. *J Anim Breed Genet*, 130 (3), 236-248.
- Rainbow MJ, Crisco JJ, Moore DC, Wolfe SW, 2008: Gender differences in capitata kinematics are eliminated after accounting for variation in carpal size. *J Biomech Eng-t Asme*, 130 (4), 041003.
- Riggs BL, Melton III LJ, Robb RA, Camp JJ, Atkinson EJ, Peterson JM, Rouleau PA, McCollough CH, Bouxsein ML, Khosla S, 2004: Population-based study of age and sex differences in bone volumetric density, size, geometry, and structure at different skeletal sites. *J Bone Miner Res*, 19 (12), 1945-1954.
- Sarač-Hadžihalilović A, Ajanović Z, Hasanbegović I, Šljuka S, Rakanović-Todić M, Aganović I, Hadžiselimović R, 2022: Analysis of gender differences on pyriform aperture of human skulls using geometric morphometric method. *Folia Morphol*, 81 (3), 707-714.
- Senol E, Gundemir O, Duro S, Szara T, Demiraslan Y, Karadag H, 2022.: A pilot study: Can calcaneus radiographic image be used to determine sex and breed in cats? *Vet Med Sci*, 8 (5), 1855-1861.
- Szara T, Duro S, Gundemir O, Demircioglu İ, 2022: Sex determination in Japanese Quails (*Coturnix japonica*) using geometric morphometrics of the skull. *Animals*, 12(3), 302.
- Vatne L, Dickson D, Tidholm A, Caivano D, Rishniw M, 2021: The effects of activity, body weight, sex and age on echocardiographic values in English setter dogs. *J Vet Cardiol*, 37, 26-41.