



## EDİTÖRE MEKTUP / LETTER TO THE EDITOR

### **Positive association between bilateral ear lobe vertical creases and occurrence of coronary artery diseases**

Bilateral kulak lobu dikey kırışıklıkları ile koroner arter hastalıklarının ortaya çıkışı arasındaki pozitif ilişki

Vagish Kumar L Shanbhag

<sup>1</sup>Yenepoya Dental College and Hospital, Department of Oral Medicine and Radiology, Yenepoya Research Centre, Yenepoya University, Mangalore-Karnataka, India

*Cukurova Medical Journal 2017;42(2):400-401*

Dear Editor,

Coronary artery disease is the leading cause of death in developed and developing countries<sup>1,2</sup>. Early diagnosis is of utmost importance in managing this disease. Frank's sign facilitates early non-invasive diagnosis of coronary artery disease especially in high risk patients<sup>3</sup>. There is limited literature available on the occurrence of bilateral vertical earlobe crease and its positive association with coronary artery disease. This article discusses a case in which bilateral vertical earlobe creases was positively associated with past history of coronary artery disease.

A 63-year-old male patient visited the hospital with a complaint of ill-fitting dentures. Extra oral examination showed bilateral vertical ear lobe creases (Figure 1). The creases were observed to run vertically from intertragic incisure of the ear towards the lower edge of the lobule. Past medical history revealed 60% stenosis in the left main coronary artery, 80% discrete lesion in ostial left anterior descending artery and 90% stenosis in distal left anterior descending artery with a diagnosis of double vessel coronary artery. Patient then had undergone immediate coronary artery bypass grafting one year back. Patient also had history of hypertension since past was 25 years. Thus a positive association between the manifestations of bilateral vertical ear lobe creases to the occurrence

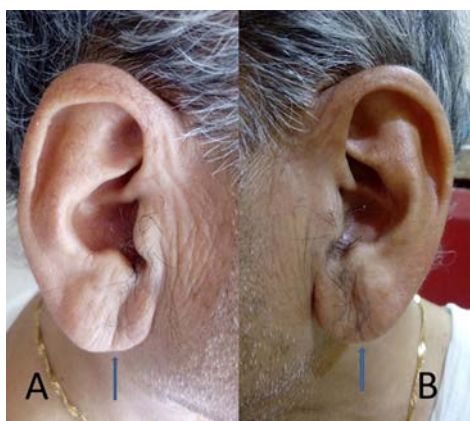
of coronary artery disease was noted.

Frank's sign is the presence of diagonal ear lobe creases. Studies have shown strong correlation between Frank's sign and coronary artery atherosclerosis<sup>4</sup>. Frank's sign is associated with the extent and severity of coronary atherosclerosis<sup>5</sup>. The diagonal creases are present on the lower ear lobes unilaterally or bilaterally<sup>6</sup>. These diagonal creases run posteriorly from the tragus of the ear at 45° angle and cross the lower ear lobule<sup>7</sup>. It is believed that both earlobes and myocardium derive their blood supply from the same genetically originated end arterioles with a common pathway<sup>8</sup>. Frank's sign is of immense diagnostic use particularly in patients with age less than 60 years<sup>9</sup>. In our case the patient had vertical creases on the earlobe bilaterally with history of coronary artery disease (CAD).

A meta-analysis study observed that 62% of patients with coronary artery disease have earlobe creases and 67% of patients without earlobe creases did not had CAD<sup>10</sup>. The study also observed that risk of CAD is 3.3 fold in patients with earlobe crease than those without them. A recent study observed independent association of diagonal bilateral ear lobe creases with cardiovascular events and ischemic stroke<sup>11</sup>. A necropsy study concluded that diagonal ear lobe creases is associated with fatal cardiovascular disease<sup>12</sup>. Hou et al in their study on Chinese population concluded that diagonal ear lobe

Yazışma Adresi/Address for Correspondence: Dr. Vagish Kumar L. Shanbhag, Department of Oral Medicine & Radiology, Yenepoya Dental College and Hospital, Yenepoya Research Centre, Yenepoya University, Mangalore-575018, Karnataka, India. E-mail: vagishkumar\_12@rediffmail.com  
Geliş tarihi/Received: 31.08.2016 Kabul tarihi/Accepted: 19.09.2016

creases combined with coronary artery disease (CAD) risk factors is helpful to predict the incidence of CAD<sup>13</sup>. In their study, angiographically diagnosed CAD patients had increased prevalence of bilateral diagonal earlobe creases. These creases are rare in children and their occurrence tends to increase with increasing age, particularly during the fifth decade of life with positive association with coronary artery sclerosis<sup>12</sup>. Diagonal ear creases are associated with thickening of carotid intima and manifests due to microvascular weakening of elastic fibers in the ear lobes- a pathology which is also seen in CAD<sup>3</sup>.



**Figure 1A.**Right ear lobe vertical crease

**Figure 1B.**Left ear lobe vertical crease.

The present case demonstrates that the presence of bilateral ear lobe vertical creases correlates with CAD and could be of significance in pre-diagnosis and in secondary prevention of CAD. More extensive research needs to be carried out to confirm the exact relationship between the presence of bilateral ear lobe vertical crease and CAD.

## REFERENCES

- Gaziano TA, Bitton A, Anand S, Abrahams-Gessel S, Murphy A. Growing epidemic of coronary heart disease in low- and middle-income countries. *Curr Probl Cardiol.* 2010;35:72-115.
- Dai X, Wiernek S, Evans JP, Runge MS. Genetics of coronary artery disease and myocardial infarction. *World J Cardiol.* 2016;8:1-23.
- Qamar A, Ioannides KL, Khetarpal SA, Kiss D. Bilateral earlobe creases and coronary artery disease. *Circulation.* 2014;130:92-3.
- Friedlander AH, López-López J, Velasco-Ortega E. Diagonal ear lobe crease and atherosclerosis: A review of the medical literature and dental implications. *Med Oral Patol Oral Cir Bucal* 2012;17:e153-9.
- Shmilovich H, Cheng VY, Rajani R, Dey D, Tamarappoo BK, Nakazato R et al. Relation of diagonal ear lobe crease to the presence, extent, and severity of coronary artery disease determined by coronary computed tomography angiography. *Am J Cardiol.* 2012;109:1283-7.
- Kwai-Ping Suen L, Lau YK, Ma HC, Lai KW, Holroyd E. Predictive value of auricular diagnosis on coronary heart disease. *Evid Based Complement Alternat Med.* 2012;2012:706249
- Griffing G. Images in clinical medicine. Frank's sign. *N Engl J Med.* 2014;370:e15.
- Evrengül H, Dursunoğlu D, Kaftan A, Zoghi M, Tanriverdi H, Zungur M et al. Bilateral diagonal earlobe crease and coronary artery disease: A significant association. *Dermatol Basel Switz.* 2004;209:271-5.
- Xu R, Pham J. Frank's sign: a coronary artery disease predictor. *BMJ Case Rep.* 2014;2014: bcr2014205770..
- Lucenteforte E, Romoli M, Zagli G, Gensini GF, Mugelli A, Vannacci A. Ear lobe crease as a marker of coronary artery disease: a meta-analysis. *Int J Cardiol.* 2014;175:171-5.
- Rodríguez-López C, Garlito-Díaz H, Madroñero-Mariscal R, Sánchez-Cervilla PJ, Graciani A, López-Sendón JL, et al. Earlobe crease shapes and cardiovascular events. *Am J Cardiol.* 2015;116:286-93.
- Kirkham N, Murrells T, Melcher DH, Morrison EA. Diagonal earlobe creases and fatal cardiovascular disease: a necropsy study. *Br Heart J.* 1989;61:361-4.
- Hou X, Jiang Y, Wang N, Shen Y, Wang X, Zhong Y, et al. The combined effect of ear lobe crease and conventional risk factor in the diagnosis of angiographically diagnosed coronary artery disease and the short-term prognosis in patients who underwent coronary stents. *Medicine (Baltimore).* 2015;94:e815.