

## The Effect of Histopathological Subtype on 5 Year and 10 Year Overall Survival in Primary Malign Tumors of the Chest Wall

### Göğüs Duvarının Primer Malign Tümörlerinde Histopatolojik Alt Tipin 5 Yıllık ve 10 Yıllık Genel Sağkalıma Etkisi

Burak ODABAŞI<sup>1</sup>, Mehmet YILDIRIM<sup>1</sup>, İsmail DAL<sup>1</sup>, Melek Didem AYDEMİR<sup>1</sup>, Kemal DEMİRCAN<sup>1</sup>, Deniz Ezgi MAHMUTOĞLU<sup>1</sup>, Seçkin DENİZ<sup>1</sup>, Semih BULUKLU<sup>1</sup>, Aybiçe Elif SİLPAĞAR<sup>1</sup>, Murat YAŞAROĞLU<sup>2</sup>, Bülent AYDEMİR<sup>1</sup>, Tamer OKAY<sup>1</sup>

1 University of Health Sciences Dr. Siyami Ersek Thoracic and Cardiovascular Surgery Training and Research Hospital, İstanbul, Türkiye  
2 Başkent University İstanbul Hospital, Thoracic Surgery Department, İstanbul, Türkiye

#### Öz

Göğüs duvarının primer tümörleri, torasik neoplazmların %5'ini oluşturan nadir tümörlerdir. Mevcut çalışma, göğüs duvarının primer malign tümörlerinde histopatolojik alt tipin 5 yıllık ve 10 yıllık genel sağkalıma ve bölgesel nüks durumlarına etkisini değerlendirmeye yönelik tasarlanmıştır. Aralık 2007'den Aralık 2019'a kadar, 20 hastanın verileri geriye dönük olarak incelendi. Histopatolojik alt tipler arasında; genel sağkalım oranları, ortalama sağkalım, bölgesel tümör nüksü saptanma oranları ve ortalama hastalısız sağkalım geriye dönük olarak kıyaslandı. Kondrosarkom (n=7), desmoid tümör (n=6), indifferansiye pleomorfik sarkom [(İPS), (n=4)], Ewing sarkomu (n=1), malign periferik sinir kılıf tümörü (n=1) ve liposarkom (n=1) tespit edilen alt tiplerdi. İPS histopatolojik alt tipinde daha düşük ortalama sağkalım tespit edildi (p = 0.004). Kondrosarkom grubunda 5 ve 10 yıllık genel sağkalım oranları sırasıyla, %71 ve %37; desmoid tümörlerde sırasıyla, %83 ve %42 saptandı. İPS'de ise 5 yıllık sağkalım gösteren hasta olmadı. Yan duvar yerleşimli kitlelerde, ön ve arka duvar yerleşimli kitlelere kıyasla daha kısa ortalama sağkalım tespit edildi (p = 0.001). Takip süresince 10 hasta (%50) hayatını kaybetti. İPS alt tipinde ortalama hastalısız sağkalımın, diğer alt tiplere kıyasla daha kısa olduğu görüldü (p = 0.002). Bölgesel nüks oranları, kondrosarkom, desmoid tümör ve İPS için sırasıyla, %57; %17 ve %75 olarak saptandı. Göğüs duvarının primer malign tümörlerinden İPS'de, 5 yıllık ve 10 yıllık genel sağkalım oranlarının ve ortalama sağkalımın; kondrosarkom ve desmoid tümör gruplarına kıyasla anlamlı ölçüde daha kısa olduğu saptandı.

**Anahtar Kelimeler:** Bölgesel Nüks, Genel Sağkalım, Göğüs Duvarı Primer Malign Tümörü, İndifferansiye Pleomorfik Sarkom

#### Abstract

Primary tumors of the chest wall are rare tumors comprising 5% of thoracic neoplasms. The current study was designed to evaluate the effect of histopathological subtype on the 5-year and 10-year overall survival and regional recurrence in primary malignant tumors of the chest wall. From December 2007 to December 2019, the data of 20 patients were analyzed. Overall survival rates, median overall survival, regional tumor recurrence and median disease-free survival rates were compared retrospectively between histopathological subtypes. Chondrosarcoma (n=7), desmoid tumor (n=6), undifferentiated pleomorphic sarcoma [(UPS), (n=4)], Ewing's sarcoma (n=1), malignant peripheral nerve sheath tumor (n=1), and liposarcoma (n=1) were the subtypes identified. A lower median overall survival was detected in the UPS histopathological subtype (p = 0.004). The 5 and 10-year overall survival rates in the chondrosarcoma group were 71% and 37%, respectively; desmoid tumors were found in 83% and 42%, respectively. There was no patient with 5-year survival in UPS. A shorter median overall survival was found in lateral wall masses compared to anterior and posterior wall masses (p = 0.001). During the follow-up, 10 patients (50%) died. It was observed that the median disease-free survival in the UPS subtype was shorter compared to the other subtypes (p = 0.002). The regional recurrence rate was 57%, 17% and 75% in chondrosarcoma, desmoid tumor and UPS, respectively. In UPS, a primary malignant tumor of the chest wall, 5-year and 10-year overall survival rates and median overall survival; it was found to be significantly shorter than the chondrosarcoma and desmoid tumor groups.

**Keywords:** Chest Wall Primary Malignant Tumor, Overall Survival, Regional Recurrence, Undifferentiated Pleomorphic Sarcoma

	ORCID No
Burak ODABAŞI	0000-0002-9469-380X
Mehmet YILDIRIM	0000-0003-4147-4053
İsmail DAL	0000-0002-5118-0780
Melek Didem AYDEMİR	0000-0003-1028-0600
Kemal DEMİRCAN	0000-0002-0028-3798
Deniz Ezgi MAHMUTOĞLU	0000-0001-9630-8760
Seçkin DENİZ	0000-0001-5637-0973
Semih BULUKLU	0000-0002-1153-7036
Aybiçe Elif SİLPAĞAR	0000-0002-9274-7982
Murat YAŞAROĞLU	0000-0001-9791-9387
Bülent AYDEMİR	0000-0001-7073-5131
Tamer OKAY	0000-0002-3058-3708

Başvuru Tarihi / Received: 07.06.2023  
Kabul Tarihi / Accepted : 07.10.2023

Adres / Correspondence : Burak ODABAŞI  
Acıbadem Mh. Çeçen Sk. 46G/190 Üsküdar/İSTANBUL

e-posta / e-mail : burakodabasi@gmail.com

#### Introduction

Chest wall tumors originate from the soft tissue, bone or cartilage tissues that make up the rib cage. Primary tumors of the chest wall are rare tumors. They correspond to 5% of thoracic neoplasms. Approximately 50-60% of primary chest wall tumors are malignant (1).

Some histopathological subtypes of primary malignant tumors of the chest wall are resistant to chemotherapy and radiotherapy. This increases the importance of surgical resection. In the surgical treatment of primary malignant chest wall tumors, full thickness (en-bloc) chest wall resection increases the success in surgical management. In order to reduce regional recurrence rates and contribute to survival, primary malignant tumors of the chest wall require wide resection to create a tumor-free surgical margin. In addition, in these patients, the defect created in the chest wall is closed with a patch if necessary. Although radiotherapy in

solitary plasmacytoma and chemotherapy in osteosarcoma and Ewing's sarcoma are applied in the first place, surgical resection and reconstruction are the priority in most of the chest wall malignant tumors (2).

55% of primary malignant tumors of the chest wall originate from cartilage or bone tissue, and 45% from soft tissue (3). Tumors originating from soft tissue are generally painless growing masses; bone-derived tumors usually apply to the clinic with complaints of pain due to periosteal damage. Pain is an indicator of poor prognosis. The most common primary malignant tumors of the chest wall; malignant fibrous histiocytoma (currently IPS), chondrosarcoma and fibrosarcoma (4).

#### *Primary Malign Tumors of the Chest Wall*

**Chondrosarcoma:** It constitutes 30% of malignant primary bone tumors. It is the most common malignant primary bone tumor of the chest wall in adults. Since it originates from the cartilage tissue, it is frequently observed in the anterior chest wall or sternum (1). It manifests as a painful, hard, fixed and slowly growing mass on the anterior chest wall (5). It usually occurs in the third and fourth decades of life. Radiographically, they appear as a lobulated mass with extensive calcification on CT imaging. In this group of tumors where chemotherapy is ineffective, surgical resection forms the basis of treatment (1,7,8). In low-grade tumors, resection can be performed with a 2 cm surgical margin; high-grade tumors should be resected with a 4 cm surgical margin. Radiation therapy can be applied in cases with no chance of resection and in patients with tumor-positive surgical margins, but it is largely ineffective. The presence or absence of tumoral tissue at the surgical margin is a significant predictor of regional recurrence. While recurrence is observed at a rate of 4% among patients with tumor-negative surgical margins, this rate increases to 73% among patients with positive surgical margins (7). Factors that increase survival; absence of metastasis, no regional recurrence, being under 50 years old and tumor grade (8,9,10). 5-year overall survival (OS) is between 64-80% (7,8,11). Distant metastases usually occur to the lung.

**Osteosarcoma:** Although it is the most common malignant primary bone tumor, it is the second most common malignant primary bone tumor of the chest wall after chondrosarcoma. It constitutes 10% to 15% of malignant tumors of the chest wall. It is more common in young adult males. It manifests itself as a rapidly growing painful mass. It has a poor prognosis. It is typical to occur with costa, clavicle or scapula involvement (1,2,6). Unlike chondrosarcomas, it responds positively to chemotherapy. Surgical treatment is applied after neoadjuvant chemotherapy (1,12). It tends to metastasize distantly and metastasizes mostly to the

lung, lymph nodes and liver. The presence of metastases despite effective treatment reduces the 5-year survival to 15% (2). Tumor burden, tumor response to chemotherapy, and presence of metastases are the factors that have the greatest impact on OS (6).

**Ewing's sarcoma:** It is a small, round cell, malignant tumor with widespread (t11;22) and (q24;q12) translocations, belonging to the malignant primitive neuroectodermal tumors (PNETs) family. Approximately 15% of Ewing's sarcoma originates from the chest wall. This tumor, which constitutes 5% to 10% of malignant tumors of the chest wall, is frequently seen in the second decade of life. It is an aggressive tumor with regional recurrence and tendency to metastasize (2). Patients apply to the physician with complaints of pain and swelling. In the radiography, areas of bone destruction are observed in places. The appearance of "onion skin" due to periosteal elevation and subperiosteal new bone tissue formation is characteristic (1,13). Diagnosis is made by incisional biopsy. After neoadjuvant chemotherapy, wide regional excision followed by adjuvant chemotherapy forms the basis of treatment. Whether the tumoral area determined by detailed evaluations before treatment can be completely resected and the positive or negative response to chemotherapy are predictive of regional recurrence. The 5-year survival rate is over 60% in cases treated with chemotherapy and surgery (1,14). Although definitive radiation therapy is among the preferred methods, radiation therapy is mostly applied after surgical resection. Post-surgical radiation therapy is a method generally used in cases where the tumor cannot be completely resected or there is a negative response to adjuvant chemotherapy (15). At the time of diagnosis, 20-30% metastases can be detected. The most common metastases are to the lung, bone and bone marrow. Metastectomy can be applied in lung metastases (13).

**Solitary plasmacytoma/myeloma:** Costal solitary plasmacytoma is rare. It is the name given to the chest wall involvement of multiple myeloma. Pain without a detectable mass is the most common symptom. On radiological evaluation, lesions indicating bone destruction accompanied by cortical thinning and opacities around the rib are often found. Pathological fractures are common. The main treatment for solitary plasmacytoma is extensive radiotherapy. In radiotherapy-resistant cases, surgical resection can be performed to provide pain control. The most important prognostic factor in survival is the development of multiple myeloma. 5-year survival is between 40% and 60% (2).

**Desmoid tumor:** It is also called aggressive fibromatosis or desmoid fibromatosis. It is a tumor originating from fibroblasts or myofibroblasts. It is also thought to result from the proliferation of mesenchymal stem cell precursors (16). Although

most desmoid tumors are seen in the abdominal wall, the chest wall and shoulder girdle are also common areas outside the abdominal region. Its incidence increases in the second and third decades of life. Desmoid tumors can also be seen in patients diagnosed with familial adenomatous polyposis. Although it is not a malignant tumor histologically, it is considered a low-grade fibrosarcoma and is treated like a malignant tumor due to its tendency to grow into surrounding tissues, cause compression symptoms, and high recurrence rate (2,13). If technically possible, extensive surgical resection is the primary treatment method. Recurrence rates are higher in cases with microscopic tumor-positive surgical margins. It has been reported that the 5-year recurrence rate increased from 37% to 89% in cases with positive surgical margins (17). In cases of multiple relapses, tumors that cannot be completely resected, and cases with positive tumor margins, radiation therapy is applied, but its effectiveness is not clearly known (18). In cases where systemic treatment is indicated, the use of tamoxifen has been shown to be effective against desmoid tumors (19). There are also studies showing that the use of imatinib, a selective tyrosine kinase inhibitor, increases progression-free survival (20).

Undifferentiated pleomorphic sarcoma (UPS): This tumor, defined as malignant fibrous histiocytoma in previous classifications, is generally observed between the ages of 50 and 70 (1). The reason why it was called malignant fibrous histiocytoma in the past was because it was thought that this tumor might be of fibrohistiocytic origin. Thanks to electron microscopy, immunohistochemical techniques and advanced molecular studies, it has been revealed that there is no evidence in favor of fibrohistiocytic differentiation. In addition, after other poorly differentiated sarcomas were added to this group, the World Health Organization reclassified the tumor group defined as malignant fibrous histiocytoma as UPS in 2012 (21). Diagnosis is usually made by incisional biopsy. The main treatment is extensive surgical resection. Although radiation therapy and chemotherapy are not considered very effective, surgery and adjuvant chemotherapy can also be applied after neoadjuvant chemotherapy (1). Regional recurrence and distant metastasis are observed at high rates. Even in cases where extensive surgical resection was performed, regional recurrence rates are over 30% (22). In 30% to 50% of cases, metastatic lesions are present at the time of diagnosis. 5-year survival is 38% (2,23).

Rhabdomyosarcoma: It is the second most common malignant chest wall tumor in children. It is rare in adults. Following neoadjuvant chemotherapy and radiation therapy, extensive surgical resection is required. Adjuvant chemotherapy and radiation therapy are also

sometimes administered. 5-year survival is between 60% and 75% (24).

Malignant Peripheral Nerve Sheath Tumor: These are tumors associated with neurofibromatosis (2). Neurofibrosarcoma develops in approximately one-third of cases with neurofibromatosis (8). It typically presents as a painful, gradually growing mass. Malignant peripheral nerve sheath tumor, also called malignant schwannoma or neurofibrosarcoma, often arises from neurofibromas of intercostal nerves, brachial plexus or spinal nerve roots. These lesions tend to cause both regional recurrence and metastasis. In treatment, adjuvant chemotherapy is applied after surgical resection. In cases with positive tumor surgical margins, postoperative radiation therapy may be applied (1,8). 5-year survival is 55% (2,8).

Liposarcoma: It is most common in men between the ages of 40-60. The history may include trauma. In treatment, extensive regional surgical resection of the tumor is essential. Chemotherapy and radiation therapy have limited place. Regional recurrence rates are high. Tumor grade, surgical margin status and histological profile are associated with survival. 5-year survival is 60% (23).

Primary malignant tumors of the chest wall are very rare and there are few studies on this subject in the literature. Few studies have reported predominantly reconstruction materials, resection size, and recurrence rates. Studies investigating the relationship between histopathological subtype and survival in primary malignant tumors of the chest wall are also limited in the written literature. The aim of this study is to evaluate the effect of histopathological subtype on survival in primary malignant tumors of the chest wall.

In the current study, the determination of histopathological subtypes of patients who underwent chest wall resection due to a primary malignant tumor of the chest wall in our clinic; statistical comparison of 5-year and 10-year OS and disease-free survival (DFS) data among histopathological subtypes; in addition, it is aimed to determine the rates of regional tumor recurrence in patients.

## Material and Method

This study was conducted on patients who were operated on at the Department of Thoracic Surgery, Dr. Siyami Ersek Thoracic and Cardiovascular Surgery Training and Research Hospital, from December 2007 to December 2019, over a 13-year period. The study was designed in accordance with the Strengthening the Reporting of Observational studies in Epidemiology (STROBE) guidelines and the principles of the Declaration of Helsinki were adhered to.

#### *Study Design and Patient Characteristics*

Patients between the ages of 18-90 who were operated on in our clinic were included in the study. Benign tumors, regional invasion of the adjacent organ malignancies to the chest wall, and metastases of other primary malignancies were excluded. From December 2007 to December 2019, chest wall tumors were detected in 98 patients in our clinic. 60 patients were excluded from the study because of benign tumor pathology, 14 patients due to regional invasion of adjacent organ tumors (breast and lung) to the chest wall, and 4 patients due to metastasis of the primary tumor (colon carcinoma, parathyroid carcinoma) to the chest wall and/or lung. Twenty patients who met the inclusion criteria were included in the study.

Histopathological subtypes were determined by examining the medical records and pathology reports of the cases. Six subtypes were detected histopathologically in the patients included in the study. Chondrosarcoma in 7 patients, desmoid tumor in 6 patients, UPS in 4 patients, Ewing's sarcoma in 1 patient, malignant peripheral nerve sheath tumor in 1 patient and liposarcoma in 1 patient was detected.

Among the patients included in the study, there was 1 patient diagnosed with Ewing's sarcoma. She wasn't included in the survival analysis because she was in clinical remission at the 47th month of his clinical follow-up and 12 months according to the last follow-up date.

1 patient with liposarcoma and 1 patient with malignant peripheral nerve sheath tumor weren't included in the survival assessments because they could not provide statistically significant data. Both patients were alive as of the last follow-up date. Three histopathological subtypes (chondrosarcoma, desmoid tumor, and UPS) with a moderate sample size were included in the survival assessment and statistical analysis.

OS; it was defined as the time from the date of pathological diagnosis to the death of the patient from any cause or the last follow-up date of the patient. DFS; it was defined as the time from the date of pathological diagnosis to the detection of findings consistent with recurrence/metastasis in clinical evaluation and radiological imaging or death from any cause, or until the last follow-up date of the patient. The 5-year and 10-year OS data between the subtypes were statistically compared.

#### *Surgical Technique and Follow-Up*

The main principle in the surgery of malignant tumors of the chest wall is that the tumor can be resected at the pathological (R0) level. The main goal in chest wall resection is full-thickness R0 resection as wide as possible. In this study, the R classification, evolved by The Union for International Cancer Control (UICC) to "R+1 mm", was used. The minimal distance between tumor and resection margin of >1 mm, specimens were

considered microscopically negative. This condition was defined as R0. The minimal distance between tumor and resection margin of  $\leq 1$  mm, specimens were judged as microscopically positive. This condition was defined as R1. Macroscopic residual tumor was categorized as R2 (25). In chest wall resections, total surgical resection of the relevant tumor tissue with negative surgical margins is the most effective treatment. In the current study of us, the tumoral tissues were excised with the surrounding ribs and/or surrounding soft tissues. Wide resection was applied to prevent regional recurrences in patients. A minimum surgical margin of 2 cm has been attempted for low-grade tumors, and a surgical margin of 4-6 cm for high-grade sarcomas. Resection of the entire involved rib and partial resection of one rib above and below the rib with the tumor were performed. If necessary, reconstruction was performed for the defect formed after resection, to protect the underlying organs, to improve respiratory function, and for cosmetic reasons. The cases included in the study were operated by five different surgeons.

Follow-up evaluation after surgery consisted of regular physical examination and imaging. In addition to physical examination findings, thoracic computed tomography (CT) and positron emission tomography (PET) findings were used in the follow-up of the patients and in the evaluation of the recurrence status. Follow-up physical and radiological examinations of the patients, starting from the date of diagnosis of the tumor, at 6-month intervals during the first 5 years; after completing 5 years, it was applied in the form of annual control examinations. Control thorax CT examination was routinely performed at the 3rd month following the surgical intervention. Thoracic CT examination if deemed necessary or suspected of recurrence; PET and magnetic resonance imaging (MRI) was preferred. Central Population Management System records and Death Notification System records were used to determine survival status.

World Health Organization guidelines were used in histopathological classification (21).

#### *End Point of the Research*

Evaluation of the effect of histopathological subtype on 5-year and 10-year OS in primary malignant tumors of the chest wall is the primary endpoint of this study.

Determination of regional recurrence rates in patients; evaluation of the effect of tumoral grade, location, metastatic disease, and surgical margin on regional recurrence and OS were the secondary endpoints of this study.

#### *Statistical Analysis*

SPSS version 21 package program was used to analyze the data. Frequency and percentage values were used for qualitative variables, median values

were used for quantitative variables. Normality test was performed and it was evaluated whether the data were normally distributed. Kaplan Meier method was used in the examinations in terms of survival and recurrence times, and the Log Rank test was used for comparisons. Continuous data are given as median (25% percentiles, 75% percentiles). Mann Whitney U test was performed for ordinal or continuous values which were distributed not normally. Finding a p-value less than 0.05 in the study was considered statistically significant.

## Results

The median age of the patients was 60[ Interquartile range (IQR) %25-%75, 40:69]; median

overall survival (mOS) 74 months (IQR %25-%75, 27:108.5); median disease-free survival (mDFS) was 52 months (IQR %25-%75, 17.5:104.5).

Specific to histopathological subtypes, the clinical data of the patients are summarized in Table 1.

When all histopathological subtypes were evaluated together, the regional recurrence rate was 45%. Considering the subtypes, regional recurrence rates were 57% in the chondrosarcoma group; 17% in the desmoid tumor group; it was found to be 75% in the UPS group.

Descriptive statistics of the patients, disease and treatment characteristics are shown in Table 2.

**Table 1.** Clinical and histopathological features of the patients included in the study. The chart was arranged primarily by histopathological subtype.

Age	Sex	Chest Wall Position	Histopathological Subtype	Grade	R	Repair and/or Reconstruction	Neoadjuvant Treatment	Adjuvant Treatment
45 <sup>1</sup>	Male	Posterior	Chondrosarcoma	Medium	R0	Primary Repair		Chemotherapy
71	Female	Anterior	Chondrosarcoma	Low	R0	Polypropylene Mesh		
71	Female	Anterior	Chondrosarcoma	Low	R0	Polypropylene Mesh		Radiotherapy
79 <sup>1</sup>	Female	Anterior	Chondrosarcoma	Medium	R1	Polypropylene Mesh		Radiotherapy
72	Male	Anterior	Chondrosarcoma	Medium	R0	Polypropylene Mesh		
58 <sup>1</sup>	Female	Posterior	Chondrosarcoma	Medium	R1	Polypropylene Mesh	Chemotherapy	
48 <sup>1</sup>	Female	Posterior	Chondrosarcoma	Medium	R0	Primary Repair		
54 <sup>1</sup>	Male	Anterior	UPS	High	R0	Polypropylene Mesh + Skin Islanded Pediculated Muscle Flap + Free Skin Graft	Chemotherapy	Chemotherapy + Radiotherapy
71 <sup>1</sup>	Male	Posterior	UPS	High	R2	Primary Repair	Radiotherapy	
60	Female	Lateral	UPS	High	R0	Titanium Plate + Polypropylene Mesh		Chemotherapy + Radiotherapy
72 <sup>1</sup>	Male	Lateral	UPS	High	R1	Primary Repair		Chemotherapy + Radiotherapy
42 <sup>1</sup>	Female	Anterior	Desmoid Tumor	Low	R0	Primary Repair		Radiotherapy
82	Female	Anterior	Desmoid Tumor	Low	R0	Polypropylene Mesh		Radiotherapy
70	Male	Posterior	Desmoid Tumor	Low	R0	Primary Repair		Radiotherapy
74	Male	Lateral	Desmoid Tumor	Low	R0	Polypropylene Mesh		
66	Male	Posterior	Desmoid Tumor	Low	R0	Primary Repair		Radiotherapy
44	Female	Posterior	Desmoid Tumor	Low	R0	Titanium Plate + Polypropylene Mesh		Radiotherapy
21	Female	Anterior	Ewing 's sarcoma	Medium	R0	Dual Mesh	Chemotherapy	Chemotherapy + Radiotherapy
82 <sup>1</sup>	Male	Anterior	Malignant Peripheral Nerve Sheath Tumor	High	R0	Titanium Mesh + Muscle Transposition		
49	Male	Anterior	Liposarcoma	Low	R0	Primary Repair		

R: Resection, UPS: Undifferentiated pleomorphic sarcoma<sup>1</sup>. These patients underwent repeated surgeries due to recurrences.

**Table 2.** Descriptive statistics of patients, disease and treatment characteristics

	N		N
<b>Gender</b>		<b>Grade</b>	
Male	10	Low	9
Female	10	Medium	6
<b>Mortality</b>		High	5
Alive	10	<b>Preoperative diagnosis</b>	
Ex	10	Undiagnosed	11
<b>Relapse</b>		Diagnosed	9
None	11	<b>Frozen section examination during surgery</b>	
Yes	9	None	7
<b>Type</b>		Yes	13
CS	7	<b>Neoadjuvant KT</b>	
DT	6	None	17
ES	1	Yes	3
UPS	4	<b>Neoadjuvant RT</b>	
OSTS	2	None	19
<b>Complaints</b>		Yes	1
Pain	5	<b>Adjuvant KT</b>	
Palpable mass	8	None	15
Growth in mass	7	Yes	5
<b>Location</b>		<b>Adjuvant RT</b>	
Anterior wall	10	None	10
Lateral wall	3	Yes	10
Posterior wall	7	<b>Complication</b>	
<b>Metastasis</b>		None	15
None	18	Yes	5
Yes	2	<b>Origin of tumor</b>	
		Bone-cartilage	8
		Soft tissue	12

CS: Chondrosarcoma; DT: Desmoid tumor; UPS: Undifferentiated pleomorphic sarcoma; OSTs: Other soft tissue sarcomas

Comparison mDFS of subgroups are presented in Table 3.

When the relationship between histopathological subtype and survival was examined, a statistically significantly lower survival time was found in the UPS subtype. In addition, a significant statistical relationship was found between the location of the tumor and the survival time. Comparison mOS of subgroups are shown in Table 4.

In the chondrosarcoma subtype, the 5-year and 10-year OS rate was respectively, 71% and 37%. The 5-year and 10-year OS rate in desmoid tumors was respectively, 83% and 42%. There were no patients in the UPS group with an OS of 5 years [(p=0.004), (Figure 1A)].

There was no patient with 5-year survival in chest wall tumors located in the lateral wall. The 5-year OS rate for tumors located in the posterior wall was 57%. For tumors located in the anterior wall, the 5-year and 10-year OS rate was respectively, 90% and 53% [(p=0.001), (Figure 1B)].

In patients with negative surgical margins, the 5-year and 10-year OS rate was respectively, 75% and 52%. The 5-year OS rate was found to be 25% in patients with positive surgical margins. No patients showed an OS of 10 years [(p=0.025), (Figure 1C)].

While there was no patient with a 5-year OS in patients with distant metastases; in cases without

metastasis, the 5-year OS rate was 72%, and the 10-year OS rate was 43% [(p=0.008), (Figure 1D)].

When the relationship between pathological cell type and DFS was examined, the 5-year and the 10-year DFS rate was 43% in the chondrosarcoma subtype. The 5-year and 10-year DFS rate in desmoid tumors was calculated as 80%. No patients showed 5-year DFS in UPSs [(p=0.002), (Figure 1E)].


In patients with negative surgical margins, the 5-year and 10-year DFS rate was 64%. There was no patient with 5-year DFS in patients with positive surgical margins [(p=0.001), (Figure 1F)].

When the relationship between DFS and tumor grade was examined, the 5-year and 10-year DFS rates were found to be 88% in low-grade tumors. In moderate tumors, the 5-year and 10-year DFS was 33%. No patients showed 5-year DFS in high-grade tumors [(p=0.003), (Figure 1G)].

## Discussion

### Chondrosarcoma

In our study, the 5-year and the 10-year DFS rate in the chondrosarcoma was 43%. The available data are similar to the previous study (27). Compared to some studies in the literature (8,39), we can attribute the lower survival rate in our study to the fact that the R1 resection rate of the patients was 29%.



**Figure 1.** A) Estimated OS curves by histopathological subtype. B) Estimated OS curves by tumor location C) Estimated OS curves by resection status. D) Estimated OS curves by metastasis. E) Estimated DFS curves by histopathological subtype. F) Estimated DFS curves by resection status. G) Estimated DFS curves by tumor grade.

In our study, 5-year and 10-year OS rate in the chondrosarcoma subtype was 71% and 37%. Previous studies in the literature (7,8,9,29-34); 5-year OS, 73.6%-80%; the 10-year OS is in the range of 64-80%. We obtained low survival values according to the literature in both survival parameters. In the current study, 58% of patients with a diagnosis of chondrosarcoma were over 70 years of age. In the study of Shewale et al., it was stated that age progression is an independent negative predictor of OS (29). In previous studies (8,9,29,32,34), the median age varied between 45 and 60; in our study, the median age was found to be 63.4 years in the chondrosarcoma subtype. Considering the data obtained in previous studies (8,28,29,34), the high average age of the patients in our study can be shown as the reason for the low OS rates.

In addition, 71% of chondrosarcoma patients had the first surgical intervention performed in another center (redo case), which may be among the reasons for the low survival rates.

#### Desmoid tumor

The reason why the DFS, which was calculated as 80% in the desmoid tumor, was slightly higher than in previous studies (17,34), may be the fact that R0 resection was achieved in all desmoid tumors in our study.

In our study, regional recurrence was observed in 17% of the desmoid tumor subtype. The first surgical intervention of all patients in this group was performed by us. In the current study, the 5-year and the 10-year OS rate for desmoid tumors was calculated as 83% and 42%.

**Table 3.** Comparison mDFS of subgroups

	mDFS (month)	(95% CI)	p
<b>Gender</b>			
Male(n=10)	52	(33.2-99.5)	0.732
Female(n=10)	50.5	(40.2-111.6)	
<b>Histopathological subtype</b>			
CS(n=7)	23	(22.3-102.5)	<b>0.002</b>
DT(n=6)	74	(64.8-134.7)	
UPS(n=4)	11.5	(1-16.7)	
<b>Origin of tumor</b>			
Bone-cartilage(n=8)	28.5	(32.3-108.1)	0.940
Soft tissue(n=12)	60	(40.3-102.9)	
<b>Complaint</b>			
Pain(n=5)	81	(66.9-134.9)	0.329
Palpable mass(n=8)	60	(20.6-104)	
Growth in mass(n=7)	51	(18.1-67)	
<b>Location</b>			
Anterior wall(n=10)	77.5	(48.4-114.8)	0.566
Lateral wall(n=3)	68	(16.2-84.5)	
Posterior wall(n=7)	23	(20.7-78.5)	
<b>Metastasis</b>			
None(n=18)	52	(49.2-100.5)	0.159
Yes(n=2)	42	(16.9-58.7)	
<b>Grade</b>			
Low(n=9)	102	(87.6-135.6)	<b>0.003</b>
Medium(n=6)	20.5	(10.9-90.3)	
High(n=5)	16	(0-43)	
<b>Resection</b>			
R0(n=16)	68	(63-114.4)	<b>0.001</b>
R1/R2(n=4)	16	(5.1-17)	
<b>Surgical Border</b>			
> 4 cm(n=3)	121	(113.4-124.6)	0.064
2-4 cm(n=10)	42.5	(49.8-118)	
< 2 cm(n=3)	17	(6.9-54.2)	

mDFS: Median Disease-Free Survival; CI: Confidence interval; KS: Chondrosarcoma; DT: Desmoid tumor; UPS: Undifferentiated pleomorphic sarcoma

#### UPS

No patient achieved a 5-year DFS in the UPS subtype. Compared to previous studies (27,34,39); among the reasons for the low survival rate in this group, both the histopathological subtype diversity in other studies and the high R1 resection rate of 50% in patients with UPS included in our study can be counted.

The diagnosis of UPS can be made after diagnosing malignant tumors with similar morphological findings, such as malignant melanoma, sarcomatoid carcinomas, anaplastic lymphoma, or other types of sarcoma (35).

Some authors include UPS in the group of heterogeneous and unclassified tumors in pleomorphic morphology (36).

In a study by Bagheri et al., it was revealed that the mortality rate was significantly higher in soft tissue sarcoma subgroups such as UPS, and the presence of distant metastases was one of the main factors affecting survival (37). King et al. stated that the prognosis in chest wall chondrosarcomas was significantly better than in patients with UPS. The 5-year OS rate was found to be 38% in the UPS group (32). In our study, there was no patient with a 5-year OS in the patient group with UPS histopathology. As

one of our cases, a 60-year-old female patient who was diagnosed with UPS and underwent chest wall resection and reconstruction is shown in Figure 2.

Sawai et al. reported the mOS as 23.2 months in patients who underwent surgical treatment for chest wall UPS (38). In our study, mOS of 15.5 months was found in UPS.

#### Location and Surgical Margin

The location of the tumor tissue on the chest wall can be important in terms of providing resection in a way that ensures negativity of the surgical margin. In our study, the OS probability of 5 years was zero in tumors located in the lateral wall.

The relationship between resection and surgical margin status and OS was evaluated. High-grade tumors accounted for 25% of the patients included in our study. R0 resection in 80% of the patients in our study; R1-R2 resection was performed in 20% of them. Compared to previous studies (8,29), the high rate of R1 resection in our study may explain the low 5 and 10-year OS rates.

#### Regional Recurrence and Distant Metastasis

Rahman et al., in their study, stated that histopathological subtype and surgical margin

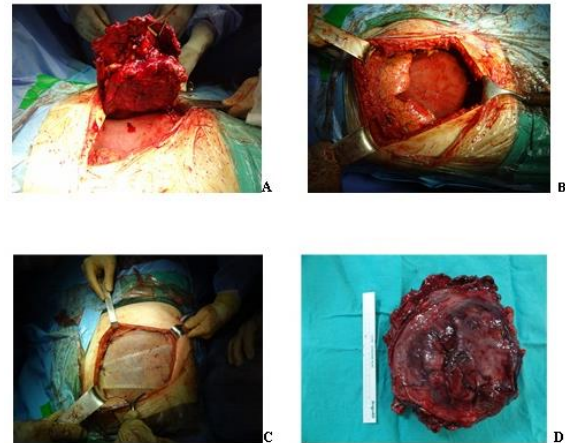


positivity increased regional recurrence rates (26). When Shah et al. examined the 115 patients who underwent surgical resection for primary malignant tumor of the chest wall, the regional recurrence rate was 50%; distant metastasis rate was 38% (40). In our study, when all histopathological subtypes were evaluated together, the regional recurrence rate was 45%; distant metastasis rate was 10%. Considering the subtypes, regional recurrence rates were 57% for chondrosarcoma, desmoid tumor and UPS, respectively; it was determined as 17% and 75%. In both patients with distant metastases, the histopathological subtype of UPS was present and the organ with metastasis was the lung.

#### Limitations

There were also some limitations in our study. Especially the small number of patients included in our study; our results make it difficult to generalize our observations. In addition, the study was carried out retrospectively; although the surgeries are performed by 5 different surgeons, they reflect the experiences of a single center; the absence of a standard resection and reconstruction protocol; the histopathological subtype diversity of the tumors included in the study; evaluation of subtypes with poor prognosis and subtypes with slower invasion

and metastasis negatively affects our generalization of OS and regional recurrence results.



**Figure 2.** Chest wall resection and reconstruction performed on a 60-year-old female patient with a diagnosis of UPS. A) Fragment of resected chest wall (Patient's head is at 9 o'clock). B) Defect after chest wall resection. C) Reconstruction with polypropylene mesh and titanium plates. D) Chest wall specimen removed with tumoral tissue. (From the archive of Dr. Mehmet YILDIRIM)

**Table 4.** Comparison mOS of subgroups

	mOS (month)	(95% CI)	P
<b>Gender</b>			
Male(n=10)	48	(41.65-103.72)	0.776
Female(n=10)	104	(71.03-125.15)	
<b>Relapse</b>			
None(n=11)	81	(73.87-126.48)	0.295
Yes(n=9)	45	(36.26-98.53)	
<b>Histopathological subtype</b>			
CS(n=7)	107	(64.5-124.7)	<b>0.004</b>
DT(n=6)	74	(68.5-135.4)	
UPS(n=4)	15.5	(4.6-29.8)	
<b>Complaint</b>			
Pain(n=5)	81	(76.81-127.62)	0.998
Palpable mass(n=8)	60.5	(30.93-105.82)	
Growth in mass(n=7)	67	(56.65-125.09)	
<b>Location</b>			
Anterior Wall(n=10)	108.5	(89.1-131)	<b>0.001</b>
Lateral Wall(n=3)	9	(0-33.2)	
Posterior Wall(n=7)	51	(45.1-108.1)	
<b>Metastasis</b>			
None(n=18)	90.5	(72.21-114.64)	<b>0.008</b>
Yes(n=2)	19	(0-47.23)	
<b>Grade</b>			
Low(n=9)	102	(85-131.8)	0.130
Medium(n=6)	72.5	(56-122.2)	
High(n=5)	21	(0.5-75.8)	
<b>Resection</b>			
R0(n=16)	81	(73.1-118.8)	<b>0.025</b>
R1/R2(n=4)	33	(2.2-92.1)	
<b>Surgical Border</b>			
> 4 cm(n=3)	113	(105.4-124.6)	0.324
2-4 cm(n=10)	66	(61.5-120.7)	
< 2cm(n=3)	33	(26.1-98.8)	

mOS: Median Overall Survival; CI: Confidence interval; CS: Chondrosarcoma; DT: Desmoid tumor; UPS: Undifferentiated pleomorphic sarcoma

## Conclusion

The UPS, which is among the primary malignant tumors of the chest wall, the OS rates of 5 and 10 years, and the mOS; it was concluded that it was significantly lower than chondrosarcoma and desmoid tumor, which are the other histopathological subtypes in our study. It was determined that the DFS and regional recurrence rates of patients who underwent surgery for UPS were significantly shorter compared to the chondrosarcoma and desmoid tumor groups.

We believe that the results obtained will contribute to future studies and meta-analysis. We think that it is important to plan patient-specific treatment involving multiple medical disciplines and to remove the tumoral tissue with the surrounding tissue in a way that will ensure surgical margin negativity.

## Conflict of interest statement

There is no conflict of interest in our study.

**Ethics Committee Approval:** Approval was obtained from the Haydarpaşa Numune Training and Research Hospital Clinical Research Ethics Committee (Approval Number: HNEAH-KAEK 2019/106).

## References

1. Smith SE, Keshavjee S. Primary chest wall tumors. *Thorac Surg Clin.* 2010;20(4):495-507.
2. Demirkaya A. Göğüs duvarı primer ve malign tümörleri. *Türkiye Klinikleri J Thor Surg-Special Topics.* 2018;9(1):123-30.
3. Cipriano A, Burfeind W Jr. Management of primary soft tissue tumors of the chest wall. *Thorac Surg Clin.* 2017;27:139-47.
4. Pairolero PC. Chest wall tumors. In: Shields TW, LoCicero J, Ponn RB, eds. *General Thoracic Surgery.* Philadelphia: Lippincott Williams&Wilkins, 2000: 589-608.
5. Somers J, Faber LP. Chondroma and chondrosarcoma. *Semin Thorac Cardiovasc Surg.* 1999;11:270-7.
6. Shah AA, D'Amico TA. Primary chest wall tumors. *J Am Coll Surg.* 2010;210(3):360-6.
7. Widhe B, Bauer HC. Surgical treatment is decisive for outcome in chondrosarcoma of the chest wall: a population-based Scandinavian Sarcoma Group study of 106 patients. *J Thorac Cardiovasc Surg.* 2009;137(3):610-4.
8. Marulli G, Duranti L, Cardillo G, et al. Primary chest wall chondrosarcomas: results of surgical resection and analysis of prognostic factors. *Eur J Cardiothorac Surg.* 2014;45(6):e194-201.
9. Burt M, Fulton M, Wessner-Dunlap S, et al. Primary bony and cartilaginous sarcomas of chest wall: results of therapy. *Ann Thorac Surg.* 1992;54:226-32.
10. McAfee MK, Pairolero PC, Bergstralh EJ, et al. Chondrosarcoma of the chest wall: factors affecting survival. *Ann Thorac Surg.* 1985;40(6):535-41.
11. Gonfiotti A, Santini PF, Campanacci D, et al. Malignant primary chest-wall tumours: techniques of reconstruction and survival. *Eur J Cardiothorac Surg.* 2010;38(1):39-45.
12. Bielack SS, Carrle D, Hards J, et al. Bone tumors in adolescents and young adults. *Curr Treat Options Oncol.* 2008;9(1):67-80.
13. Oğuzkaya F, Hasdrız L. Göğüs duvarı tümörleri. Ökten İ, Kavukçu HŞ, editör. *Göğüs Cerrahisi.* 2. Baskı. İstanbul: İstanbul Tıp Kitabevi; 2013.p.1455-1461.
14. Shamberger RC, Laquaglia MP, Gebhardt MC, et al. Ewing sarcoma/primitive neuroectodermal tumor of the chest wall: impact of initial versus delayed resection on tumor margins, survival, and use of radiation therapy. *Ann Surg.* 2003;238:563-8.
15. Denbo JW, Shannon Orr W, Wu Y, et al. Timing of surgery and the role of adjuvant radiotherapy in Ewing sarcoma of the chest wall: a single-institution experience. *Ann Surg Oncol.* 2012;19(12):3809-15.
16. Wu C, Amini-Nik S, Nadesan P, et al. Aggressive fibromatosis (desmoid tumor) is derived from mesenchymal progenitor cells. *Cancer Res.* 2010;70:7690-8.
17. Abbas AE, Deschamps C, Cassivi SD, et al. Chest-wall desmoid tumors: results of surgical intervention. *Ann Thorac Surg.* 2004;78(4):1219-23.
18. Bolke E, Krasniqi H, Lammering G, et al. Chest wall and intrathoracic desmoid tumors: surgical experience and review of the literature. *Eur J Med Res.* 2009;14:240-3.
19. Bonvalot S, Eldweny H, Haddad V, et al. Extra-abdominal primary fibromatosis: Aggressive management could be avoided in a subgroup of patients. *Eur J Surg Oncol.* 2008;34:462-8.
20. Dufresne A, Bertucci F, Penel N, et al. Identification of biological factors predictive of response to imatinib mesylate in aggressive fibromatosis. *Br J Cancer.* 2010;103:482-5.
21. Fletcher CDM, Bridge JA, Hogendoorn PCW, et al. WHO classification of tumours of soft tissue and bone. Lyon: IARC Press, 2013.
22. Yoshida N, Miyanari N, Yamamoto Y, et al. Successful treatment of malignant fibrous histiocytoma originating in the chest wall: report of a case. *Surg Today.* 2006;36(8):714-21.
23. Gallo AE. *The Johns Hopkins manual of cardiothoracic surgery.* New York: McGraw-Hill; 2007.
24. Hayes-Jordan A, Stoner JA, Anderson JR, et al. The impact of surgical excision in chest wall rhabdomyosarcoma: a report from the Children's Oncology Group. *J Pediatr Surg.* 2008;43:831-6.
25. Wittekind C, Compton CC, Greene FL, et al. TNM residual tumor classification revisited. *Cancer.* 2002;94:2511-6.
26. Abdel Rahman ARM, Rahouma M, Gaafar R, et al. Contributing factors to the outcome of primary malignant chest wall tumors. *J Thorac Dis.* 2017;9(12):5184-93.
27. Yoon SH, Jung JC, Park IK, et al. Clinical outcomes of surgical treatment for primary chest wall soft tissue sarcoma. *Korean J Thorac Cardiovasc Surg.* 2019;52(3):148-54.
28. Harati K, Kolbenschlög J, Bohm J, et al. Long-term outcomes of patients with soft tissue sarcoma of the chest wall: analysis of the prognostic significance of microscopic margins. *Oncol Lett.* 2018;15(2):2179-87.
29. Shewale JB, Mitchell KG, Nelson DB, et al. Predictors of survival after resection of primary sarcomas of the chest wall-A large, single-institution series. *J Surg Oncol.* 2018;118(3):518-24.
30. Singer S, Corson JM, Demetri GD, et al. Prognostic factors sarcoma. *Ann Surg.* 1995;221:185-95.
31. Ito T, Suzuki H, Yoshino I. Mini review: surgical management of primary chest wall tumors. *Gen Thorac Cardiovasc Surg.* 2016;64(12):707-14.
32. King RM, Pairolero PC, Trastek VF, et al. Primary chest wall tumors: factors affecting survival. *Ann Thorac Surg.* 1986;41:597-601.
33. Friesenbichler J, Leithner A, Maurer-Ertl W, et al. Surgical therapy of primary malignant bone tumors and soft tissue sarcomas of the chest wall: a two-institutional experience. *Int Orthop.* 2014;38:1235-40.
34. van Geel AN, Wouters MW, Lans TE, et al. Chest wall resection for adult soft tissue sarcomas and chondrosarcomas: analysis of prognostic factors. *World J Surg.* 2011;35(1):63-9.
35. Hamza A, Alrajjal A, Edens J, et al. Utility of additional tissue sections in surgical pathology. *Int J Surg Pathol.* 2018;26(5):392-401.

36. Hornick JL. Practical soft tissue pathology: a diagnostic approach, 2nd ed. Philadelphia: Elsevier, 2019.
37. Bagheri R, Haghi SZ, Kalantari MR, et al. Primary malignant chest wall tumors: analysis of 40 patients. *J Cardiothorac Surg.* 2014;9:106.
38. Sawai H, Kamiya A, Kurahashi S, et al. Malignant fibrous histiocytoma originating from the chest wall: report of a case and collective review of cases. *Surg Today.* 1998;28:459-63.
39. Kuwahara H, Salo J, Nevala R, et al. Single-institution, multidisciplinary experience of soft tissue sarcomas in the chest wall. *Ann Plast Surg.* 2019;83(1):82-8.
40. Shah AC, Komperda KW, Mavanur AA, et al. Overall survival and tumor recurrence after surgical resection for primary malignant chest wall tumors: a single-center, single-surgeon experience. *J Orthop Surg (Hong Kong).* 2019;27(2):2309499019838296.