



# The success of volumetric means ADC in predicting MGMT promoter hypermethylation in glioblastomas

 Serhat Korkmaz<sup>1</sup>,  Emin Demirel<sup>2</sup>

<sup>1</sup>Department of Neurosurgery, Faculty of Medicine, Afyonkarahisar University of Health Sciences, Afyonkarahisar, Turkey

<sup>2</sup>Department of Radiology, Afyonkarahisar State Hospital, Afyonkarahisar, Turkey

**Cite this article as:** Korkmaz S, Demirel E. The success of volumetric means ADC in predicting MGMT promoter hypermethylation in glioblastomas. *J Health Sci Med.* 2023;6(4):767-771.

Received: 09.06.2023

Accepted: 01.07.2023

Published: 30.07.2023

## ABSTRACT

**Aims:** This study aimed to investigate the relationship between volumetric mean ADC values and MGMT promoter hypermethylation status in glioblastoma (GB) patients segmented into perilesional edema area, solid tumor area, and necrosis area.

**Methods:** The 212 GB patients in the University of California San Francisco Preoperative Diffuse Glioma MRI (UCSF-PDGM) dataset were retrieved from the Cancer Imaging Archive (TCIA). The mean volumetric ADC value was calculated in patients with shared segmentation data in the UCSF-PDGM dataset. The difference in mean volumetric ADC value was investigated in patients divided into groups based on MGMT promoter hypermethylation (MGMT+/ MGMT-).

**Results:** Of the patients in our study, 125 (59.0%) were male. The median age of the patients was 62 years (26-94). MGMT promoter hypermethylation was observed in 152 (71.7%) patients. Mean Survival was calculated as 574.14±345.57 days in the MGMT+ group and 484.68±301.71 days in MGMT- group. According to volumetric mean ADC values, a difference was observed in the solid tumor and perilesional edema areas according to MGMT promoter hypermethylation ( $p < 0.001$ ). In the ROC analysis, the AUC value was calculated as 0.897 for the edema area and 0.812 for the solid tumor area. MGMT+ group could be identified with a cut-off value of  $>1.14$  in ADC measurements from the edema area with 72% sensitivity and 90% specificity. MGMT+ group could be determined with a sensitivity of 88% and specificity of 69% with a cut-off value of  $>1.01$  in ADC measurements from the solid tumor area.

**Conclusion:** Volumetric ADC measurements from the perilesional edema and solid tumor areas revealed higher ADC values in the MGMT+ group.

**Keywords:** Glioblastoma, diffusion magnetic resonance imaging, MGMT hypermethylation, apparent diffusion coefficient (ADC)

## INTRODUCTION

Glioblastoma (GB) is the most common and aggressive primary brain neoplasm. GB has a very poor prognosis, which is often explained by the molecular heterogeneity of its genome, leading to an unpredictable clinical course with unpredictable treatment response.<sup>1</sup> The 2016 WHO classification of central nervous system tumors added molecular features to the diagnostic criteria for gliomas, which were previously based on histological diagnosis, and with the 2021 edition, the term glioblastoma has been used only for isocitrate dehydrogenase (IDH) wild-type glial tumors.<sup>2</sup> O6-methylguanine-DNA methyltransferase (MGMT) repairs DNA damage induced by temozolomide, and therefore higher MGMT levels lead to temozolomide resistance. MGMT promoter hypermethylation (MGMT+) reduces MGMT protein expression, thereby increasing sensitivity to

temozolomide.<sup>3</sup> Previous studies have shown that MGMT hypermethylated patients with grade II or III glioma or glioblastoma have a longer overall survival time than those whose MGMT promoter is not methylated (MGMT-).<sup>4</sup>

Magnetic resonance imaging (MRI) is widely accepted as the preferred method for diagnosing and evaluating treatment response.<sup>5</sup> GB has an infiltrative growth pattern and may expand beyond the conventional radiologic margin into normal-appearing brain tissue. Standard MRI tests underestimate the true tumor size.<sup>6</sup> Diffusion-weighted imaging (DAG) is combined with other sequences to assess brain tissue function and physiology. Apparent diffusion coefficient (ADC) maps/values, a subset of DAG, represent Brownian motion in water molecules at a sub-voxel level.<sup>7</sup> ADC maps and

**Corresponding Author:** Serhat Korkmaz, drserhat57@gmail.com



This work is licensed under a Creative Commons Attribution 4.0 International License.

DAG are technically robust and can be obtained without administering a contrast agent. Since the extracellular volume fraction is linked to water diffusion and is highly correlated with tissue cellularity, tissue edema, and tissue necrosis, DAG and ADC maps are helpful in the initial evaluation and post-treatment assessment of GBs.<sup>8,9</sup> Studies have shown that low ADC values before treatment are associated with high cellularity and overall Survival of glioma patients.<sup>10</sup> Furthermore, mean ADC values have been found to correlate with overall Survival.<sup>9</sup> ADC values have been used in differentiation in the challenging diagnostic dilemma of pseudoprogression and radiation necrosis.<sup>11</sup>

This study aimed to investigate the relationship between volumetric mean ADC values and MGMT promoter hypermethylation status in glioblastoma patients segmented into perilesional edema area, solid tumor area, and necrosis area.

## METHODS

### Ethics

With the decision of Afyonkarahisar University of Health Sciences Medical Ethics Committee dated 13.04.2023 and numbered 2023/4, it was decided that there was no need to obtain ethics committee approval for this study. All procedures were carried out in accordance with the ethical rules and the principles.

### Patient Selection

The 374 GB patients in the University of California San Francisco Preoperative Diffuse Glioma MRI (UCSF-PDGM) dataset<sup>12</sup> were retrieved from the Cancer Imaging Archive (TCIA).<sup>13</sup> Patient characteristics, including age, sex, pathologic grade, and genomic profile, were obtained from the TCIA. The TCIA data did not contain any personal identifying information; ethics committee approval and informed consent were obtained in the reference study of the open-source dataset.

Inclusion criteria were determined as follows: (a) patients with a pathologic diagnosis of primary (de novo) IDH wild type (glioblastoma), (b) patients with preoperative imaging DAG MR imaging data, (c) patients with gross total resectability of the lesion. Exclusion criteria were defined as (a) patients without MGMT mutation data; (b) cranial MR images with poor quality and artifacts. We included 212 glioblastoma patients who met the selection criteria.

### Segmentation and Average ADC Value Measurement

For patients with shared segmentation data in the UCSF-PDGM dataset, a series of operations were applied to the images of all patients before the mean volumetric ADC value was measured. Advanced Normalization tools

for Python, intensity normalization package, bias field correction, and Z-score normalization tools were used. Resampling of the images to 1 × 1 voxel spacing and resizing to 256 × 256 pixels was performed. Afterward, the mean ADC value was calculated in the areas of necrosis, solid tumor area, and perilesional edema. All these processes were performed with Slicer v 13 (<http://www.slicer.org>) (Figure 1).

### Ethics Committee

With the decision of Afyonkarahisar University of Health Sciences Medical Ethics Committee dated 13.04.2023 and numbered 2023/4, it was decided that there was no need to obtain ethics committee approval for this study.

### Statistical Analysis

Statistical analysis was conducted using R (R Core Team v. 3.6.1). The Shapiro-Wilk test and the one-sample Kolmogorov-Smirnov test were used to assess the normality of the data, which are presented in quantile-comparison plots and histograms. The data were normally distributed. Student's t-test was used to compare between groups. Overall p-values <0.05 were considered statistically significant. Receiver-operating characteristic (ROC) curves were generated for significant areas, and the area under the curve (AUC) was calculated.

## RESULTS

Of the patients included in our study, 125 (59.0%) were male. The median age of the patients was 62 years (26-94). MGMT promoter hypermethylation was observed in 152 (71.7%) patients. Mean Survival was calculated as 574.14±345.57 days in the MGMT+ group and 484.68±301.71 days in MGMT- group. Based on volumetric mean ADC values, a difference was observed in the solid tumor and perilesional edema areas according to MGMT promoter hypermethylation (p<0.001). No significant difference was observed between the two groups in the measurements made from the necrosis area. A more detailed evaluation can be seen in Table.

**Table.** MGMT promoter hypermethylation (MGMT+/MGMT-) glioblastomas patients data

	MGMT+mean (standard deviation)	MGMT-mean (standard deviation)	P value
Age (years)	61.90 (12.07)	61.93 (12.07)	0.985
Gender (male)	84 (55%)	41(68%)	0.081
Frequency (percentage)	574.14 (345.57)	484.68 (301.71)	0.05
Mean survival (days)	1.201 (0.114)	1.013 (0.094)	<0.001
Average ADC in the edema area	1.102 (0.101)	0.971 (0.110)	<0.001
Average ADC in solid area	1.28 (0.216)	1.31 (0.234)	0.289

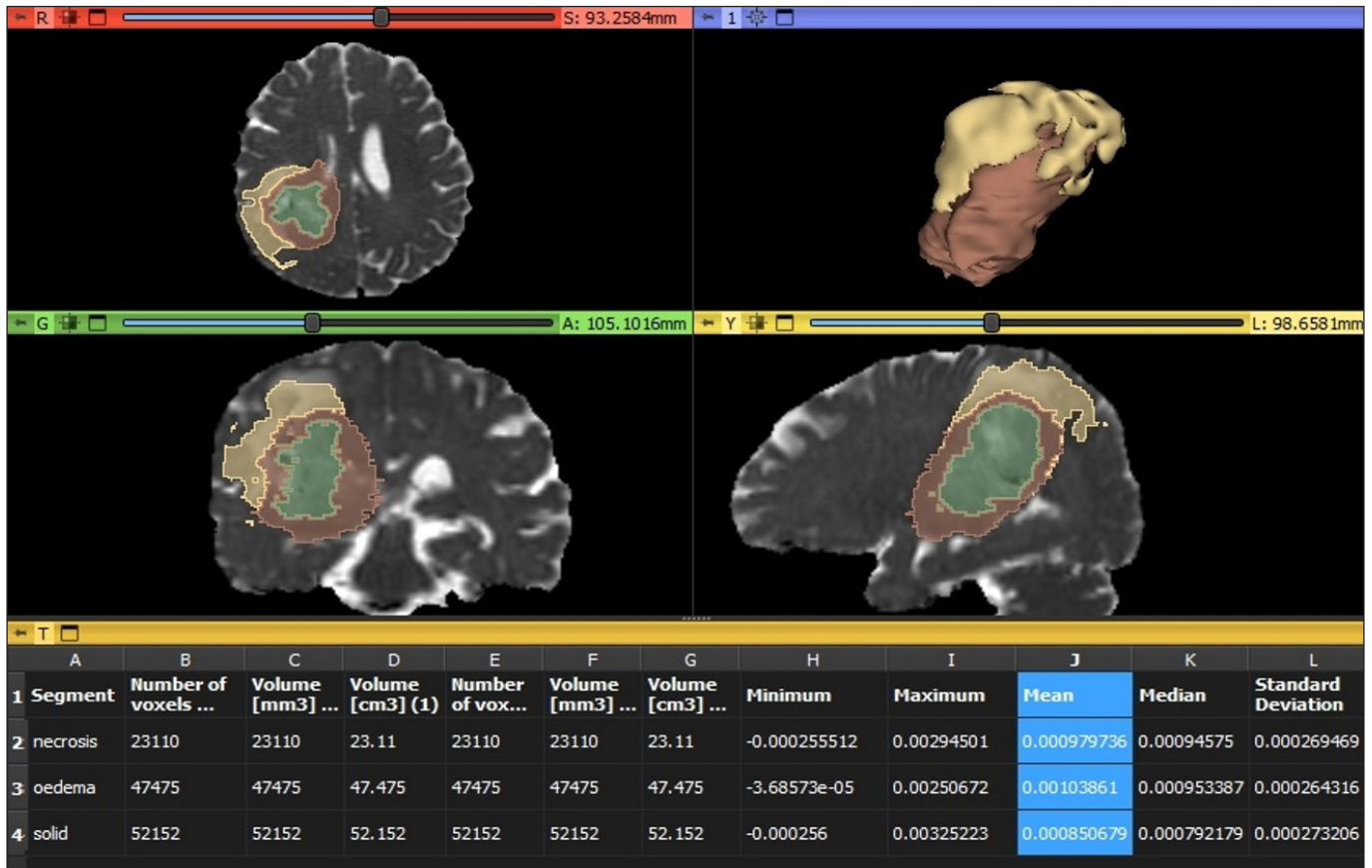


Figure 1. Measurement screen of 1 patient in Slicer 3D program. In the figure, green represents the necrosis area, brown represents the solid tumor area, and yellow represents the perilesional edema area.

In the ROC analysis, the AUC value for edema area was 0.897 (Figure 2) and 0.812 for solid tumor area (Figure 3). MGMT+ group could be identified with a cut-off value of >1.14 in ADC measurements from the edema area with 72% sensitivity and 90% specificity. MGMT+ group could be determined with a sensitivity of 88% and specificity of 69% with a cut-off value of 1.01 in ADC measurements made from the solid tumor area.

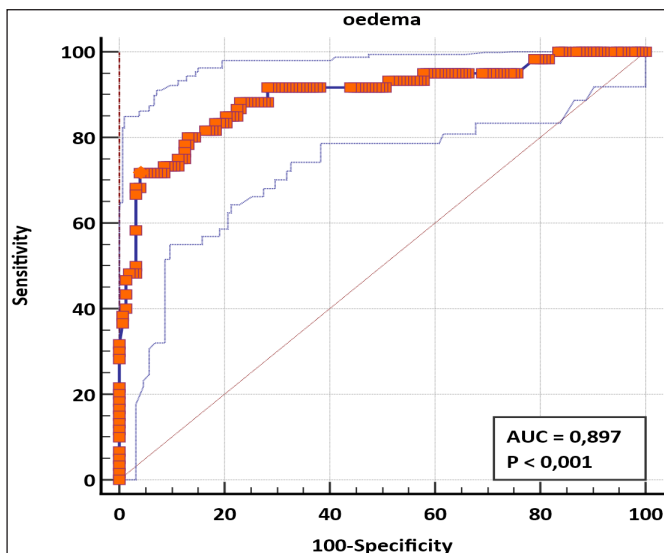


Figure 2. ROC analysis with volumetric mean ADC value from the perilesional edema area to determine MGMT status

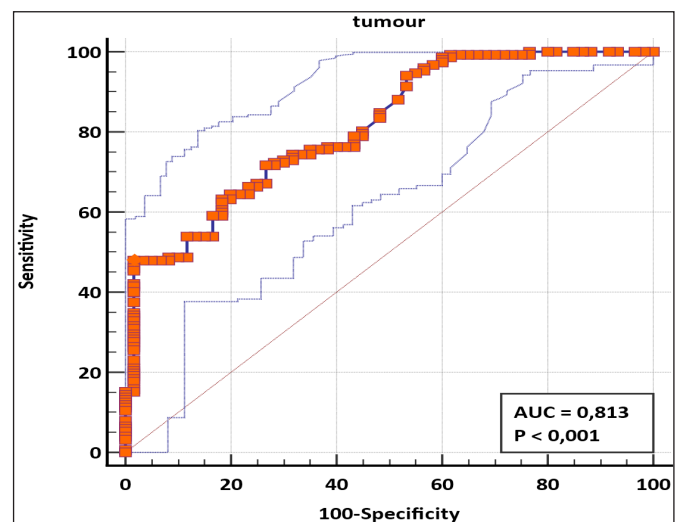


Figure 3. ROC analysis with volumetric mean ADC value from solid tumor area to determine MGMT status

### DISCUSSION

Our results showed that there were significant differences in the ADC values obtained from the perilesional edema area and solid tumor area of patients with GB, which correlated with the genetic profiles of MGMT methylation status.

MGMT methylation status is an important prognostic factor because the methylation level of MGMT corresponds to the therapeutic effects of chemotherapeutic alkylating agents such as temozolomide.<sup>14</sup> Although many studies have been conducted on the correlation of visual parameters (tumor location and laterality, enhancement features such as ring enhancement) and MGMT methylation status, there is still no generally accepted consensus.<sup>15</sup> Advances in radiologic diagnostics may lead to a development where molecular profiles can be predicted based on an initial MRI study, which could have major implications for treatment options prior to any surgical intervention (biopsy or resection).

In studies, lower ADC values have been associated with more malignant tumors and tumors with higher cellularity.<sup>16</sup> It has been suggested that radiologic reports of gliomas should include the locations of areas with the lowest ADC values. These low ADC areas and other imaging indices and features are considered the parts of these tumors with the most malignant potential.<sup>17,18</sup>

Our results did not find a significant difference based on the MGMT methylation status of the centrally located necrosis area. We think that this is predictable because the necrosis area does not contain significant cellularity.

Higher ADC values were measured in the area of perilesional edema in the MGMT+ group. We used a cut-off value of >1.14 to determine MGMT+ status. The perilesional T2-hyperintense white matter in GB also contains a significant amount of tumor invasion area, unlike the vasogenic edema areas found in other brain mass lesions with metastases.<sup>19</sup> Ladenhauf et al.<sup>20</sup> found lower ADC values in the peri-tumoral edema area in the MGMT+ group in their ROI-based measurement from the peritumoral area, which differs from our study. Unlike our study, ROI-based normalized ADC value was used, and a relatively small sample group of 42 patients was studied. We think this may be the reason for the difference between the results.

Higher ADC values were measured in the solid tumor area in the MGMT+ group. The MGMT+ group could be identified with a sensitivity of 88% and specificity of 69% with a cut-off value of >1.01 in ADC measurements. In a recent study by Xie et al.<sup>21</sup> IDH mutant and MGMT+ patients were compared with patients with other IDH and MGMT conditions. They found higher ADC values in the IDH mutant and MGMT+ group according to the results of ADC analysis and ADC histogram analysis. Although the study group was quite heterogeneous, similar results with our study are noteworthy. Choi et al.<sup>22</sup> found no correlation between ADC histogram analysis and MGMT status.

Diffusion imaging, one of the main neuroimaging examinations, both tumor imaging and neuroimaging obtained in other conditions, stores much more information than routine use. Without clear results, there is still much uncertainty about the relationship between ADC values and MGMT profile. The results of our study with the largest sample group in the literature on this subject are promising. Although we only evaluated the mean ADC value in our study, it can be evaluated more accurately in future studies with refined texture analysis-based artificial intelligence models,<sup>23</sup> of which there are many examples in glial tumors.

Our study has some important limitations. Since the study was planned retrospectively, no evaluation could be made regarding data such as performance status and other mutations, not in the patient's available data set.

## CONCLUSION

As a result, volumetric ADC measurements from the perilesional edema and solid tumor areas showed higher values in the MGMT+ group. It is promising that MGMT promoter hypermethylation, an important prognostic marker for glioblastoma, can be predicted preoperatively non-invasively with ADC maps. Future prospective studies, which may include more comprehensive texture analyses, will solidify the place of ADC analysis.

## ETHICAL DECLARATIONS

**Ethics Committee Approval:** With the decision of Afyonkarahisar University of Health Sciences Medical Ethics Committee dated 13.04.2023 and numbered 2023/4, it was decided that there was no need to obtain ethics committee approval for this study.

**Informed Consent:** Because the study was designed retrospectively, no written informed consent form was obtained from patients.

**Referee Evaluation Process:** Externally peer reviewed.

**Conflict of Interest Statement:** The authors have no conflicts of interest to declare.

**Financial Disclosure:** The authors declared that this study has received no financial support.

**Author Contributions:** All the authors declare that they have all participated in the design, execution, and analysis of the paper, and that they have approved the final version.

## REFERENCES

1. Vigneswaran K, Neill S, Hadjipanayis CG. Beyond the World Health Organization grading of infiltrating gliomas: advances in the molecular genetics of glioma classification. *Ann Transl Med.* 2015;3(7):95. doi: 10.3978/j.issn.2305-5839.2015.03.57

2. McNamara C, Mankad K, Thust S, et al. 2021 WHO classification of tumours of the central nervous system: a review for the neuroradiologist. *Neuroradiology*. 2022;64(10):1919–1950.
3. Chen R, Smith-Cohn M, Cohen AL, Colman H. Glioma subclassifications and their clinical significance. *Neurotherapeutics*. 2017;14(2):284–297.
4. Haque W, Teh C, Butler EB, Teh BS. Prognostic and predictive impact of MGMT promoter methylation status in high risk grade II glioma. *J Neurooncol*. 2022;157(1):137–146.
5. Wen PY, Macdonald DR, Reardon DA, et al. Updated response assessment criteria for high-grade gliomas: response assessment in neuro-oncology working group. *J Clin Oncol*. 2010;28(11):1963–1972.
6. Watanabe M, Tanaka R, Takeda N. Magnetic resonance imaging and histopathology of cerebral gliomas. *Neuroradiology*. 1992;34:463–469.
7. Schaefer PW, Grant PE, Gonzalez RG. Diffusion-weighted MR imaging of the brain. *Radiology*. 2000;217(2):331–345.
8. Yamasaki F, Sugiyama K, Ohtaki M, et al. Glioblastom treated with postoperative radio-chemotherapy: prognostic value of apparent diffusion coefficient at MR imaging. *Eur J Radiol*. 2010;73(3):532–537.
9. Qu J, Qin L, Cheng S, et al. Residual low ADC and high FA at the resection margin correlate with poor chemoradiation response and overall Survival in high-grade glioma patients. *Eur J Radiol*. 2016;85(3):657–664.
10. Murakami R, Sugahara T, Nakamura H, et al. Malignant supratentorial astrocytoma treated with postoperative radiation therapy: prognostic value of pretreatment quantitative diffusion-weighted MR imaging. *Radiology*. 2007;243(2):493–499.
11. Hein PA, Eskey CJ, Dunn JF, Hug EB. Diffusion-weighted imaging in the follow-up of treated high-grade gliomas: tumor recurrence versus radiation injury. *Am J Neuroradiol*. 2004;25(2):201–209.
12. Calabrese E, Villanueva-Meyer JE, Rudie JD, et al. The University of California San Francisco Preoperative Diffuse Glioma MRI Dataset. *Radiol Artif Intell*. 2022;4(6):e220058.
13. Clark K, Vendt B, Smith K, et al. The Cancer Imaging Archive (TCIA): Maintaining and operating a public information repository. *J Digit Imaging*. 2013;26(6):1045–1057.
14. Weller M, Stupp R, Reifenberger G, et al. MGMT promoter methylation in malignant gliomas: ready for personalized medicine? *Nat Rev Neurol*. 2010;6(1):39–51.
15. Gupta A, Omuro AM, Shah AD, et al. Continuing the search for MR imaging biomarkers for MGMT promoter methylation status: conventional and perfusion MRI revisited. *Neuroradiology*. 2012;54:641–643.
16. Darbar A, Waqas M, Enam SF, Mahmood SD. Use of preoperative apparent diffusion coefficients to predict brain tumor grade. *Cureus*. 2018;10(3).
17. Gates EDH, Lin JS, Weinberg JS, et al. Guiding the first biopsy in glioma patients using estimated Ki-67 maps derived from MRI: conventional versus advanced imaging. *Neuro-Oncol*. 2019;21(4):527–536.
18. Wang Q, Zhang J, Xu X, Chen X, Xu B. Diagnostic performance of apparent diffusion coefficient parameters for glioma grading. *J Neurooncol*. 2018;139(1):61–6.
19. Artzi M, Bokstein F, Blumenthal DT, et al. Differentiation between vasogenic-edema versus tumor-infiltrative area in patients with glioblastom during bevacizumab therapy: a longitudinal MRI study. *Eur J Radiol*. 2014;83(7):1250–1256.
20. Ladenhauf VK, Galijasevic M, Kerschbaumer J, et al. Peritumoral ADC values correlate with the MGMT methylation status in patients with glioblastom. *Cancers*. 2023;15(5):1384.
21. Xie Z, Li J, Zhang Y, et al. The diagnostic value of ADC histogram and direct ADC measurements for coexisting isocitrate dehydrogenase mutation and O6-methylguanine-DNA methyltransferase promoter methylation in glioma. *Front Neurosci* [Internet]. 2023 [cited 2023 Apr 2];16. Available from: <https://www.frontiersin.org/articles/10.3389/fnins.2022.1099019>
22. Choi YS, Ahn SS, Kim DW, et al. Incremental prognostic value of ADC histogram analysis over MGMT promoter methylation status in patients with glioblastom. *Radiology*. 2016;281(1):175–184.
23. Demirel E, Özer Gökaslan Ç, Dilek O, Ozdemir C, Boyaci M, Korkmaz S. Differential diagnosis of glioblastom and solitary brain metastasis – the success of artificial intelligence models created with radiomics data obtained by automatic segmentation from conventional MRI sequences. *Čes Slov Neurol Neurochir*. 2022;84:541.