

## Optic Nerve Hypoplasia; Case Report

Zekeriya Çetinkaya<sup>1</sup> (ID), Kuddusi Erkiliç<sup>2</sup> (ID)

<sup>1</sup>Elbistan State Hospital Ophthalmology Department, Kahramanmaraş

<sup>2</sup>Erciyes University School of Medicine, Department of Ophthalmology, Kayseri

Received: 16 June 2023, Accepted: 06 August 2023, Published online: 29 October 2023

© Ordu University Institute of Health Sciences, Turkey, 2023

### Abstract

Optic nerve hypoplasia (ONH) is a rare neurodevelopmental disorder described by the optic disc is abnormally small regardless of sex or race. Imaging methods are frequently used in the diagnosis. In our case, a 17-year-old male patient, came to the clinic because of a deviation in his left eye, the examination showed hypoplasia of the optic nerve in the left eye. In ON hypoplasia, reported cases may include severe Central nervous system (CNS) malformations. However, we recommend periodic systemic examinations along with occupational rehabilitation, parental education and mobility training for these unique children.

**Key Words:** Hypoplasia of optic nerve, congenital optic nerve anomaly, optic nerve

### Optik sinir hipoplazisi;Olgu sunumu

#### Özet

Optik sinir hipoplazisi, cinsiyet veya ırktan bağımsız olarak optik diskin anormal derecede küçük olması ile tanımlanan nadir bir nörogeşimsel bozukluktur. Tanıda görüntüleme yöntemleri sıklıkla kullanılmaktadır. Olgumuzda 17 yaşında erkek hasta sol gözünde kayma şikayeti ile kliniğe başvurdu, yapılan muayenede sol gözde optik sinir hipoplazisi saptandı. Optik sinir hipoplazisinde, bildirilen vakalar ciddi Santral sinir sistemi (SSS) malformasyonlarını içerebilir. Ancak bu çocuklar için mesleki rehabilitasyon, ebeveyn eğitimi ve hareket eğitimi ile birlikte periyodik sistemik muayeneleri önermekteyiz.

**Anahtar Kelimeler:** Optik sinir hipoplazisi, konjenital optik sinir anomalisi, optik sinir

**Suggested Citation:** Çetinkaya Z, Erkiliç K. Optic Nerve Hypoplasia; Case Report. ODU Med J, 2023;9(3): 148-152.

Copyright@Author(s) - Available online at <https://dergipark.org.tr/tr/pub/odutip>

Content of this journal is licensed under a Creative Commons Attribution-NonCommercial 4.0 International License.



### Address for correspondence/reprints:

Zekeriya Çetinkaya

**Telephone number:** +90 (532) 056 04 90

**E-mail:** zekeriyaçetinkaya@hotmail.com.tr

### INTRODUCTION

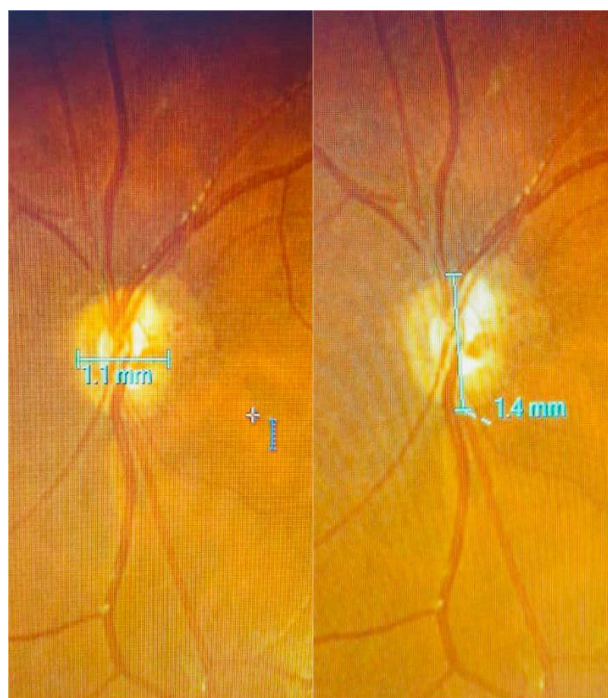Optic nerve hypoplasia (ONH) is a very rarely occurring congenital condition that can affect one or both eyes. ONH is often associated with other eye disorders. These include punched-out chorioretinal abnormalities, retinal dystrophy, sclerocornea, microphthalmia, cataracts and

coloboma (1). Bilateral cases commonly occur in association with serious congenital anomalies of the brain (2). However, unilateral and bilateral optic nerve aplasia have also been reported in otherwise healthy children (3). Optic nerve aplasia may occur in isolation or in combination with congenital eye disease or other non-ocular abnormalities. These abnormalities include congenital heart disease, corpus callosum hypogenesis and bilaterally hypoplastic ovaries (4).

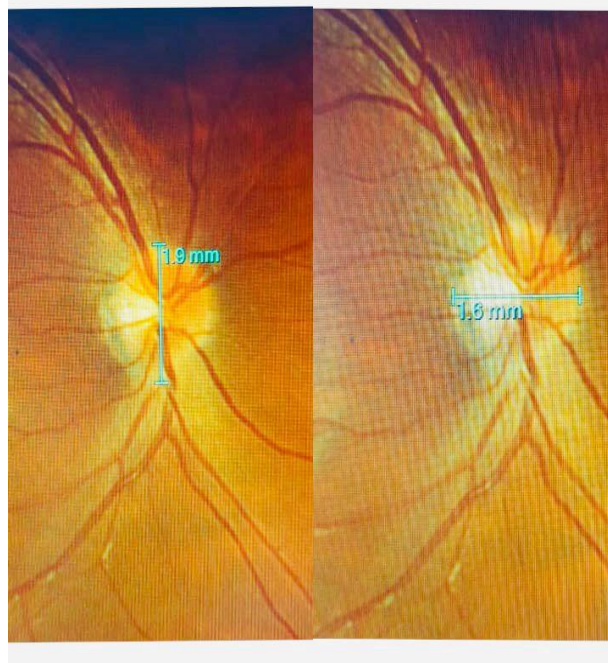### CASE REPORT

A 17-year-old male born of a nonconsanguineous marriage had an occasional deviation of the left eye since birth. He was the first child of his parents and there was no significant history of eye disorder in the family. On examination, he had no behavioural response to bright light in the left eye and the pupils in the left eye were non-reactive. Both corneas were clear. The dilated fundus was examined and a hypoplastic optic nerve was seen in the left eye. (Fig. 1). The fundus of the right eye was within normal limits (Fig. 2). The neurological examination was normal except for vision.

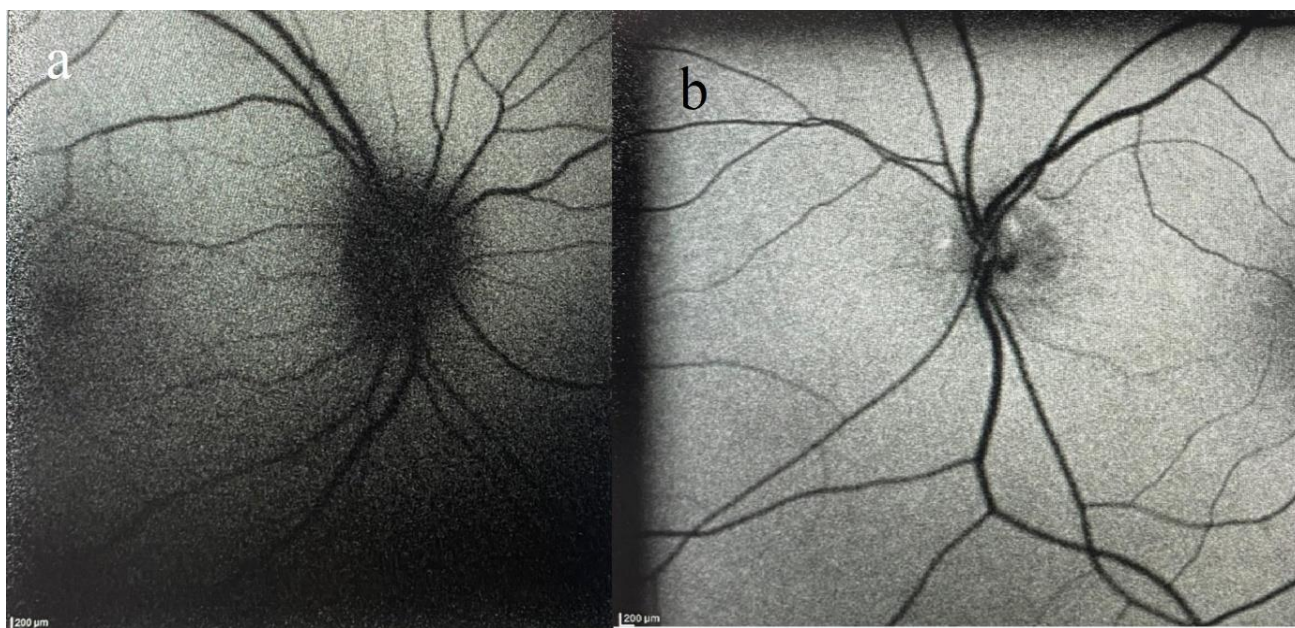
The ultrasound B-scan showed no shadowing of the optic nerve in the left globe. The intraorbital course of the left optic nerve was absent in the retinal segment. A thin cord was visible in the posterior segment. There were no significant abnormalities of the brain (Fig. 4).



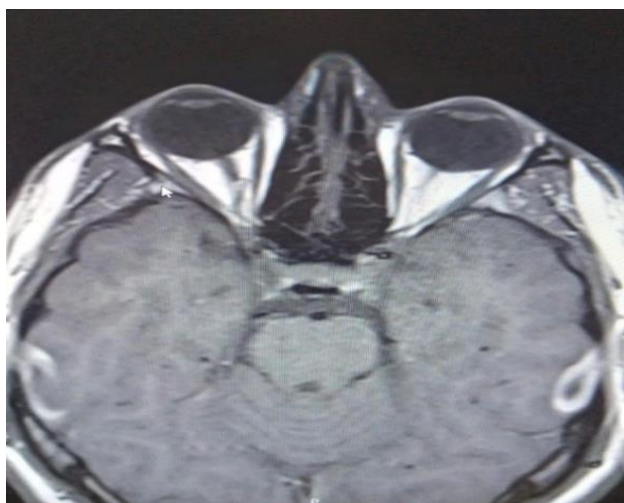
**Figure 1:** Severe hypoplasia of the optic nerve in the left eye. The left optic disc appeared quite small. The left optic disc was slightly pale and surrounded by a double ring.



**Figure 2:** Right eye is normal



**Figure 3:** a) Photo of the right optic disc, b) Photo of the left optic disc. The fundus autofluorescence image of the right eye shows no autofluorescence signal in the disc area, but there is hyperautofluorescence in the disc area of the left eye.



**Figure 4:** The Magnetic resonance imaging (MRI) scan shows a narrow stalk that represents the presumed left optic nerve in the orbit.

## DISCUSSION

Optic nerve aplasia is the total absence of the optic nerve head, nerve fibre layer, ganglion cells and retinal vascular structures. Histopathologically, only a dural sheath can be seen penetrating the sclera in its normal position,

together with characteristics of retinal dysplasia in the form of rosetting (3). Clinical features of true Optic nerve aplasia include blindness (no light perception), absence of the optic disc, absent central and branch retinal vascular structures, and an afferent papillary defect (5,6). There was no light perception and the optic disc was hypoplasia in the left eye of this case. Neuroimaging of the brain and orbit of the left eye showed optic disc hypoplasia. Thus, this case had ON hypoplasia in the left based on clinical, Magnetic resonance imaging (MRI) and USG findings. The left eye of the child in our case had all the clinically and radiologically features of ON hypoplasia. The histopathology to look for the absence of ganglion cells and nerve fibre layer together with the presence of a rudimentary dural sheath may be helpful in differentiating true



ON aplasia from severe ON hypoplasia (4). However, this is not possible in this case. Because of the lack of light perception, the absence of pupillary reflex, the hypoplasia of disc on fundus examination, the hypoplasia of ON on MRI and USG of the left eye, we assumed that this was also a case of ON hypoplasia in the left eye.

In the past, eyes with ON aplasia have been reported to lack optic nerve fibres, ganglion cells and retinal blood vascular structures (5,7). One-sided ON aplasia is usually related to normal brain development, whereas most two-sided forms are associated with CNS dysfunction (8). There have been some reports of cardiovascular, gastrointestinal and vertebral abnormalities in ON aplasia (9).

### CONCLUSION

The diagnostic procedures for optic nerve abnormalities in children require a thorough ophthalmic examination and appropriate ancillary tests. Some neuroimaging techniques like MRI may be of diagnostic significance in demonstrating optic nerve abnormalities and related disorders. MRI is a useful imaging technique for confirming the disease and identifying other neurological abnormalities. Parents are mainly advised on educational, occupational and physical rehabilitation for blind children. ON hypoplasia is rarely seen, but cases may include severe central nervous system abnormality. However, we advocate periodic

systemic assessment along with occupational rehabilitation, parent counselling and movement education for these unique cases.

---

**Ethics Committee Approval:** Consent form was obtained from the patient. An informed consent form was signed by the patient/relatives for the case presentation and applied by the Helsinki principles.

**Peer-review:** Externally peer-reviewed

**Author Contributions:** Concept - ZC; Design ZC; Supervision ZC; Data Collection and/or Processing - KE; Analysis and/or Interpretation - KE; Writing - ZC; Critical Review - ZC

**Conflict of Interest:** The author declared no conflict of interest.

**Financial Disclosure:** The author declared that this study has not received no financial support.

---

### REFERENCES

1. Taylor D. Optic nerve axons: life and death before birth. *Eye (Lond)* 2005;19:499–527.
2. Taylor D. Developmental abnormalities of the optic nerve and chiasm. *Eye (Lond)* 2007;21:1271–84.
3. Sanjari MS, Ghasemi Falavarjani K, Parvaresh MM, Kharazi HH, Kashkooli MB. Bilateral aplasia of the optic nerve, chiasm, and tracts in an otherwise healthy infant. *Br J Ophthalmol.* 2006;90:513–4.
4. Rajan RP, Deb AK, Kannan NB, Ramasamy K. Bilateral optic nerve aplasia with corpus

- callosum hypogenesis in an otherwise healthy child: Report of a rare case. *Indian J Ophthalmol.* 2019;67(7):1231-1233.
5. Meire F, Delpierre I, Brachet C, Roulez F, Van Nechel C, Depasse F, et al. Non-syndromic bilateral and unilateral optic nerve aplasia: First familial occurrence and potential implication of CYP26A1 and CYP26C1 genes. *Mol Vis.* 2011;17:2072–2079
  6. Sadasivan KS, Pawar N, Ravindran M, Rengappa R. Optic nerve aplasia: A case series. *Indian J Ophthalmol.* 2018;66:717–9.
  7. Caputo R, Sodi A, Menchini U. Unilateral optic nerve aplasia associated with rudimental retinal vasculature. *Int Ophthalmol.* 2009;29:517–519.
  8. Brodsky MC, Atreides SP, Fowlkes JL, Sundin OH. Optic nerve aplasia in an infant with congenital hypopituitarism and posterior pituitary ectopia. *Arch Ophthalmol.* 2004;122:125–126.
  9. Alqahtani J. Optic nerve aplasia: A case report and literature review. *J Pediatr Neurosci.* 2008;3:150–153.