

A Single Center Experience on the Management of Placental Invasion Abnormalities

Alper Biler¹, Atalay Ekin¹, Cenk Gezer¹, Ulaş Solmaz¹, Nuri Peker², Aykut Özcan¹, Mehmet Özeren¹

ABSTRACT

Objective: The aim of this study is to investigate our management of placental invasion abnormalities.

Methods: A retrospective study was conducted on patients admitted to a tertiary referral center with a diagnosis of placental invasion abnormalities between 2011 and 2015. Risk factors and perinatal outcomes associated with placental invasion abnormalities were identified.

Results: The overall incidence of placental invasion abnormalities during the 5-year period was 8.3/10000 deliveries, which showed an increasing trend. Ultrasonography and magnetic resonance imaging correctly identified placental invasion abnormality in 36.7% and 68.7% cases, respectively. Majority of patients (55.1%) with adherent placenta were diagnosed at the time of delivery. Of these patients, 22.4% underwent hysterectomy, 83.8% required at least one of the additional surgical procedures and 55% were transfused at least four units of packed red blood cell.

Conclusion: Since placental invasion abnormalities are associated with significant morbidity, delivery should be scheduled in a tertiary center with appropriate expertise and facilities. *J Clin Exp Invest 2016; 7 (1): 14-18*

Key words: placenta accreta, placenta increta, placenta percreta, placental invasion abnormality

Tek Bir Merkezin Plasental İnvazyon Anomalilerinin Yönetimindeki Deneyimi

ÖZET

Amaç: Bu çalışmanın amacı plasental invazyon anomalilerinin yönetimini incelemektir.

Yöntemler: 2011 ve 2015 tarihleri arasında tersiyer bir merkeze başvuran plasental invazyon anomalisi olan hastalarla retrospektif bir çalışma yürütülmüştür. Plasental invazyon anomalileriyle birlikte olan risk faktörleri ve perinatal sonuçlar belirlenmiştir.

Bulgular: İnsidansı artma eğiliminde olan plasental invazyon anomalilerin 5 yıllık süredeki insidansı 8,3/10000 doğumdur. Ultrasonografi ve manyetik rezonans inceleme vakaların %36,7 ve %68,7'sinde plasental invazyon anomalisini doğru olarak belirlemiştir. Plasenta adezyonu olan hastaların çoğunluğu doğum sırasında tanı almıştır. Bu hastaların %22,4'üne histerektomi uygulanmış, %83,8'ine ek bir cerrahi girim gerekmiş ve %55'ine en az 4 ünite eritrosit süspansiyonu transfüze edilmiştir

Sonuç: Plasental invazyon anomalileri önemli morbiditeyle ilişkili olduklarından, doğum deneyim ve imkanları yeterli olan tersiyer bir merkezde planlanmalıdır

Anahtar kelimeler: plasenta akreata, plasenta inkreata, plasental invazyon anomalisi, plasenta perkreata

INTRODUCTION

Placental invasion abnormalities are defined as abnormal attachment or invasion of the placenta to the underlying myometrium [1]. In placenta accreta, the villi penetrates the decidua but not myometrium. In placenta increta, placental villi penetrates the myometrium. Placenta percreta is the most severe form, in which

placental villi penetrate through the uterine serosa and sometimes into neighbor organs such as cervix, bladder or bowel [2]. Placental invasion abnormalities is associated with considerable maternal mortality and morbidity including large volume of blood transfusion, peripartum hysterectomy, cystotomy, intensive care unit admission, infection, and prolonged hospitalization [3, 4]. The prevalence is known to be ap-

¹ Kadın Hastalıkları ve Doğum Kliniği, Tepecik Eğitim ve Araştırma Hastanesi, İzmir, Türkiye

² Kadın Hastalıkları ve Doğum Kliniği, Acıbadem Üniversitesi Tıp Fakültesi Hastanesi, İstanbul, Türkiye

Correspondence: Atalay Ekin,

Kadın Hastalıkları ve Doğum Kliniği, Tepecik Eğitim ve Araştırma Hastanesi, İzmir, Türkiye Email: atalayekin@hotmail.com

Received: 13.01.2016, Accepted: 10.02.2016

Copyright © JCEI / Journal of Clinical and Experimental Investigations 2016, All rights reserved

proximately 1/500 to 1/2500 pregnancies [5]. Because of the worldwide increasing cesarean section rates, frequency of abnormal placentation have been raised in recent years.

The traditional management of placental invasion abnormalities is peripartum cesarean hysterectomy [6]. Recently, more conservative uterine sparing approaches are being performed to reduce the morbidity of peripartum hysterectomy as well as to allow future fertility [6,7]. However, there is a need for additional studies for identifying risk factors and perinatal outcomes among patients with placental invasion abnormalities. Accordingly, we designed the present study to review our experience with placental invasion abnormalities.

METHODS

This is a retrospective study of patients with a diagnosis of placental invasion abnormalities who admitted to a tertiary care center between 2011 and 2015. Placental invasion abnormality was defined as difficult or incomplete manual removal of placenta from uterine wall immediately after delivery. The definition was based on delivering clinician due to lack of pathological confirmation and included placenta accreta, increta and percreta.

All patients who admitted for the suspicion of adherent placenta were underwent detailed ultrasonography. Findings on ultrasonography that suggest placental invasion abnormality are placental lacuna, interruption of the posterior bladder-uterine border, myometrium thickness <1 mm, obliteration of the echo lucent area between the uterus and placenta. Magnetic resonance imaging (MRI) was performed along with ultrasonography in cases where placental invasion abnormality could not be excluded.

A delivery was considered elective if it was planned at least 1 day following admission and performed nonurgently either because of documented fetal maturity or clinical concerns for risks associated with expectant management. Severe antenatal bleeding was managed with emergency cesarean delivery. Early and delayed re-operations were defined as surgical procedures occurring less than or greater than 7 days after delivery, respectively. Medical records were reviewed for demographic and obstetric characteristics, diagnostic testing, surgical management, complications after surgery, adverse maternal and neonatal outcomes.

Statistical analyses were performed using SPSS ((SPSS for Windows version 20.0, SPSS Inc., Chicago, Illinois, USA). Descriptive statistics were used to describe the study. Data were expressed as number and percentages or mean with standard deviations.

RESULTS

During the 5-year of the study period, 58900 women were delivered at our institution. Forty-nine cases of surgically confirmed placental invasion abnormalities were identified. The number of cases with placental invasion abnormality showed an increasing trend (Figure 1). The overall incidence during the 5-year period was 8.3/10000 deliveries.

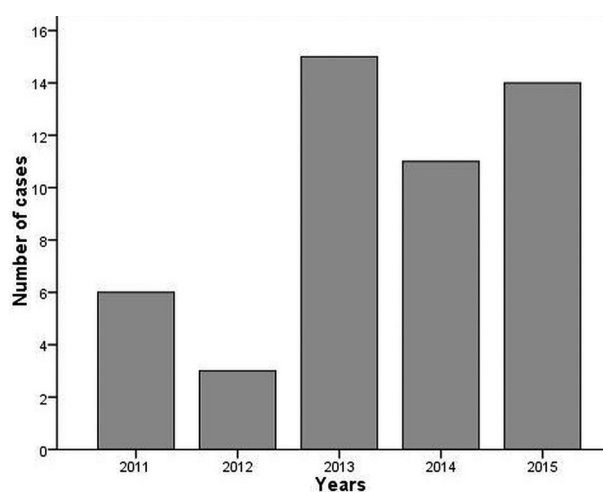


Figure 1. Distribution of the number of cases with placental invasion abnormality according to the year of occurrence

Table 1 shows maternal demographics and clinical characteristics of our study population. Mean gestational age at birth was 35.8 ± 3.6 weeks with a birthweight of 2755 ± 712 gr. All were singleton pregnancies. Nineteen babies were born at less than 37 weeks of gestation. Fourteen babies had a birthweight of less than 2500 g. All women had identifiable risk factors for placental invasion abnormality. Majority of the patients had placenta previa (91.8%) and history of at least one cesarean delivery (77.6%). Nearly half of the patients (46.9%) had two or more previous cesarean sections.

Table 2 describes the diagnosis of placental invasion abnormalities. Majority of women (55.1%) with adherent placenta were diagnosed at the time of delivery. Eighteen (36.7%) women were suspected of having a placental invasion abnormality with antenatal

ultrasonography. MRI was not routinely used. Sixteen women underwent MRI, which correctly identified placental invasion abnormality in 11 (68.7%) cases.

Table 1. Demographic and clinical characteristics of the study population

| | |
|----------------------------------|------------|
| Maternal age (yr) | 31.8 ± 5.8 |
| Gravidity | 3.2 ± 1.2 |
| Parity | 1.6 ± 0.8 |
| Gestational age at delivery (wk) | 35.8 ± 3.6 |
| Birthweight (gr) | 2755 ± 712 |
| Prior cesarean delivery, n (%) | |
| 0 | 11 (22.4) |
| 1 | 15 (30.6) |
| 2 | 18 (36.7) |
| ≥ 3 | 5 (10.2) |
| Prior uterine curettage, n (%) | |
| 0 | 39 (79.5) |
| 1 | 8 (16.3) |
| ≥ 2 | 2 (4) |
| Placental previa, n (%) | |
| Previa | 45 (91.8) |
| No previa | 4 (8.2) |

Table 2. Diagnosis of placental invasion abnormality in this study

| | Study group n = 49 |
|-----------------------|--------------------|
| Diagnosed at birth | 27 |
| Diagnosed antenatally | 22 |
| Diagnosed by USG | 18 |
| Routine USG | 16 |
| USG for hemorrhage | 2 |
| Use of MRI | 16 |
| Diagnosed by MRI | 11 |

MRI, magnetic resonance imaging; USG, ultrasonography

Table 3 summarizes peripartum management and maternal outcomes of cases with placental invasion abnormality. All of the patients were delivered by cesarean section. Delivery of 29 (59.1%) women were performed under elective conditions. Eleven (22.4%) patients underwent hysterectomy. Four patients required early re-operation after cesarean delivery due to hemodynamic instability. All of these patients underwent hysterectomy. No surgical procedures were

performed in 16.4% women. Nearly 84 percent of women required at least one of the surgical procedures other than hysterectomy (uterine compression sutures, uterine artery ligation, hypogastric artery ligation). More than half of the patients (55.2%) required at least four units of packed red blood cell transfusion. Three cases of uterine rupture due to placenta percreta were diagnosed during surgery. There were no maternal and neonatal deaths.

Table 3. Peripartum management and maternal morbidity of women with placental invasion abnormality

| | n | % |
|-----------------------------|----|------|
| Elective delivery | 29 | 59.1 |
| Emergency delivery | 20 | 40.9 |
| Blood transfusion | | |
| No | 7 | 14.2 |
| < 4 units | 15 | 30.6 |
| 4-10 units | 25 | 51 |
| > 10 units | 2 | 4.2 |
| Hysterectomy | | |
| Primary | 7 | 14.3 |
| Return to theater | 4 | 8.2 |
| Additional procedures | | |
| Compression sutures | 19 | 38.7 |
| Uterine artery ligation | 12 | 24.4 |
| Hypogastric artery ligation | 20 | 40.8 |
| Renal tract injury | | |
| Ureter | 1 | 2 |
| Bladder | 4 | 8.1 |
| Re-operation* | | |
| Early | 4 | 8.2 |
| Late | | |
| ICU admission | 4 | 8.1 |
| Wound infection | 2 | 4.1 |

* Early re-operation was defined as additional surgery within 7 days from initial surgery; ICU, intensive care unit

DISCUSSION

The overall incidence of placental invasion abnormality in our hospital was 8.3/10000 deliveries during the 5-year study period. Between 2011 and 2015, the incidence was found to be 3.9%, 2.2%, 14.7%, 10.5% and 14.9 per 10000 deliveries, respectively. A significant increase in the incidence has been noticed over three years probably due to rise in cesarean section rates.

The cesarean section rates of our center was 32.8% of all live births in 2011, 44.1% in 2012, 57.7% in 2013, 56.7% in 2014 and 56.6% in 2015. Furthermore, increased patient referrals to our center from surrounding hospitals might have contributed to this incidence.

Prenatal diagnosis of placental invasion abnormalities can help reduce perinatal morbidity and mortality by allowing the clinicians to choose best time and place of delivery [8]. The sensitivity and specificity to diagnose these pathologies is 93% and 79% for grayscale ultrasound and 82.4% and 95.3% for Doppler ultrasound, respectively [9,10]. MRI is reported to have a sensitivity of 38% to 100% and a specificity of 55% to 100% for diagnosis of abnormal placentation [11,12]. In general, ultrasonography is considered as the primary diagnostic tool for abnormal placentation because it is relatively inexpensive and widely available. However, invasion of adjacent organs could be evaluated better with MRI than ultrasound. Therefore, MRI is frequently used as an adjunct in diagnosis when the ultrasound findings are suspicious or placenta previa implants on posterior or lateral uterine wall [13]. Bailit et al. [14] reviewed a cohort of 115502 women and their neonates born in 25 hospitals in the United States. They reported that only 53% of morbidly adherent placentas were suspected before delivery even at larger tertiary care centers. In our study population, a significant number of patients with placental invasion abnormality were not diagnosed during antenatal period. This may be due to the fact that ultrasonography and MRI were dependent mainly on the skills of the sonographer or radiologist.

Women with placental invasion abnormalities are at increased risk for massive blood transfusion, extensive surgery, and admission to intensive care unit. Our study demonstrated the association between significant maternal morbidity and placental invasion abnormalities. Majority (83.6%) of our patients required an unexpected surgical intervention such as hysterectomy, uterine compression sutures, uterine artery ligation and hypogastric artery ligation. Fourteen percentage of patients suffered from surgical complications, particularly from renal tract injury. Four patients underwent early re-operation. Eighty-six percent of patients required blood transfusion and nearly two thirds of these women were transfused at least four units of packed red blood cell. These results are consistent with previously published reports regarding surgical management of placental invasion abnormalities [3, 15]. However, reduction of emergency surgery by an-

tenatal diagnosis can play important role to decrease potential morbidity and mortality rates [11,16,17]. Similarly, Eller et al. [16] reported that scheduled surgery associated with reduced maternal morbidity in women with suspected placenta accreta. An interesting finding of our study is that we have not observed significant differences between patients underwent elective and emergency surgery in terms of maternal morbidity. The possible explanation for this is the low rates of antenatal diagnosis and lack of a standardized protocol.

Optimal antepartum and intrapartum management strategies for placental invasion abnormalities have not been fully elucidated, yet. There are no published, randomized, controlled studies showing that one procedure is superior to the other. Therefore, management is based on retrospective case series and expert opinions [18-20]. It is believed that an experienced multidisciplinary team should be prepared in a tertiary care to improve outcomes. Although hysterectomy has traditionally been advised in the management for suspected placental invasion abnormalities, conservative uterine preserving surgery have also been described to allow future fertility [6,7]. Those approaches include leaving the placenta in situ after cesarean delivery, oversewing of the placental vascular bed, uterine compression sutures, bilateral uterine artery ligation, bilateral hypogastric artery ligation, embolisation of uterine vessels, hysteroscopic resection of retained placental tissue, use of mifepristone and misoprostol, and methotrexate administration [18]. Several small case series suggested that conservative management with uterine preservation is a safe and reasonable choice [6,21-23]. However, successful management of placental invasion abnormality is not guaranteed with conservative management and risks such as delayed hemorrhage, infection, sepsis, intensive care unit admission may be significant. In a multicenter study from France, 167 women treated with conservative management were reviewed. In that study, uterine preservation was applied in majority of patients, but 11% of patients underwent hysterectomy within 24 hours of delivery due to severe hemorrhage [24]. They also reported a 28 % overall rate of infection, 6% occurrence of severe maternal morbidity including sepsis, septic shock and one maternal death [24]. Another important issue with conservative treatment is the risk of placental invasion abnormality in the subsequent pregnancies [25]. In the study of Kabiri et al., the odds ratio for recurrent placenta accreta was found to be 15.41 (95% CI 6.09–39.03; $p < 0.001$) [26].

In our study population, 78% women were managed conservatively. The placenta was removed after delivery in all these patients. According to the degree of bleeding, uterine compression sutures, bilateral uterine artery ligation, bilateral hypogastric artery ligation were used and if needed, two or more techniques were performed. Due to hemodynamic instability, 4 patients undergone hysterectomy during cesarean section and 4 underwent hysterectomy during early re-operation. Among patients treated conservatively, two experienced wound infection, three experienced renal tract injury and two admitted intensive care unit.

Our study had several limitations. First, the retrospective nature of the study design inevitably leads to missing data and incomplete collection of all required information. Second, the management options of patients were decided by the responsible obstetrician and hence, multidisciplinary standardized protocols were not routinely applied. Third, being a tertiary referral center may be associated with selection bias due to referral of more significant cases of placental invasion abnormalities that require a higher level of medical care. Finally, all cases of placental invasion abnormalities were not confirmed pathologically. Instead, the diagnosis was mainly made by surgeon during surgery according to visual signs such as placental adhesion, depth of myometrial invasion, invasion to other pelvic organs and degree of bleeding.

In conclusion, the incidence of placental invasion anomalies has been rising significantly in the past years. However, there is not a completely sensitive and specific test for the diagnosis. When the probability of abnormal placentation is raised, delivery should be scheduled in a tertiary center with appropriate expertise and facilities.

Declaration of Conflicting Interests: The authors declare that they have no conflict of interest.

Financial Disclosure: No financial support was received.

REFERENCES

- Esmans A, Gerris J, Corthout E, et al. Placenta percreta causing rupture of an unscarred uterus at the end of the first trimester of pregnancy: case report. *Hum Reprod* 2004;19:2401-2403.
- Silver RM, Barbour KD. Placenta accreta spectrum: accrete, increta, and percreta. *Obstet Gynecol Clin North Am* 2015;42:381-402.
- Oyelese Y, Smulian JC. Placenta previa, placenta accreta, and vasa previa. *Ed Obstet Gynecol* 2006;107:927-941.
- Silver RM, Landon MB, Rouse DJ, et al. Maternal morbidity associated with multiple repeat cesarean deliveries. *Obstet Gynecol* 2006;107:1226-1232.
- Wu S, Kocherginsky M, Hibbard JU. Abnormal placentation: twenty-year analysis. *Am J Obstet Gynecol* 2005;192:1458-1461.
- Kayem G, Davy C, Goffinet F, et al. Conservative versus extirpative management in cases of placenta accreta. *Obstet Gynecol* 2004;104:531-536.
- Timmermans S, van Hof AC, Duvekot JJ. Conservative management of abnormally invasive placentation. *Obstet Gynecol Surv* 2007;62:529-539.
- Cali G, Giambanco L, Puccio G, Forlani F. Morbidly adherent placenta: evaluation of ultrasound diagnostic criteria and differentiation of placenta accreta from percreta. *Ultrasound Obstet Gynecol* 2013;41:406-412.
- Finberg HJ, Williams JW. Placenta accreta: prospective sonographic diagnosis in patients with placenta previa and prior cesarean section. *J Ultrasound Med* 1992;11:333-343.
- Chou MM, Ho ES, Lee YH. Prenatal diagnosis of placenta previa accreta by transabdominal color Doppler ultrasound. *Obstet Gynecol* 2000;15:25-35.
- Warshak CR, Eskander R, Hull AD, et al. Accuracy of ultrasonography and magnetic resonance imaging in the diagnosis of placenta accreta. *Obstet Gynecol* 2006;108:573-581.
- Peker N, Turan V, Ergenoglu M, et al. Assessment of total placenta previa by magnetic resonance imaging and ultrasonography to detect placenta accreta and its variants. *Ginekol Pol.* 2013;84:186-192.
- Comstock CH, Bronsteen RA. The antenatal diagnosis of placenta accreta. *BJOG* 2014;121:171-181.
- Bailit JL, Grobman WA, Rice MM, et al. Morbidly adherent placenta treatments and outcomes. *Obstet Gynecol* 2015;125:683-689.
- Grace Tan SE, Jobling TW, Wallace EM, et al. Surgical management of placenta accreta: a 10-year experience. *Acta Obstet Gynecol Scand* 2013;92:445-450.
- Eller AG, Porter TF, Soisson P, Silver RM. Optimal management strategies for placenta accreta. *BJOG* 2009;116:648-654.
- Shamshirsaz AA, Fox KA, Salmanian B, et al. Maternal morbidity in patients with morbidly adherent placenta treated with and without a standardized multidisciplinary approach. *Am J Obstet Gynecol* 2015;212:218.e1-9.
- Silver RM, Barbour KD. Placenta accreta spectrum: accreta, increta, and percreta. *Obstet Gynecol Clin North Am* 2015;42:381-402.
- Erdemoğlu M, Kale A, Akdeniz N. Analysis of 46 hysterectomies performed for obstetric indications. *Dicle Med J* 2006;33:227-230.
- Evsen MS, Sak ME, Özkul Ö, Et al. Emergency peripartum hysterectomy. *Dicle Med J* 2009;36:23-27.
- İncebiyik A, Camuzcuoğlu A, Hilali NG, et al. Approach to cases with postpartum haemorrhage: retrospective analysis of 41 cases. *J Clin Exp Invest* 2014;5:18-23.
- D'Souza DL, Kingdom JC, Amsalem H, et al. Conservative Management of Invasive Placenta Using Combined Prophylactic Internal Iliac Artery Balloon Occlusion and Immediate Postoperative Uterine Artery Embolization. *Can Assoc Radiol J* 2015;66:179-184.
- Shabana A, Fawzy M, Refaie W. Conservative management of placenta percreta: a stepwise approach. *Arch Gynecol Obstet* 2015;29:993-998.
- Sentilhes L, Ambroselli C, Kayem G, et al. Maternal outcome after conservative treatment of placenta accreta. *Obstet Gynecol* 2010;115:526-534.
- Provansal M, Courbiere B, Agostini A, et al. Fertility and obstetric outcome after conservative management of placenta accreta. *Int J Gynaecol Obstet* 2010;109:147-150.
- Kabiri D, Hants Y, Shanwetter N, et al. Outcomes of subsequent pregnancies after conservative treatment for placenta accreta. *Int J Gynaecol Obstet* 2014;127:206-210.