



How to avoid from an ectropion complication by using motor innervation prevention at lower eyelid blepharoplasty surgery

Basar Kaya^{a*}, Senem Ozge Turacli Karagüven^b

^a Department of Plastic, Reconstructive and Aesthetic Surgery, Faculty of Medicine, Ufuk University, Ankara, Turkey

^b Department of Plastic, Reconstructive and Aesthetic Surgery, Faculty of Medicine, Yildirim Beyazıt University, Yenimahalle Research and Training Hospital, Ankara, Turkey

ARTICLE INFO

ABSTRACT

Article History

Received 16 / 06 / 2016

Accepted 10 / 03 / 2017

* Correspondence to:

Başar Kaya
Department of Plastic,
Reconstructive and Aesthetic Surgery,
Faculty of Medicine,
Ufuk University,
Ankara, Turkey
e-mail: basarkaya@gmail.com

The subciliary incision is the most commonly used approach for lower eyelid blepharoplasty because of the advantages like ease of combining with other periocular and midface rejuvenation techniques. However, the most common reported major complication is lower lid malposition. In this article we described our subciliary dissection technique to protect the motor branches of tarsal orbicularis oculi to avoid from ectropion.

Keywords:

Blepharoplasty
Ectropion
Lower-lid blepharoplasty
Midface lift

© 2016 OMU

1. Introduction

As part of the aging process eyelids and mid face show characteristic changes. The youthful eyelid shows continuum with the cheek creating a single convexity from the lower lid margin to the orbital rim. In an aging face the lower eyelid separates from the cheek at the orbital rim owing to loss or descent of soft tissue. This descent results in deep tear trough deformities, festoons, accentuation of the orbital rim, and too evident lid-cheek transition which creating a double convexity (Bedrossian, 2005).

Skin or skin-muscle flap approaches with or without excision of herniated orbital fat were more popular until a few years ago. But a dramatic surgical shift to preserving or repositioning fat versus excising it is the most current approach (Goldberg, 2000) Nevertheless, it has been accepted that the techniques used for lower eyelid were unable to correct the midface area. Over the last decades, understanding of the anatomic relationships between the lower eyelid and the midface, important new modifications were developed to achieve elevation of the midface.

2. Experimental procedure

We applied this dissection and motor nerve protection technique to 32 female and 4 male patient between 2012-2015 in lower blepharoplasty operation. The patient ages ranged from 36 to 67 years (median, 51 years). Mean follow up period was 16 (12 to 24) months after operations.

Snap test should be done before the operation planning. The patient is marked in the upright position. All markings are performed before infiltration of the local anesthetic.

Surgery can be performed either under general anesthesia, monitored care or local anesthesia depending on the extent of surgery and preferences of the patient. If no sedation is to be used, tumescent can be used to reduce the risk of local anesthetic toxicity. Ophthalmic lubrication and protective corneal shields coated with ointment are inserted into each eye. After the lower eyelid and mid cheek is infiltrated with 10 cc of Klein solution then a subciliary incision is performed with a #15 blade where fits to preoperative markings, extending 2 to 3 mm laterally below the lateral canthus. A limited skin flap is raised by leaving 1.5 cm orbicularis muscle intact. Preservation of this pretarsal orbicularis muscle is recommended to protect the functional integrity of the lower eyelids. Blunt dissection is carried out by a delicate scissor until the orbital septum to the level of the infraorbital rim. Because of the anatomic course of the nerve, orbicularis oculi muscle should split perpendicularly by using a blunt scissor. 3-5 motor branches of pretarsal orbicularis oculi muscle which has a course from deep structures of the infraorbital rim can be seen and protected during the inferior muscle-skin lower eyelid flap elevation by this blunt dissection. (Fig. 1, Fig. 2).

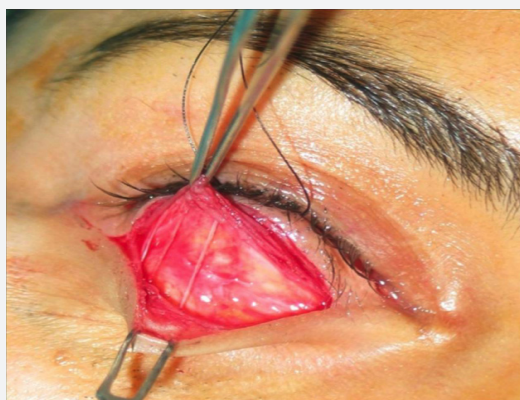


Fig. 1. Motor branches of pretarsal orbicularis oculi muscle

3. Results

We had only 8 complications, 3 limited hematoma which did not need to reoperation, 3 corneal edema and

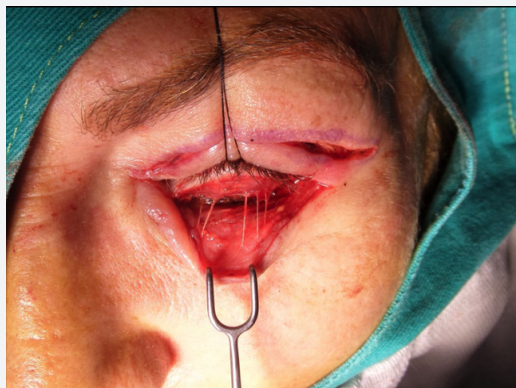

Fig. 2. Preserved motor branches of pretarsal orbicularis oculi muscle

2 chemosis. We had no scleral showing and-or ectropion complication. Our patient satisfaction percentages are high regarding to their results (Fig. 3, Fig. 4).

4. Discussion

In all aesthetic surgical procedures preoperative planning is one of the main step to achieve success. Preoperative markings in seated or standing position should be placed prior to surgery to avoid asymmetries due to gravity vector changings. The most advantage of the preoperative marking is, to correct tear through deformity and nasojugal groove and nasolabial fold symmetrically while suspending malar fat pad.

The subciliary approach is the most commonly used and technically less challenging for surgeons experienced in facelift techniques. Transeyelid midface lifting was first described by Shorr and Martin (1985) in a patient with lower eyelid retraction to achieve cosmetic and functional repair. Because of the advantages like ease of combining with other periorcular and midface rejuvenation techniques, this approach gain popularity.

The most common reported major complication after lower eyelid blepharoplasty is lower lid malposition, which is a result of denervation of the pretarsal orbicularis oculi muscle, excessive skin excision or scar contracture of the orbital septum (Lelli sand Richard, 2010; de Saint-Cyr et al., 2007). Understanding the relevant anatomy can provide an accurate plane of surgical dissection which can reduce the risk of motor nerve branch damage.

Previously, it was thought that the terminal branches of zygomatic nerve enter the lower orbicularis oculi muscle at its lateral aspect and run parallel to muscle fibers. Ramirez et al. (2000) changed this prevalent idea by showing three to five branches of zygomatic nerve that entering the lower orbicularis oculi muscle at a right angle. Hwang et al. (Hwang et al., 2001) enhanced these anatomic findings with cadaveric and clinical studies and reported not only zygomatic

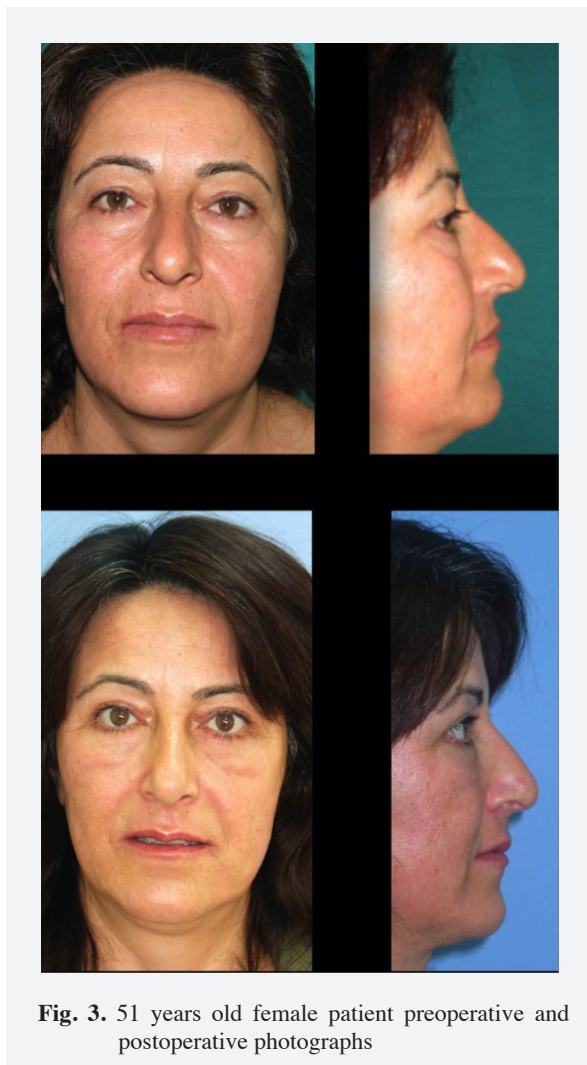

Fig. 3. 51 years old female patient preoperative and postoperative photographs

branches, moreover buccal branches and more terminal branches of zygomatic nerve is innervating the lower orbicularis oculi muscle. The authors also emphasized the need to protect “critical zone” which is a circle of 0.5 cm radius lateral and inferior to the lateral canthus to avoid postoperative ectropion. Moreover, in our opinion the most common cause of ectropion during a blepharoplasty is the muscle denervation which is caused by the complete separation of the pretarsal muscle from its motor innervation. During dissection surgeons should protect the dominant motor branches. So understanding the anatomic orientation will help us to perform our surgical dissection in a more rational

REFERENCES

- Bedrossian, E.H., 2005. “Reconstructive Lower Lid Blepharoplasty.” *Ophthalmol. Clin. North Am.* 2, 291-300.
- Botti, G., C, Botti., 2014. “Midface Lift: Our Current Approaches.” *Handchirurgie, Mikrochirurgie, plastische Chirurgie: Organ der Deutschsprachigen Arbeitsgemeinschaft für Handchirurgie; Organ der Deutschsprachigen Arbeitsgemeinschaft für Mikrochirurgie der Peripheren Nerven und Gefäße: Organ der V.* 4, 224-233.
- de Saint-Cyr, B., Cornette, Garey, L.J., Maillard, G.F., Aharoni, C. 2007. “The Vertical Midface Lift. An Improved Procedure.” *Journal of Plastic, Reconstructive & Aesthetic Surgery* 60, no. 12, 1277-1286.

way. This will fundamentally avoid denervation of the lower eyelid during peri-orbital procedures and decrease postoperative complications.

The conventional “destructive” lower eyelid blepharoplasty known as fat removal has been replaced by a “reconstructive” blepharoplasty involving minimal or no fat removal with malar tissue repositioning (Bedrossian, 2005). Additional minimal invasive surgical techniques include neurotoxin applications, soft tissue fillers, fat grafting and fractional laser applications can also be combined with surgeries for facial rejuvenation. Most of the time fat grafting is a good option to restore volume loss at the same time as a midface lift (Botti and Botti, 2014).

In conclusion, lower eyelid blepharoplasty approach is commonly used and an elegant access for midface lift. Understanding the relevant anatomy and protecting the dominant motor branches during dissection will avoid denervation of the lower eyelid and decrease postoperative complications.

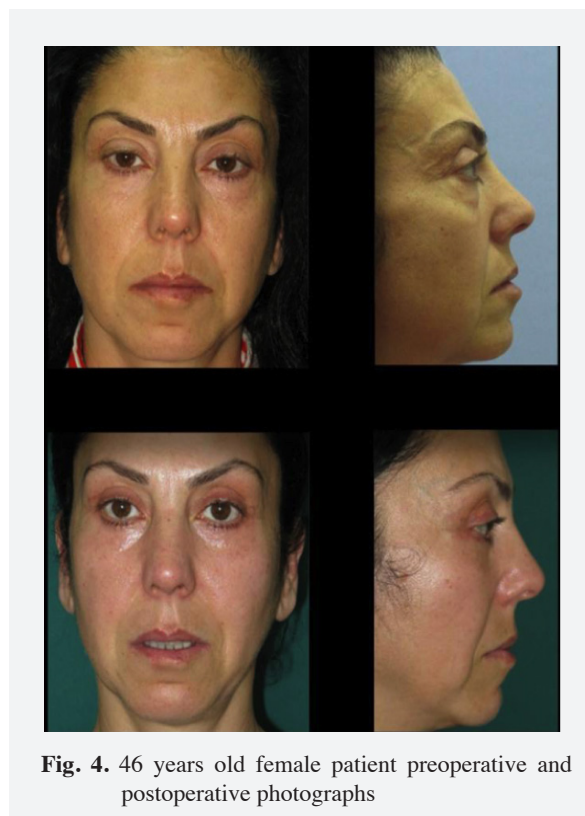


Fig. 4. 46 years old female patient preoperative and postoperative photographs

- Goldberg, Robert Alan. 2000. "Transconjunctival Orbital Fat Repositioning: Transposition of Orbital Fat Pedicles into a Subperiosteal Pocket." *Plast. Reconstr. Surg.* 2, 743-748.
- Hwang, Kun, Lee, D.K., Lee, E.J., Chung, I.H., Lee, S.I., 2001. "Innervation of the lower eyelid in relation to blepharoplasty and midface lift: Clinical observation and cadaveric study." *Ann. Plast. Surg.* 1, 1-7.
- Lelli, Jr., G.J., Richard, D.L., 2010. "Blepharoplasty Complications." *Plast. Reconstr. Surg.* 3, 1007-1017.
- Ramirez, O.M, and Rodrigo S., 2000. "Spatial orientation of motor innervation to the lower orbicularis oculi muscle." *J. Aesthet. Surg.* 2, 107-113.
- Shorr, N., Martin, K.F., 1985. "Madame Butterfly" Procedure: Combined cheek and lateral canthal suspension procedure for post-blepharoplasty, Round Eye, and Lower Eyelid Retraction." *Ophthalmic Plast. Reconstr. Surg.* 4, 229-235.