



PROTECTIVE EFFECTS OF ETHANOL EXTRACT FROM *HIPPOPHAE RHAMNOIDES* L. LEAVES AGAINST INDOMETHACIN-INDUCED GASTRIC ULCER IN RATS

Lale DUYSAK^{1*}, Mine GULABOGLU¹, Tugba Nurcan YUKSEL², Zekai HALICI³, Dogukan CANAYAKIN¹, Galip Mesut DEMIR¹

¹Ataturk University, Faculty of Pharmacy, Department of Biochemistry, 25240, Erzurum, Türkiye

²Tekirdag Namik Kemal University, Faculty of Medicine, Department of Pharmacology, 59030, Tekirdag, Türkiye


³Ataturk University, Department of Pharmacology, Faculty of Medicine, 25240, Erzurum, Türkiye


Abstract: We aimed to determine the effects of ethanol extract of *Hippophae rhamnoides* L. leaves on indomethacin-induced gastric ulcer in rats. 35 male Sprague Dawley rats were divided into 7 groups (n=5) at random: healthy; *Hippophae rhamnoides* L. leaves ethanol extract (HR) III; indomethacin; indomethacin+famotidine; indomethacin+HRI (100 mg/kg); indomethacin +HRII (250 mg/kg) and indomethacin +HRIII (500 mg/kg). All rats except the healthy group fasted for 24 hours. At the end of this period, HR and famotidine (20 mg/kg) were administered by oral gavage to the corresponding rat groups. Five minutes after the HR treatments, 25 mg/kg of indomethacin was applied by oral gavage to all groups except the Healthy and HR III groups. Six hours after indomethacin administration, stomach tissues were removed for investigation macroscopic and biochemically (Superoxide dismutase activity, Glutathione, and Malondialdehyde levels). HR administration improved ulcerative injury in stomach tissues caused by the indomethacin-induced gastric ulcer. HR administration reduced indomethacin-induced ulcer areas. Moreover, HR treatment significantly decreased malondialdehyde levels, increased glutathione levels, and elevated superoxide dismutase activity. HR significantly improved gastric ulcer by alleviating oxidative stress that could be important in ulcer. HR may be a new potential treatment option for ulcer treatment with an antioxidant effect. These findings may provide a mechanistic basis for using HR leaves to treat gastric ulcer.


Keywords: Antioxidant, Antiulcerogenic effect, Ethanol extract, Gastric ulcer, *Hippophae rhamnoides* L., Indomethacin


*Corresponding author: Ataturk University, Faculty of Pharmacy, Department of Biochemistry, 25240, Erzurum, Türkiye


E mail: lgozcu@atauni.edu.tr (L. DUYSAK)


Lale DUYSAK  <https://orcid.org/0000-0001-7872-3880>

Mine GULABOGLU  <https://orcid.org/0000-0002-3248-1502>

Tugba Nurcan YUKSEL  <https://orcid.org/0000-0001-5092-1674>

Zekai HALICI  <https://orcid.org/0000-0001-6854-6059>

Dogukan CANAYAKIN  <https://orcid.org/0000-0006-5974-7880>

Galip Mesut DEMIR  <https://orcid.org/0000-0001-6107-2604>

Received: August 02, 2023

Accepted: September 28, 2023

Published: October 15, 2023

Cite as: Duysak L, Gulaboglu M, Yuksel TN, Halici Z, Canayakin D, Demir GM. 2023. Protective effects of ethanol extract from *hippophae rhamnoides* l. leaves against indomethacin-induced gastric ulcer in rats. BSJ Health Sci, 6(4): 697-704.

1. Introduction

Gastric ulcer has been defined as one of the common diseases that occur in the stomach and duodenum, affecting millions of people worldwide (Wang et al., 2021). The main causes of gastric ulcers include increased stomach acid, pepsin, *Helicobacter pylori* infection, alcohol and tobacco consumption, and overuse of nonsteroidal anti-inflammatory drugs (Antonisamy et al., 2016). Compared with other nonsteroidal anti-inflammatory drugs, indomethacin (IND) causes more severe injury to the gastric mucosa in rats (Isnain et al., 2022). Intake of IND results in vascular damage, ulceration, and gastric cell necrosis (Halici et al., 2016). Therefore, the IND-induced model is a frequently used experimental model to study the pathophysiological mechanisms and pharmacological interventions of gastric ulcer (Pineda-Pena et al., 2020). Pathogenic

mechanisms underlying IND-induced gastric ulcer involve elevated generation of reactive oxygen species (ROS) (Eraslan et al., 2020), thereby causing oxidative stress in the gastric tissue (Bhattacharyya et al., 2014). Excessive ROS will deplete the activities and contents of some antioxidant enzymes and non-enzymatic substances, such as superoxide dismutase (SOD) and glutathione (GSH), in the initial antioxidant system of gastric tissue, thereby leading to the production of some lipid and protein oxidation products, such as malondialdehyde (MDA) (Barboza et al., 2018; Yoldaş et al., 2022), which can severely damage the mucosal surface of gastric tissue, eventually leading to tissue and organ injuries and diseases (Pizzino et al., 2017). Consequently, pharmacological agents with anti-oxidative properties may be a promising strategy for avoiding gastric ulcer.

Sea buckthorn, commonly referred to as *Hippophae*



rhamnoides L. (HR) from the Elaeagnaceae family members, is a spiny deciduous shrub or small tree. It is a flowering shrub native to cold temperate regions. The fruits, seeds and leaves of the plant are widely used as folk medicine in the treatment of edema, hypertension, inflammation, tissue regeneration, burns/injuries, wounds and ulcers (Pundir et al., 2021; Sharma et al., 2020). The Qinghai-Tibet Plateau and nearby areas are where this species was first discovered and moved to (Jia et al., 2012). Extreme environments with high salinity, cold, heat, and drought are some of their natural habitats (Bonciu et al., 2020). When consumed as a food or as a dietary supplement, HR and its processed products are potentially nontoxic. (Wang et al., 2022). As a result, researchers have been interested in HR's nutritional, therapeutic, and ecological benefits for centuries (Gatlan and Gutt, 2021). In experimental studies, the defensive impacts of HR on various tissue injuries have been individually proven in diverse tissues, including cerebral vascular (Purushothaman et al., 2008) and liver (Ran et al., 2021) injuries. HR's protective effects in various situations such as burn (Upadhyay et al., 2011), pulmonary vascular leakage (Purushothaman et al., 2011), and obesity (Lee et al., 2011) have also been studied. Also, HR fruit has been shown to have an antiulcerogenic effect against IND-induced gastric ulcer (Suleyman et al., 2001). HR seed and pulp oils have also been shown to have preventive and curative effects against experimental gastric ulcers in rats (Xing et al., 2002). There is also evidence that sea buckthorn seed oil has a therapeutic effect against dexamethasone-induced gastric ulceration and erosions in dogs (Dogra et al., 2013). Sea buckthorn procyanidins play an important role in the healing of acetic acid-induced gastric lesions possibly by the acceleration of mucosal repair (Xu et al., 2007). A hexane extract obtained from the fresh fruit of *Hippophae rhamnoides* L. produces beneficial effects on gastric tissue glutathione levels and on the prevention of ethanol-induced ulcer formation in rats (Halis Suleyman et al., 2001). Moreover, Li et al. (2005) showed that ethanol extract of *Hippophae rhamnoides* leaf exhibited potent anti-*Helicobacter pylori* action (Li et al., 2005). However, the effects of HR leaves on IND-induced gastric ulcer is unknown.

Based on all this information, in this study, we aim to investigate the protective effects of HR on IND-induced gastric ulcer in rats with macroscopic and biochemical (SOD activity, GSH and MDA levels) analyses.

2. Materials and Methods

2.1. Animals

In this study, 35 Sprague Dawley (weight: 180-220 gr) were purchased from Atatürk University Medical Experimental Application and Research Center. Before the experiment, the rats underwent a one-week adaptation period. All the animals were kept in standard plastic cages under standard conditions (temperature: 22 ± 1 °C, relative humidity: 40–80%, 12 h light-dark

cycle). Throughout the experiment, the animals had unlimited access to the usual rat water and food (ad libitum). All experimental procedures were carried out by national guidelines for the use and care of laboratory animals.

2.2. Chemical Substances

IND (25 mg Endol, 25 capsule) and FAM (Neotab tablet, 40 mg) were purchased from Deva, Türkiye. Abbott (Istanbul, Türkiye) supplied the thiopental sodium (Pentothal sodium, 1 g). Analytical-grade chemicals were used for all other standard substances in biochemical reactions.

2.3. Analysis and Preparation of the *Hippophae rhamnoides* L. Leaves Ethanol Extract

HR was obtained from Erzurum province in Türkiye. HR was defined by Prof. Dr. Ali Aslan from Yüzüncü Yıl University, Faculty of Pharmacy, Department of Botany, using international diagnostic methods. HR leaves were cleaned and dried at 25 °C. The plant leaves were ground into a powder with liquid nitrogen in a mortar. It was extracted in 70% ethyl alcohol by filtration in a water bath at 50 °C every 12 hours for a total of 72 hours and the filtrates were collected in glass bottles. It was then evaporated in the evaporator under reduced pressure at 50 °C. The extract, which was completely removed from its dissolvent, was placed in a storage box and stored in a refrigerator (2-8 °C).

2.4. Experimental Design

The 35 rats were divided into 7 groups at random (n = 5 per group) as showed Table 1. Drug doses were selected according to previous studies following the literature. The doses of 25 mg/kg IND (Calik et al., 2020), 20 mg/kg FAM (Toktay et al., 2022), and 100, 250, and 500 mg/kg HR (Saggu and Kumar, 2008; Halis Suleyman et al., 2001) were chosen according to previous studies in accordance with the literature and they were administered orally by gavage to rats.

2.5. Indomethacin-Induced Gastric Ulcer Model

All rats except the healthy group fasted for 24 hours before the experiment in a special ulcer cage with tor underneath to empty the stomach and prevent coprophagia without limiting water access. At the conclusion of this time, the corresponding rat groups received the HR and FAM treatments in the aforementioned dosages. Five minutes after the HR treatments, all groups, except the healthy and HR III groups, received an oral gavage dose of IND at a dosage of 25 mg/kg. All of the rats were put to death using the high-dose anesthetic thiopental 50 mg/kg six hours after receiving IND. Following the midline cut rat stomachs were removed. They were washed with serum physiological solution (0.9% NaCl) and a macroscopical examination revealed the presence of an ulcer emphasis on the gastric surface. Following this assessment, the stomachs were kept at 80 °C for biochemical evaluations.

2.6. Macroscopic Examination of Stomach Tissue

To evaluate gastric lesions macroscopically, rat stomach tissues were opened along the greater quartile. After

washing with physiological saline, the number and areas of ulcers were determined. Ulcer area widths were measured with a magnifying glass using millimetric paper. The antiulcer effects of HR and FAM were calculated according to the formula (equation 1) below.

$$\text{Antiulcer effect} = \frac{\text{IND group ulcer area} - \text{experimental group ulcer area}}{\text{IND group ulcer area}} \times 100 \quad (1)$$

2.7. Biochemical Investigations

100 mg of all specimens reserved for biochemical investigations were treated with 1 ml of PBS, ground in liquid nitrogen with a Tissue Lyser II (Qiagen), and centrifuged. Supernatants obtained by centrifugation were used as samples. SOD (Cayman Chemical Superoxide Dismutase Assay Kit Item Number 706002), GSH (Cayman Chemical Glutathione Assay Kit Item Number 703002), and MDA (Cayman Chemical TBARS Assay Kit Item Number 10009055) levels were

determined with an enzyme-linked immunosorbent assay (ELISA) reader. SOD activity, GSH, and MDA levels of the stomach tissues expressed respectively as U/mg, μM/mg, and μM/mg tissue. The mean and standard deviation for each set of data was displayed per mg of tissue.

2.8. Statistical Analysis

For the statistical analysis of biochemical results (SOD activity, GSH and MDA levels), we used SPSS 20.0 software program and the results are presented as the means ± standard deviation (SD). Comparisons between the groups were performed using the One-Way ANOVA and Duncan multiple comparison tests. P value less than 0.05 was considered statistically significant. Means with the same letter in the same column do not differ significantly from each other, whereas means with different letters in the same column show significant differences between the groups.

Table 1. Experimental groups and design to investigate the effects of HR in the stomach tissue on indomethacin-induced gastric ulcer in rats

Groups	24 h before ulcer-induced	5 min before ulcer-induced	0th hour ulcer-induced	6 h after ulcer-induced
Healthy	-	-	-	Sacrification
HR III	Fasted	HR (500 mg/kg)	-	Sacrification
IND	Fasted	-	Indomethacin (25 mg/kg)	Sacrification
IND+FAM	Fasted	Famotidine (20 mg/kg)	Indomethacin (25 mg/kg)	Sacrification
IND+HR I	Fasted	HR (100 mg/kg)	Indomethacin (25 mg/kg)	Sacrification
IND+HR II	Fasted	HR (250 mg/kg)	Indomethacin (25 mg/kg)	Sacrification
IND+HR III	Fasted	HR (500 mg/kg)	Indomethacin (25 mg/kg)	Sacrification

FAM= famotidine, HR= *hippophae rhamnoides* L. leaves ethanol extract, IND= indomethasine

3. Results

3.1. Macroscopic Findings of Impacts of HR on Stomach Tissue

To investigate the effects of HR on IND-induced gastric ulcer, stomach tissue was examined macroscopically and ulcer areas were shown in Table 2. There were no gastric damage areas noted in the Healthy and HRIII groups. Also, ulcer focus was not seen in the IND+FAM group. The

macroscopic findings of this group were similar to those of the Healthy group. In the stomach tissues of the IND group, serious ulcer areas were observed. The ulcer areas decreased in the treatment groups (IND+HRI, IND+HRII, and IND+HRIII), compared with the ulcer group (P<0.05). When the treatment groups were compared among themselves, the closest result to the healthy group was obtained with the IND+HRII(250mg/kg) administration.

Table 2. Macroscopic findings of the effects of HR in the stomach tissue on indomethacin-induced gastric ulcer in rats

Groups	Dose (mg/kg)	Rat	Ulcer area (mm ²)	Antiulcer effect (%)
Healthy		5	0.0 ± 0.0 ^a	0
HR III	500	5	0.0 ± 0.0 ^a	0
IND	25	5	40.0 ± 1.581 ^f	-
IND+FAM	20	5	7.6 ± 1.140 ^b	81
IND+HR I	100	5	25.2 ± 1.483 ^e	37
IND+HR II	250	5	12.0 ± 0.707 ^c	70
IND+HR III	500	5	15.2 ± 0.837 ^d	62

FAM= famotidine, HR= *hippophae rhamnoides* L. leaves ethanol extract, IND= indomethasine

3.2. Impacts of HR on Oxidant and Antioxidant Parameters in Stomach Tissue

To investigate the effect on oxidative stress parameters of HR, SOD activity (Figure 1), GSH (Figure 2), and MDA (Figure 3) levels were analyzed and quantitative findings were showed Table 3. The administration of alone 500 mg/kg HR did not affect SOD activity, GSH, and MDA levels in comparison to the healthy group ($P > 0.05$) (Fig 1-3). SOD activity, which indicates an antioxidant system, was dramatically lower in the IND group in comparison to the healthy group ($P < 0.05$). The HR therapy (IND+HR I, IND+HR II, and IND+HR III) remarkably healed the decreased SOD activity induced by gastric ulcer ($P < 0.05$) in comparison to the IND group (Figure 1). When the treatment groups were compared among themselves, the closest result to the healthy group was obtained with the 250mg/kg HR administration.

GSH level, a sign of the antioxidant situation, significantly reduced due to oxidative stress damage in the stomach tissues of the IND group ($P < 0.05$). HR administration (IND+HR I, IND+HR II, and IND+HR III) significantly fixed the drop in GSH levels engendered by gastric ulcer ($P < 0.05$), as compared to the IND group. MDA levels, indicators of the oxidant status, increased in the IND group as compared to the healthy group ($p < 0.05$). HR administration improved the increase in MDA levels induced by a gastric ulcer, crosschecked to the IND group. When the HR treatment groups were compared among themselves, the closest result to the healthy group was obtained with the IND+HR II (250 mg/kg) administration. Furthermore, the 250mg/kg HR application generated the closest results to the healthy group.

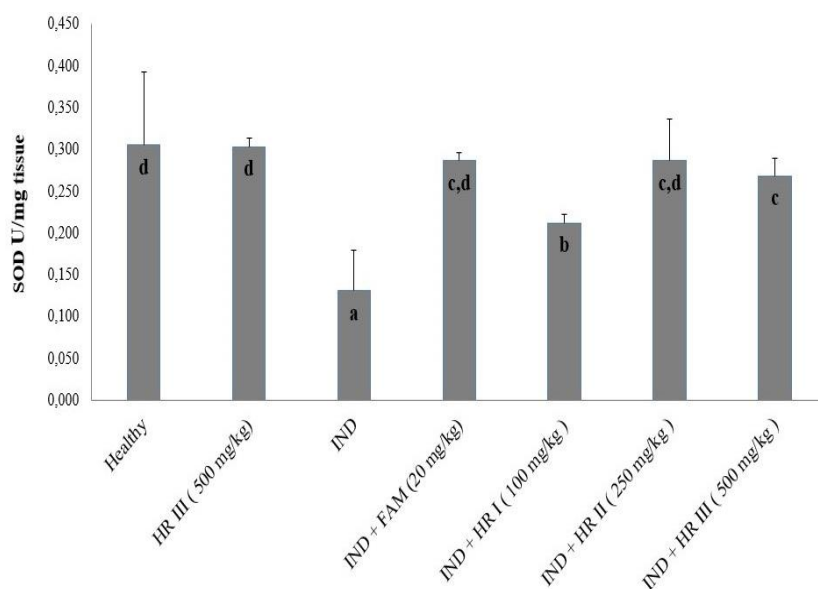


Figure 1. The effects of HR on SOD activity (U/mg tissue) on indomethacin-induced gastric ulcer in rats. FAM= famotidine, HR= *hippophae rhamnoides* L. leaves ethanol extract, IND= indomethasine.

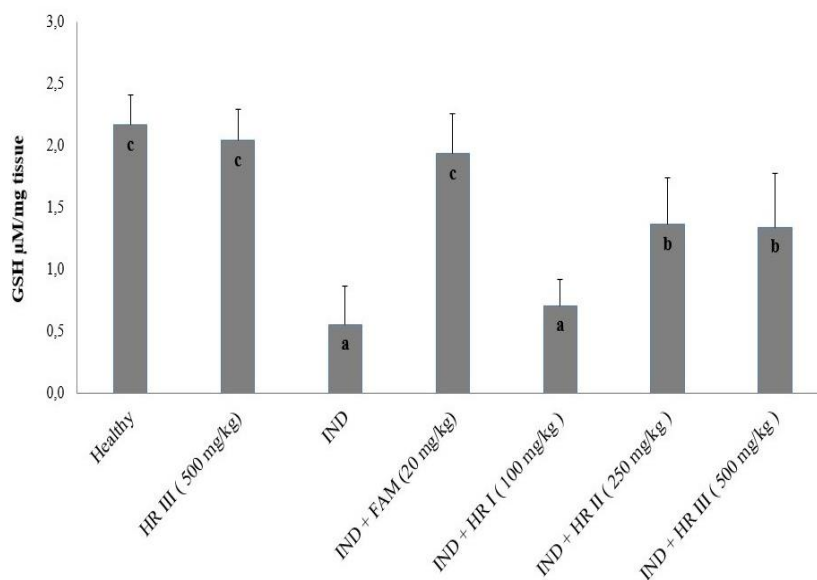


Figure 2. The effects of HR on GSH levels (µM/mg tissue) on indomethacin-induced gastric ulcer in rats. FAM= famotidine, HR= *hippophae rhamnoides* L. leaves ethanol extract, IND= indomethasine.

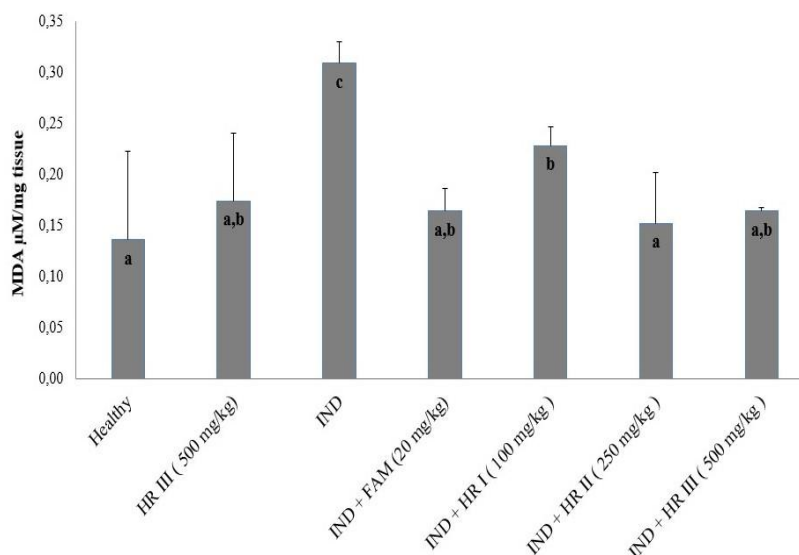


Figure 3. The effects of HR on MDA levels (µM/mg tissue) on indomethacin-induced gastric ulcer in rats FAM= famotidine, HR= *hippophae rhamnoides* L. leaves ethanol extract, IND= indomethasine.

Table 3. Quantitative findings of the effects of HR on oxidative stress in indomethacin-induced gastric ulcer in rats

Groups	Dose (mg/kg)	Rat	SOD (U/mg tissue)	GSH (µM/mg tissue)	MDA (µM/mg tissue)
Healthy		5	0.305 ± 0.087 ^d	2.168 ± 0.245 ^c	0.136 ± 0.087 ^a
HR III	500	5	0.303 ± 0.011 ^d	2.042 ± 0.252 ^c	0.174±0.067 ^{a,b}
IND	25	5	0.131 ± 0.049 ^a	0.557 ± 0.310 ^a	0.309 ± 0.021 ^c
IND+FAM	20	5	0.286 ± 0.010 ^{c,d}	1.935 ± 0.326 ^c	0.164±0.022 ^{a,b}
IND+HR I	100	5	0.212 ± 0.010 ^b	0.707 ± 0.208 ^a	0.228 ± 0.019 ^b
IND+HR II	250	5	0.286 ± 0.005 ^{c,d}	1.365 ± 0.375 ^b	0.152 ± 0.050 ^a
IND+HR III	500	5	0.268 ± 0.021 ^c	1.340 ± 0.440 ^b	0.164±0.003 ^{a,b}

FAM= famotidine, HR= *hippophae rhamnoides* L. leaves ethanol extract, IND= indomethasine

4. Discussion

Gastric ulcer severity varies according to age, gender, and geographic location, and it is linked to serious complications such as hemorrhages, perforations, gastrointestinal blockage, and cancer. As a result of its high morbidity, mortality, and financial damage, this clinical manifestation represents a global health problem (Adinortey et al., 2013). A gastric ulcer evolves when the physiological balance between harmful and protective factors in the gastrointestinal tract is disrupted (Mahmoud et al., 2021).

The pharmacological functions of HR are traditionally well-known (Pundir et al., 2021; Shivapriya et al., 2015). It includes vitamins A and C, alpha-tocopherol, large quantities of carotenoids, vitamin E, minerals, monosaccharides, amino acids, flavonoids, fatty acids, phytosterols, glycerol phospholipids, zeaxanthin esters, and polyphenolic compounds (Zakynthinos and Varzakas, 2015). With this information in mind, the protective effects of ethanol extract of *Hippophae rhamnoides* L. Leaves on IND-induced gastric ulcer in rats were evaluated macroscopically and biochemically.

Primarily, we evaluated ulcer areas macroscopically to investigate the effects of HR in stomach tissues on IND-

induced gastric ulcer. Regarding the macroscopic scores in the current investigation, the total damage score of ulcer areas was quite high in the IND group, while the score was reduced in the groups treated with HR. In the ulcer group, severe macroscopic alterations showed gastric mucosa. In contrast, the macroscopic aspect of the gastric mucosa in the groups treated with HR was nearly too healthy group.

Oxidative stress indicates a severe imbalance between free radical formation and antioxidant defense mechanisms (Bostanci et al., 2016). One of the key factors involved in the disease complication and development causing IND-induced gastric ulcer is oxidative stress. Oxidative stress results from either ROS overproduction or decreased antioxidant activity (Balmus et al., 2016). Either an increase in ROS production or a decrease in antioxidant activity causes oxidative stress. Under typical physiological conditions, the body has an integrated oxidation-antioxidation balance system (Ding and Hong, 2013). The constant production and elimination of ROS maintain the dynamic equilibrium of the oxidation-antioxidation system, and an imbalance in this system is one of the main factors contributing to the development of stomach ulcers (Suo et al., 2016). One common sign of this imbalance is the loss of antioxidant enzymes (like

SOD and GSH-Px) and the rise in oxidative stress products (like MDA) (Li et al., 2017). These antioxidant parameters, along with oxidation products, somewhat reflect the degree of gastric tissue injury and levels of oxidative stress.

We investigated the biochemical-oxidative stress parameters related to gastric ulcer, SOD activity, GSH and MDA levels. Previous studies have shown that the MDA level increased and SOD activity and GSH levels decreased, after gastric ulcer injury (Harakeh et al., 2022; Jafari et al., 2022). Ermis et al. demonstrated that MDA levels significantly raised, while GSH and SOD levels were significantly decreased in the rats with gastric ulcer (Ermis et al., 2023). Guzmán-Gómez et al. reported that MDA levels increased, while GSH and SOD levels were significantly decreased in IND-induced gastric ulcer in rats (Guzman-Gomez et al., 2023). Our research detected SOD activity and the levels of GSH and MDA in stomach tissue and we found that compared with the healthy group, the MDA level in the stomach tissue of the IND group was significantly increased, while GSH level and SOD activity were significantly decreased, suggesting that after gastric ulcer, oxidative stress reaction was aggravated in the stomach tissues. Consistent with other findings reported in the literature, our result suggests that oxidant parameter generation increases, while anti-oxidant parameter generation decreases in the gastric ulcer situation.

HR treatment importantly reduced MDA levels and significantly raised GSH level and SOD activity. Especially IND plus HR II (250 mg/kg) administration generated the closest results to the healthy group by regulating oxidative stress. These HR-induced impacts appeared to be correlated with the suppression of oxidative stress and, to a lower extent, inflammatory reactions. These findings demonstrated that HR reduced oxidative stress and alleviated gastric ulcer. Geetha et al. reported that leaf extract of HR modulated GSH and MDA levels and protected the animals from chromium-induced oxidative injury (Geetha et al., 2003). Maheshwari et al. reported that the phenolic-rich fraction of HR provided significant protection against oxidative damage modulated GSH level and SOD activity (Maheshwari et al., 2011). Kubczak et al. In a human cell toxicity study, it was discovered that *Hippophae rhamnoides* L. leaf extracts are rich in bioactive compounds with potent antioxidant activity (Kubczak et al., 2022). Moreover, previous studies have shown HR restored oxidative stress parameters in various studies (Cho et al., 2017; Dubey et al., 2016). Consistent with other findings reported in the literature, our result suggests that HR treatment reduces oxidant parameter generation while increasing anti-oxidant parameter generation, protecting stomach tissue from gastric ulcer by controlling oxidative stress, similar but not superior to famotidine. Also, our biochemical findings were corroborated by our macroscopic findings. With its natural content, HR can play an important role in the production of new preventive drugs against ulcers.

Perhaps in future studies, the superiority to famotidine can be evaluated with molecular analysis and by studying different doses of HR as a natural nutrient.

The study's limitations involve the inability to investigate the anti-inflammatory effects of HR on IND-induced gastric ulcers. We believe that more in-depth studies, including molecular analyses, are now required to gain a better understanding of the influence mechanism demonstrated in this research. The primary goal of the study was to determine whether HR has a positive impact on IND-induced gastric ulcer in rats by biochemical analyses.

In reality, macroscopic imaging of the effects of HR on IND-induced gastric ulcers may be preferable. We anticipate that this study will inspire additional research. Future research might also look into the molecular basis of HR. However, as the first to demonstrate HR's impact on IND-induced gastric ulcer, this study is particularly significant.

Based on the macroscopic and biochemical findings, we have shown that HR significantly improved IND-induced gastric ulcer. HR may intervene with antioxidant processes that may be essential in gastric ulcer damage. HR may be a promising agent in the development of novel preventative therapies for gastric ulcers with its natural ingredient.

Author Contributions

The percentage of the author(s) contributions is present below. All authors reviewed and approved final version of the manuscript.

	L.D	M.G	T.N.Y.	Z.H.	D.C.	G.M.D.
C	50	50				
D	50	50				
S	75	25				
DCP	50	10	10	10	10	10
DAI	60				40	
L	60				20	20
W	50		50			
CR	20	20	20	20	10	10
SR	50		50			
PM	40	60				
FA	40	60				

C=Concept, D= design, S= supervision, DCP= data collection and/or processing, DAI= data analysis and/or interpretation, L= literature search, W= writing, CR= critical review, SR= submission and revision, PM= project management, FA= funding acquisition.

Conflict of Interest

The authors declared that there is no conflict of interest.

Ethical Approval/Informed Consent

The authors confirm that the ethical policies of the journal, as noted on the journal's author guidelines page, have been adhered to. The experimental procedures were approved by the Local Animal Care and Ethics Committee Ataturk University. This study and all its protocols were approved by the Experimental Animal Ethics Committee of Ataturk University (approval date: June 22 2013 and protocol code: 36643897-44).

Acknowledgements

This work was supported by Scientific Research Projects Unit of Ataturk University (grant number: 2013/58).

References

Adinortey MB, Ansah C, Galyuon I Nyarko A. 2013. In vivo models used for evaluation of potential antigastroduodenal ulcer agents. *Ulcers*, 2013.

Antonisamy P, Arasu MV, Dhanasekaran M, Choi K. C, Aravinthan A, Kim N. S, . . . Kim JH. 2016. Protective effects of trigonelline against indomethacin-induced gastric ulcer in rats and potential underlying mechanisms. *Food Function*, 7(1): 398-408.

Balmus IM, Ciobica A, Trifan A Stanciu C. 2016. The implications of oxidative stress and antioxidant therapies in Inflammatory Bowel Disease: Clinical aspects and animal models. *Saudi J Gastroenterol*, 22(1): 3-17. doi:10.4103/1319-3767.173753.

Barboza KRM, Coco LZ, Alves GM, Peters B, Vasquez EC, Pereira TMC, . . . Campagnaro B. P. 2018. Gastroprotective effect of oral kefir on indomethacin-induced acute gastric lesions in mice: Impact on oxidative stress. *Life Sci*, 209 370-376. doi:10.1016/j.lfs.2018.08.035

Bhattacharyya A, Chattopadhyay R, Mitra S Crowe S. E. 2014. Oxidative stress: an essential factor in the pathogenesis of gastrointestinal mucosal diseases. *Physiol Rev*, 94(2): 329-354. doi:10.1152/physrev.00040.2012.

Bonciu E, Olaru AL, Rosculete E Rosculete C. A. 2020. Cytogenetic study on the biostimulation potential of the aqueous fruit extract of *Hippophaë rhamnoides* for a sustainable agricultural ecosystem. *Plants*, 9(7): 843.

Bostanci MS, Bakacak M, Inanc F, Yaylali A, Serin S, Attar R, . . . Yildirim G. 2016. The protective effect of G-CSF on experimental ischemia/reperfusion injury in rat ovary. *Arch Gynecol Obstet*, 293(4): 789-795. doi:10.1007/s00404-015-3878-8.

Calik I, Yayla M, Cinar I, Cadirci E, Albayrak A, Sirin B, . . . Halici Z. 2020. LP44 (4-[2-(methylthio)phenyl]-N-(1234-tetrahydronaphthalen-1-yl)-1-piperazinehexanamide): exerts anti-ulcer effects via 5-hydroxytryptamine receptor 7 activation on indomethacin-induced gastric ulcers in rats. *Inflammopharmacol*, 28(4): 893-902. doi:10.1007/s10787-020-00725-3.

Cho C. H, Jang H, Lee M, Kang H, Heo H. J Kim D. O. 2017. Sea Buckthorn (*Hippophae rhamnoides* L.): Leaf Extracts Protect Neuronal PC-12 Cells from Oxidative Stress. *J Microbiol Biotechnol*, 27(7): 1257-1265. doi:10.4014/jmb.1704.04033.

Ding W, Hong L. 2013. Progress research on relationship between oxidative stress and collagen metabolism diseases. *J Jilin University, (Medicine Edition)*: 39(06): 1302-1306.

Dogra R, Tyagi SP, Kumar A. 2013. Efficacy of Seabuckthorn (*Hippophae rhamnoides*): Oil vis-a-vis Other Standard Drugs for Management of Gastric Ulceration and Erosions in Dogs. *Vet Med Int*, 2013: 176848. doi:10.1155/2013/176848.

Dubey S, Deep P, Singh AK. 2016. Phytochemical characterization and evaluation of anticataract potential of seabuckthorn leaf extract. *Vet Ophthalmol*, 19(2): 144-148. doi:10.1111/vop.12271.

Eraslan E, Tanyeli A, Guler MC, Kurt N, Yetim Z. 2020. Agomelatine prevents indomethacin-induced gastric ulcer in rats. *Pharmacol Rep*, 72(4): 984-991. doi:10.1007/s43440-019-00049-2.

Ermis A, Aritici Colak G, Acikel-Elmas M, Arbak S Kolgazi M. 2023. Ferulic acid treats gastric ulcer via suppressing oxidative stress and inflammation. *Life (Basel)*, 13(2). doi:10.3390/life13020388.

Gatlan AM, Gutt G. 2021. Sea Buckthorn in Plant Based Diets. An Analytical Approach of Sea Buckthorn Fruits Composition: Nutritional Value Applications and Health Benefits. *Int J Environ Res Public Health*, 18(17). doi:10.3390/ijerph18178986.

Geetha S, Sai Ram M, Mongia SS, Singh V, Ilavazhagan G, Sawhney RC. 2003. Evaluation of antioxidant activity of leaf extract of Seabuckthorn (*Hippophae rhamnoides* L.): on chromium(VI): induced oxidative stress in albino rats. *J Ethnopharmacol*, 87(2-3): 247-251. doi:10.1016/s0378-8741(03):00154-5.

Guzman-Gomez O, Garcia-Rodriguez RV, Perez-Gutierrez S, Rivero-Ramirez NL, Garcia-Martinez Y, Pablo-Perez SS, . . . Chamorro-Cevallos G. 2023. Protective Effect of the Phycobiliproteins from *Arthrospira maxima* on Indomethacin-Induced Gastric Ulcer in a Rat Model. *Plants (Basel)*, 12(8). doi:10.3390/plants12081586.

Halici Z, Polat B, Cadirci E, Topcu A, Karakus E, Kose D, . . . Bayir Y. 2016. Inhibiting renin angiotensin system in rate limiting step by aliskiren as a new approach for preventing indomethacin induced gastric ulcers. *Chem Biol Interact*, 258: 266-275. doi:10.1016/j.cbi.2016.09.011.

Harakeh S, Saber SH, Akefe IO, Shaker S, Barkaat Hussain M, Saad Almasaudi A, . . . Almasaudi S. 2022. Saudi honey alleviates indomethacin-induced gastric ulcer via improving antioxidant and anti-inflammatory responses in male albino rats. *Saudi J Biol Sci*, 29(4): 3040-3050. doi:10.1016/j.sjbs.2022.01.031.

Isnain FS, Liao NC, Tsai HY, Zhao YJ, Huang CH, Hsu JL, . . . Chen YK. 2022. Freshwater Clam Extract Attenuates Indomethacin-Induced Gastric Damage In Vitro and In Vivo. *Foods*, 12(1). doi:10.3390/foods12010156.

Jafari A, Andishfar N, Esmailzadeh Z, Khezri MR Ghasemnejad-Berenji M. 2022. Gastroprotective effect of topiramate on indomethacin-induced peptic ulcer in rats: Biochemical and histological analyses. *Basic Clin Pharmacol Toxicol*, 130(5): 559-568. doi:10.1111/bcpt.13718.

Jia DR, Abbott RJ, Liu TL, Mao K. S, Bartish IV, Liu JQ. 2012. Out of the Qinghai-Tibet Plateau: evidence for the origin and dispersal of Eurasian temperate plants from a phytogeographic study of *Hippophaë rhamnoides* (Elaeagnaceae). *New Phytologist*, 194(4): 1123-1133.

Kubczak M, Khassenova AB, Skalski B, Michlewska S, Wielanek M, Sklodowska M, . . . Ionov M. 2022. *Hippophae rhamnoides* L. leaf and twig extracts as rich sources of nutrients and bioactive compounds with antioxidant activity. *Sci Rep*, 12(1): 1095. doi:10.1038/s41598-022-05104-2.

Lee HI, Kim MS, Lee KM, Park SK, Seo KI, Kim H. J, . . . Lee MK. 2011. Anti-visceral obesity and antioxidant effects of powdered sea buckthorn (*Hippophae rhamnoides* L.): leaf tea in diet-induced obese mice. *Food Chem Toxicol*, 49(9): 2370-2376. doi:10.1016/j.fct.2011.06.049.

Li W, Wang X, Zhi W, Zhang H, He Z, Wang Y, . . . Zhang X. 2017.

- The gastroprotective effect of nobiletin against ethanol-induced acute gastric lesions in mice: impact on oxidative stress and inflammation. *Immunopharmacol Immunotoxicol*, 39(6): 354-363. doi:10.1080/08923973.2017.1379088.
- Li Y, Xu C, Zhang Q, Liu JY, Tan R.X. 2005. In vitro anti-Helicobacter pylori action of 30 Chinese herbal medicines used to treat ulcer diseases. *J Ethnopharmacol*, 98(3): 329-333. doi:10.1016/j.jep.2005.01.020.
- Maheshwari DT, Yogendra Kumar MS, Verma SK, Singh VK, Singh SN. 2011. Antioxidant and hepatoprotective activities of phenolic rich fraction of Seabuckthorn (*Hippophae rhamnoides* L.): leaves. *Food Chem Toxicol*, 49(9): 2422-2428. doi:10.1016/j.fct.2011.06.061.
- Mahmoud MF, Nabil M, Abdo W, Abdelfattah MAO, El-Shazly AM, El Kharrassi Y, Sobeh M. 2021. Syzygium samarangense leaf extract mitigates indomethacin-induced gastropathy via the NF-kappaB signaling pathway in rats. *Biomed Pharmacother*, 139: 111675. doi:10.1016/j.biopha.2021.111675.
- Pineda-Pena EA, Orona-Ortiz A, Velazquez-Moyado JA, Tavares-Carvalho JC, Chavez-Pina AE, Balderas-Lopez JL, Navarrete A. 2020. Anti-inflammatory antioxidant and gaso-protective mechanism of 3alpha-hydroxymasticadienoic acid and diligustilide combination on indomethacin gastric damage. *Naunyn Schmiedebergs Arch Pharmacol*, 393(8): 1501-1513. doi:10.1007/s00210-020-01857-7.
- Pizzino G, Irrera N, Cucinotta M, Pallio G, Mannino F, Arcoraci V, . . . Bitto A. 2017. Oxidative Stress: Harms and Benefits for Human Health. *Oxid Med Cell Longev* 2017 8416763. doi:10.1155/2017/8416763.
- Pundir S, Garg P, Dwiwedi A, Ali A, Kapoor V, Kapoor D, . . . Negi P. 2021. Ethnomedicinal uses phytochemistry and dermatological effects of *Hippophae rhamnoides* L.: A review. *J Ethnopharmacology*, 26: 113434.
- Purushothaman J, Suryakumar G, Shukla D, Jayamurthy H, Kasiganesan H, Kumar R Sawhney R. C. 2011. Modulation of Hypoxia-Induced Pulmonary Vascular Leakage in Rats by Seabuckthorn (*Hippophae rhamnoides* L.). *Evid Based Complement Alternat Med*, 2011: 574524. doi:10.1093/ecam/nep199.
- Purushothaman J, Suryakumar G, Shukla D, Malhotra AS, Kasiganesan H, Kumar R, . . . Chami A. 2008. Modulatory effects of seabuckthorn (*Hippophae rhamnoides* L.): in hypobaric hypoxia induced cerebral vascular injury. *Brain Res Bull* 77(5): 246-252. doi:10.1016/j.brainresbull.2008.08.026.
- Ran B, Guo CE, Li W, Li W, Wang Q, Qian J, Li H. 2021. Sea buckthorn (*Hippophae rhamnoides* L.): fermentation liquid protects against alcoholic liver disease linked to regulation of liver metabolome and the abundance of gut microbiota. *J Sci Food Agric*, 101(7): 2846-2854. doi:10.1002/jsfa.10915.
- Saggu S Kumar R. 2008. Effect of seabuckthorn leaf extracts on circulating energy fuels lipid peroxidation and antioxidant parameters in rats during exposure to cold hypoxia and restraint (C-H-R): stress and post stress recovery. *Phytomedicine*, 15(6-7): 437-446. doi:10.1016/j.phymed.2007.11.002.
- Sharma B, Arora S, Sahoo D Deswal R. 2020. Comparative fatty acid profiling of Indian seabuckthorn showed altitudinal gradient dependent species-specific variations. *Physiol Molec Biol Plants*, 26: 41-49.
- Shivapriya S, Ilango K Dubey G. P. 2015. Evaluation of antioxidant and neuroprotective effect of *Hippophae rhamnoides* (L.): on oxidative stress induced cytotoxicity in human neural cell line IMR32. *Saudi J Biol Sci*, 22(5): 645-650. doi:10.1016/j.sjbs.2015.04.011.
- Suleyman H, Buyukokuroglu M, Koruk M, Akcay F, Kiziltunc A Gepdiremen A. 2001. The effects of *Hippophae rhamnoides* L. extract on ethanol-induced gastric lesion and gastric tissue glutathione level in rats: a comparative study with melatonin and omeprazole. *Indian J Pharmacology*, 33(2): 77-81.
- Suleyman H, Demirezer LO, Buyukokuroglu ME, Akcay MF, Gepdiremen A, Banoglu Z. N Gocer F. 2001. Antiulcerogenic effect of *Hippophae rhamnoides* L. *Phytother Res*, 15(7): 625-627. doi:10.1002/ptr.831.
- Suo H, Zhao X, Qian Y, Sun P, Zhu K, Li J Sun B. 2016. Lactobacillus fermentum Suo Attenuates HCl/Ethanol Induced Gastric Injury in Mice through Its Antioxidant Effects. *Nutrients*, 8(3): 155. doi:10.3390/nu8030155.
- Toktay E, Yayla M, Sahin L, Harmankaya A, Ozic C, Aksu Kilice P, . . . Bayram P. 2022. The effects of dragon fruit (*Hylocereus polyrhizus*): extract on indomethacin-induced stomach ulcer in rats. *J Food Biochem*, 46(9): e14274. doi:10.1111/jfbc.14274.
- Upadhyay NK, Kumar R, Siddiqui MS Gupta A. 2011. Mechanism of Wound-Healing Activity of *Hippophae rhamnoides* L. Leaf Extract in Experimental Burns. *Evid Based Complement Alternat Med*, 2011: 659705. doi:10.1093/ecam/nep189.
- Wang GY, Chen SY, Chen YY, Hong CJ, Hsu YH Yen GC. 2021. Protective effect of rosmarinic acid-rich trichodesma khasianum clarke leaves against ethanol-induced gastric mucosal injury in vitro and in vivo. *Phytomedicine*, 80: 153382. doi:10.1016/j.phymed.2020.153382.
- Wang K, Xu Z Liao X. 2022. Bioactive compounds health benefits and functional food products of sea buckthorn: a review. *Crit Rev Food Sci Nutr*, 62(24): 6761-6782. doi:10.1080/10408398.2021.1905605.
- Xing J, Yang B, Dong Y, Wang B, Wang J Kallio HP. 2002. Effects of sea buckthorn (*Hippophae rhamnoides* L.): seed and pulp oils on experimental models of gastric ulcer in rats. *Fitoterapia*, 73(7-8): 644-650. doi:10.1016/s0367-326x(02):00221-6..
- Xu X, Xie B, Pan S, Liu L, Wang Y Chen C. 2007. Effects of sea buckthorn procyanidins on healing of acetic acid-induced lesions in the rat stomach. *Asia Pac J Clin Nutr*, 16(Suppl 1): 234-238.
- Yoldaş A, Eser N, Yaylalı A, Kökbaş U Bozkurt AS. 2022. Attenuation of senescence-induced oxidative exacerbations in aged rat testis by ferula elaeochytris root extract. *European J Therapeutics*, 28(4): 306-312.
- Zakynthinos G, Varzakas T. 2015. *Hippophae rhamnoides*: safety and nutrition. *Current Res Nutri Food Sci J*, 3(2): 89-97.