

EDİTÖRE MEKTUP / LETTER TO THE EDITOR

Superficial femoral vein injury: is it mortal?

Süperfisyal femoral ven yaralanması: ölümcül olabilir mi?

Mihriban Yalçın¹, Eda Gödekmerdan¹, Kaptanı Derya Tayfur¹, Serkan Yazman¹

¹Ordu State Hospital, Ordu, Turkey

Cukurova Medical Journal 2017;42(3):594-595

Dear Editor,

Venous injuries vary from contusion to full transection. Blunt trauma, stab wound, bullet, bomb fragments and hyperextension injury are causes of venous injuries. Lesions of large vessels are best managed by using contralateral saphenous vein. For good functional recovery prompt vascular imaging and surgical treatment are required. Femoral vein traumatic injuries are rare. The overall incidence of vascular injuries is very low, estimated at 0.9 to 2.3 per 100,000¹. Hemodynamic instability, major decreases in hematocrit, active bleeding or the absence of distal pulses are the symptoms of an unsuspected vascular lesion². Venous obstruction, cyanosis and oedema of the affected limb are the signs of femoral vein injury. Venous injuries usually have normal palpable distal pulses and may mimic a deep vein thrombosis when compared with arterial injuries. The saphenous vein harvested from the other leg is the preferred conduit.

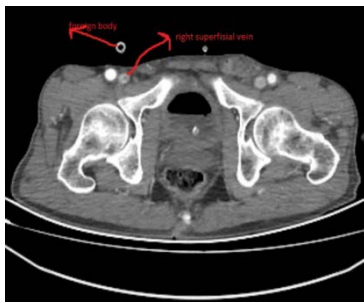


Figure 1. CT angiography shows intact femoral vein and artery.

Herein we present an unusual case of an isolated superficial femoral vein injury from a gunshot accidentally and repaired with an interposition of contralateral saphenous vein. A 62-year-old shepherd admitted to our emergency department, he suffered a gunshot wound to the right lower extremity. He was unconscious and hemodynamically unstable on admission. Physical examination was unremarkable except for entry and exit wounds. Aortabifemoral CT revealed that vascular system was intact. (Figure 1).

His haemoglobin value was 6.4 g/dL. We thought that he was in shock after extensive hemorrhage with a blood pressure of 60/40 mmHg requiring immediate resuscitation with 5 units blood products and crystalloid. The decision was made to explore the affected area to improve the patient's symptoms. The patient was taken to operation emergently. There was a complete disruption on superficial femoral vein. The contralateral saphenous vein was then harvested for use as an interposition graft. Vascular repair was performed by using interposition of contralateral saphenous graft. The contralateral saphenous vein was used in order to preserve the ipsilateral saphenous vein and maximize venous collateral flow in the injured extremity.

The post-operative course was uneventful. The patient was heparinized and then was discharged home with ASA and compression sock and without swollen leg. Two weeks later doppler ultrasound revealed the vein graft was patent with no stenosis and he had resumed all normal activities. The

Yazışma Adresi/Address for Correspondence: Dr. Mihriban Yalçın, Ordu State Hospital, Ordu, Turkey. E-mail: mihribandemir33@hotmail.com

Geliş tarihi/Received: 06.07.2016 Kabul tarihi/Accepted: 02.10.2016

patient is symptom-free after 2 months of follow-up.

The best treatment for major venous injuries remains controversial. But surgical reconstruction of vein lesions is recommended. Venous repair can be performed by primary repair or end-to-end anastomosis in case of minor injuries. But when more severe injuries occurs interposition grafts or patch venoplasty are required. In the haemodynamically unstable patient the first choice may be primary venous ligation which causes severe postoperative oedema. In the studies it was reported that significant comorbidity (limb oedema and post-phlebotic limbs) associated with ligation than repair. But Yelon et al reported that 86% of patients treated by ligation of pelvic or lower extremity venous injuries were free of oedema at discharge ³. Thrombosis and failure of repair can occur in up to 15% patency rate up to 74% following repair ⁴. For optimal long-term patency and to minimize chronic complications a durable venous repair is needed. For managing life-threatening hemorrhage and avoiding limb threatening compartment syndrome and long-term chronic swelling, femoral venous injury must

be treated quickly⁵. This case highlights that isolated vascular injury, can be mortal if it does not treat promptly.

REFERENCES

1. Larsen MB, Bækgaard N. Acceptable results after venous reconstructive surgery following iatrogenic injuries to the iliofemoral vein segment. *Dan Med J*. 2012;59:A4410.
2. Davaine JM, Lintz F, Cappelli M, Chaillou P, Gouin F, Patra P et al. Acute compartment syndrome of the thigh secondary to isolated common femoral vessel injury: an unusual etiology. *Ann Vasc Surg*. 2013;27:802.e1-802. e4
3. Yelon JA, Scalea TM. Venous injuries of the lower extremities and pelvis: repair versus ligation. *J Trauma*. 1992;33:532-6.
4. Hassouna A, Dennis M. Handlebar injury to femoral vein: case report and review. *Phlebology*. 2011;26:311-2.
5. Holt AM, West CA, Davis JA, Gilani R, Askenasy E. Common femoral vein reconstruction using internal jugular vein after blast injury. *Ann Vasc Surg*. 2014;28:1791.e5-7.