



## Lens absorption and aphakia secondary to trauma

Nazife Sefi Yurdakul\*, Seda Bodur

Department of Ophthalmology, İzmir Atatürk Education and Research Hospital, İzmir, Turkey

### ARTICLE INFO

### ABSTRACT

#### Article History

Received 19 / 03 / 2015

Accepted 26 / 07 / 2015

#### \* Correspondence to:

Nazife Sefi Yurdakul  
Department of Ophthalmology,  
İzmir Atatürk Education and Research  
Hospital,  
İzmir, Turkey  
e-mail: nsefi@yahoo.com

In this article we aimed to report a case with lens absorption and aphakia secondary to trauma. A 27-year-old woman presented with low vision and exotropia. Biomicroscopic examination demonstrated no pathology in the right eye. The left eye was aphakic with intact lens capsule and minimal central corneal opacity. The uncorrected visual acuity was 20/20 in the right eye and hand movement in the left eye. The best corrected visual acuity was 20/40 with +12.00 D in her left eye. She had not undergone any eye surgery, however, the parents described a trauma to her left eye at the age of seven. Routine blood tests were within normal range. Our diagnosis was cataractous or clear lens absorption secondary to trauma and sensory exotropia. Following secondary intraocular lens implantation and strabismus surgery, visual acuity of the patient increased and orthophoria was achieved. Consequently, lens absorption should always be considered in cases with aphakia secondary to trauma.

#### Keywords:

Aphakia  
Exotropia  
Lens  
Trauma

© 2017 OMU

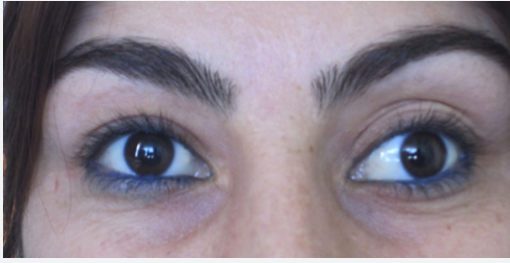### 1. Introduction

Absorption of cataractous or clear crystalline lens is a rare clinical condition. Trauma and intraocular foreign bodies are among the main causes reported to lead to absorption (Gobert et al., 1995; Rofagha et al., 2008). Painter et al. (2008) presented the case of a young man who accidentally penetrated his cornea and lens with a needle and subsequently developed lens absorption. Similarly, in this report, we will discuss a case with lens absorption likely to trauma which occurred without any eye surgery. This was the first case of lens absorption secondary to trauma that we had encountered throughout our clinical practice.

### 2. Case report

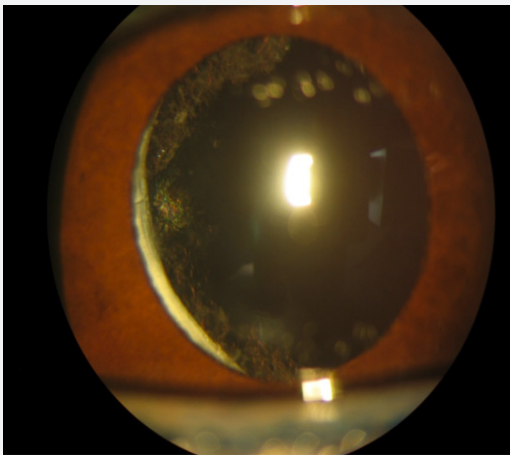
A 27-year-old woman was admitted to our clinic

with complaints of low visual acuity and strabismus. The uncorrected visual acuity was 20/20 in the right eye and hand movement in the left eye. The best corrected visual acuity was 20/40 with +12.00 D in her left eye. The intraocular pressure was 14 mmHg in the right eye and 15 mmHg in the left eye. She had 60 prism diopters monocular sensory exotropia at both near and distance in her left eye (Fig. 1). Slit-lamp biomicroscopic examination of the right eye revealed entirely normal ocular findings. She had minimal central corneal opacity in the left eye that could hardly be observed; the depth of the anterior chamber, iris, pupil and posterior segment were normal. The patient was aphakic with an intact lens capsule and peripheral opacities (Fig. 2). No history of ocular surgery including perforation repair or cataract extraction



**Fig. 1.** Monocular sensory exotropia in her left eye

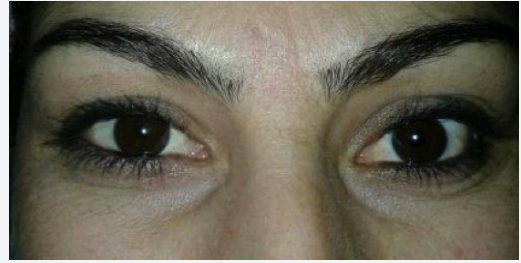was reported by the patient or her parents. However, the parents described a trauma to her left eye at the age of seven, and in the subsequent years she developed exotropia. Routine blood tests were within normal range. Our diagnosis was cataractous or clear lens absorption secondary to trauma and sensory exotropia.



**Fig. 2.** Anterior segment photography of the left eye showing aphakia and intact lens capsule with peripheral opacities.

According to the tenets of the Declaration of Helsinki, informed consent was obtained from the patient. Then, under topical anesthesia with benoxinate 0.4% drops, a 22.00 diopter biconvex, hydrophobic acrylic foldable intraocular lens with polymethylmethacrylate haptics (Sensor, Model AR40e, Abbott Medical Optics Inc. USA) was implanted in the ciliary sulcus. Two months after intraocular lens implantation, 8 mm lateral rectus muscle recession combined with 7.5 mm medial rectus muscle resection was performed in the left eye under general anesthesia.

Six months postoperatively, the best corrected visual acuity improved to 20/32 with minus 1.50 at 45 degrees in the left eye. In primary position, the patient had orthotropia at near and distance by cover test (Fig. 3).



**Fig. 3.** Appearance of the patient after strabismus surgery

### 3. Discussion

Absorption of crystalline lens is an unusual clinical condition without any surgical intervention. Marlow's (1952) review of the literature and his own cases indicated the prevalence of this condition to be one case reported annually. He discussed the classification of the causes of spontaneous absorption, including absorption after spontaneous rupture of the anterior or posterior capsule. Osmotic forces induced by chemical changes on either side of the lens capsule are thought to be of great importance. It was postulated that osmotic forces between the aqueous or vitreous humor and lens cause the lens fibers to disintegrate when the lens capsule is no longer intact.

Gobert et al. (1995) described a case of a paralimbal scleral perforation with iris prolapse and aphakia due to resorption of the lens probably caused by an amniocentesis needle. Painter et al. (2008) reported the case of a young man who inadvertently penetrated his cornea and lens with a needle used for injecting heroin. Three years later, the lens had completely reabsorbed leaving a fibrosed capsular bag resulting in aphakia. They reported achieving excellent visual outcome with a secondary intraocular lens implantation. Similarly, in the history of cataract surgery, lens discission was performed in the treatment of congenital cataract cases for many years. The disintegrated lens substance as a result of discission led to spontaneous absorption, or the released lens substance was irrigated and aspirated within the next few days (Buller, 1899; Jackson, 1913). Our patient was initially assumed to have had a traumatic cataract surgery. However, her medical history revealed that she hadn't undergone any kind of eye surgery before, or even had an eye examination, and she did not have any systemic disease. Based on the corneal nephelion that could hardly be seen with the slit-lamp biomicroscopic examination, and also normal iris and pupil examinations, the patient was considered to have lens absorption secondary to trauma with or without the possibility of cataract formation. Eventually, decreased visual acuity due to aphakia and binocular dysfunctions anticipated the development of

sensory exotropia over time. Visual acuity of the patient increased with secondary intraocular lens implantation and orthophoria was achieved with strabismus surgery.

In conclusion, lens absorption and aphakia may rarely develop secondary to trauma without any eye surgery.

#### REFERENCES

- Buller, F., 1899. Double needle intended to facilitate the dissection of secondary cataract. *Trans. Am. Ophthalmol. Soc.* 8, 563-567.
- Gobert, A., Vereecken, G., Meire, F., Van Oye, R., De Laey, J.J., 1995. Ocular perforation in utero. *Bull. Soc. Belge. Ophthalmol.* 259, 77-80.
- Jackson, E., 1913. Dissection of the crystalline lens. *Trans. Am. Ophthalmol. Soc.* 13, 394-402.
- Marlow, S.B., 1952. Spontaneous absorption of cataract. *Trans. Am. Ophthalmol. Soc.* 50, 283-293.
- Painter, S.L., Imrie, F.R., Mayer, E.J., 2008. Lens reabsorption following self-induced needling and subsequent intracapsular secondary intraocular lens placement. *J. Cataract Refract. Surg.* 34, 868-870. doi: 10.1016/j.jcrs.2007.12.037.
- Rofagha, S., Day, S., Winn, B.J., Ou, J.I., Bhisitkul, R.B., Chiu, C.S., 2008. Spontaneous resolution of a traumatic cataract caused by an intralenticular foreign body. *J. Cataract Refract Surg.* 34, 1033-1035. doi:10.1016/j.jcrs.2008.01.033.