



The Relationship Between the Prenatal Exposure to Terbinafine and Abnormal Skin Development in the Newborn Rats*

İsmail CAN¹✉, Hüseyin Serhat İNALÖZ², Serap Sergül İNALÖZ³, Necmetin KIRTAK², Ayhan ERALP³, Jale SELLİ⁴, Gülname Fındık GÜVENDİ⁵

1. Kafkas University, Faculty of Medicine, Department of Histology and Embryology, Kars, TURKEY.
2. Gaziantep University, Faculty of Medicine, Department of Dermatology, Gaziantep, TURKEY.
3. Gaziantep University, Faculty of Medicine, Department of Histology and Embryology, Gaziantep, TURKEY.
4. Atatürk University, Faculty of Medicine, Department of Histology and Embryology, Erzurum, TURKEY.
5. Kafkas University, Faculty of Medicine, Department of Pathology, Kars, TURKEY.

Geliş Tarihi/Received
27.10.2014

Kabul Tarihi/Accepted
26.02.2015

Yayın Tarihi/Published
20.10.2015

Abstract: The aim of our study is to investigate the safety of terbinafine usage in pregnancy. This study was designed to investigate the teratogenic effects of prenatal terbinafine exposure in newborn rats in terms of macroscopic organ anomalies, anthropometric scales and abnormalities in skin development. Female Wistar-Albino rats (250–300 g) were randomly divided into a control group (physiological saline, during pregnancy; n=6), group A (terbinafine treatment, 20 mg/kg/day, for 21 days; n=6), group B (terbinafine treatment, 20 mg/kg/day, for 51 days; n=6) and group C (terbinafine treatment, 60 mg/kg/day, for 21 days; n=6). After birth, five rat pups from each experimental group were sacrificed by intracardiac infusion of 10% formalin. Skin biopsies were performed from the abdominal region and prepared for light microscopic analysis. Hyperkeratosis, epidermal atrophy and disordered epidermal cell lineage were demonstrated in all terbinafine doses with increase in severity at higher doses. Damage to hair follicles was observed in groups B and C. In conclusion, terbinafine exposure during pregnancy can cause abnormalities of the skin and growth retardation in newborn rats, and the effects vary depending upon application time and dose.

Keywords: Rat, Skin, Teratogenicity, Terbinafine.

Yeni Doğan Sıçanlarda Prenatal Terbinafine Maruziyeti ile Anormal Deri Gelişimi Arasındaki İlişki

Öz: Çalışmamızda, gebelikte terbinafin kullanım güvenliğinin araştırılması amaçlanmıştır. Bu çalışmada deri gelişiminde makroskobik organ anomaliler, antropometrik ölçekler ve anormallikler açısından yeni doğan sıçanlarda prenatal terbinafin maruziyetinin teratojenik etkilerini araştırmak amacıyla tasarlandı. Dişi Wistar-albino sıçanları (250-300 g), rastgele olarak kontrol grubu (n=6, gebelik sırasında fizyolojik su), A grubu (n=6, 21 gün boyunca 20 mg/kg/gün terbinafin tedavisi), B grubu (n=6, 51 gün boyunca 20 mg/kg/gün terbinafin tedavisi) ve C gruplarına (n=6, 21 gün boyunca 60 mg/kg/gün terbinafin tedavisi) ayrıldı. Doğumdan sonra, her bir deney grubundan beş fare yavrusu intrakardiyak 10% formalin uygulaması yoluyla sakrifiye edildi. Deri biyopsileri karın bölgesinden elde edildi ve ışık mikroskobik analizi için hazırlandı. Hiperkeratoz, epidermal atrofi, düzensiz epidermal hücreler tüm terbinafin dozlarında gösterildi. Kıl foliküllerinde hasar grup B ve C'de gözlemlendi. Sonuç olarak, gebelik sırasında terbinafine maruziyet yeni doğan sıçanlarda deri anormallikleri ve büyüme geriliğine neden olabilir ve etkileri uygulama süresi ve doza bağlı olarak değişir.

Anahtar Kelimeler: Deri, Sıçan, Teratojenik, Terbinafin.

✉ İsmail CAN

Kafkas University, Faculty of Medicine, Department of Histology and Embryology, Kars, TURKEY.
e-mail: drismailcan@yahoo.com

*This study was summarized from the postgraduate thesis of İsmail CAN.

INTRODUCTION

Drug usage has been documented more commonly during the first and third trimesters, which exposes the fetus to teratogenic effects during the critical period of organogenesis (1,2). Since no drug administered during pregnancy has been proved to be entirely free of adverse effects concerning well-being of the fetus, great caution should be taken for prescribing drugs during pregnancy to prevent the potential teratogenicity. However, difficulties in testing novel agents in pregnant women as well as a paucity of research have complicated the clarification of drug use during pregnancy when compared to other therapeutic measures (3).

Defined as structural or functional dysgenesis of the fetal organs (4), teratogenesis consists of congenital malformations with varying severity, including intrauterine growth restriction, carcinogenesis and fetal demise. Hence, an understanding of the mechanisms underlying teratogenicity is crucial to estimate the potential risk of a certain drug to produce congenital malformations (3) as well as to optimize drug use by pregnant women who have been reported to take many medications besides vitamin supplements or iron, despite a growing awareness of the need to avoid drugs (5,6).

As an allylamine that inhibits squalene epoxidase leading to intracellular accumulation of squalene, which is lethal to fungal cells, terbinafine represented a major advance in the therapy for onychomycosis owing to rapid eradication of difficult-to-kill organisms at much lower drug concentrations than other anti-fungal agents (7).

Terbinafine has not been reported with any teratogenic changes in rats or rabbits, however, to our knowledge, there are no studies available regarding its use in human pregnancy (8). It has been classified by the FDA as a pregnancy category B agent, which is less restrictive than the classification assigned to itraconazole (7) and is excreted in breast milk (9).

Terbinafine was first introduced in the UK in February 1991 and was approved for the treatment of onychomycosis in the US in May 1996 (3,8,9). Since then, terbinafine has been used widely for the effective treatment of superficial candidiasis (8,9). Owing to the presence of limited data on the adverse-effects profile of oral terbinafine in pregnancy (9), use of terbinafine during pregnancy has been suggested to be avoided (3). Since terbinafine has been known to distribute and also accumulate in nails, epidermis, dermis and adipose tissue, the present study was designed to investigate the possible teratogenic effects of prenatal terbinafine exposure in newborn rats in terms of macroscopic organ anomalies, anthropometric scales and abnormalities in skin development.

MATERIALS and METHODS

Animals

Adult Wistar-Albino female rats (250–300 g) were kept in a light and temperature-controlled room with 12:12-h light–dark cycles, where the temperature (22 ± 0.5 °C) and relative humidity (65–70%) were kept constant. The animals were fed with standard pellets.

Experimental Design

Based on available data concerning experimental use of terbinafine at the dose of 20–200 mg/kg in the literature (10,11), the rats were randomly divided into four groups; control (physiological saline, during 21 days of pregnancy; n=6), group A (terbinafine treatment, 20 mg/kg/day, during 21 days of pregnancy; n=6), group B (terbinafine treatment, 20 mg/kg/day, 30 days before and during 21 days of pregnancy; n=6) and group C (terbinafine treatment, 60 mg/kg/day, during 21 days of pregnancy; n=6). The present study aimed to determine the teratogenic effects of terbinafine having a risk of accumulation in the

human body as a result of 3-6 months of use prior to pregnancy (12).

On the day 30 of terbinafine administration for group B, each of the female rats in the experimental groups were housed in the same cage with a male partner for 11 hours (22:00 p.m.-09:00 a.m.) and presence of sperm in the vaginal smear was considered as a reliable indicator of mating, after which terbinafine was initiated. The number of overall newborn rat pups in the control, A, B and C groups were 51, 50, 45 and 42, respectively. Five rat pups from each experimental group were sacrificed by intracardiac infusion of 10% formalin, following length and weight measurements immediately after birth to determine the teratogenic effects of terbinafine. Skin biopsies were performed from the abdominal region and fixated in 10% formalin for 24 hours before tissue processing.

Histopathological Procedures

The study included formalin-fixed, paraffin wax embedded skin tissue samples from control and experimental groups. Routine paraffin wax embedding procedures were used. In brief, tissue samples were fixed in 10% formalin, dehydrated in a graded ethanol series, cleared in xylene, embedded in paraffin wax and 5 mm thick sections were cut. The tissue sections were stained with Haematoxylin and Eosin (H&E) for histological assessment under an Olympus BX 50 bright-field microscope (Olympus, Tokyo, Japan) and photographed using Kodak ISO 400 film.

Preparation of the Experimental Drug

Terbinafine-HCl solution (25 mg/ml) was freshly prepared by dissolution of 250 mg tablet form in 10 ml distilled water and given in 20 mg/kg and 60 mg/kg doses according to experimental groups.

Vaginal Smear Method

After 11 hours incubation with a common male partner, each pair of female rats was separated to

evaluate the presence of sperm in the vaginal smear as a reliable indicator of mating, after which terbinafine was initiated.

Statistical Analysis

Statistical analysis was made using SPSS statistical software (version 10.0, SPSS Inc. Chicago, IL). Experimental groups were compared statistically using Chi-square (χ^2), ANOVA, Kruskal-Wallis and post-hoc Tukey tests. Data were expressed as "mean \pm standard error of mean (SEM)" and percentage (%) where appropriate. Differences were considered statistically significant when $P < 0.05$.

RESULTS

Macroscopic Findings

Macroscopic observation of the rat pups did not reveal any gross anomaly development, and number of offspring was similar in experimental groups. In anthropometric scale analysis, there was a dose-dependent reduction in the length of newborn pups in groups A (37.27 \pm 3.36 mm), B (37.54 \pm 4.02 mm) and C (29.69 \pm 1.66 mm; $P < 0.001$; Table 1) when compared to rats in the control group (44.94 \pm 2.90 mm). Therefore, the length of rat pups in group C was significantly smaller than pups in the A and B groups ($P < 0.001$ for each; Table 1). When compared to rats in the control group (6.35 \pm 0.55 gr), there was a significant reduction in the weight of newborn pups in groups A (5.56 \pm 0.65 gr), B (5.14 \pm 0.63 gr) and C (3.25 \pm 0.43 gr; $P < 0.001$; Table 1). The most significant reduction in body weight was observed in group C ($P < 0.001$; Table 1).

Histopathological Findings

Histological analysis of abdominal skin samples revealed the normal epidermis and dermis layers of the skin in the control group. The epidermis was composed of stratified squamous epithelium and was seen in its normal thickness. The border between the epidermis and dermis was clearly

demarcated. The underlying papillary layer of the dermis had abundant capillaries and connective tissue cells, whereas the reticular layer of the dermis was composed of a denser connective tissue rich in collagen fibers (Fig 1a, b). Histological analysis of abdominal skin samples A revealed hyperkeratotic stratum corneum (Fig 1d) and atrophic epidermis with mild spongiosis in group A (Fig 1c, d) and marked hyperkeratosis and significant atrophy in the epidermis in group B (Fig 2a, b). Additionally, marked irregularity in the cell lineage and structural abnormalities in the hair follicles with

fibrotic tissue increase in the dermis and hair follicles were determined in group A and B (Fig 2a, b). In group C, there was marked hyperkeratosis, abnormal cell lineage and striking endometrial atrophy with structural abnormalities in the epidermal cells (Fig 2c). Hyperchromatic appearance of dysplastic epidermal cells with pronounced dysplasia and, structural abnormalities in the hair follicles with fibrotic tissue increase in the dermis and hair follicles were also determined in group C (Fig 2c, d)

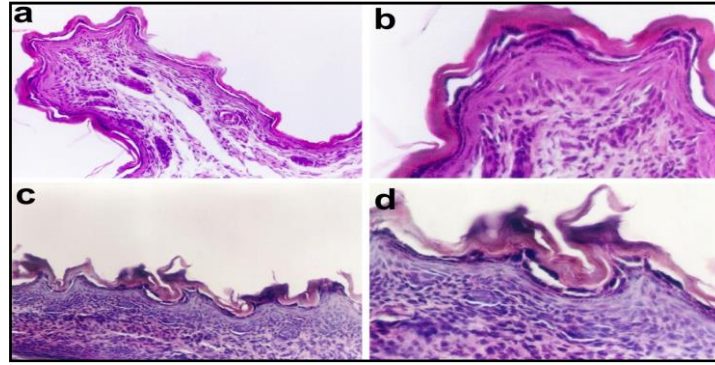


Figure 1. The normal epidermis and dermis appearance of skin sections of the control group (a, b) of subjects. Hyperkeratosis, variable epidermal atrophy and spongiotic appearance of the epidermis in group A (c, d) newborn pups (Dye: H-E, Mag.; a/c= X20; b/d=X40).

Şekil 1. Kontrol grubuna (a, b) ait deneklerin deri kesitlerinde normal epidermis ve dermin görünümü. Grup A (c, d) yenidoğan yavruların epidermisinde hiperkeratozis, değişen epidermal atrofi ve spongiyotik görünümü (Boya: H-E, Büy.; a/c= X20; b/d=X40).

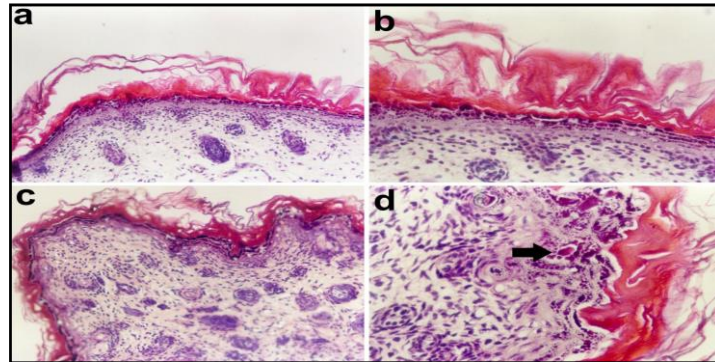


Figure 2. Marked hyperkeratosis, significant epidermal atrophy and structural deformity of hair follicles in group B (a, b) newborn pups. Marked hyperkeratosis and dysplastic epidermal cells (black arrow) in group C (c, d) newborn pups (Dye: H-E, Mag.; a/c= X20; b/d=X40).

Şekil 2. Grup B (a, b) yenidoğan yavrularda belirgin hiperkeratozis, anlamlı epidermal atrofi ve kıl foliküllerinin yapısal deformasyonu. Grup C (c, d) yenidoğan yavrularda belirgin hiperkeratozis ve displastik epidermal hücreler (siyah ok) (Boya: H-E, Büy.; a/c= X20; b/d=X40).

DISCUSSION and CONCLUSION

While it was documented to be associated with possible teratogenic effects in the literature (13), available data on the relation of systemic use of antifungal agents to teratogenicity are inconsistent. There is no evidence concerning potential teratogenicity of amphotericin B (14), while increase in malformation risk, spontaneous abortion, premature birth and low birth weight was reported for administration of itraconazole during pregnancy (15,16). However, there are reports concerning the safety of itraconazole during pregnancy (17) as well as teratogenicity of fluconazole in doses higher than 150 mg/day (14) in the literature.

Ketoconazole, flucytosine and griseofulvine were demonstrated as teratogenic and/or embryotoxic agents in the experimental studies (14,18,19). While the side effect profile of terbinafine is well known through clinical trials and post-marketing surveys, limited data exist related to use during pregnancy, as indicated by the FDA's classification of the drug as a pregnancy category B agent, which is less restrictive than the classification assigned to itraconazole (7,9) and is excreted in breast milk (9). According to our findings, terbinafine administration during the whole course of the pregnancy in rats was associated with histopathological developmental abnormalities in the skin of newborn pups in relation to dosage and amount of the exposure to the drug during fetal life.

Although there was no macroscopic malformation in newborn pups related to terbinafine use in pregnancy, significant reduction was observed in length and weight measurements of rat pups depending on the dosage and amount of prenatal exposure. Likewise, histopathological findings in our experimental groups indicate the dose and time dependent teratogenicity of terbinafine administration in rats. In fact, based on the low birth weight and length as well as alterations in the epidermal cells, prenatal long-term use of high dose terbinafine seems to

associate with intrauterine growth retardation in the newborn.

Antifungal drugs were reported to be fungistatic at low concentrations, but fungicidal with toxicity risk at higher concentrations (20). Accordingly the adverse effects of prenatal terbinafine treatment regarding anthropometric measurements as well as histopathological alterations in the skin were most significant in the case of the 60-mg/kg dose of the drug in our study.

Since administration of long-term antifungal therapy is essential to enabling a successful cure and prevention of future relapses, use of antifungal drugs during pregnancy is associated with an increased teratogenic potential of these agent on the fetus (21). In this regard, studies concerning possible teratogenic effects of antifungal drugs are essential.

Hyperkeratosis demonstrated in all of our experimental groups including prenatal terbinafine administration, has been considered as a well-known integumentary reaction of a fetus to foreign external agents administered during pregnancy (22-24). Furthermore, epidermal atrophy observed in all of the rat pups exposed to terbinafine in our study was also shown in experimental intrauterine growth retardation models in the skins of newborn rats (25). Indicating dose-dependent deterioration of skin development, damage to hair follicles was observed in groups B and C while appearance of hyperchromatic and dysplastic cells was specific to group C rats exposed to the highest dose (60 mg/kg) of terbinafine in our study.

Demonstration of disordered epidermal cell lineage in all terbinafine doses and appearance of hyperchromatic and dysplastic cells only in the highest dose of terbinafine show the pronounced deterioration in the epidermal cell growth. Terbinafine may also be assumed to have possible carcinogenic effects besides teratogenicity, based on the evidence of hyperchromatic and dysplastic cells. Damage to hair follicles on the other hand indicates the possible involvement of deeper layers

of the skin, especially with high doses and/or long-term terbinafine exposure in the prenatal life.

In conclusion, terbinafine administration was associated with growth retardation and integumentary abnormalities in newborn rats in relation to dosage and length of the exposure period during fetal life. While our findings concerning teratogenic effects of prenatal terbinafine administration on fetal skin tissue are compatible with distribution as well as accumulation properties of terbinafine in the body including nails, epidermis, dermis and adipose tissue; possible teratogenic effects of the drug on other fetal tissues remain to be uncovered by future studies.

REFERENCES

1. van Gelder MM., van Rooij IA., Miller RK., Zielhuis GA., de Jong-van den Berg LT., Roeleveld N., 2010. Teratogenic mechanisms of medical drugs. *Human Reproduction Update*, 16, 378-394.
2. DeVane L., Goetzel LM., Ramamoorthy S., 2011. Exposing fetal drug exposure. *Clinical Pharmacology & Therapeutics*, 89, 786-788.
3. Shehata HA., Nelson-Piercy C., 2000. Drugs to avoid in pregnancy. *Current Obstetrics & Gynaecology*, 10, 44-52.
4. Moore KL., Persaud TVN., Torchia MG., 2008. The developing human: clinically oriented embryology. 8th ed. 458-484, Saunders/Elsevier, Philadelphia.
5. Begg EJ., 2008. Prescribing in pregnancy and lactation. *British Journal of Clinical Pharmacology*, 65, 627-628.
6. Katic J., Fucic A., Gamulin M., 2010. Prenatal, early life, and childhood exposure to genotoxicants in the living environment. *Archives of Industrial Hygiene and Toxicology*, 61, 455-464.
7. Leyden J., 1998. Pharmacokinetics and pharmacology of terbinafine and itraconazole. *Journal of the American Academy of Dermatology*, 38, 42-47.
8. Suhonen R., Neuvonen PJ., 1997. The tolerability profile of terbinafine. *Reviews in Contemporary Pharmacotherapy*, 8, 373-386.
9. Gupta AK., Shear NH., 1997. Terbinafine: an update. *Journal of the American Academy of Dermatology*, 37, 979-988.
10. Maldonado RA., Molina J., Payares G., Urbina JA., 1993. Experimental chemotherapy with combinations of ergosterol biosynthesis inhibitors in murine models of Chagas' disease. *Antimicrobial Agents and Chemotherapy*, 37, 1353-1359.
11. Contini C., Colombo D., Cultrera R., Prini E., Sechi T., Angelici E., Canipari R., 1996. Employment of terbinafine against pneumocystis carinii infection in rat models. *British Journal of Dermatology*, 46, 30-32.
12. Bahadir S., Inaloz HS., Alpay K., Agaoglu C., Cimsit G., Parlat P., Tak H., 2000. Continuous terbinafine or pulse itraconazole: a comparative study on onychomycosis. *Journal of the European Academy of Dermatology and Venereology*, 14, 422-423.
13. Fletcher H., Williams NP., Nicholson A., Rainford L., Phillip H., East-Innis A., 2000. Systemic phaeohyphomycosis in pregnancy and the puerperium. *The West Indian Medical Journal*, 49, 79-82.
14. King CT., Rogers PD., Cleary JD., Chapman SW., 1998. Antifungal therapy during pregnancy. *Clinical Infectious Diseases*, 27, 1151-1160.
15. Bar-Oz B., Moretti ME., Mareels G., Van Tittelboom T., Koren G., 1999. Reporting bias in retrospective ascertainment of drug-induced embryopathy. *Lancet*, 13, 1700-1701.
16. Bar-Oz B., Moretti ME., Bishais R., Mareels G., Van Tittelboom T., Verspeelt J., Koren G., 2000. Pregnancy outcome after in utero exposure to itraconazole: a prospective cohort study. *American Journal of Obstetrics and Gynecology*, 183, 617-620.
17. De Santis M., Di Gianantonio E., Cesari E., Ambrosini G., Straface G., Clementi M., 2009.

- First-trimester itraconazole exposure and pregnancy outcome a prospective cohort study of women contacting teratology information services in Italy. *Drug Safety*, 32, 239-244.
18. Czeizel AE., Metneki J., Kazy Z., Puho E., 2004. A population-based case-control study of oral griseofulvin treatment during pregnancy. *Acta Obstetrica et Gynecologica Scandinavica*, 83, 827-831.
 19. Moudgal W., Sobel JD., 2003. Antifungal drugs in pregnancy: a review. *Expert Opinion on Drug Safety*, 2, 475-483.
 20. Mesaik MA., Khan KM., Rahat S., Choudhary MI., Murad S., Abdullah NR., Ahmad A., Siddiqui RA., 2005. Immunomodulatory properties of synthetic imidazolone derivatives. *Letters in Drug Design & Discovery*, 2, 490-496.
 21. Rubin PC., 1986. Prescribing in pregnancy; General principles. *British Medical Journal*, 293, 1415-1417.
 22. Deveci E., Inaloz SS., Inaloz HS., 1998. Teratogenic effects of cadmium on rat skin. *Acta Dermatologica-Kyoto*, 93, 155-159.
 23. Inaloz HS., Ketani MA., Inaloz SS., Yilmaz F., Ketani S., 2000a. The effects of sialoadenectomy and flutamide on skin development. *Clinical and Experimental Obstetrics & Gynecology*, 26, 231-234.
 24. Inaloz HS., Inaloz SS., Deveci E., Eralp A., 2000b. Teratogenic effects of nicotine on rat skin. *Clinical and Experimental Obstetrics and Gynecology*, 26, 241-243.
 25. Inaloz HS., Sari I., Inaloz SS., Bayhan G., Unal B., Yayla M., Eralp A., Yuncu M., 2000c. The effects of unilateral uterine artery ligation on skin development. *Clinical and Experimental Obstetrics & Gynecology*, 26, 218-220.