

A Novel Paraflex-Softbox Setup for Standardized Anterior and Posterior Intraoral Photography

Anterior ve Posterior Standardize İntraoral Fotoğrafıama için Yeni Bir Paraflex/Softbox Düzenegi

Bora KORKUT¹, Ibrahim OGRAK¹, Özgür Yıldırım TORUN², Javier Tapia GUADIX³

ABSTRACT

Objective: The main limitation of intraoral dental photography is the standardization of the repetitive dental images. The parameters affecting the standardization can be divided into 3 groups such as; parameters related to the camera settings, parameters related to the flashlight, and parameters related to the shooting position. The parameters related to the camera settings are exposure [the combination of the lens aperture (f-stop) and the shutter speed], the sensitivity of the media (ISO), and white balance (WB), which may affect the brightness, sharpness, and depth of field of the dental image. The parameters related to the illumination are the power output of the light source, softboxes/diffusers, the distance of the light source, and the distance and angulation between the dual flashlights. The parameters related to the shooting position are the position of the dental unit and the clinician/camera which define the working distance. Among these, the clinician should standardize as many parameters as he/she can to provide accurate and precise repetitive intraoral dental images. This paper suggests two novel paraflex/softbox setups to provide the standardized intraoral photography of both anterior/posterior teeth and the occlusal surfaces at the same time, clinically.

Clinical Technique: The positions of dental unit and head support should be fixed. The first setup involves 3 paraflexes/softboxes fixed vertically and horizontally above the dental unit symmetrically at 45° of inclination. Two are positioned for introvert angulation and one should be placed right above the dental unit between the other two with a slight inclination towards the patient's head. The second setup involves only 2 paraflexes/softboxes fixed vertically at 45° of inclination above the dental unit and with the ability of horizontally re-positioning easily. Through these setups, the clinician can take both anterior and posterior repetitive intraoral dental photographs by minimizing the

major parameters related to the camera settings, illumination, and shooting position.

Keywords: Dental photography, paraflex, softbox, occlusal photography, standardization

ÖZET

Amaç: Ağız içi dental fotoğrafçılıkta ana limitasyon tekrarlayan fotoğraflardaki standardizasyonun sağlanmasıdır. Standardizasyonu etkileyen parametreler temel olarak üç grupta incelenebilir. Bunlar kamera ayarları ile ilgili parametreler, flaş ışıkları ile ilgili parametre ve çekim pozisyonu ile ilgili parametrelerdir. Kamera ayarları ile ilgili olanlar dental fotoğrafın alan derinliğini, keskinliğini ve aydınlığını etkileyebilen pozlama (objektif açıklığı ve deklanşör hızının birleşimi), ortam hassasiyeti (ISO) ve beyaz dengesi (WB) olarak sayılabilir. Flaş ışıkları ile ilgili olanlar ışık kaynağının çıkış gücü, softbox veya yansıtıcılar ve dual ışık kaynaklarının uzaklığı ve açılmasıdır. Çekim pozisyonu ile ilgili olanlar ise çalışma uzaklığını belirleyen dental koltuğun ve klinisyenin/kameranın pozisyonudur. Tekrarlayan intraoral dental fotoğraflarda kesin ve doğru çekimler için klinisyen bahsi geçen birçok parametreyi standardize ederek çekim yapılmalıdır. Bu yayın anterior/posterior dişler ve okluzal yüzeylerden standardize intraoral fotoğraflar çekilebilmesi için iki yeni klinik paraflex/softbox düzeneği önermektedir.

Klinik Teknik: Dental koltuk ve tetiyer pozisyonları sabitlenmiş olmalıdır. İlk düzenek dental koltuk üzerinde dikey ve yatay olarak 45° açı ile simetrik şekilde konumlandırılmış 3 adet paraflex/softbox içermektedir. Flaşlardan iki tanesi içe doğru açılmış şekilde ve bir tanesi koltuğun tam üzerinde, iki simetrik flaşın tam ortasında ve hasta başına hafifçe açılmış olarak konumlandırılmaktadır. İkinci düzenek dental koltuk üzerinde dikey olarak 45° açı ile konumlandırılmış yalnızca iki adet paraflex/softbox içermektedir. Bu düzenekteki iki flaş yatay düzlemde açıları değiştirilmeden kolayca yeniden pozisyonlandırılabilir. Bu yeni düzenekler sayesinde klinisyen tekrar eden anterior ve posterior intraoral fotoğrafları kamera ayarları, aydınlatma ve çekim pozisyonları ile ilgili parametreleri minimize ederek çekebilecektir.

Anahtar kelimeler: Dental fotoğrafçılık, paraflex, softbox, okluzal fotoğraf, standardizasyon

Bora KORKUT (✉)

Assoc. Prof. Dr., Department of Restorative Dentistry, Faculty of Dentistry, Marmara University, Istanbul, Turkey. E-mail: bora.korkut@marmara.edu.tr

İbrahim OGRAK

Private Practice, Ankara, Turkey

Özgür Yıldırım TORUN

Private Practice, Ankara, Turkey.

Javier Tapia GUADIX

Private Practice, Madrid, Spain.

Submitted / Gönderilme: 25.09.2023

Accepted/Kabul: 11.12.2023

INTRODUCTION

Dental photography is not an option but a must for clinical practice today. Intra-oral and extra-oral dental records are essential for patient persuasion, digital treatment planning, provisional outcome simulations, restorative material shade selection, technician communication, and even legal issues (Korkut B, 2022; Hardan et al., 2022; Korkut et al., 2022). Regarding restorative dentistry, dental photography is a common diagnostic tool for dental conditions such as tooth decay, tooth wear, dental trauma, and for the evaluation of dental restorations (Signori et al., 2018). Also intraoral photography can be used to perform quantitative or qualitative scoring for purpose-made indices such as pink esthetic score white esthetic score, papilla index, etc.) (Bertl et al., 2019).

The follow-up records are important to assess the success rate of a restoration in terms of restorative dentistry. However, the main limitation is the standardization of the repetitive dental images (Korkut B, 2022; Korkut et al., 2022; Jackson et al., 2019). There are several parameters affecting the standardization of dental photography (Snow, 2009). These parameters can be divided into 3 groups according to the major influencing factor such as; parameters related to the camera settings, parameters related to the illumination, and parameters related to the shooting position (Galdino et al., 2001).

Standardization parameters for intra-oral photography

1. Parameters related to the camera settings

Shooting parameters related to the selected camera are an important factor that may affect mainly the brightness, sharpness, and depth of field of the dental image. The major parameters are exposure, sensitivity of the media (ISO), and white balance (WB). The exposure is the combination of the lens aperture opening (f-stop) and the shutter speed and is influenced by the ISO and the distance of the camera to the subject (Korkut B, 2022; Snow, 2009).

The lens aperture determines the depth of field (focus range from front to back) and also the intensity of the light (Ahmad, 2009; Moussa et al., 2021). The aperture size is defined as the f-stop numbers at the camera settings (the larger the number is, the smaller the aperture will be) (Snow, 2009). In terms of intra-oral dental photography, to increase the depth of field, the lens aperture opening should be set as small as possible depending on the selected macro objective

(the range is up to f18 – f64) (Terry & Snow, 2008). Once this parameter is set, it can be standardized that there will be no need to change it unless the camera and flashlight setups change. For better image quality with an acceptable depth of field, it is recommended to adjust the aperture between f22-f32. However, it is important to take into consideration that small aperture openings will lead to a decrease in the brightness of the images. If the aperture is smaller than f22, the depth of field and the image clarity may also be seriously diminished (Korkut B, 2022; Ahmad, 2009).

The duration of the light is guided by the shutter speed which is the length of time that the shutter remains open during the shooting (Snow, 2009). It is expressed in fractions of seconds such as 1/125s 1/250s (Korkut et al., 2022). In terms of intra-oral dental photography, the shutter speed can be set at 1/125 as a standard for both anterior and posterior/occlusal shootings (Korkut B, 2022; Ahmad, 2020).

The ISO is a camera setting that determines the camera sensor sensitivity and therefore the image quality by providing or eliminating the unwanted speckled artifacts known as noise or grain on the dental image (Snow, 2009). ISO can be considered a stabilizer to the lens aperture in terms of the image brightness. If the ISO increases, the brightness increases. A constant ISO value of 200 is often ideal for intraoral purposes (Snow, 2009). However, the top limit should be ISO:400 to avoid noise regarding the cameras with the mirror (Korkut B, 2022). Whereas, the mirrorless cameras have the advantage of letting the ISO increase to 6400 without providing noise. Nevertheless, setting the ISO at a number in a range of 100-400 depending on the aperture setting can standardize the repetitive intra-oral photography unless the camera and flashlight setups change (Korkut B, 2022).

The WB is one of these parameters that should be calibrated to equalize the temperatures of the repetitive images (Snow, 2009). It can be performed either through the camera settings depending on the camera model or even by using a grey calibration card (%18) during the shooting (Snow, 2009; Ahmad, 2009).

Therefore, the parameters regarding the camera settings can be standardized for the selected dental photography kit, and once they are set there will be usually no need to change them if the parameters related to the illumination and the shooting position are also standardized.

2. Parameters related to the illumination

Illumination is the most important variable in dental photography which is provided particularly by the flash lights (Korkut B, 2022). The type of the flashlight (ring flash, dual flash, or paraflash), the power output of the selected light source, the use of softboxes/diffusers, the distance of the light source to the teeth, and the distance and angulation between the dual flashlights may influence the quality of illumination on the teeth to be captured. Additionally, the position of the patient's head may also affect the illumination and thereby the final outcome (Korkut B, 2022).

Many of these parameters can be calibrated for intraoral photography. The angulation of the twin flashes of paraflashes should be placed away from the objective at an angulation of approximately 45° for the anterior photography to obtain light reflections at the transition lines (Hardan et al., 2022). But they should be placed very close to the objective for the posterior/occlusal photography to obtain good illumination. A mounting bracket such as the Owlbrckt (Torun & Torun Ağız ve Diş Sağlığı Hiz. Ltd. Şti., Ankara, Turkey) is very useful for the standardized placement of the dual flashes (Ahmad, 2009). Regarding the paraflash use, two paraflashes should be placed at an angulation of approximately 45° for the anterior photography.

The level of softness of the light also influences the quality of the photograph (Korkut B, 2022). Intraoral photography involves not only white teeth but also surrounding pink soft tissues like gingiva. Accordingly, soft illumination may provide better visuality, especially for soft tissues, which can be provided by using auxiliary photography equipment such as diffusers, reflectors, or softboxes (Korkut B, 2022). Whereas, it is a well-known fact that the use of paraflashes / softboxes may be less informative in terms of the dental surface structures, compared to the battery-powered ring flashes and dual flashes (Korkut et al., 2022). The complications related to the restorations or the pathologies related to the natural dental tissues may not be visible through intraoral photography due to the highly diffuse paraflash illuminations, which may lead to clinical misinterpretations (Korkut et al., 2022). However, this issue usually depends on the brand and power output of the selected paraflashes. It is suggested to use 300-watt paraflashes at full power and 400-500-watt paraflashes at less than full power to avoid high light diffusion on the tooth surface for more informative intraoral photography. Some examples of such paraflashes in the market used for dental photography are VL 400 Plus Elfin (Visico, Zhejiang, China) and SK300 II (Godox, Shenzhen, China), and

HiMax 500 (Hensel, Germany). However, using the HiMax 500 paraflashes / softboxes for intraoral dental photography may also inhibit the information on dental surface structures due to the high diffusion of the light depending on the flash power output and the camera settings (Korkut B, 2022). Therefore, it is very important to calibrate and standardize the parameters related to the illumination at maximum level to provide repetitive intraoral photographs.

In terms of the paraflash use, the size of the softbox is not an influencing factor for intraoral photography, due to the small size of the oral cavity. Therefore, the use of softboxes of 80x100, 60x90, or 50x70 are all considered indicated (Korkut B, 2022).

3. Parameters related to the shooting position

Taking photographs at different shooting angles bears a high risk of inconsistencies in the perception of reality due to potential distortions (Bertl et al., 2019). Positioning devices for intra-oral photography, pre-fabricated splints, and photography guides have been used previously to perform standardized intraoral anterior photography. However, such methods were considered quite complicated, and also their effectiveness has not been assessed (Bertl et al., 2019).

There are shooting parameters related to the position of the dental unit and the position of the clinician as well as the camera, which can alter the working distance (Snow, 2009). The angulation and height of the dental unit may affect not only the shooting distance but also the distance to the light source. This parameter can be standardized by setting the dental unit at a constant position for every kind of intraoral photography (anterior and posterior/occlusal) (Korkut B, 2022). The positioning of the clinician/camera is more complicated. Although the use of a mounting bracket can standardize the placement of the dual flashes, the position of the clinician is still an effective variable as the camera and the flashes are held by him/her. Therefore, to achieve a constant working distance, the objective should be set at manual focus mode and the clinician manually select a specific and consistent magnification ratio for each repetitive shooting (Snow, 2009; Ahmad, 2020). Whereas, using the constantly placed proper paraflashes / softboxes at 45° over the patient's head may also overcome almost all the standardization problems regarding the flashlights (Korkut B, 2022). The wall mounts can be effectively used with the paraflashes/softboxes in this regard clinically.

The paraflashes / softboxes have gained a wide range of use for anterior intraoral photography, besides the extraoral

portrait photography, due to the simplicity of the system and the effectiveness of the soft light illumination. Whereas, the paraflashes / softboxes have had a limited indication for the intraoral photography of the posterior dentition and the occlusal surfaces due to the insufficient illumination of the operating field. There must be an easy way to perform standard everyday clinical documentation by free-hand shooting, for the anterior and also the posterior dentition.

The suggested intraoral photography setups may provide the standardization in intraoral photography of both anterior/posterior dentition and the occlusal surfaces at the same time clinically. Two different paraflashes / softboxes placement options are recommended above the dental unit; (1) three paraflashes are placed constantly, (2) two paraflashes are placed with the ability of simple repositioning (Fig. 1 and Fig. 2 a,b). Therefore, from now on the paraflashes softboxes can be considered indicated for also the posterior/occlusal intraoral photography through the suggested following simplified setups.



Figure 1: Recommended setup no 1 including 3 paraflashes at fixed positions above the dental unit.

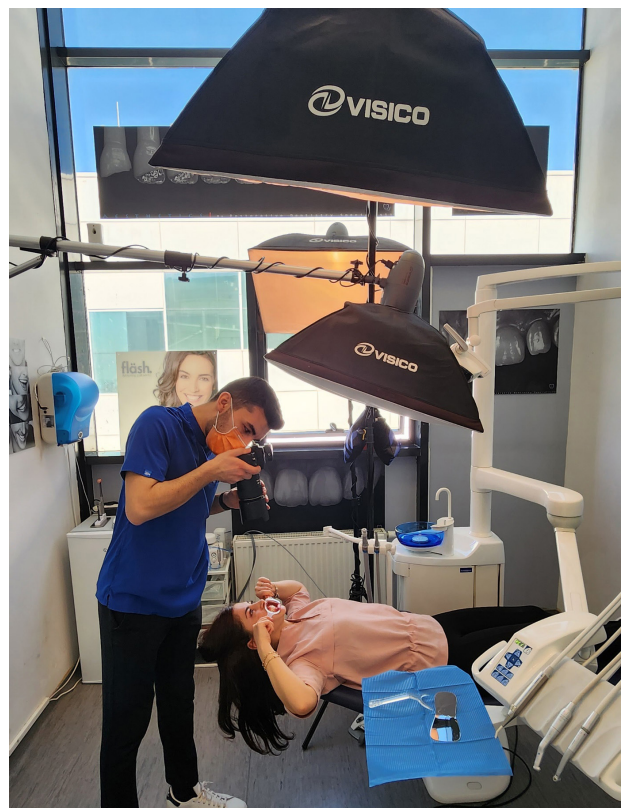

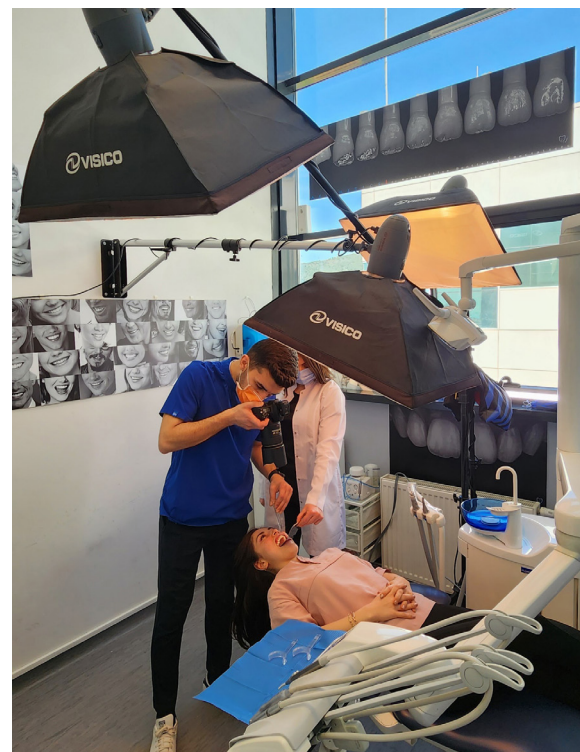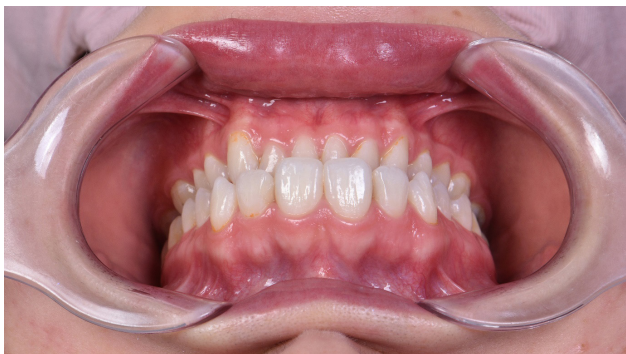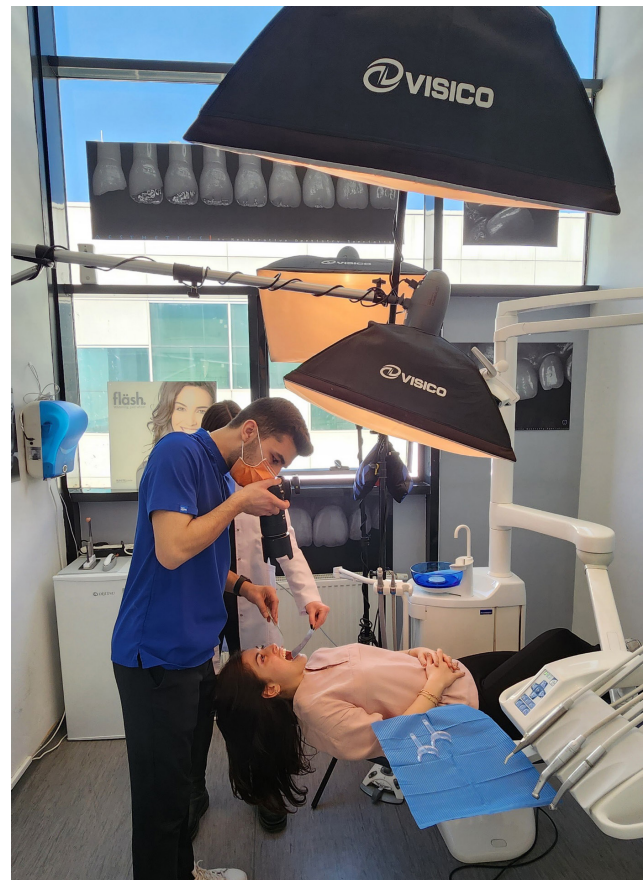Figure 2: Recommended setup no 2 including only 2 paraflashes above the dental unit with the ability of simple repositioning. (a) Placement for the paraflashes for the anterior photography. (b) Placement for the paraflashes for the posterior / occlusal photography.

Recommended clinical setup no 1 for anterior and posterior/occlusal intraoral photography

This setup involves 3 paraflashes with 50x70 softboxes which are vertically and horizontally fixed at approximately 2 meters above the dental unit. Two should be positioned symmetrically in 45° of introvert angulation and one should be placed right above the dental unit, between the other two, with a slight inclination towards the patient's head. The positions of the dental unit and head support should be fixed (Desai & Bumb, 2013).

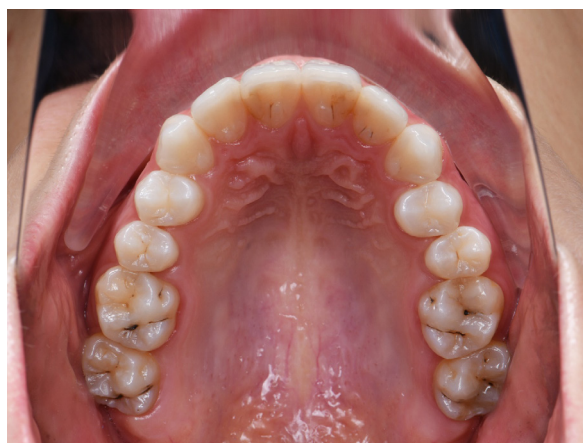Regarding the frontal photography of the anterior incisors and canines, only two symmetrical paraflashes should be operational and the one in the middle should be turned off. The clinician should stand at the 12 o'clock position. A direct photograph is taken by using two separate transparent lip retractors (Fig. 3 a-c).





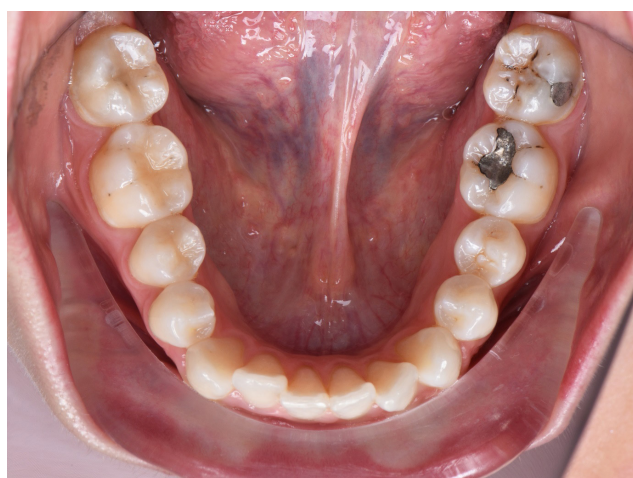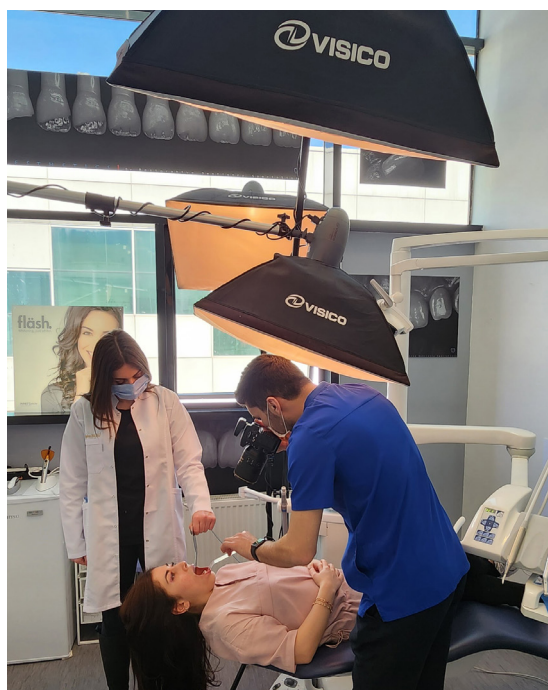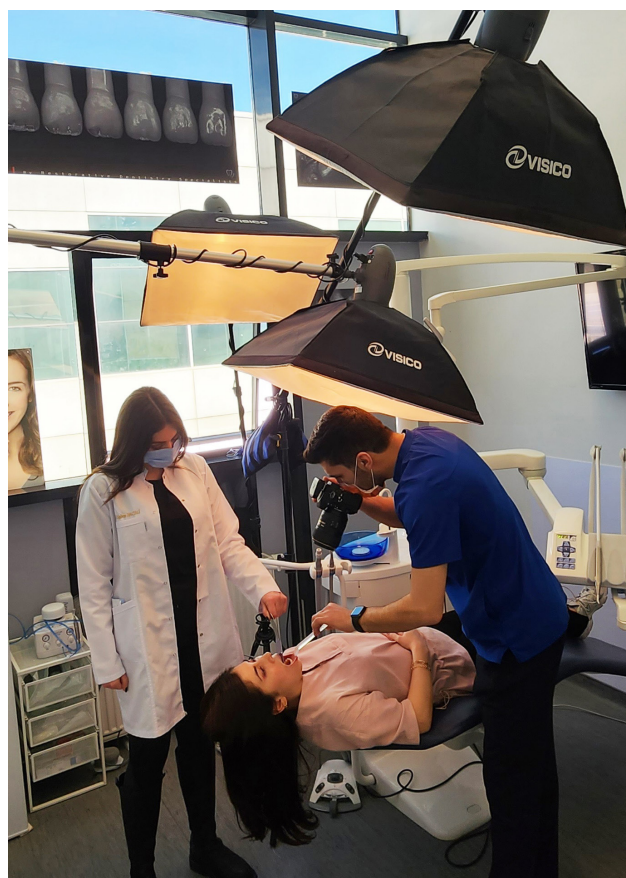Figures 3: (a) Standardized intraoral photography of anterior dentition with (3 paraflash setup / direct shooting). Only two symmetrical paraflashes are operational at 45° of angulation. The position of the dental unit and head support should be fixed. (b) Shooting should be performed at 12 o'clock position. The dental assistant is not required. (c) Intraoral frontal photography of anterior dentition.

Regarding the photography of the maxillary posterior dentition and occlusal surfaces, all three paraflashes should be operational. The clinician should stand at 12 o'clock position. An indirect photograph is taken by using an occlusal intraoral mirror and a C-shape transparent lip retractor (Fig. 4 a-c) (McLaren & Terry, 2001).



Figures 4: (a) Standardized intraoral photography of maxillary posterior dentition / occlusal surfaces (3 parafash setup / indirect shooting by using an occlusal mirror). Third parafash is turned on and all three parafashes are operational. The position of the dental unit and head support should be fixed. (b) Shooting should be performed at 12 o'clock position. The dental assistant is required (Korkut B, 2022). (c) Intraoral occlusal photography of maxillary dentition.

Regarding the photography of the mandibular posterior dentition and occlusal surfaces, all three parafashes should be operational. The clinician should stand on one side of the patient. An indirect photograph is taken by using an occlusal intraoral mirror and a C-shape transparent lip retractor (Fig. 5 a-c).

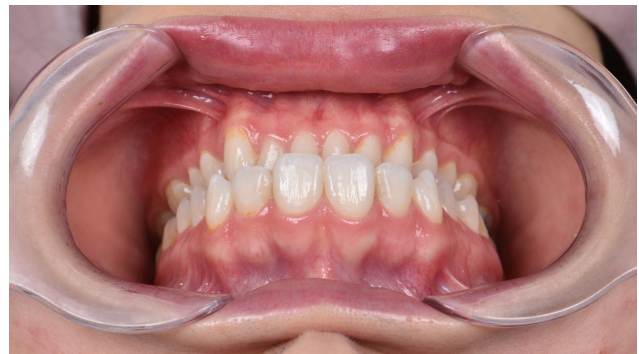
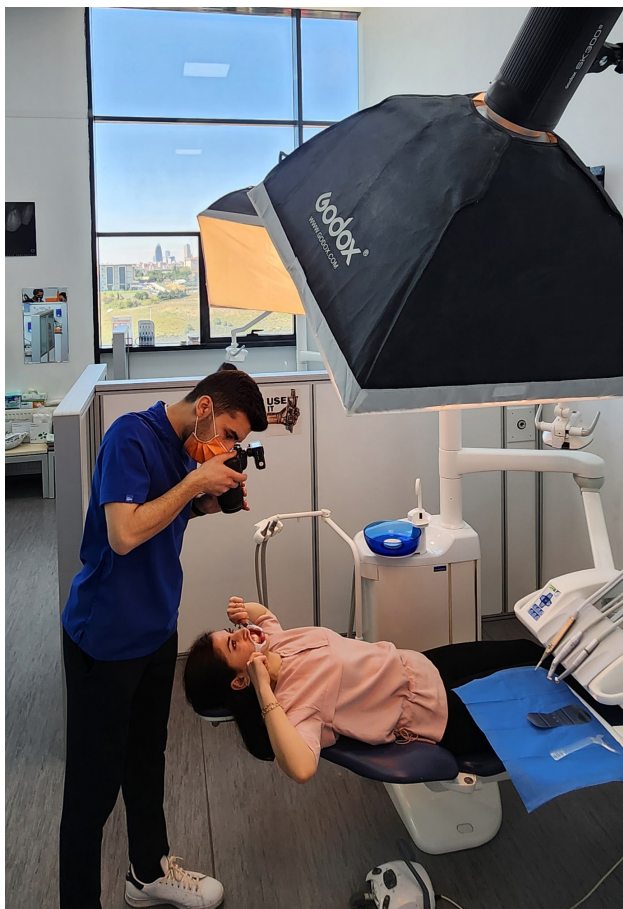
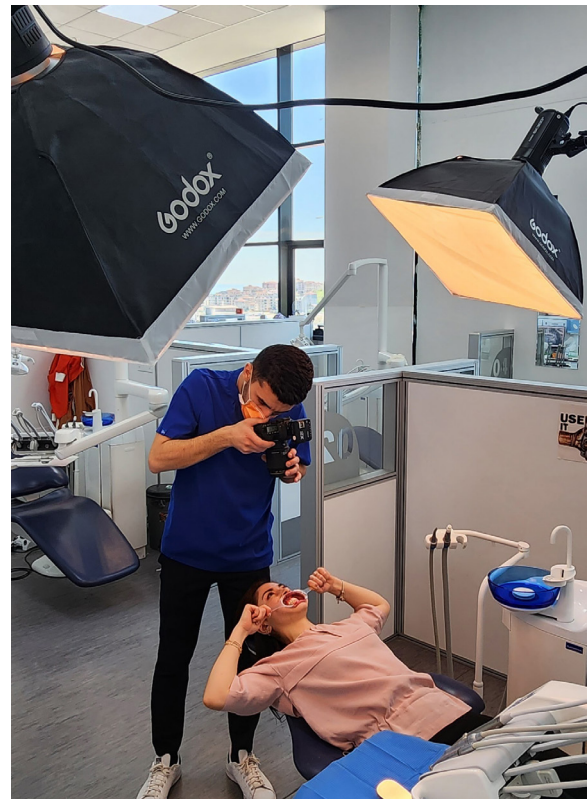Figures 5: (a) Standardized intraoral photography of mandibular posterior dentition / occlusal surfaces (3 parafash setup / indirect shooting by using an occlusal mirror). The third parafash is turned on and all three parafashes are operational. (b) Shooting should be performed at the side of the patient. The position of the dental unit and head support should be fixed. The dental assistant is required. (c) Intraoral occlusal photography of mandibular dentition.

Recommended clinical setup no 2 for anterior and posterior/occlusal intraoral photography

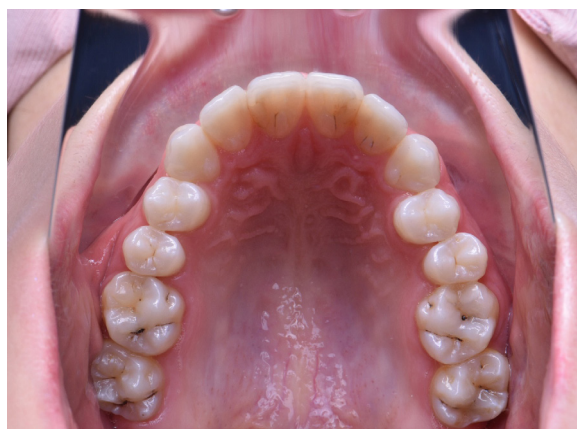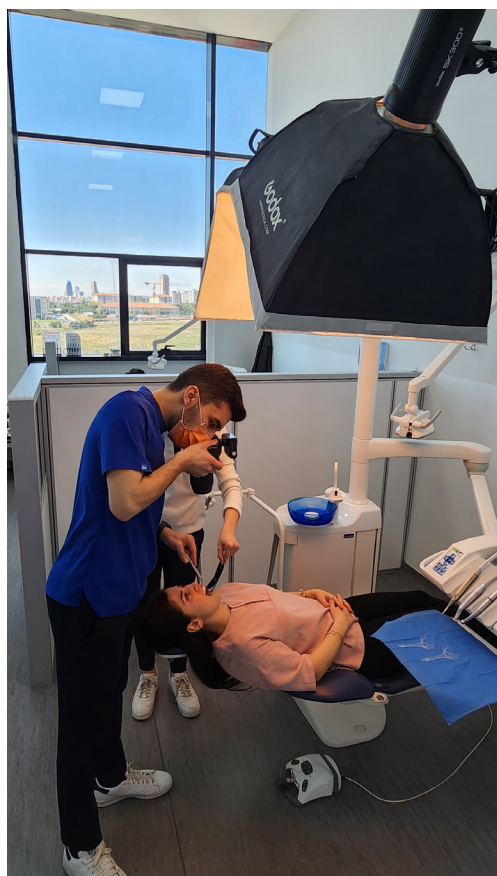This setup involves only 2 paraflashes with 50x70 softboxes which are fixed vertically at approximately 2 meters above the dental unit with symmetrically introvert angulation of 45°. However, the paraflashes can be repositioned horizontally, but not fixed in position. The ability of the horizontal movement is required for shooting both anterior and posterior intraoral photographs. The dental unit's and head support's positions should be fixed.

Regarding the frontal photography of the anterior incisors and canines. The two symmetrical paraflashes should be positioned apart from each other at approximately 1.5 m of distance on both sides. During the repositioning, the vertical height and the introvert angulation of the paraflashes should remain stable. The clinician should stand at the 12 o'clock position. A direct photograph is taken by using two separate transparent lip retractors (Fig. 6 a-c).



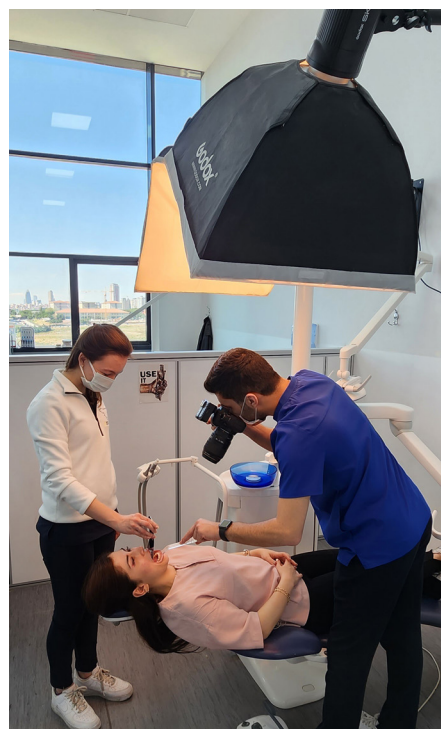Figures 6: (a) Standardized intraoral photography of anterior dentition (2 paraflash setup / direct shooting). Both symmetrically positioned paraflashes are operational at 45° of introvert angulation. The position of the dental unit and head support should be fixed. (b) Shooting should be performed at 12 o'clock position. The dental assistant is not required. (c) Intraoral frontal photography of anterior dentition.

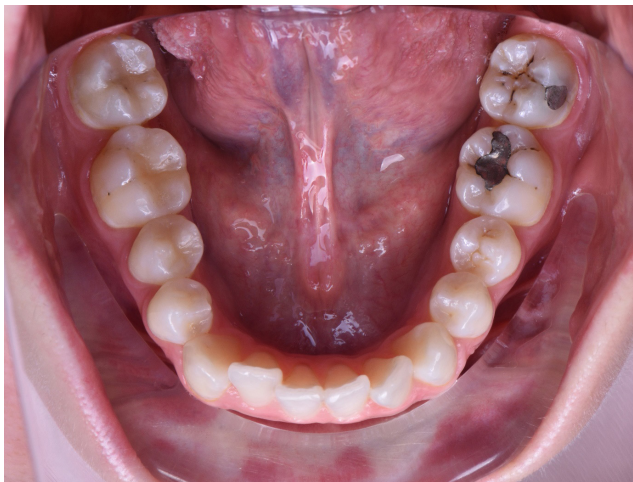
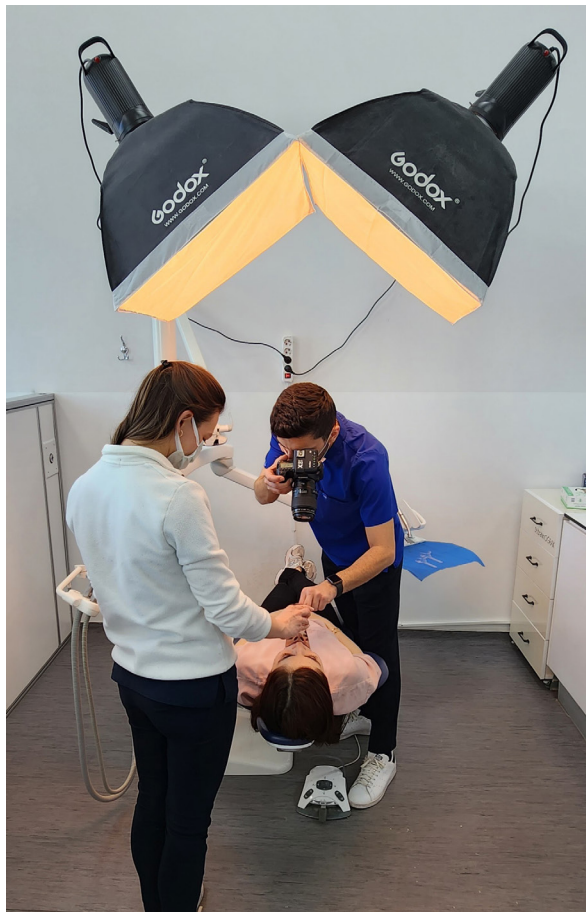Regarding the photography of the maxillary posterior dentition and occlusal surfaces, the two symmetrical paraflashes should be transferred horizontally to the middle forming a tent-shape, right above the patient's head. During the repositioning, the vertical height of the paraflashes remains stable. The clinician should stand at the 12 o'clock position. An indirect photograph is taken by using an occlusal intraoral mirror and a C-shape transparent lip retractor (Fig. 7 a-c).



Figures 7: (a) Standardized intraoral photography of maxillary posterior dentition / occlusal surfaces (2 paraflex setup / indirect shooting by using an occlusal mirror). Both symmetrically positioned paraflexes are operational at 45° of introvert angulation. The position of the dental unit and head support should be fixed. (b) Shooting should be performed at 12 o'clock position. The dental assistant is required. (c) Intraoral occlusal photography of maxillary dentition.

Regarding the photography of the mandibular posterior dentition and occlusal surfaces, the two symmetrical paraflexes should be transferred horizontally to the middle forming a tent-shape, right above the patient's head. During the repositioning, the vertical height of the paraflexes remains stable. The clinician should stand on one side of the patient. An indirect photograph is taken by using an occlusal intraoral mirror and a C-shape transparent lip retractor (Fig. 8 a-c).





Figures 8: (a) Standardized intraoral photography of mandibular posterior dentition / occlusal surfaces (2 paraflash setup / indirect shooting by using an occlusal mirror). Both symmetrically positioned paraflashes are operational at 45° of introvert angulation. The position of the dental unit and head support should be fixed. (b) Shooting should be performed at the side of the patient. The dental assistant is required. (c) Intraoral occlusal photography of mandibular dentition.

CONCLUSION

This paper recommends contemporary, simplified clinical paraflash / softbox setups for both anterior and posterior intraoral photography for the first time. Standardization in intraoral dental photography for both anterior/posterior dentition and the occlusal surfaces can be enhanced by using one of the suggested setups for everyday clinical documentation.

REFERENCES

1. Ahmad I. Digital dental photography. Part 6: camera settings. *British Dent J.* 2009;207(2):63-69.
2. Ahmad I. Standardization for Dental Photography-PART 2. *J Cosmet Dent.* 2020;36(3):44-63.
3. Bertl K, Bertl MH, Gotfredsen K, Heimel P, Lettner S, Bertl W, Stavropoulos A. Reproducibility of intraoral photography for pink and white tissue assessment—Is it worth the hassle?. *J Prosthodont Res.* 2019;63(4):404-410.
4. Desai V, Bumb D. Digital dental photography: a contemporary revolution. *Int J Clin Pediatr Dent.* 2013;6(3):193-196.
5. Galdino GM, Vogel JE, Vander Kolk CA. Standardizing digital photography: it's not all in the eye of the beholder. *Plastic Reconstr Surg.* 2001;108(5):1334-1344. Beholder. *Plast. Reconstr. Surg.* 2001;108(5):1334-1344.
6. Hardan L, Bourgi R, Cuevas-Suárez CE, Lukomska-Szymanska M, Monjarás-Ávila AJ, Zarow M, Haikel Y. Novel trends in dental color match using different shade selection methods: a systematic review and meta-analysis. *Mater.* 2022;15(2):468.
7. Jackson TH, Kirk CJ, Phillips C, Koroluk LD. Diagnostic accuracy of intraoral photographic orthodontic records. *J Esthet Restor Dent.* 2019;31(1):64-71.
8. Korkut B. Anterior estetikte rezin kompozit restorasyonlar In: Kulak Özkan Y, Aslan U. *Diş Hekimliğinde Kullanılan Fotoğraf Ekipmanları ve Kullanım Teknikleri*, Quintessence Publishing Türkiye, 2022.p.98-114.
9. Korkut B, Dokumacıgil G, Murat N, Atali PY, Tarcin B, Gocmen GB. Effect of polymerization on the color of resin composites. *Oper Dent.* 2022;47(5):514-526.
10. McLaren EA, Terry DA. Photography in dentistry. *J California Dent Assoc.* 2001;29(10):735-741.
11. Moussa C, Hardan L, Kassis C, Bourgi R, Devoto W, Jorquera G, Lukomska-Szymanska M. Accuracy of Dental Photography: Professional vs. Smartphone's Camera. *Biomed Res. Int.* 2021;3910291:1-7.
12. Signori C, Collares K, Cumerlato CB, Correa MB, Opdam NJ, Cenci MS. Validation of assessment of intraoral digital photography for evaluation of dental restorations in clinical research. *J Dent.* 2018;71:54-60.
13. Snow SR. Dental photography systems: required features for equipment selection. *Compen Contin Edu Dent.* 2005;26(5):309-310.

14. Snow SR. Assessing and achieving accuracy in digital dental photography. *J California Dent Assoc.* 2009;37(3):185-191.
15. Terry DA, Snow SR, McLaren EA. Contemporary dental photography: selection and application. *Compend Contin Educ Dent.* 2008;29(8):432-436, 438, 440-442.