

# Compressive external bracing in pectus carinatum : Results of the first 100 patients

Nezih Onur ERMERAK 

Department of Throacic Surgery, School of Medicine, Marmara University, Istanbul, Turkey

**Corresponding Author:** Nezih Onur ERMERAK

**E-mail:** onur.ermerek@marmara.edu.tr

**Submitted:** 19.08.2023

**Accepted:** 01.09.2023

## ABSTRACT

**Objective:** Pectus carinatum is the second most common chest wall deformity causing psychological problems. There has been a growing interest in the conservative treatment of the disease in recent years. Here, we present results of the first 100 patients who were treated with compressive external bracing therapy.

**Patients and Methods:** A total of one hundred patients who were treated with compressive external bracing between 2017-2023 were reviewed from database. Parameters recorded include demographics, type of the deformity, duration of the treatment time, complications, and patient satisfaction.

**Results:** Among 100 patients 88 were male (88%) and 12 were female (12%) and the mean age was 13.3 years (3-19). 76 patients (76%) had a symmetric pectus carinatum and 24 patients (24%) had asymmetric. 23 (23%) patients had scoliosis, 9 (9%) had kyphosis, 1 (1%) had Poland Syndrome and 1 (1%) patient had Marfan Syndrome as accompanying anomalies. Quality of Life Questionnaire revealed 94.8 % satisfaction in patients who completed the treatment.

**Conclusion:** Compressive external bracing is associated with satisfactory results in the treatment of pectus carinatum. This non-surgical intervention enables us to treat more patients in younger ages with lesser comorbidity than surgical intervention.

**Keywords :** Pectus carinatum, Chest wall deformities, Pectus excavatum, Orthosis, Compressive external bracing

## 1. INTRODUCTION

Pectus carinatum (PC) or pigeon chest deformity is characterized by convex protrusion of anterior chest wall along with costal cartilages and sternum [1-3]. It is the second most common chest wall deformity following pectus excavatum (PE) [4,5]. The prevalence of the deformity is between 0.3%-0.7% with a male predominancy [6]. Although, it is less common than PE, it is harder for patients to cover it with clothes and accessories. Etiology of the deformity is unclear, but it is very likely to have a genetic inheritance by having 25% positive family history of the patients [7]. PC becomes prominent with puberty and causes cosmetic and psychosocial problems [8,9]. Although, there are studies investigating the cardiopulmonary impact of the deformity on these patients, no affect has been detected so far [10]. Therefore, patients with PC mainly suffer from cosmetic issues, resulting in a reduced self-image and a lower quality of life compared with control patients without this deformity. Until

recently, the mainstay of treatment for PC has been surgical. The most well-known technique is the Ravitch procedure and its modifications, consisting of subperichondreal resection of cartilage and reconstruction of the sternum [11]. A more recent surgical technique for the correction of PC is the Abramson procedure in which a steel bar is placed subcutaneously over the sternum for correction [12]. Abramson procedure has gained popularity in the last decade as being minimally invasive. Although, non-surgical brace treatment has been applied to the patients since 1970s, results were unsatisfactory due to compliance and technical problems until last decade. Similar results with surgical treatment options have been reported after the improvement of compressive external bracing (CEB) in the last decade. There has been guidelines and treatment algorithms reported according to the flexibility of the chest wall. Here,

**How to cite this article:** Ermerak ON. Compressive external bracing in pectus carinatum : Results of the first 100 patients. Marmara Med J 2023; 36(3):334-338. doi: 10.5472/marumj.1367999

we report our experience with the first 100 patients who were treated with CEB.

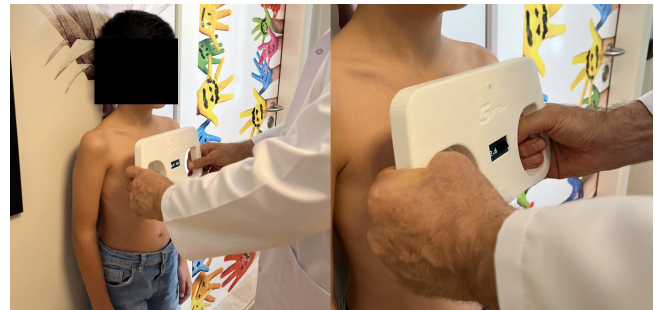## 2. PATIENTS and METHODS

One hundred patients who were treated with CEB between January 2017 and June 2023 were reviewed retrospectively from database. All data regarding pressure for initial correction (PIC) measurement, demographics, type of deformity, comorbidities, duration of the treatment, complications, Quality of Life Questionnaire scores and follow-up have been recorded. Patients were followed up in outpatient clinics for 3 years. Additionally, pre-treatment, and post-treatment pictures of the patients were taken for the archive in every encounter with them. Furthermore, all the patients were administered the Quality of Life Questionnaire after the completion of the CEB program. None of the patients were excluded during the study. Satisfactory result was defined as desired optimum correction following CEB that was verified by the results of Quality-of-Life Questionnaire after completing the CEB treatment.

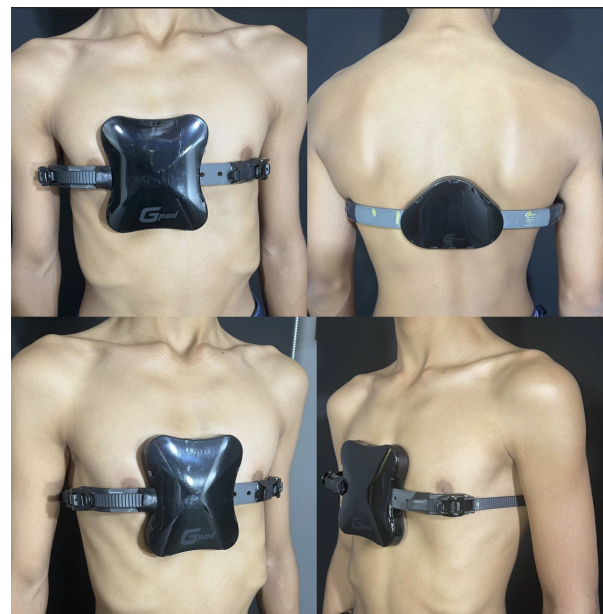
### Compressive External Bracing Protocol

We used the same type of custom-made brace for all the patients (G-pad Pectus Braces, Istanbul). Figure-1 demonstrates the brace and its application. We used a pressure measuring device (G-Pressure, Istanbul, Turkey) which permits the clinician to measure the pressure needed for optimum correction (Figure 2). This pressure was measured at the first consultation by using the measurement device on the thorax of a patient standing with the back against a wall. The pressure required to redress the chest into its normal position is called the pressure for initial correction (PIC) and is measured in pounds per square inch (psi). We used a PIC of 10 psi as a cutoff point for a thorax suitable for the CEB. Patients with a PIC above 10 psi had a more rigid thorax and would probably benefit only from surgical treatment options [13]. Patients were selected for brace treatment if the initial PIC measurement was 10 psi or below. For every patient the mean pressure of initial correction was measured by our team. We only ordered standard chest x-rays in the first outpatient clinic appointment. No other diagnostic imaging was done unless necessary. We did not use any indices for categorizing patients. The patients with PC, who did not receive brace treatment or patients with a PIC above 10 psi, were not enrolled into the CEB program. Therefore, they were treated with Abramson procedure. We performed modified Ravitch surgery only for chondromanubrial type of PC patients which is also named as pectus arcuatum [14]. Brace patients were advised to wear the brace as often as possible during day and night except during showering, bathing, or sports. Patients were seen at our outpatient clinic initially every 4 to 6 weeks for checking on the compliance of the patient and progress of the deformity after CEB. When we reached to a desired correction, we gradually decreased the wearing time (Maintenance Phase). We followed a maintenance phase pattern as decreasing the wearing time to only 8 hours at night, once every 2 nights, 2 nights a week and 1 night a week. After completing this phase,

we only recommended them to wear the brace if the deformity starts to reoccur. This phase lasts 2 to 22 months. If there was no improvement or insufficient improvement of the deformity after 6 to 12 months of treatment, we stop CEB and recommend Abramson procedure for optimum correction. Figure 2 shows the application of specific designed custom-made compressive external bracing.



**Figure 1.** Images demonstrate the use of measurement device for identifying the pressure for initial correction (PIC). This pressure is measured when the patient standing with the back against a wall.



**Figure 2.** Images demonstrate the application of compressive external brace. Brace is adjusted according to the location of the deformity and size of the toracic cavity.

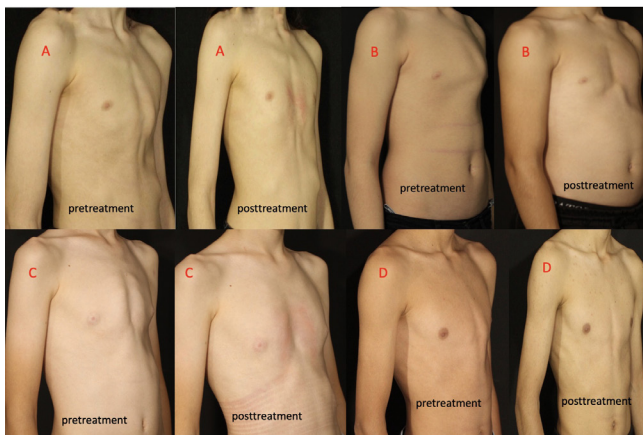### Statistical Analysis

Statistical analyses were performed using statistical software (SPSS, version 25.0 for Windows; SPSS, Chicago, Illinois, United States). Discrete random variables were presented as percentage and continuous random variables were presented as mean and range (max-min values).

### 3. RESULTS

A total of 100 patients were included for compressive external bracing. Of them, 88 were male (88%) and 12 were female (12%) and the mean age was 13.3 years (range, from 3 to 19 years). 76 patients (76%) had a symmetric PC and 24 patients (24%) had asymmetric. Among them, 24 patients (24%) had a positive family history for PC or PE. Table I shows details of the patient characteristics. Although, majority of patients complained a variety of psychosocial issues because of their thoracic deformity, there were also several physical issues.

We had 52 patients (52 %) in the active phase of treatment, while 24 (24 %) were in the maintenance phase. In addition to that, we had 24 patients (24%) who had completed treatment after a mean treatment time of 16 months (range, 9 to 28 months). No recurrences were detected in the whole series, and we did not have any patients who abandoned or had problems with compliance. Although younger patients had tendency to not to wear as planned, they got better results in a shorter time than the older patients. 23 (23%) patients had scoliosis, 9 (9%) had kyphosis, 1 (1%) had Poland Syndrome and 1 (1%) patient had Marfan Syndrome as accompanying anomalies. The patient with Marfan Syndrome had a history of right thoracotomy due to aortic coarctation operation. Additionally, 46 (46%) of the patients had flaring ribs bilaterally which were treated with specially designed rib bandages along with CEB if they are younger than 16 years old. If bandages did not help in correcting the rib flares, we recommended custom-made rib flare braces as we did in the adult population. For patients who were older than 16 years we did not use bandages and preferred custom-made rib flare braces initially. Figure 3 demonstrates pre – and post-treatment pictures of some of our patients.



**Figure 3.** Pre and post-treatment images of some of the patients. A. A 13-year-old male patient before and after application of CEB B. An 11-year-old male patient before and after application of CEB C. A 12-year-old male patient before and after application of CEB D. A 16-year-old male patient before and after application of CEB.

**Abbreviations :** CEB ; compressive external bracing

Four patients (4%) experienced skin lesions as adverse events from application of CEB. We discontinued the CEB treatment until the complete resolution of the skin lesions and restarted application with lower pressures to avoid the same complication. Quality-of-Life Questionnaire revealed 97% patient satisfaction.

**Table I.** Characteristics of the patients<sup>a</sup>

Number of the patients (n)	100
Age (yr.)	13.3 (3-19)
Sex (n)	
Female	12 (12%)
Male	88 (88%)
Type of the deformity (n)	
Symmetrical	76 (76%)
Asymmetrical	24 (24%)
Comorbidities (n)	
Scoliosis	23 (23%)
Kyphosis	9 (9%)
Poland Syndrome	1 (1%)
Marfan Syndrome	1 (1%)
Rib Flare	36 (36%)
Past Surgical History (n)	
Aorta coarctation	1 (1%)
Psychosocial symptoms	
Ashamed of appearance	72 (72%)
Cosmetic issues	46 (46%)
Anxiety	34 (34%)
Problems in social life	21 (21%)
Symptoms	
Exercise intolerance	24 (24%)
Exertional SOB	21 (21%)
Palpitation	15 (15%)
Exertional chest pain	9 (9%)

<sup>a</sup> The values are presented as a number (the percentage of variables) or the mean value (range). Abbreviations: mo, month; SOB, shortness of breath ; yr, year.

### 4. DISCUSSION

There have been some studies about the brace treatment application for the correction of PC. Although, there are multiple types of bracings and techniques, most of them have similar successful results except the difference in costs of the brace of choice [15-18]. Even though, bracing has been used since 1970s in the treatment of PC, the routine use of it became popular in the last decade due to the report of the successful results from various centers [16,17]. This led to the establishment and development of new concepts and protocols in the management of non-surgical treatment of PC. Another reason for the delay in the use of CEB was the successful results from the surgical treatment. Several studies exist in the literature presenting the satisfactory outcomes after Abramson procedure [19-21] It has been preferred by pectus physicians in PC treatment for years by being minimally invasive and having less morbidity rates. Nevertheless, this preference has changed in the last decade. Several studies with various techniques from different centers all over the world proved that CEB is as successful as surgical



treatment. Results from the first 100 patients of our program revealed 97% of patient satisfaction without any recurrence or major complication. Martinez-Ferro and colleagues reported their series of 208 patients by applying dynamic compression system which the pressure applies can be objectively adjusted by the physician. They presented excellent results with high patient satisfactions [13]. Fraser and friends published their data on 249 patients who had treated with classic CEB and reported 98% concordance and 94% satisfaction. They highlighted the compliance of the patient to the bracing program as the key factor in the whole process [22]. Dekonenko et al., reported outcomes of 460 PC patients with dynamic compression system with a high satisfaction rate in compliant patients [23]. On the other hand, Moon and his colleagues published their work including 320 PC patients. They reported their results with classical CEB treatment with high satisfaction rate (87.4%). In addition to that, they also proved the long-term success of the CEB [24]. Our series with 97% patient satisfaction match with the existing data published by pioneer reference centers all over the world. Although, we did not experience any recurrences in our patient series who completed the CEB program, it remains unknown whether protrusion of the chest may recur in the long run. This success of non-surgical option also made an increase in the numbers of patients admitting to the outpatient clinics by offering a non-invasive option for the correction. Addition to that, CEB enabled us to treat patients at earlier ages before causing psychosocial problems and symptoms.

During exercise even though majority of the centers take 7.5 psi as the cutoff value for starting CEB, few exceptional examples exist. Cohee et al., published their series including a patient with a PIC above 9 PSI who had an excellent result after a total treatment time of 16 months [25]. Lopez and colleagues reported 2 patients with a PIC of 14 psi who were improving under treatment [26]. In our study, we included 2 patients with a PIC above 10 psi and one of them completed the CEB program with satisfaction and the other one was in the retainer mode without any problems. These data show that there will be more studies in the future extending the cutoff value in the decision making of CEB application.

Some PC patients have severe costal flaring which is the protrusion of the lower costal arches. Unfortunately, CEB or DCS cannot correct those accompanying deformities. We recommend application of specially designed costal flaring braces for the correction of them. We have experienced satisfactory result with this non-surgical approach. In contrary, some centers recommend surgical correction of those deformities [27]. Additionally, no data exists in the literature about the results of CEB in patients with Ehlers-Danlos syndrome. We believe there will be studies in the future for the treatment of PC with CEB including patients with Ehlers-Danlos syndrome to draw a conclusion about the outcomes.

### Limitations

This study has some limitations. This study shows the results of a single center with a specific type of CEB program and brace. We need to design a multicenter study with the same program

especially including centers from all over the world. Addition to that, we need to wait to see the long-term results to assess whether protrusion of the chest will recur after brace treatment is discontinued. This will be an important factor before we can recommend brace therapy as the treatment of choice in patients with PC and a flexible chest.

### Conclusion

In conclusion, compressive external bracing provides satisfactory results in compliant patients. It enables us to treat more patients in younger ages with lesser comorbidity than surgical option.

Compressive external bracing is an effective non-surgical and safe option in the treatment of PC patients and can be applied without problems in experienced centers.

### Compliance with Ethical Standards

**Ethical approval:** The study was approved by the Marmara University, School of Medicine Ethical Board (14.07.2023 – 07.2023.1139).

**Financial Support:** No financial support to disclose.

**Conflict of Interest:** Author has nothing to declare.

**Authors contributions:** NOE: Data acquisition, data analysis, data interpretation, manuscript preparation and revisions.

### REFERENCES

- [1] Shamberger RC, Welch KJ. Surgical correction of chondromanubrial deformity (Currarino Silverman syndrome). *J Pediatr Surg* 1988;23:319-22
- [2] Golladay ES. Pectus carinatum and other deformities of the chest wall. In: Ziegler MM, Azizkhan RG, Weber TR, editors. *Operative Pediatric Surgery*. New York (NY) : 7 McGraw-Hill, 2003:269-277.
- [3] Fonkalsrud EW, Beanes S. Management of pectus carinatum: 30 years experience. *World J Surg* 2001;25:898-903
- [4] Ravitch M. The operative correction of pectus carinatum (pigeon breast). *Ann Surg* 1960;151:705-14.
- [5] Abramson H. A minimally invasive technique to repair pectus carinatum. Preliminary report. *Arch Bronconeumol* 2005;41:349-51.
- [6] Goretsky MJ, Kelly RE Jr, Croitoru D, Nuss D. Chest wall anomalies: pectus excavatum and pectus carinatum. *Adolesc Med Clin* 2004 Oct;15:455-71. doi: 10.1016/j.admecli.2004.06.002.
- [7] Janssen N, Daemen JHT, Franssen AJPM, et al. Modification of the Abramson procedure for minimally invasive repair of pectus carinatum: introduction of a pectus carinatum compression system. *J Thorac Dis* 2023 ;15:4120-9. doi: 10.21037/jtd-23-642.
- [8] Park CH, Kim TH, Haam SJ, Lee S. Does overgrowth of costal cartilage cause pectus carinatum? A three-dimensional computed tomography evaluation of rib length and costal cartilage length in patients with asymmetric pectus carinatum.

- Interact Cardiovasc Thorac Surg 2013 ;17:757-63. doi: 10.1093/icvts/ivt321
- [9] Coelho Mde S, Guimarães Pde S. Pectus carinatum. J Bras Pneumol 2007;33:463-74. doi: 10.1590/s1806.371.3200700.040.0017.
- [10] Westphal FL, Lima LC, Lima Neto JC, Chaves AR, Santos Junior VL, Ferreira BL. Prevalence of pectus carinatum and pectus excavatum in students in the city of Manaus, Brazil. J Bras Pneumol 2009; 35:221-6.
- [11] Shamberger RC, Welch KJ. Surgical correction of pectus carinatum. J Pediatr Surg 1987; 22:48-53. J Pediatr Surg 1987;22:48-53.
- [12] Abramson H, Aragone X, Blanco JB, Ciano A, Abramson L. Minimally invasive repair of pectus carinatum and how to deal with complications. J Vis Surg 2016;2:64. doi: 10.21037/jovs.2016.03.11.
- [13] Martinez-Ferro M, Fraire C, Bernard S. Dynamic compression system for the correction of pectus carinatum. Semin Pediatr Surg 2008;17:194-200.
- [14] Kuzmichev V, Ershova K, Adamyan R. Surgical correction of pectus arcuatum. J Vis Surg 2016;2:55. doi: 10.21037/jovs.2016.02.28.
- [15] de Beer S, Volcklandt S, de Jong J, Oomen M, Zwaveling S, van Heurn E. Dynamic compression therapy for pectus carinatum in children and adolescents: Factors for success. J Pediatr Surg 2023;58:1440-5. doi: 10.1016/j.jpedsurg.2022.09.008.
- [16] Poola AS, Pierce AL, Orrick BA, et al. A single-center experience with dynamic compression bracing for children with pectus carinatum. Eur J Pediatr Surg 2018;28:12-7. doi: 10.1055/s-0037.160.6845.
- [17] Emil S, Sévigny M, Montpetit K, et al. Success and duration of dynamic bracing for pectus carinatum: A four-year prospective study. J Pediatr Surg 2017;52:124-9. doi: 10.1016/j.jpedsurg.2016.10.032.
- [18] Sesia SB, Holland-Cunz S, Häcker FM. Dynamic compression system: an effective nonoperative treatment for pectus carinatum: a single center experience in Basel, Switzerland. Eur J Pediatr Surg 2016;26:481-6. doi: 10.1055/s-0035.157.0758.
- [19] Kocher G, Gioutsos K, Nguyen TL, Sesia S. Minimally invasive repair of pectus carinatum using the Abramson technique. Multimed Man Cardiothorac Surg 2021;2021. doi: 10.1510/mmcts.2021.082.
- [20] Yuksel M, Lacin T, Ermerak NO, Sirzai EY, Sayan B. Minimally invasive repair of pectus carinatum. Ann Thorac Surg 2018;105:915-23. doi: 10.1016/j.athoracsur.2017.10.003.
- [21] Zhang X, Hu F, Bi R, Wang L, Jiang L. Minimally invasive repair of pectus carinatum with a new steel bar. J Thorac Dis 2022;14:2781-90. doi: 10.21037/jtd-22-189.
- [22] Fraser S, Harling L, Patel A, Richards T, Hunt I. External compressive bracing with initial reduction of pectus carinatum: compliance is the key. Ann Thorac Surg 2020;109:413-9. doi: 10.1016/j.athoracsur.2019.08.026.
- [23] Dekonenko C, Dorman RM, Pierce A, et al. Outcomes following dynamic compression bracing for pectus carinatum. J Laparoendosc Adv Surg Tech A 2019;29:1223-7. doi: 10.1089/lap.2019.0171.
- [24] Moon DH, Kang MK, Lee HS, Lee S. Long-term results of compressive brace therapy for pectus carinatum. Thorac Cardiovasc Surg 2019 ;67:67-72. doi: 10.1055/s-0038.166.9927.
- [25] Cohee AS, Lin JR, Frantz FW, Kelly RE Jr. Staged management of pectus carinatum. J Pediatr Surg 2013;48:315-20. doi: 10.1016/j.jpedsurg.2012.11.008.
- [26] Lopez M, Patoir A, Varlet F, et al. Preliminary study of efficacy of dynamic compression system in the correction of typical pectus carinatum. Eur J Cardiothorac Surg 2013;44:e316-9. doi: 10.1093/ejcts/ezt425.
- [27] Nagasao T, Aizezi N, Tamai M, Kogure T, Morotomi T. Separation of the seventh costal-sternal junction-A new technique to improve outcomes for the Nuss procedure for pectus excavatum. J Plast Reconstr Aesthet Surg 2023 ;76:4-9. doi: 10.1016/j.bjps.2022.10.002.