

The Relationship between Testis Arfi Elastography Values and Sperm Count in Infertile Patients

İnfertil Hastalarda Testis Arfi Elastografi Değerlerinin Sperm Sayıları İle İlişkisi

Cihad VAROL¹ , Hale ÇOLAKOĞLU ER² , Mehmet DEMİR³ 

¹ Private Gözde Hospital Radiology Department, Aydın, TÜRKİYE

² Private Güven Hospital Radiology Department,, Ankara, TÜRKİYE

³ Harran University, Faculty of Medicine, Department of Radiology, Şanlıurfa, TÜRKİYE

Abstract

Background: The aim of this prospective study was to determine the relationship between testicular shear wave elastography (SWE) and sperm count in infertile male patients and to evaluate diagnostic performance.

Materials and Methods: The study was carried out with 113 patients over 18 years of age who were diagnosed as infertility. All patients underwent US examination and virtual touch tissue imaging measurement (VTIQ) SWE examination. A total of 6 measurements were made in each testis. Volume measurements of testes were calculated with US examination. Patients were evaluated for varicocele using color Doppler ultrasonography

Results: Right and left testis volume values in azoospermia patients found statistically different and lower than other groups ($p=0,001$). The mean SWE values in all zones were significantly higher in azoospermia patients compared to the other groups ($p=0,001$). Moderate positive correlation was found between sperm count and mean volume ($r=0,545$, $p=0,001$). Negative correlation was found between sperm count and mean SWE ($r=-0,429$, $p=0,001$). There was a moderate negative relationship between mean volume and mean SWE ($r=-0,590$, $p=0,001$). Using ROC analysis between normal sperm and azoospermia patients, the cut-off value was 2.06 m/sec. sensitivity 72% specificity was measured 87.88% ($p<0,001$; AUC=0,837; Sensitivity= 72,00% (95% GA 46,5-85,1); Specificity=87,88% (95% GA 81,5-95,2). Using ROC analysis between the azoospermia patient group and the oligospermia patient group, the cut-off point was 2.04m/sec. For differentiating azoospermia and oligospermia patients groups, the sensitivity (sensitivity) was 72% and the specificity was 83.33% ($p<0,001$; AUC=0,789; Sensitivity= 72,00% (95% GA 46,5-85,1); Specificity=83,33% (95% GA 81,5-95).

Conclusions: SWE is a noninvasive method for the evaluation of testicular parenchyma in male patients who have infertility and may provide helpful information in addition to gray scale and RDUS.

Key Words: Infertility, testis, shear wave ultrasonography, ultrasound, VTIQ

Öz

Amaç: Bu prospektif çalışmanın amacı infertil erkek hastalarda shear wave elastografinin (SWE) sperm sayısı ile ilişkisini saptamak ve tanısal performansının değerlendirilmesidir.

Materyal ve Metod: alışıma infertilite tanısı almış ve semen analizi yapılan 113 hasta ile yapılmıştır. Tüm hastalara US incelemesi ve virtual touch tissue imaging quantification (VTIQ) kullanılarak SWE incelemesi yapıldı. Her testiste toplam 6 ölçüm yapıldı. US inceleme ile testislerin hacim ölçümleri yapıldı.

Bulgular: Azospermi hastalarında sağ ve sol testis volüm değerleri diğer gruplardan istatistiksel olarak farklı ve düşük değerde bulunmuştur ($p=0,001$). Azospermi hastalarında tüm zonlarda ve ortalama SWE değerleri diğer gruplara göre anlamlı yüksek bulunmuştur ($p=0,001$). Sperm sayısı ile ortalama volüm arasında pozitif yönde orta şiddette bir ilişki saptanmıştır ($r=0,545$, $p=0,001$). Sperm sayısı ile ortalama SWE arasında negatif yönde orta şiddette bir ilişki saptanmıştır ($r=-0,429$, $p=0,001$). Ortalama volüm ile ortalama SWE arasında negatif yönde orta şiddette bir ilişki saptanmıştır ($r=-0,590$, $p=0,001$). Sperm sayısı normal hasta grubu ile azospermi hastaları arasında yapılan ROC analizinde kesim değeri 2,06 m/sn olup sensitivite (duyarlılık) %72 spesivite (özgüllük) %87,88 ölçülmüştür. ($p<0,001$; EAA=0,837; Sensitivite= 72,00% (95% GA 46,5-85,1); Spesivite=87,88% (95% GA 81,5-95,2). Azospermi hasta grubu ile oligospermi hasta grubu arasında yapılan ROC analizinde kesim noktası 2,04 m/sn olarak belirlenmiştir. Buna göre yapılan değerlendirmede sensitivite %72 spesivite %83,33 ölçülmüştür. ($p<0,001$; EAA=0,789; Sensitivite= 72,00% (95% GA 46,5-85,1); Spesivite=83,33% (95% GA 81,5-95).

Sonuç: İnfertilite şikayetiyle başvuran erkek hastalarda testis parankiminin değerlendirilmesinde, SWE invaziv olmayan bir yöntem olup gri skala ve RDUS tetkiklerine ek yararlı bilgiler sağlayabilir.

Anahtar Kelimeler: İnfertilite, Testis, Shear wave elastografi, Ultrason, VTIQ

Corresponding Author/Sorumlu Yazar

Dr. Mehmet DEMİR

Harran University, Faculty of Medicine, Department of Radiology, Şanlıurfa, TÜRKİYE

E-mail: dr.mehmetdemir@hotmail.com

Received / Geliş tarihi: 16.10.2023

Accepted / Kabul tarihi: 11.12.2023

DOI: 10.35440/hutfd.1377085

This study is derived from the thesis titled 'The Relationship Between Testis Arfi Elastography Values And Sperm Count In Infertile Patients' dated 2019 (National thesis centre thesis number: 596150).

Introduction

The steps followed in the evaluation of the infertile man are anamnesis, physical examination, laboratory tests and imaging methods. After all these steps, a diagnosis is made and treatment options are determined in line with this diagnosis. Although there are mostly idiopathic causes in etiology, positive results can be obtained with the diagnosis and treatment of treatable causes. Accordingly, treatable causes should be revealed. Among the imaging methods that help in diagnosis, the first choice is Ultrasonography (US), which is an easily applied and low-cost method (1). Developments in technology contribute to the development of new applications in imaging methods, as in all fields. This situation has been reflected in US with ARFI (Acoustic Radiation Force Impulse), whose application area has been gradually expanding in recent years. It has been widely accepted in the distinction between benign and malignant cases in the thyroid, breast and partly in the prostate gland, and studies have been conducted and continue to be carried out in other areas such as the scrotum and musculoskeletal areas (2). In our study, it was questioned what kind of information the ARFI technique could provide us about infertility in infertile patients. For this reason, the correlation of ARFI findings with semen analysis results was studied.

Materials and Methods

Patient Selection

This study was approved by the faculty ethics committee and informed consent forms were obtained from all patients before the procedures. 113 patients over the age of 18, who were previously diagnosed with infertility, sent to our department for scrotal US and requested semen analysis between December 2018 and April 2019, were included in

the study. A total of 226 testicular examinations were performed in 113 patients.

Gray Scale US Examination:

In the grey-scale US examination, the patients were examined in the supine position. Firstly, conventional B-Mode US examination was performed. Testicular echogenicity and homogeneity were examined. Bilateral testicular volumes were measured in the longest three axes and calculated automatically with an ultrasound device. All applications were performed using an Acuson S2000 (Siemens Medical Solution, Mountain View, CA, USA) ultrasound device and a 4-9 MHz 9L4 linear transducer.

Shear Wave Elastography Review:

Shear wave elastography review with Acuson S2000 (Siemens Medical Solution, Mountain View, CA, USA) ultrasound, 4-9 MHz with VTIQ (Siemens Medical Solution, Mountain View, CA, USA) application, an ARFI-based elastography application. It was made with a 9L4 linear transducer with a wide frequency range. With gray scale US, the testicle was taken into the examination area with the transducer perpendicular to the skin, avoiding applying pressure to the area. The patient was told not to move, paying attention to the gel thickness between the transducer and the skin. By placing a sampling box on the testicle, the testicle was divided into 3 parts as upper, middle and lower, and two ROI (Region of interest - Sampling area) giving Shear wave speeds (m/sec) were placed in each part, and a total of 6 speed values were measured for each testicle. Then, these values were averaged by using a harmonic mean and the average Shear Wave velocities of each region and testicle were measured. There is a color spectrum corresponding to all speed values within the sample area; high speed values are coded in red and low speed values in blue (Figure 1).

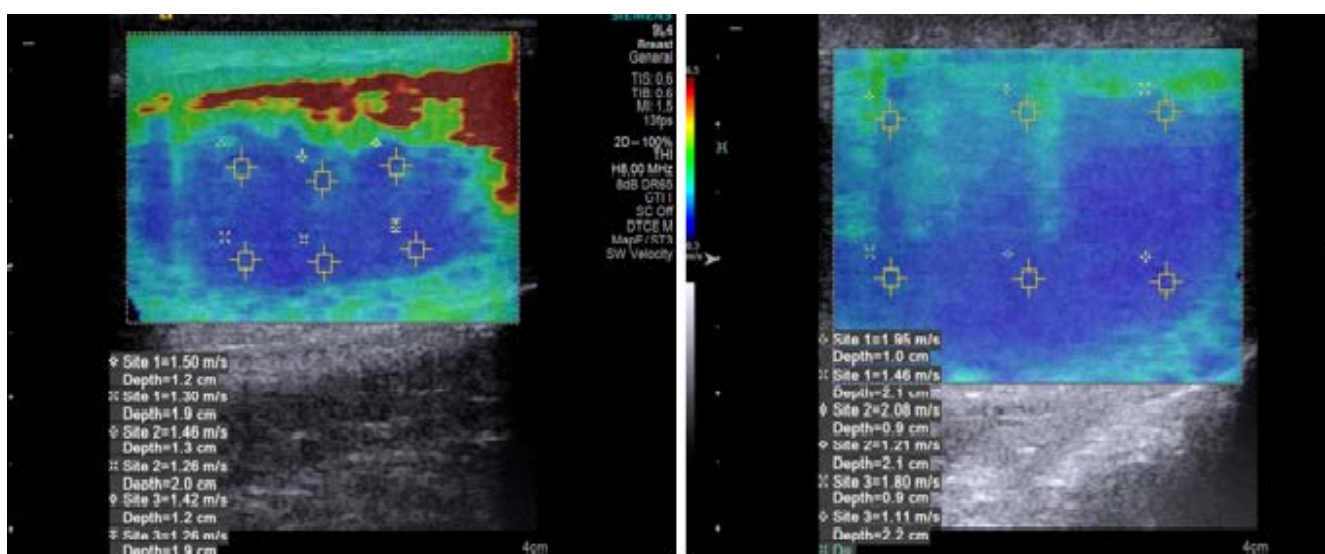


Figure 1. Shear Wave measurements and gray scale ultrasonography images of a 27-year-old patient with oligospermia, which were high at some points.

Semen Analysis

Semen analysis was carried out in the sperm analysis laboratory of Department of Urology, by taking a sperm sample under appropriate conditions after three days of sexual abstinence. In our study, semen volume (ml), sperm count per milliliter (million/ml), total motility (%), progressive motility (%) and normal morphology (%) criteria were used. According to the sperm analysis results, we divided the patients into 4 groups; (I) Azoospermia, (II) Oligospermia, (III) Normospermia and (IV) Low motility (Sperm count is normal).

Statistical Analysis

Normal distribution test of the data obtained from the study according to groups was performed with Kolmogorov-Smirnov and Shapiro Wilk tests. One-way analysis of variance (ANOVA) was used to compare variables with normal distribution by groups, and the Kruskal Wallis test was used to compare variables that were not normally distributed by groups. As a result of ANOVA analysis, LSD test, one of the post hoc tests, was used to determine the difference between groups. As a result of Kruskal Wallis analysis, post hoc pairwise test was used to determine the difference between groups. Spearman Rank Correlation coefficient was used for correlation analysis. Analyzes were carried out with the help of SPSS 22.0 program. Values of $p < 0.05$ were considered significant.

Results

The number of patients included in the study was 113 and their ages ranged from 20 to 53 years. The average age of the patients was calculated as 21.90 ± 6.32 years. 25 patients in group 1 (azoospermia), 30 patients in group 2 (oligospermia), 33 patients in group 3 (normal) and 25 patients in group 4 (low motility) were studied (Figure 2).

When the volumes are examined, the right testicular and left testicular volume values of the groups show a statistically significant difference ($p < 0.05$). The right and left testicular volume values of the azoospermia group are statistically different and lower than the other groups ($p = 0.001$). The right volume values of the oligospermia group were found to be statistically lower than the normal and motility disorder groups, but higher than the azoospermia group (Table 1).

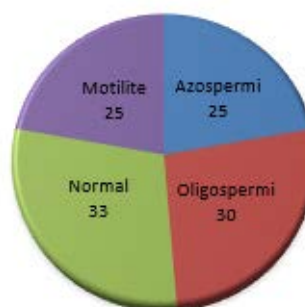

Figure 2. Distribution of infertile patients by groups

Table 1. Distribution and statistical data of testicular volumes according to groups

	Gruplar	N	Mean Volume	Standard deviation	p
Right testicular volume	1 (azoospermia)	25	7,98	4,56	0,001
	2 (oligospermia)	30	14,04	5,89	
	3(normal)	33	16,71	4,14	
	4 (low motility)	25	16,45	4,57	
Left testicular volume	1 (azoospermia)	25	7,72	4,41	0,001
	2 (oligospermia)	30	13,76	6,01	
	3(normal)	33	15,46	4,68	
	4 (low motility)	25	16,01	4,18	

The right upper zone SWE, right middle zone SWE, right lower zone SWE, left upper zone SWE, left middle zone SWE, left lower zone SWE and average SWE values in the azoospermia group are significantly higher than those in the oligospermia, normal sperm count and low motility groups was found to be high ($p = 0.001$) (Table 2). No significant difference was detected between other groups. Analysis was performed using ROC (Receiver Operating Characteristic) curves to obtain cut-off values between the patient group with normal sperm count and the azoospermia and oligospermia groups.

For the average SWE variable, the sperm count normal CI 46.5-85.1); specificity=83.33% (95% CI 81.5-95).

In the examination, a moderate positive relationship was found between sperm count and average volume ($r = 0.545$, $p = 0.001$). A moderate negative relationship was

group and the azoospermia group were included, and the cut-off point was used in ROC analysis and the cut-off point was determined as 2.06 m/sec. Accordingly, in the evaluation, sensitivity was measured as 72% and specificity as 87.88%. ($p < 0.001$; AUC=0.837; sensitivity= 72.00% (95% CI 46.5-85.1); specificity=87.88% (95% CI 81.5-95.2).

Oligospermia group and azoospermia group were included for the average SWE variable, and ROC analysis was used to determine the cut-off point and the cut-off point was determined as 2.04 m/sec. Accordingly, in the evaluation, sensitivity was measured as 72% and specificity as 83.33%. ($p < 0.001$; AUC=0.789; sensitivity= 72.00% (95% CI 46.5-85.1); specificity=83.33% (95% CI 81.5-95.2).

A moderate negative relationship was found between mean volume and mean SWE ($r = -0.590$, $p = 0.001$).

Table 2. SWE (m/sec) measurement results in testicular parenchyma and distribution according to groups, statistical analysis

Groups		N	Mean	Sd	P
Right upper zone SWE	1(azoospermia)	25	2,71	1,16	0,001
	2(oligospermia)	30	1,77	0,64	
	3(Normal)	33	1,50	0,4	
	4(low motility)	25	1,55	0,68	
Right middle zone SWE	1(azoospermia)	25	2,79	1,22	0,001
	2(oligospermia)	30	1,78	1,02	
	3(Normal)	33	1,53	0,64	
	4(low motility)	25	1,55	0,59	
Right lower zone SWE	1(azoospermia)	25	2,83	1,23	0,001
	2(oligospermia)	30	1,82	0,84	
	3(Normal)	33	1,42	0,55	
	4(low motility)	25	1,58	0,78	
Left upper zone SWE	1(azoospermia)	25	2,55	0,97	0,001
	2(oligospermia)	30	1,69	0,69	
	3(Normal)	33	1,59	0,64	
	4(low motility)	25	1,74	0,75	
Left middle zone SWE	1(azoospermia)	25	2,87	1,38	0,001
	2(oligospermia)	30	1,68	0,8	
	3(Normal)	33	1,65	0,86	
	4(low motility)	25	1,62	0,66	
Left lower zone SWE	1(azoospermia)	25	2,98	1,23	0,001
	2(oligospermia)	30	1,94	1,05	
	3(Normal)	33	1,63	0,67	
	4(low motility)	25	1,60	0,48	
Mean	1(azoospermia)	25	2,77	1,03	0,001
	2(oligospermia)	30	1,75	0,75	
	3(Normal)	33	1,57	0,49	
	4(lowmotility)	25	1,60	0,52	

N: Count Sd: Standart deviation, SWE: shear wave elastography

Discussion

In this study, in our evaluation of the volume; The right and left testicular volume values of the azoospermia group were found to be statistically different and lower than the other groups (p = 0.001). The right volume values of the oligospermia group were found to be statistically lower than the normal and motility disorder groups, but higher than the azoospermia group (p=0.001). In our correlation study between sperm count and average testicular volume, a moderate positive relationship was found (r=0.545, p=0.001). Our findings are compatible with the studies of Arai et al. (3), Bujanet al (4). and Macleod et al (5). Causes of testicular tissue stiffness can be explained by the anatomy of the testicle.

We see that sonoelastography is used more frequently in testicular lesions. In a study conducted by Aigner et al. using sonoelastography, they stated that hardness increased in neoplastic testicular lesions and decreased in partial infarction and orchitis (6). Zhang et al.'s study using Shear Wave Elastography suggested that testicular stiffness-hardness could be used to evaluate spermatogenesis after torsion (7). The first study investigating the relationship between testicular elasticity and infertility was the study by Liet al (8). It examined the contribution of elasticity scoring and Strain Index in the diagnosis of azoospermia. The study conducted by Anastasi et al. using the ARFI technique on 23 volunteers without testicular pathology is the first study conducted with shear wave wave speed (9).

The testicle is divided into segments and lobes by the rete

testis by numerous small septa. The size of these lobes is larger and longer in the central part of the testicle. The mediastinum consists of testicles, connective tissue, central vascular structures and larger vessels drained from the lobules by lymphatics (10). Some changes occur in the testicles depending on age. It has been found that in men, sperm quality, testicular size, and the number of all germ cell types, including Leydig and Sertoli cells, decrease with older ages. Histomorphological examinations showed that the volume containing the seminiferous tubes decreased, while the tissue formed by the testicular interstitium remained constant. Additionally, accumulation of lipid droplets in Sertoli cell cytoplasm has also been demonstrated. Since this development is similar to the changes observed after experimental ischemia, it has been suggested that vascular lesions may play an important role in age-related testicular atrophy (11,12). In the study of Anastasi et al., a positive correlation was found between advanced age and shear wave speed, and the reasons listed above were suggested as the reason (6). In our study, no correlation was found between age and average testicular volume, sperm count and SWE values. The reason for this is thought to be related to the narrow age range of infertile patients applying to our study and the small number of older patient groups.

In our study, mean SWE values in all zones and in the azoospermia group were found to be significantly higher than the other groups ($p = 0.001$). The reason for this is thought to be seminiferous tubule hyalinization, which is identified in testicular biopsies and known as end stage testicle. Although ischemia and infection are among the reasons that cause this, no obvious reason has been found in most cases. If the patient has Klinefelter syndrome, the reason for the increase in testicular hardness is Leydig cell hyperplasia or SCO (Sertoli cell only) syndrome (5,13,14).

A moderate negative correlation was detected between mean volume and mean SWE values in all patient groups ($r = -0.590$, $p = 0.001$, $r = -0.429$, $p = 0.001$). In the Elastography Strain Index study performed by Li et al. by scoring from 1 to 5, a strong negative correlation was found between testicular volume and elastography values (8). In our study, a moderate negative correlation was found between sperm count and average SWE values in all patient groups. In the analysis made between the azoospermia group and the normal sperm count groups using the ROC curve, the cut-off value was determined as 2.06 m/sec. Accordingly, in the evaluation, sensitivity was measured as 72% and specificity as 87.88%. In the analysis made between the azoospermia group and oligospermia groups using the ROC curve, the cut-off value was determined as 2.04 m/sec. In this evaluation, sensitivity was measured as 72% and specificity as 83.33%. The only cut-off study in the literature is the study by Yavuz et al., and in their study with similar groups, the cut-off value was measured as 1.465 in the group with azoospermia and normal sperm count, and the sensitivity was 75% and the specificity was 75%. has been found. In the

azoospermia and oligospermia groups, 1,528 m/sec was measured and the sensitivity was found to be 60.7% and the specificity was 66.7% (15). The reason why our findings are different may be due to the different patient population and technical differences. It is thought that more studies and technical optimization on this subject may be useful.

Our study has some limitations, such as the fact that testicular SWE measurements were taken in fewer numbers than other studies, there was no classification as obstructive and non-obstructive in the azoospermia group, and there was no discrimination between pre-testicular, testicular and post-testicular causes of azoospermia.

As a conclusion, we believe that SWE combined with semen analysis is a method that can be used as a non-invasive, repeatable auxiliary technique in patients presenting with infertility complaints.

Ethical Approval: This study is derived from the thesis titled 'The Relationship Between Testis Arfi Elastography Values And Sperm Count In Infertile Patients' dated 2019 (National thesis centre thesis number: 596150).

Author Contributions:

Concept: C.V., H.Ç.E.

Literature Review: M.D.

Design : C.V., M.D.

Data acquisition: C.V.

Analysis and interpretation: H.Ç.E.

Writing manuscript: C.V., M.D.

Critical revision of manuscript: H.Ç.E.

Conflict of Interest: The authors have no conflicts of interest to declare.

Financial Disclosure: Authors declared no financial support.

References

1. Ammar T, Sidhu PS, Wilkins CJ. Male infertility: the role of imaging in diagnosis and management. *Br J Radiol* 2012; 85 Spec No 1: S59-68.
2. Chaturvedi P, Insana MF, Hall TJ. Ultrasonic and elasticity imaging to model disease-induced changes in soft-tissue structure. *Med Image Anal* 1998; 2(4): 325-38.
3. Arai T, Kitahara S, Horiuchi S, Sumi S, Yoshida K. Relationship of testicular volume to semen profiles and serum hormone concentrations in infertile Japanese males. *Int J Fertil Womens Med* 1998; 43(1): 40-7.
4. Bujan L, Miousset R, Mansat A, Moatti JP, Mondinat C, Pontonnier F. Testicular size in infertile men: relationship to semen characteristics and hormonal blood levels. *Br J Urol* 1989; 64(6): 632-7.
5. MacLeod J, Wang Y. Male fertility potential in terms of semen quality: a review of the past, a study of the present. *Fertil Steril* 1979; 31(2): 103-16.
6. Aigner F, De Zordo T, Pallwein-Pretner L, et al. Real-time sonoelastography for the evaluation of testicular lesions. *Radiology* 2012; 263(2): 584-9.
7. Zhang X, Lv F, Tang J. Shear wave elastography (SWE) is reliable method for testicular spermatogenesis evaluation after torsion. *Int J Clin Exp Med* 2015; 8(5): 7089-97.
8. Li M, Du J, Wang ZQ, Li FH. The value of sonoelastography scores and the strain ratio in differential diagnosis of azoospermia. *J Urol* 2012; 188(5): 1861-6.

9. D'Anastasi M, Schneevoigt BS, Trottmann M, Crispin A, Stief C, Reiser MF, Clevert DA. Acoustic radiation force impulse imaging of the testes: a preliminary experience. *Clin Hemorheol Microcirc* 2011; 49(1-4): 105-14.
10. Juul S, Group TEISS, Karmaus W, Group TEISS, Olsen J, Group TEISS. Regional differences in waiting time to pregnancy: pregnancy-based surveys from Denmark, France, Germany, Italy and Sweden. *Human Reproduction* 1999; 14(5): 1250-4.
11. Handelsman Dj, Staraj S. Testicular Size: The Effects of Aging, Malnutrition, and Illness. 1985; 6(3): 144-51.
12. Mahmoud AM, Goemaere S, El-Garem Y, Van Pottelbergh I, Comhaire FH, Kaufman JM. Testicular Volume in Relation to Hormonal Indices of Gonadal Function in Community-Dwelling Elderly Men. *The Journal of Clinical Endocrinology & Metabolism* 2003; 88(1): 179-84.
13. Aksglaede L, Skakkebaek NE, Almstrup K, Juul A. Clinical and biological parameters in 166 boys, adolescents and adults with nonmosaic Klinefelter syndrome: a Copenhagen experience. *Acta Paediatr* 2011; 100(6): 793-806.
14. Cerilli LA, Kuang W, Rogers D. A practical approach to testicular biopsy interpretation for male infertility. *Arch Pathol Lab Med* 2010; 134(8): 1197-204.
15. Yavuz A, Yokus A, Taken K, Batur A, Ozgokce M, Arslan H. Reliability of testicular stiffness quantification using shear wave elastography in predicting male fertility: a preliminary prospective study. *Med Ultrason* 2018; 20(2): 141-7.