



ARAŞTIRMA / RESEARCH

Association of calcifications at aortic arch with calcifications in different segments of carotid arteries

Arkus aortadaki kalsifikasyonların karotis arterin farklı segmentlerindeki kalsifikasyonlarla ilişkisi

Kaan Esen¹, Engin Kara¹, Anıl Özgür¹, Feramuz Demir Apaydın¹, Arda Yılmaz²

¹Mersin University, School of Medicine, Department of Radiology, ²Department of Neurology, Mersin, Turkey

Cukurova Medical Journal 2017;42(4):694-699

Abstract

Purpose: The aim of this study is to evaluate the association of calcifications at aortic arch with different segments of carotid arteries.

Material and Methods: Carotid computed tomography (CT) angiography examinations of 134 patients, which were performed between January 2013 and February 2015, were retrospectively evaluated. Calcifications at aortic arch, orifice of brachiocephalic trunk, orifice of common and internal carotid arteries, petrous and cavernous/ophthalmic segments of internal carotid arteries were scored.

Results: A statistically significant relationship was detected between calcification scores of aortic arch and brachiocephalic trunk orifice, left common carotid artery orifice, both internal carotid artery orifice, both internal carotid artery cavernous/ophthalmic segments. There was a statistically significant correlation between the age and total calcification scores. However, there was not a relationship between the calcification scores of aortic arch and right common carotid artery orifice, aortic arch and both internal carotid artery petrous segments.

Conclusion: Aortic arch calcifications detected at routine chest CT may be useful to predict the calcification scores of internal carotid artery segments and total carotid calcification score.

Key words: Calcification, aortic arch, carotid artery.

Öz

Amaç: Bu çalışmanın amacı arkus aortadaki kalsifikasyonların, karotis arterin farklı segmentlerindeki kalsifikasyonlarla ilişkisini değerlendirmektir.

Gereç ve Yöntem: Ocak 2013 Şubat 2015 tarihleri arasında, karotis bilgisayarlı tomografi (BT) anjiyografi yapılmış 134 hastanın tetkikleri retrospektif olarak değerlendirildi. Arkus aorta, brakiosefalik trunkus orifisi, her iki ana karotis ve internal karotis arter orifisleri, her iki internal karotis arter petröz ve kavernöz/oftalmik segmentlerindeki kalsifikasyonlar skorlandı.

Bulgular: Arkus aortadaki kalsifikasyonlar ile brakiosefalik trunkus orifisi, sol ana karotis arter orifisi, her iki internal karotis arter orifisi ve her iki internal karotis arter kavernöz/oftalmik segmentinde skorlanan kalsifikasyonlar arasında istatistiksel olarak anlamlı ilişki tespit edildi. Yaş ile total kalsifikasyon skoru arasında da istatistiksel olarak anlamlı ilişki saptandı. Ancak arkus aortadaki kalsifikasyonlar ile sağ ana karotis arter orifisi ve her iki internal karotis arter petröz segmentinde skorlanan kalsifikasyonlar arasında istatistiksel olarak anlamlı ilişki saptanmadı.

Sonuç: Rutin toraks BT tetkiklerinde arkus aortada izlenen kalsifikasyonlar, karotis arterin farklı segmentlerindeki kalsifikasyonlar ve toplam karotis kalsifikasyon skoru için bir öngörü sağlayabilir.

Anahtar kelimeler: Kalsifikasyon, arkus aorta, karotis arter.

INTRODUCTION

Atherosclerosis is a multifactorial disease and an important risk factor for cerebrovascular stroke^{1,2}. Following intimal accumulation of inflammatory

cells, formation of intimal fatty streaks and atherosclerotic plaques are observed. In the advanced stage of atherosclerosis, calcification occurs in the atherosclerotic plaques^{3,4}. Arterial calcification is a frequent finding in elderly

Yazışma Adresi/Address for Correspondence: Dr. Kaan Esen, Mersin University, School of Medicine, Department of Radiology, Mersin, Turkey. E-mail: kaanesen@yahoo.com
Geliş tarihi/Received: 10.01.2017 Kabul tarihi/Accepted: 16.03.2017

population and accepted as a marker of atherosclerosis.

Aortic arch, orifices of major aortic arch branches and internal carotid artery (ICA) orifices are the prominent segments where calcifications concentrate⁵. CT angiography (CTA) is the foremost noninvasive imaging modality that can assess the calcifications of aortic arch and whole carotid system. Aortic arch calcifications can be detected both on routine chest X-rays and CT examinations.

In a population-based cohort study, aortic arch calcification was present in 1.9% of men and 2.6% of women⁶. The clinical importance of aortic arch calcifications has been reported in different studies. Aortic arch calcifications detectable on chest X-rays were reported as a strong independent predictor of cardiovascular events⁷. The presence of atherosclerotic plaques in the proximal aorta, those ≥ 4 mm thick were reported in association with ischemic stroke⁸. On chest CT examinations, aortic arch is barely visible and it is easy to detect the calcifications located there. May the assessment of the calcified plaques with a simple scoring system at the aortic arch be a marker to predict the calcification in the other segments of carotid artery? The aim of this study is to detect the association of calcifications at aortic arch with different segments of carotid arteries at CTA examinations.

MATERIALS AND METHODS

Study population

The radiologic examinations and medical records of the patients, who underwent carotid CTA examination between January 2013 and February 2015 in our clinic, were retrospectively evaluated. CTA examinations were performed with different indications such as the diagnosis of stenosis, aneurysms or vascular malformations. In previous reports, symptomatic carotid atherosclerotic plaques have been reported even at the age of 35 years⁹. Therefore, we considered the lower limit of participation as 35 years.

Patients with bilateral or unilateral carotid stents and carotid occlusions, vascular abnormalities such as carotid hypoplasia and inadequate examinations due to artifacts (such as patient movement, aneurysm coils) were excluded. The patients without information about major vascular risk factors (hyperlipidemia, hypertension, diabetes mellitus) in

the hospital archive system were also excluded. Hypertension and diabetes mellitus were defined as present if there was a diagnosis or the use of antihypertensive / diabetic medications⁴. Hyperlipidemia was accepted as present if the level of fasting triglyceride (≥ 150 mg/dL) or total cholesterol (≥ 200 mg/dL) were elevated or there was a data of lipid lowering medication^{2,10}. Approval for the study was obtained from the ethical committee of our institute (22.10.2015, 2015/318).

CTA imaging protocol

CTA examinations were performed with a 64-slice CT scanner (Toshiba Aquilion 64, Toshiba Medical Systems, Tokyo, Japan). Eighty cc nonionic contrast medium was administered via an antecubital vein. Bolus tracking technique was used. Scanning was initiated when the contrast attenuation in the aortic arch reached 100 Hounsfield units. The scanning range was from the ascending aorta to the vertex. CT parameters were as follows: tube voltage, 120 kVp; effective mAs, 220; slice thickness, 0.5 mm. "Multiplanar reformatted reconstruction (MPR)", "maximum intensity projection (MIP)" images were obtained from axial images^{11,12}.

Calcification detection and scoring

The examinations were evaluated by two experienced radiologists in consensus. Coronal and axial MIP CTA examinations were evaluated to score the calcifications at aortic arch, orifice of common carotid artery (CCA) and ICA, petrous and cavernous/ophthalmic segments of ICA. Aortic arch, orifice of brachiocephalic trunk and left CCA were evaluated in a different session blinded to the other segments. There was one week interval between the measurements of aortic arch and ICA. ICA orifice was defined as the proximal 3 cm-segment of ICA plus the distal 2 cm-segment of CCA. Aortic arch was accepted as the segment between ascending and descending aorta. The orifices of main branches were not included in the aortic arch measurements.

Calcifications were scored according to a five-point grading scale (0-no calcification, 1-calcification like a point, 2-thin continuous or thick discontinuous calcification, 3-thick calcification longer than 3mm, and 4-calcification looks like double tracts) as used in the literature¹⁰. Figure 1 shows examples of calcification scores.

Statistical analysis

All analyses were performed using IBM SPSS Statistics Version 20.0 statistical software package. Categorical variables were expressed as numbers and percentages, whereas continuous variables were summarized as mean and standard deviation and as median and minimum-maximum where appropriate. Chi-square test was used to compare categorical variables between the groups. The normality of distribution for continuous variables was confirmed with the Kolmogorov-Smirnov test. For non-normal distributed data, Kruskal Wallis test was used to compare more than two groups. Bonferroni adjusted Mann Whitney U test was used for multiple comparisons of groups. To evaluate the correlations between measurements, Pearson Correlation Coefficient was used. The statistical level of significance for all tests was considered to be 0.05.

RESULTS

A total of 134 patients were evaluated (51 women and 83 men; 35-96 years old, mean age 65.7 ± 12.3 years). There were no calcifications at the patients under age of 40 years; the eldest patient without

calcification was 70 years old. There were 19 patients with a total calcification score of 0. Table 1 shows the distribution of patients regarding the calcification scores of each segment. A statistically significant relationship was detected between calcification scores of aortic arch and brachiocephalic trunk orifice ($p < 0.001$), aortic arch and left common carotid artery orifice ($p < 0.001$), aortic arch and both ICA orifices ($p < 0.001$ at right and $p < 0.001$ at left), aortic arch and both ICA cavernous/ophthalmic segments ($p < 0.001$ at right and $p < 0.001$ at left).

However, there was not a relationship between the calcification scores of aortic arch and right common carotid artery orifice ($p = 0.372$), aortic arch and both ICA petrous segments ($p = 0.132$ at right and $p = 0.277$ at left). Total calcification scores were evaluated with the sum of calcification scores for each patient. There was a statistically significant correlation between the age and total calcification scores of the patients (Figure 2) ($r = 0.568$, $p < 0.001$). The distribution of aortic arch calcification scores with respect to total calcification scores of the patients is presented in Table 2.

Table 1. The distribution of patients regarding the calcification scores of each segment.

Segments	Calcification Score (N)				
	0	1	2	3	4
Aortic arch	26 (19.4%)	10 (7.5%)	18 (13.4%)	73 (54.5%)	7 (5.2%)
Brachiocephalic orifice	79 (59%)	16 (11.9%)	18 (13.4%)	21 (15.7%)	0
R CCA orifice	118 (88.1%)	3 (2.2%)	10 (7.5%)	3 (2.2%)	0
R ICA orifice	47 (35.1%)	9 (6.7%)	24 (17.9%)	42 (31.3%)	12 (8.9%)
R ICA petrous	107 (79.8%)	4 (3.0%)	8 (6.0%)	13 (9.7%)	2 (1.5%)
R ICA cavernous/ophthalmic	31 (23.1%)	8 (6.0%)	20 (14.9%)	46 (34.3%)	29 (21.6%)
L CCA orifice	79 (59.0%)	12 (8.9%)	20 (14.9%)	21 (15.7%)	2 (1.5%)
L ICA orifice	45 (33.6%)	12 (8.9%)	29 (21.6%)	39 (29.1%)	9 (6.7%)
L ICA petrous	104 (77.6%)	6 (4.5%)	10 (7.5%)	11 (8.2%)	3 (2.2%)
L ICA cavernous/ophthalmic	26 (19.4%)	10 (7.5%)	27 (20.1%)	43 (32.1%)	28 (20.9%)

CCA: Common carotid artery, ICA: Internal carotid artery, N: Number of patients, R: Right, L: Left.

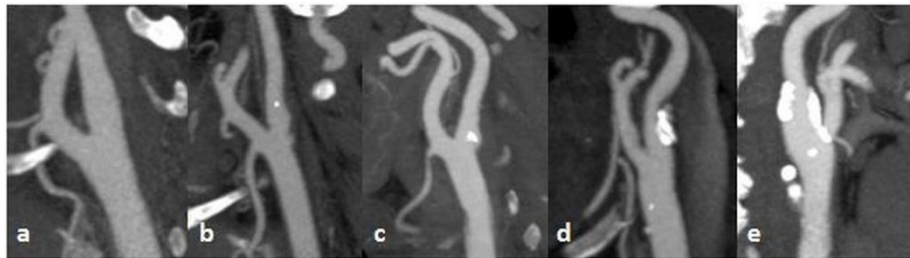


Figure 1. Calcification examples of five-point grading system at internal carotid artery origins on coronal maximum intensity projection images: (a) 0-no calcification, (b) 1-calcification like a point, (c) 2-thin continuous or thick discontinuous calcification, (d) 3-thick calcification longer than 3 mm and (e) 4-calcification looks like double tracts.

Aortic arch calcification scores were compared in pairs with respect to total calcification scores. A statistically significant difference was detected between aortic arch calcification score pairs of 0 and 3 ($p=0.000$), 0 and 4 ($p=0.0001$), 1 and 3 ($p=0.005$), 1 and 4 ($p=0.002$), 2 and 3 ($p=0.0001$), 2 and 4 ($p=0.001$).

However, there was not a statistically significant difference between aortic arch calcification score pairs of 0 and 1 ($p=0.459$), 0 and 2 ($p=0.074$), 1 and 2 ($p=1.000$), 3 and 4 ($p=1.000$). The mean total carotid calcification scores of the patients with aortic arch calcification scores of 3 and 4 were higher than 0, 1 and 2.

Table 2. The distribution of aortic arch calcification scores with respect to total calcification scores.

Aortic Arch Calcification Score	Total Calcification Score				
	Mean	N	±SD	Minimum	Maximum
0	1.04	26	2.088	0	8
1	7.80	10	5.653	1	18
2	8.78	18	4.166	2	19
3	18.21	73	5.520	7	29
4	23.29	7	3.638	19	30
Total	13.10	134	8.668	0	30

SD: Standard Deviation, N: Number of patients.

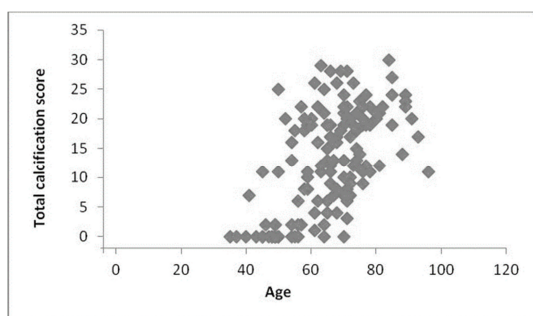


Figure 2. The relationship between age and total calcification score ($r=0.568$, $p<0.001$).

Table 3. The statistical significant level of vascular risk factors with respect to total calcification scores.

Vascular Risk Factors		Mean Total Calcification Score (±SD)	p
Hypertension	+	14.00 (8.24)	0.188
	-	12.02 (9.10)	
Diabetes Mellitus	+	15.79 (7.74)	0.001
	-	11.04 (8.81)	
Hyperlipidemia	+	15.21 (8.69)	0.015
	-	11.53 (8.36)	

SD: Standard Deviation

Hypertension, diabetes mellitus and hyperlipidemia were detected in 54.5%, 43.3% and 42.5% of the patients respectively. The statistical significant level of vascular risk factors with respect to total calcification scores is shown in Table 3.

DISCUSSION

In this study, we found a significant relationship

between the calcification scores of aortic arch, bilateral ICA orifices and ICA cavernous/ophthalmic segments. Aortic arch calcifications also showed a significant relationship with brachiocephalic trunk orifice and left CCA orifice calcifications. Association of mural calcifications at different vessels has been investigated in the literature. Odink et al. found a moderate correlation between calcifications in the

coronary arteries, aortic arch and extracranial carotid arteries, by using volume assessment of calcifications¹³. In that study, proximal 1 cm of the major vessels originating from the aortic arch has been included to the aortic arch different from our study. We also used a simple grading system for the calcifications rather than volume assessment. Another study using 4 grade simple scale system on CTA images demonstrated a higher correlation between the calcification scores of the ICA origins and the orifices of large vessels originating from the aortic arch than between the ICA origins and the aortic arch⁵. Adar et al reported aortic arch calcification as a strong and independent predictor of coronary artery calcification¹⁴.

The extent of vascular calcification has been reported to be related with total burden of atherosclerosis⁴. We calculated total calcification scores in order to evaluate the relationship of aortic arch calcification scores with the extent of calcification. The mean total carotid calcification scores of the patients with a calcification score of 3 and 4 at aortic arch, were statistically higher than 0, 1 and 2 scores. According to our results, patients with a higher calcification score at aortic arch have a higher calcification burden at carotid arteries. As a result, calcifications detected at aortic arch may allow us to predict the extent of calcification at carotid arteries.

Vascular calcification is a part of the atherosclerotic process and occurs in 80 to 90% of atherom plaques¹⁵. The relationship of calcifications at aortic arch and at different segments of carotid arteries with cerebrovascular events has been previously reported in the literature. However, the role of calcifications in ischemic events is controversial in the literature. Plaque calcification has been demonstrated as a marker of regional plaque stability¹⁶. Saba et al. pointed out that calcium provides stabilization of the carotid plaques and CT-detectable brain lesions were found with a lower incidence with calcified carotid plaques when compared with other types of plaques¹. On the other hand, Nandalur et al. reported that overall cervical calcium load may be valuable considering the occurrence of ischemic symptoms¹⁷. Hong et al. reported that carotid siphon calcification was correlated with the existence of lacunar infarction and the degree of carotid siphon calcification may be useful to predict the probability of lacunar infarction⁴. Aortic arch calcifications detected on

chest X-rays were reported as useful in the classification of risks for vascular diseases and a strong independent predictor of cardiovascular events^{18,7}. Classification of risks with assessment of aortic arch calcification may ensure the management of atherosclerotic disease⁷. Iribarren et al reported that aortic arch calcification was independently related to coronary heart disease risk⁶.

CTA has an important role in the diagnosis of carotid artery diseases and provides non-invasive evaluation of calcifications¹⁶. However CTA is not a suitable imaging modality for screening because of radiation exposure. Additionally, the classification of vascular calcifications with a simple 4 or 5 grading system is useful only for evaluating short segments of major vessels⁵. Therefore, the relationships that we investigated between aortic arch and relatively short segments of carotid arteries may be beneficial at chest CT in our daily practice.

Our study has some limitations. First of all this is a retrospective analysis. The other limitations are small number of patient population that does not reflect the general population and semi-quantitative evaluation of calcifications. We also could not evaluate the degree of statistical relationships between calcification scores because of semi-quantitative evaluation. A study with a larger population and volumetric measurement of calcifications is needed.

As a result, our study showed that total carotid calcification score is higher at the patients with higher calcification scores of aortic arch. Therefore, aortic arch calcifications detected with routine chest CT may be helpful to predict the extent of calcification at carotid arteries.

1-5 Kasım 2016 tarihinde Antalya’da yapılan 37. Ulusal Radyoloji Kongresinde sözlü bildiri olarak sunulmuştur.

REFERENCES

1. Saba L, Montisci R, Sanfilippo R, Mallarini G. Multidetector row CT of the brain and carotid artery: a correlative analysis. *Clin Radiol.* 2009;64:767-78.
2. Bos D, van der Rijk MJ, Geeraedts TE, Hofman A, Krestin GP, Wittman JC et al. Intracranial carotid artery atherosclerosis: prevalence and risk factors in the general population. *Stroke.* 2012;43:1878-84.
3. Bos D, Ikram MA, Elias-Smale SE, Krestin GP, Hofman A, Wittman JC et al. Calcification in major vessel beds relates to vascular brain disease.

- Arterioscler Thromb Vasc Biol. 2011;31:2331-7.
4. Hong NR, Seo HS, Lee YH, Kim JH, Seol HY, Lee NJ et al. The correlation between carotid siphon calcification and lacunar infarction. *Neuroradiology*. 2011;53:643-9.
 5. Yamada S, Hashimoto K, Ogata H, Watanabe Y, Oshima M, Miyake H. Calcification at orifices of aortic arch branches is a reliable and significant marker of stenosis at carotid bifurcation and intracranial arteries. *Eur J Radiol*. 2014;83:384-90.
 6. Iribarren C, Sidney S, Sternfeld B, Browner WS. Calcification of the aortic arch: risk factors and association with coronary heart disease, stroke, and peripheral vascular disease. *JAMA*. 2000;283:2810-5.
 7. Iijima K, Hashimoto H, Hashimoto M, Son BK, Ota H, Ogawa S et al. Aortic arch calcification detectable on chest X-ray is a strong independent predictor of cardiovascular events beyond traditional risk factors. *Atherosclerosis*. 2010;210:137-44.
 8. Amarenco P, Cohen A, Tzourio C, Bertrand B, Hommel M, Besson G et al. Atherosclerotic disease of the aortic arch and the risk of ischemic stroke. *N Engl J Med*. 1994;331:1474-9.
 9. Butcovan D, Mocanu V, Baran D, Ciurescu D, Tinica G. Assessment of vulnerable and unstable carotid atherosclerotic plaques on endarterectomy specimens. *Exp Ther Med*. 2016;11:2028-32.
 10. Yilmaz A, Akpınar E, Topcuoglu MA, Arsava EM. Clinical and imaging features associated with intracranial internal carotid artery calcifications in patients with ischemic stroke. *Neuroradiology*. 2015;57:501-6.
 11. Silvennoinen HM, Ikonen S, Soenne L, Railo M, Valanne L. CT angiographic analysis of carotid artery stenosis: comparison of manual assessment, semiautomatic vessel analysis, and digital subtraction angiography. *AJNR Am J Neuroradiol*. 2007;28:97-103.
 12. Lell MM, Anders K, Uder M, Klotz E, Ditt H, Vega-Higuera F, Boskamp T, Bautz WA, Tomandl BF. New techniques in CT angiography. *Radiographics*. 2006;26:45-62.
 13. Odink AE, van der Lugt A, Hofman A, Hunink MG, Breteler MM, Krestin GP et al. Association between calcification in the coronary arteries, aortic arch and carotid arteries: the Rotterdam study. *Atherosclerosis*. 2007;193:408-13.
 14. Adar A, Erkan H, Gokdeniz T, Karadeniz A, Cavusoglu IG, Onalan O. Aortic arch calcification is strongly associated with coronary artery calcification. *Vasa*. 2015;44:106-14.
 15. Bugnicourt JM, Chillon JM, Massy ZA, Canaple S, Lamy C, Deramond H et al. High prevalence of intracranial artery calcification in stroke patients with CKD: a retrospective study. *Clin J Am Soc Nephrol*. 2009;4:284-90.
 16. Shaalan WE, Cheng H, Gewertz B, McKinsey JF, Schwartz LB, Katz D et al. Degree of carotid plaque calcification in relation to symptomatic outcome and plaque inflammation. *J Vasc Surg*. 2004;40:262-9.
 17. Nandalur KR, Baskurt E, Hagspiel KD, Finch M, Phillips CD, Bollampally SR et al. Carotid artery calcification on CT may independently predict stroke risk. *AJR Am J Roentgenol*. 2006;186:547-52.
 18. Xu L, Jiang CQ, Lam TH, Thomas GN, Zhang WS, Cheng KK. Aortic arch calcification and vascular disease: The Guangzhou biobank cohort study. *Cardiology*. 2010;117:260-4.