

■ Case Report

Evaluation of EMG activities of masticatory muscles after reestablishment of vertical dimension in patients with worn dentition: A case series

Diş aşınması olan hastalarda dikey boyutun yeniden yapılandırılması sonrasında çiğneme kaslarının EMG aktivitesinin değerlendirilmesi: Vaka Serisi

 Elif Didem Demirdag¹,  Ayse Canan Adam Erden²,  Sila Burcu Ozer Yagci³,  Duygu Karakis^{3*}

¹Department of Prosthodontics, Faculty of Dentistry, Special Clinic, Ankara, Turkey,

²Clinician, Dentart Dental Clinics, Ankara, Turkey,

³Department of Prosthodontics, Faculty of Dentistry, Gazi University, Ankara, Turkey.

Abstract

Management of the patient with worn dentition has been required the reestablishment of occlusal vertical dimension and comprehensive treatment planning for each case. In the present study, the effect of increased occlusal vertical dimension with dental restoration on the EMG activities and functional indices of masticatory muscles have been evaluated. The rehabilitation of three patients with worn dentition was presented. Before and after the restorative treatment, EMG recordings were taken and the activity index and asymmetry index were measured. The functional indices have been found more related to occlusal contact stability.

Keywords: bruxism, electromyography, occlusal vertical dimension, activity and asymmetry index, masticatory muscles

Corresponding Author*: Duygu Karakis, Department of Prosthodontics Faculty of Dentistry

Gazi University, Ankara, Turkey.

E-mail: dtduygukc@hotmail.com

Orcid: 0000-0001-9976-8797

Doi: 10.18663/tjcl.1382154

Received: 30.10.2023 accepted: 17.11.2023

Öz

Aşınmış diş yapısına sahip hastanın tedavisi, oklüzal dikey boyutun yeniden oluşturulmasını ve her bir vaka için kapsamlı tedavi planlamasını gerektirir. Bu çalışmada diş restorasyonu ile artan oklüzal dikey boyutun çiğneme kaslarının EMG aktiviteleri ve fonksiyonel indeksleri üzerindeki etkisi değerlendirildi. Dişlerinde aşınma olan üç hastanın rehabilitasyonu sunuldu. Restoratif tedavi öncesi ve sonrasında EMG kayıtları alınarak aktivite indeksi ve asimetri indeksi ölçüldü. Fonksiyonel indekslerin oklüzal temas stabilitesi ile daha fazla ilişkili olduğu bulunmuştur.

Anahtar Kelimeler: Bruksizm, elektromiyografi, oklüzal vertikal boyut, aktivite ve asimetri indeksi, çiğneme kasları

Introduction

Occlusal wear has mostly been consisting of the contribution of attrition, erosion, abrasion and parafunctional habits. In patient with excessive wear, esthetic appearance particularly for anterior teeth become a problem. The rehabilitation of these patients with restoration required the reestablishment of occlusal vertical dimension (OVD) [1].

Management of patients with worn dentition requires a careful and comprehensive treatment plan. Depending on the degree of tooth wear, treatment options can change from the range of the placement of bonded composite restoration to full mouth restoration [2]. Diagnostic wax up casts provide detailed information for the desired aesthetics and the determination of the amount of distance to increase and to discuss the treatment options. Adaptation of newly formed OVD confirmed with a diagnostic splint or provisional prosthesis [3]. The best OVD increase has been performed at the patients' satisfied esthetic desires with the most conservative approach [4].

The jaw muscles are the primary determinant of vertical dimension [5]. There is an important relationship between the jaw muscles and the maxillo-mandibular relationship that an increase in OVD leads to the stretching of jaw closing muscles and has a more direct effect on vertically oriented muscle fibers [6]. To evaluate and observe the electro-physiological behavior of the muscles surface electromyography (EMG) is widely used in dentistry [7,8,9]. EMG is a non-invasive and useful assessment of the electrical activity of muscles at rest and during muscle contraction [10-11]. The symmetry of EMG activity between the right and left side may be an indicator of the structural or functional disorders of the stomatognathic system [7]. The activity indices (Aci) indicate the ratio of one muscle group to the other that is used to evaluate the participation of the masseter muscle (MM) and temporalis anterior muscle (TAM) in the clenching activity [7]. The asymmetry index (Asi) determines ratios between the right and left sides that are used

to estimate the activity balance for each muscle pair [7]. In the presence of pain [13], changed occlusion parameters [14], or temporomandibular disorders (TMDs) [15], masticatory muscles present abnormal activity patterns [9]. The functional indices provide the evaluation of the integrated EMG activity analysis of masticatory muscles. Therefore, any particular change in functional indices ratios can be related to an abnormal pattern of masticatory muscle activity and an early sign of disturbance [12]. In addition, the functional indices of masticatory muscles could be a useful tool to determine functional improvement and to observe the effects of applied treatment.

There are many studies related to the OVD increase [1-4]. Some authors supposed that the alteration of OVD may damage the physiology and the functional status of the masticatory system and temporomandibular joint (TMJ) structures [16,17], on the other hand, others reported that these symptoms are temporary [16,18,19]. In the literature, there are no studies about the effect of increased OVD on the functional indices of masticatory muscles. Therefore, in the present study, we aimed to investigate the effect of increased OVD with dental restoration on the EMG activities and functional indices of masticatory muscles.

EMG activity recording procedure

Before the start of the restorative treatment EMG recordings were taken from patients. EMG recordings of the MM and TAM were performed in the resting and clenching activity at the maximum intercuspal position. EMG recordings were performed with a BioEMG III (BioPAK, BioResearch Associates Inc., Milwaukee, WI, USA) EMG amplifier connected to a PC running Windows (Microsoft, Redmond, WA, USA) and the BioPAK software program. The signals of EMG recordings were graphically viewed on the computer screen. The eight channel amplifier had a bandwidth of 30-1000 Hz and an input impedance of >100 MU. EMG activity was recorded bilaterally in microvolts (mV) with bipolar electrodes (BioFlex, BioResearch). Before placing the

electrodes on the muscle, the muscles were palpated by using fingers. Initially, the palpation of the MM and TA was performed to define the placement of the electrodes that were positioned parallel to the direction of the muscle fibers. Before the electrode placement, the skin was cleaned with 95 % alcohol. A disposable ground electrode was placed on the neck.

First EMG recordings of patients performed in the rest position. The patients sat in an upright position parallel to the Frankfurt Horizontal Plane and were instructed not to contact teeth and to release the mandibula in the rest position. In the rest position the EMG activities of muscles (MMR: Right masseter muscle; MML: Left masseter muscle; TAR: Right temporalis anterior; TAL: Left temporalis anterior) were recorded. Then in the intercuspal position, the patients performed 3 clenches in maximum voluntary contraction for 1-3 seconds, and the mean values of these 3 clenches were recorded as the maximum contraction values of each muscle. After 8 weeks of the completion of restorative treatment, all records were repeated in the same procedures.

The calculation of activity and asymmetry index of muscles

Acl and Asl were measured from the RMS (Root means Square) (20). Acl are used to evaluate the participation of MM and TAM during clenching activity. The Acl is used to measure the ratio of one muscle group to the other [7]. Acl values are set between -100 and +100. The negative (-) values show the predominance of the TAM and the positive (+) values suggest an MM advantage. Acl values range between +100% and -100%, with +100% indicating the involvement of only the MM during activity and -100% of only the TA [20].

$$Acl = (RMS\ MM - RMS\ TA) / (RMS\ MM + RMS\ TA) \times 100$$

The Asl was calculated to determine ratios between the right and left sides based on the equation by Naeije (1989) [20]. This index has been used to estimate the activity balance for each muscle pair. If the muscle activation level is fully symmetrical Asl is 0%, while the full asymmetry corresponds to 100%. The formula is:

$$Asymmetry\ index\ (Asl) = (RMS\ right - left\ RMS) / (RMS\ right + left\ RMS) * 100$$

Case Presentations

Case 1

A 64-year-old female patient applied to the prosthodontic clinics with the complaint of worn dentition, poor esthetic and, difficulty in masticatory function. Medical and dental history was obtained and the patient gave a history of bruxism. On

extraoral clinical examination, a reduced lower face height was noted. Dental examination showed a generalized worn dentition, diastemas in anterior teeth, and missed teeth numbers as; 24,26,35,36,37,45,46 (Figure 1). TMJ evaluation revealed no history of dysfunction, no joint sound, and pathology. Masticatory muscle, and head and neck muscles were normal at palpation. The mandibular range of the motion and jaw opening were within the normal limits.

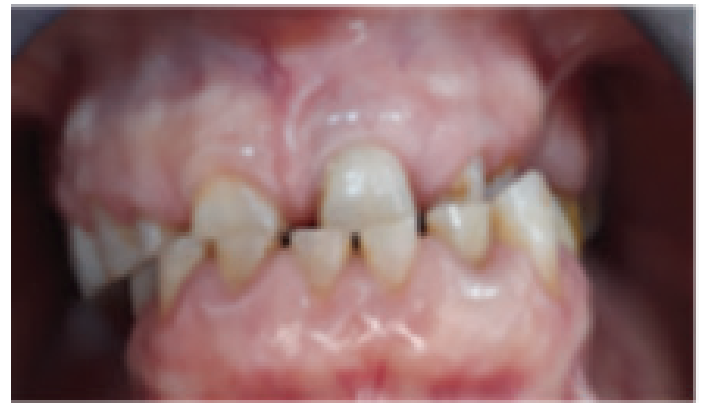

Figure 1. Intraoral view before treatment

To determine the amount of OVD increase a mock up procedure was performed (Figure 2). The impression of upper and lower dentition was taken with hydrocolloid impression material (Hydrocolor 5, Zhermack, Badia Polesine, Italy). Then facebow record (UTS Face-bow, Ivoclar Vivadent, Austria) was performed and casts were mounted on an articulator (Stratos 300, Ivoclar-Vivadent, Austria). Then, mock up waxing was performed and trained in the patient's mouth. A total 6 mm OVD increase was detected in facial measurement (distance between nose and chin tip) with the Niswonger method. Actual increase was determined as 4 mm in the anterior teeth and the incisal guidance of the articulator pin was set.

After the esthetic and functional evaluation of mock up restoration, the patient was informed about the possible restorative treatment options, and also the advantages, disadvantages, and possible risks of the treatment options. The restorative treatment involves the restoration of upper and lower teeth with increasing OVD. Upper fixed restorations (21,22,23, 24,25,26,27,11,12,13,14,15,16,17) and lower fixed restorations (31,32,33,34,41,42,43,44,47) with the removable partial denture (35,36,37,45,46) were planned for the rehabilitation of patients. For the adaptation of the patient to altered OVD, a self-cured acrylic resin (Panacryl, Arma Dental, Istanbul, Turkey) occlusal splint was produced with bilateral anterior and posterior simultaneous contacts in centric relation (Figure 3). The patient

was instructed to wear a splint for 24 hours, for 4 weeks. After the four-week adaptation period, no muscle tenderness and temporomandibular discomfort were reported. The occlusal splint was kept to take bite registration at preparation procedures. After preparation of all anterior and posterior teeth final impressions were made with polyvinylsiloxane impression material (Optosil Comfort/Xantopren VL Plus, Heraeus Kulzer, Hanau, Germany) and provisional restorations were fabricated using a self-cured acrylic resin (Figure 4).

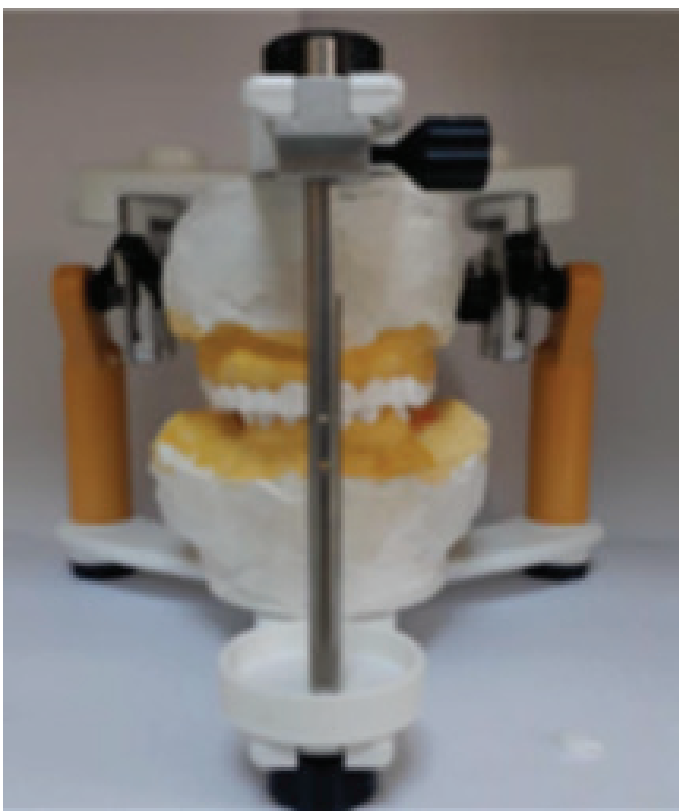


Figure 2. Diagnostic wax up

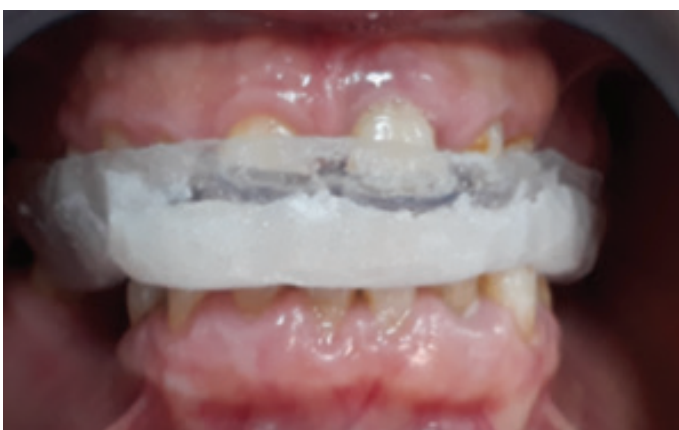

Figure 3. Maxillary occlusal splint

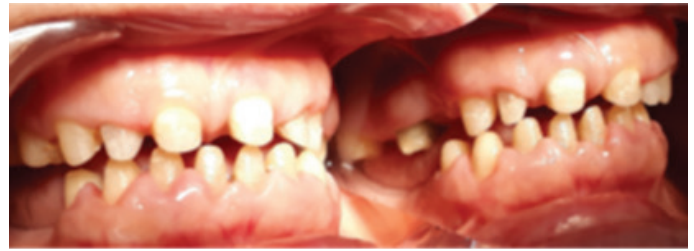

Figure 4. Intraoral view after preparation of teeth

In the following sessions, metal substructures of fixed restorations (Kera N, Dr.-Konrad-Wiegand-Str. 9 - D-63939 Wörth, Germany) were performed (Figure 5) and the trial of ceramic restoration (Ceramco 3, Dentsply, Dreieich, Germany) was accomplished with minor occlusal adjustments. The final restorations were glazed and cemented with zinc polycarboxylate cement (Adhesor-Carbofine, Spofa-Dental, Germany). At the session three days later, a second impression of the mandibular removable denture was taken with alginate impression material. The metal framework of the lower denture and tooth alignment was performed in the following sessions. Then acrylic removable mandibular denture was adjusted in the patient's mouth. The occlusal scheme of definitive restoration was designed as group functional occlusion (Figure 6). The patient was advised to maintain oral hygiene and schedule regular check-ups every six months. Written informed consent was obtained from the patient for the publication of her data.

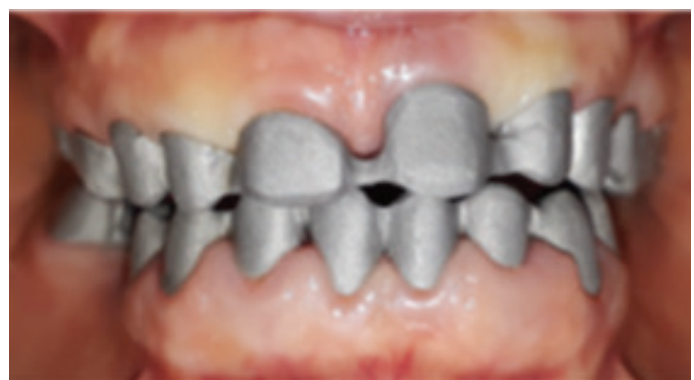

Figure 5. Metal substructure

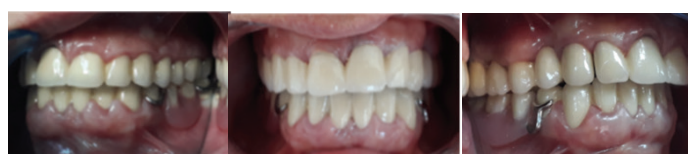

Figure 6. Intraoral view of final restoration

Case 2

A 77-year-old male patient was referred to the clinic with the chief complaint of poor aesthetics, a generalized worn dentition, and missing teeth (12,13,16,17,46) (Figure 7). The patient has a history of bruxism and is wearing a night guard to prevent attrition of dentition. In the periodontal examination, generalized stainings and calculus were observed on teeth. Supragingival scaling was performed to remove plaque and calculus and then polishing was applied. TMJ evaluation showed no history of dysfunction, no joint sound, and pathology. Masticatory, head and neck muscles were normal to palpation. The mandibular range of the motion and jaw opening were within the normal limits.

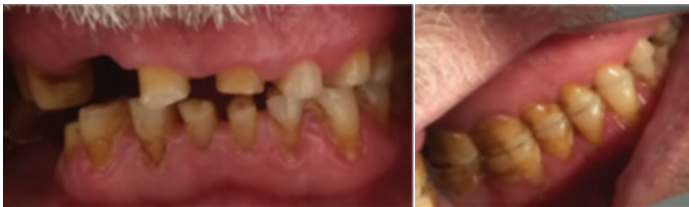

Figure 7. Intraoral view before treatment

As there was not enough space for the rehabilitation of missing anterior teeth with restoration, we needed to increase OVD to create a space for dental materials. To determine the amount of increase a mock up procedure was performed. The impression of upper and lower dentition was taken with hydrocolloid impression material (Hydrocolor 5, Zhermack, Zhermack SpA., Badia Polesine, Italy). Then facebow record (UTS Facebow, Ivoclar Vivadent, Austria) was performed and casts were mounted on an articulator (Stratos 300, Ivoclar-Vivadent, Austria) with a facebow record (Figure 8). Mock up waxing was performed with the 4 mm increase of anterior dentition (Figure 9). The prepared mock up waxing was trained in the patient's mouth and a 6 mm OVD increase was detected in facial measurement (distance between nose and chin tip) with the Niswonger method. The patient was informed about the possible restorative treatment options. Upper fixed restorations (11,12,13,14,15,21,22,23,24,25,26) with removable partial denture (16,17) and lower fixed restorations (31,32,33,34,35,36, 37,41,42,43,44,45,46,47) with increasing OVD were planned for the rehabilitation of patients. A self-cured acrylic resin (Panacryl, Arma Dental, Istanbul, Turkey) occlusal splint was performed to evaluate the adaptation of the patient to the increased OVD. The patient was instructed to wear a splint for 24 hours for 4 weeks. At the end of the adaptation period, no muscle tenderness and temporomandibular discomfort were reported

by the patient. The preparation of all anterior and posterior teeth (Figure 10) was completed, and second impressions were made with polyvinylsiloxane impression material (Optosil Comfort/Xantopren VL Plus, Heraeus Kulzer, Hanau, Germany) and provisional self-cured acrylic resin restorations were inserted. In the next sessions four days the metal substructures (Kera N, Germany) and ceramics (Ceramco 3, Dentsply, Dreieich, Germany) of fixed restorations were adjusted (Figure 11). The definitive restorations were glazed and cemented with zinc polycarboxylate cement (Adhesor-Carbofine, Spofa-Dental, Germany). The group functional occlusion was established. The patient was satisfied with the improved aesthetics and also the function of dentition. Written informed consent was obtained from the patient for the publication of his data.



Figure 8. Diagnostic wax up

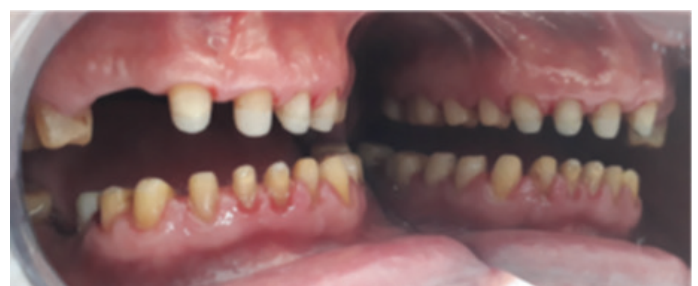

Figure 9. Intraoral view after preparation of teeth

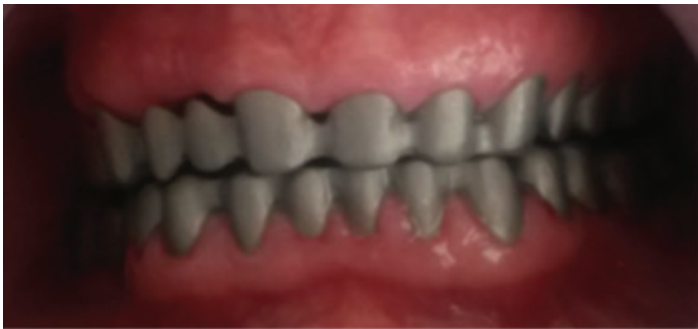

Figure 10. Metal substructure

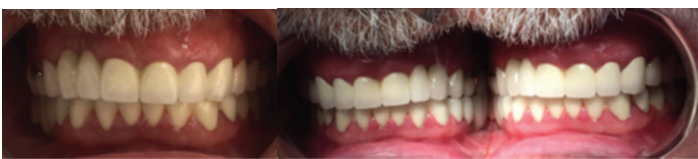

Figure 11. Intraoral view of final restoration

Case 3

A 62-year-old male patient applied to the prosthodontic clinics with complaints of poor aesthetics of anterior teeth. The patient had an apparent worn upper anterior teeth with missing teeth (16,26,36,47) (Figure 12). The plaque accumulation has been examined. The patient did not have any dysfunction in the TMJ evaluation. For the rehabilitation of worn anterior teeth and rehabilitation of posterior missing teeth, upper full mouth restoration (11,12,13,14,15,16,21,22,23,24,25,26,27) and fixed partial bridge restorations for lower missing teeth were planned (45-46-47, 35,36,37). The patient was informed about the potential restorative treatment option and all the advantages, disadvantages and possible risks of treatment have been explained.

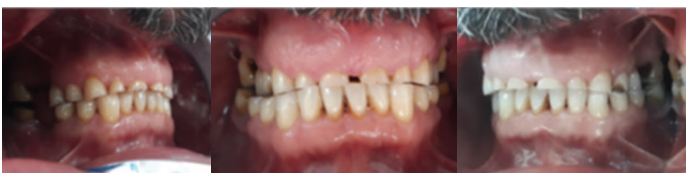

Figure 12. Intraoral view before treatment

To provide enough space for the dental restoration material in the anterior upper teeth, we need to increase the OVD. A mock up waxing was performed (Figure 13). The impression of upper and lower dentition was taken with hydrochloride impression material and facebow registration (UTS Facebow, Ivoclar Vivadent, Austria) was performed. The casts were mounted on an articulator (Stratos 300, Ivoclar-Vivadent, Austria). The mock-up waxing was tried on the patient and it

was decided that the OVD should be increased by 4 mm in the anterior teeth. Following the aesthetic approval by the patient, to evaluate the neuromuscular adaptation to the planned OVD increase, an occlusal splint was prepared (Figure 14). This was used by him for 4 weeks and finally, no muscle tenderness and temporomandibular discomfort were noted. After the functional adaptation to the new OVD, upper and lower teeth were prepared to receive full metal ceramic crowns. The second impressions were obtained and provisional auto-polymerized acrylic resin restorations were prepared and placed. Then, definitive metal (Kera N, Germany) supported ceramic restorations (Ceramco 3, Dentsply, Dreieich, Germany) were fabricated and adjusted in canine guided occlusion (Figure 15). After the glazing procedure, the restorations were cemented (Figure 16). Written informed consent was obtained from the patient for the publication of his data.



Figure 13. Diagnostic wax up

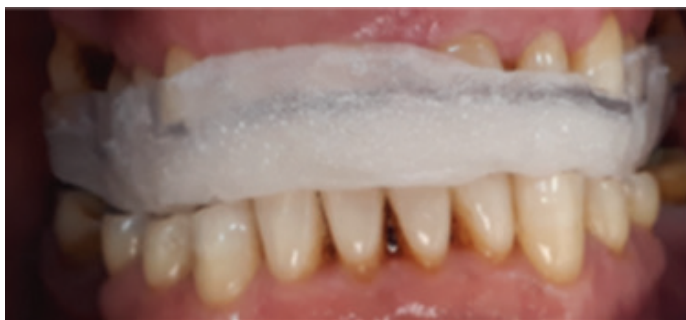

Figure 14. Maxillary occlusal splint

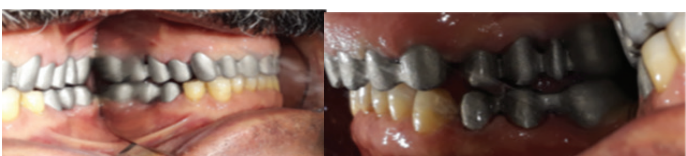

Figure 15. Metal substructure

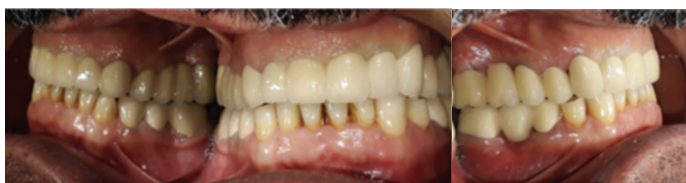

Figure 16. Intraoral view of final restoration

Discussion

The OVD is based on a balance between the hard and soft tissues where any disruption in these components will affect the balance of the forces and result in a change in the form of bony remodeling and/or soft tissue adaptation [5]. As a result of this situation, in the present three case reports patients with the loss of OVD and teeth suffer from the insufficient masticatory efficiency

EMG activity of masticatory muscles is the indicator of masticatory efficiency and is related to the vertical dimension of subjects. In the present study, in the evaluation of the EMG activity of the patients before the restoration of occlusion and OVD, all patients had a normal range of EMG activity in resting, for both masticatory muscle groups (Table 1). However, the functional indices showed impaired balance in the MM and TA activity in three cases (Table 2).

Table 1. Resting EMG activity (mV) of cases before and after treatment.

	Before treatment				After treatment			
	TAR	TAL	MMR	MML	TAR	TAL	MMR	MML
Case 1	1.04	1.32	1.25	0.79	2.76	2.78	1.66	1.22
Case 2	2.05	1.39	1.84	2.74	1.8	2	2.8	2.5
Case 3	1.3	1	1.8	17.6	0.87	0.96	1.28	1.43

Abbreviations: TAR: Right temporalis anterior, TAL: Left temporalis anterior, MMR: Right masseter muscle, MML: Left masseter muscle

Table 2. Activity and asymmetry index values of cases before and after treatment.

	Before treatment				After treatment			
	Activity index		Asymmetry index		Activity index		Asymmetry index	
	TAR-MMR	TAL-MML	TAR-TAL	MMR-MML	TAR-MMR	TAL-MML	TAR-TAL	MMR-MML
Case 1	27	47	66	20	84	96	95	76
Case 2	71	68	79	77	61	78	87	90
Case 3	91	94	49	47	98	70	64	46

Abbreviations: TAR: Right temporalis anterior, TAL: Left temporalis anterior, MMR: Right masseter muscle, MML: Left masseter muscle

The muscle activity pattern of case 1 showed that she has increased EMG activity of MMR. As a result of this predominant MMR activity, there was an increased asymmetry indices of MML and MMR and activity indices in MMR -TAR. After the restoration of occlusion and OVD, all the muscle activity comes to near value of each other which has indicated an increased activity and asymmetry indices values.

In case 2, before treatment, the patient had a relatively increased MML and TAL activity which could be related to the presence and full contact of left side teeth, while there was dis-occlusion on the right side. After the treatment, activity indices didn't show important changes, however, asymmetry indices came to a higher level. It was shown that the re-establishment of occlusion on the left side led to an increase in left side muscles activities.

In case 3, the patient had bruxism and had increased activity in both the MM and TA in clenching. With the restorative treatment of the patient, EMG activities of both muscles decreased, however in the evaluation of asymmetry indices there is still a predominance of EMG activity of MM and TA on the left-side, in the evaluation of activity indices increased activity of MM on the left side was seen.

For all 3 patients before and after the treatment, resting EMG activities were in normal ranges, however when evaluating clenching EMG activity of both muscles there was a decrease after the treatment. Also in functional indices, it was seen that there was an equalization of the balance in the asymmetry and activity indices after the dental restoration.

Manns et al stated that with the increasing of the postural position of the mandibula, the EMG activity of muscles shows a decrease [21]. It has been stated that in the early period the increase of OVD increases the EMG activity of masticatory muscles however after 2 to 3 months, EMG activities of muscles will have returned to the baseline values [22]. With

this result, in the present study one month later after dental restoration presented cases showed a decrease in clenching EMG activity of MM and TA. On the other hand, Widmer et al stated that, two different changes in jaw-closing muscle activity were observed depending on the way the increasing OVD with the freely moving jaw by interocclusal appliance or inter-maxillary fixation by fixed restoration [5]. The increased OVD with appliance appears to lead to the addition of sarcomeres to lengthen the muscle fiber and hypertrophy of the muscle fiber. On the other hand, the increase of OVD with the fixed restoration, leads to an increase in muscle length that results in the formation of new sarcomeres at the ends of the muscle fiber and atrophy of the muscle fibers [5]. In the presented cases the reduced EMG activity of both muscles after restoration could be related to increasing OVD fixed restoration that leads to muscle fiber atrophy.

In all cases, in addition to increasing occlusal vertical dimension, also, occlusion has been restored providing occlusal stability, therefore both of those factors will affect on EMG activity of the anterior temporalis and MM [23]. In many studies, the number of occlusal contacts has been related to the positive correlation of the EMG activity of masticatory muscles [24,25,26]. Among the present cases, the most tooth loss was seen in case 1 with the lack of posterior occlusal support in the mandibula and also after the treatment with the restoration of the missing teeth, the most apparent improvement in functional indices was seen in case 1. This apparent change in the EMG activity of muscles and the functional indices after treatment could be related to ensuring stable occlusal contacts with restoration of dentition. This result was in agreement with the study of Ribeiro et al that the increase in OVD did not alter the electrical activity of the masticatory muscles of asymptomatic participants due to the number of stable occlusal contacts already present [23].

In conclusion, the present clinical reports described the use of occlusal splint to restore occlusal vertical dimension and prosthetic rehabilitation of 3 patients with worn dentition. As a result of the presented 3 cases, it could be stated that functional indices are more related to the occlusal contact stability, however, the EMG activity of related muscles during clenching seems to be more related to the amount of the OVD changing.

Informed consent

Written informed consent was obtained from the patients for publication of this article.

Conflict of Interest

The authors declare no conflict of interest.

Funding

The authors received no financial support for this research.

Authors' Contribution

Elif Didem Demirdağ: Application of treatment and taking records

Ayşe Canan Adam Erden: Application of treatment and taking records

Sıla Burcu Özer Yağcı: Taking records and writing

Duygu Karakış: Desing, writing and reviewing.

References

1. Assis EGR, Aguiar FHB, Pereira R, Velo MMAC, Lima DANL, Giorgi MCC. Re-Establishment of an Occlusal Vertical Dimension: A Case Report. *J Dent Health Oral Disord Ther* 2018; 9: 00336.
2. Young song Mi, Park Ji-Man, Park Eun-Jin. Full mouth rehabilitation of the patient with severely worn dentition: a case report. *J Adv Prosthodont* 2010; 2: 106-110.
3. Moslehifard E, Nikzad S, Geraminpanah F, Mahboub F. Full-mouth rehabilitation of a patient with severely worn dentition and uneven occlusal plane: a clinical report. *J Prosthodont* 2012; 21: 56-64.
4. Lerner J. A systematic approach to full-mouth reconstruction of the severely worn dentition. *Pract Proced Aesthet Dent* 2008; 20: 81-7.
5. Charles G. Widmer. The Effects of Altering Vertical Dimension on the Masticatory Muscles and Temporomandibular Joint. *Semin Orthod* 2002; 8: 155-161.
6. Matano T, Tamai K, Kurokawa T. Adaptation of skeletal muscle in limb lengthening: a light diffraction study on the sarcomere length in situ. *J Orthop Res* 1994; 12: 193-9.
7. Ginszt M, Zielinski G. Novel Functional Indices of Masticatory Muscle Activity. *J Clin Med* 2021; 10: 1440.
8. Lauriti L, Silva PF da C, Politti F et al. Pattern of electromyographic activity in mastication muscles of adolescents with temporomandibular disorder. *J Phys Ther Sci* 2013; 25: 1303-7.
9. Hotta GH, de Oliveira AIS, de Oliveira AS, Pedroni CR. Electromyography and asymmetry index of masticatory muscles in undergraduate students with temporomandibular disorders. *Braz J Oral Sci.* 2015; 14: 176-181.
10. Celinski AI, Cunali RS, Bonotto D, Farias ACD, Cunali PA. Surface electromyography for temporomandibular disorders: systematic review. *Rev Dor.* 2013; 14: 147-150.



11. Hugger S, Schindler HJ, Kordass B, Hugger A. Clinical relevance of surface EMG of the masticatory muscles. (Part 1): Resting activity, maximal and submaximal voluntary contraction, symmetry of EMG activity. *Int J Comput Dent* 2012; 15: 297-314.
12. Zielinski G, Matysik-Wozniak A, Rapa M et al. The Influence of Visual Input on Electromyographic Patterns of Masticatory and Cervical Spine Muscles in Subjects with Myopia. *J Clin Med* 2021; 10: 5376.
13. Chandu A, Suvinen TI, Reade PC, Borromeo GL. The effect of an interocclusal appliance on bite force and masseter electromyography in asymptomatic subjects and patients with temporomandibular pain and dysfunction. *J Oral Rehabil* 2004; 31: 530-7.
14. Scopel V, Alves da Costa GS, Urias D. An electromyographic study of masseter and anterior temporalis muscles in extra-articular myogenous TMJ pain patients compared to an asymptomatic and normal population. *Cranio J Craniomandib Pract* 2005; 23: 194-203.
15. Rodrigues-Bigaton D, Berni KCS, Almeida AFN, Silva MT. Activity and asymmetry index of masticatory muscles in women with and without dysfunction temporomandibular. *Electromyogr Clin Neurophysiol*. 2010; 50: 333-8.
16. JAbduo, KLyons. Clinical considerations for increasing occlusal vertical dimension: a review. *Aust Dent J* 2012; 57: 2-10.
17. Turner KA, Missirlan DM. Restoration of the extremely worn dentition. *J Prosthet Dent* 1984; 52: 467-74.
18. Ormianer Z, Gross M. A 2-year follow-up of mandibular posture following an increase in occlusal vertical dimension beyond the clinical rest position with fixed restorations. *J Oral Rehabil* 1998; 25: 877-83.
19. Carlsson GE, Ingervall B, Kocak G. Effect of increasing vertical dimension on the masticatory system in subjects with natural teeth. *J Prosthet Dent* 1979; 41: 284-9.
20. Naeije M, McCarroll RS, Weijs WA. Electromyographic activity of the human masticatory muscles during submaximal clenching in the inter-cuspal position. *J Oral Rehabil*. 1989; 16: 63-70.
21. Manns A, Miralles R, Cumsille F. Influence of vertical dimension on masseter muscle electromyographic activity in patients with mandibular dysfunction. *J Prosthet Dent* 1985; 53: 243-7.
22. Bloom D, Padayachy J. Increasing occlusal vertical dimension-Why, when and how. *Br Dent J* 2006; 200: 251-6.
23. Ribeiro AB, Pita MS, Ribeiro AB, Garcia AR, Junqueira Zuim PR. Effect of short-term increase in occlusal vertical dimension on masticatory muscle electrical activities and pressure-to-pain threshold: A crossover clinical study. *J Prosthet Dent* 2022; 128: 970-6.
24. Bakke M, Michler L, Möller E. Occlusal control of mandibular elevator muscles. *Scand J Dent Res* 1992; 100: 284-291.
25. MacDonald JWC, Hannam AG. Relationship between occlusal contacts and jaw-closing muscle activity during tooth clenching: Part 1. *J Prosthet Dent* 1984; 52: 718-29.
26. Hidaka O, Iwasaki M, Saito M, Morimoto T. Influence of clenching intensity on bite force balance, occlusal contact area, and average bite pressure. *J Dent Res* 1999; 78: 1336-44.