



Idiopathic Granulomatous Mastitis Mimicking Breast Cancer: A Case Report Meme Kanserini Taklit Eden İdiyopatik Granülomatöz Mastit: Olgu Sunumu

Emine Sevcan Ata¹, Hicret Biber¹, Melis Baykara Uluşan¹

¹ University Health Sciences, İstanbul Training and Research Hospital, Department of Radiology, İstanbul, Turkey

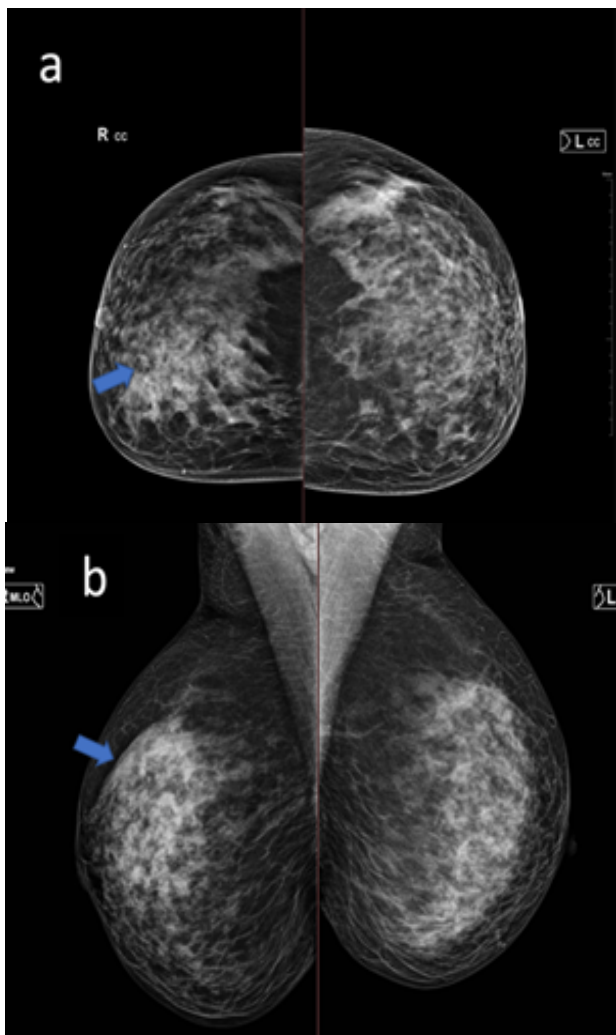


Figure 1. a) CC (craniocaudal) b) MLO (Mediolateral oblique) digital mammograms show an ill-defined asymmetric parenchymal density completely filling the upper inner quadrant of the right breast (arrows). No microcalcifications were observed.

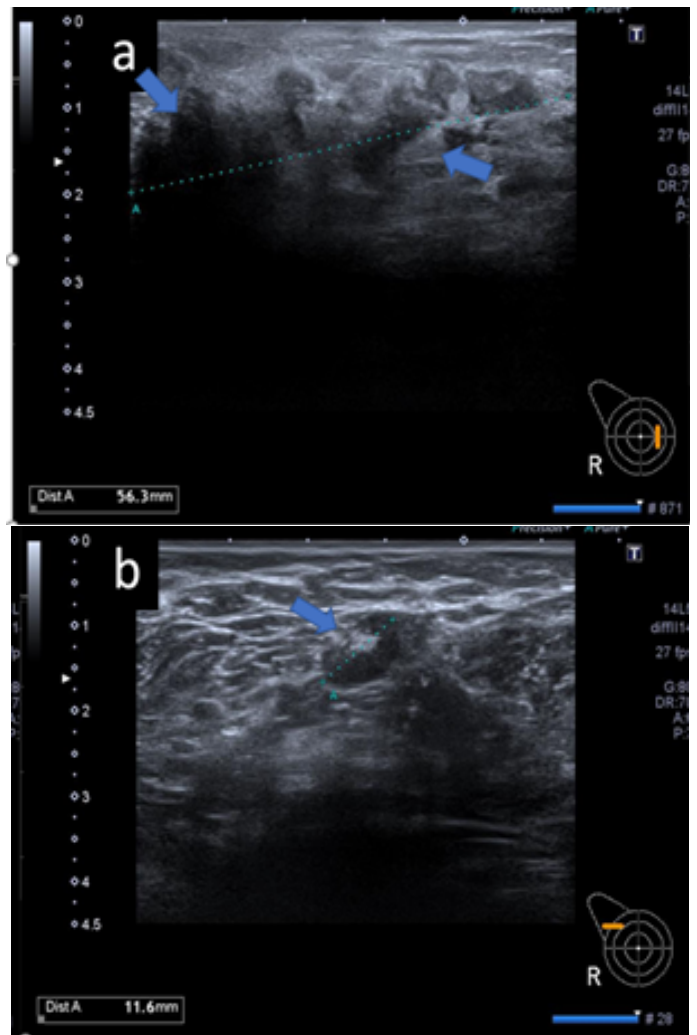


Figure 2. a) Ultrasound (US) image of the inner right shows a large non-mass heterogeneous area with distorted contour containing atypical dense content (arrows) b) Sonogram shows cortical thickening of the lymph node (arrow).

Corresponding Author: Emine Sevcan Ata, University Health Sciences, İstanbul Training and Research Hospital, Department of Radiology, İstanbul, Turkey **Email:** e.s.ata@hotmail.com
Cite this article as: Ata ES, Biber H, Uluşan MB. Idiopathic Granulomatous Mastitis Mimicking Breast Cancer: A Case Report. JAMER 2024;9(1):33-35.

Received: 07.11.2023
Accepted: 24.02.2024
Online Published: 19.04.2024

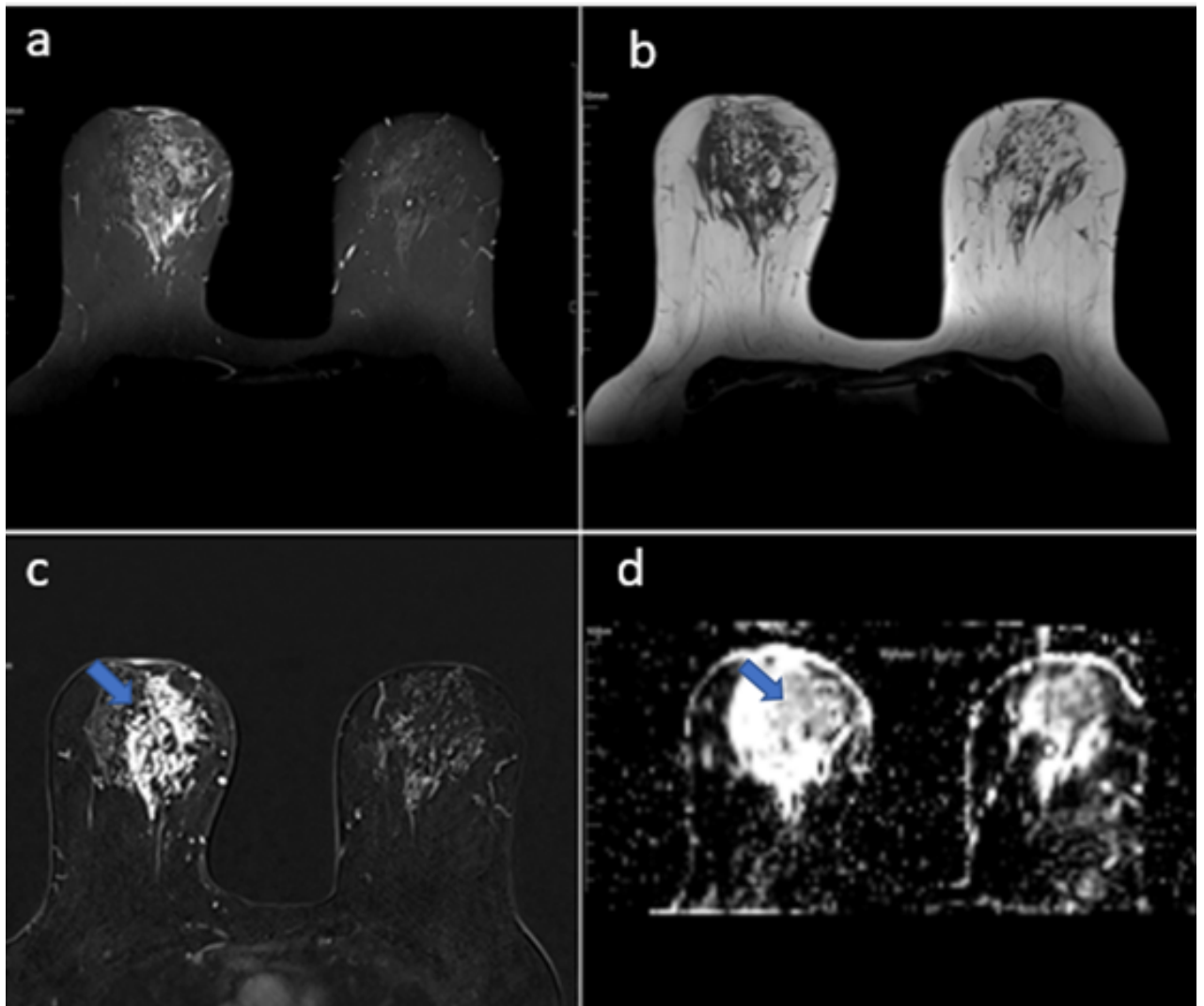


Figure 3. a) STIR axial b) T1-Weighted axial c) Contrast enhanced fat-suppressed T1W axial MR images; blue arrows show heterogeneous clustered intensely enhanced non-mass area filling whole upper inner quadrant of the right breast and retro areolar region. d) Diffusion restriction on diffusion-weighted imaging (arrows).

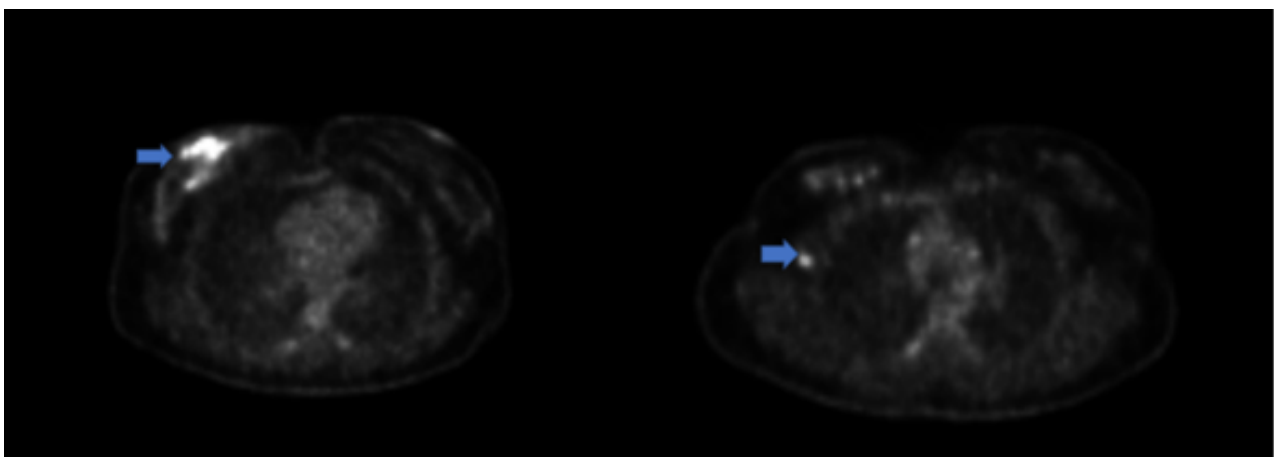


Figure 4. Hypermetabolic nodular area covering the upper middle zone of the right breast on 18F-FDG PET/CT images, with no significant mass formation. Additionally, a hypermetabolic axillary lymph node is observed, which is indicative of a primary malignant breast tumor (arrows).

A 35-year-old female presented with complaints of stiffness and pain in her right breast. She had intermittent, spontaneous, clear nipple discharge. Upon examination, a hard lump was palpated in the upper inner quadrant of the right breast. There were no signs of infection, such as erythema or increased temperature. Given the clinical presentation and imaging findings (mammography: Fig 1 and ultrasonography: Fig 2), malignancy and infectious pathologies were suspected. Ultrasound-guided core needle biopsy was performed. The pathology was reported as chronic granulomatous mastitis, and the fine needle aspiration biopsy on the axilla revealed benign cytology.

Idiopathic Granulomatous Mastitis (IGM) is a rare, chronic inflammatory disease that is resistant and shows a wide range of manifestations on radiological imaging. IGM was first described as a distinct clinical entity by Kessler and Wolloch in 1972. Generally, it affects young women of reproductive age, mostly during the five years following childbirth. Etiology is still unknown; many factors, mainly including hormonal factors, are proposed (1). Histologic criteria for granulomatous mastitis focus on lobules, excluding infections and specific causes. According to the concept of mammary duct-associated inflammatory disease sequence, certain conditions such as pregnancy, breastfeeding, and drug-induced hyperprolactinemia or galactorrhea might be associated with an increased risk of IGM.

A definite diagnosis is through by histopathological evaluation, and radiology has a crucial role for the diagnostic process. Mammography, ultrasonography, and Magnetic resonance imaging are commonly used for diagnosis. However, due to their wide spectrum and low sensitivity, interpreting the findings can be challenging (2). IGM presents similar clinical signs and symptoms to breast carcinoma. Irregular hypoechoic mass with multiple tubular extensions, asymmetry on mammograms, multiple heterogeneous areas with ring-like enhancement, regional heterogeneous non-mass enhancements (NMEs), or enhanced masses are the most common findings. Skin thickening, parenchymal distortion, nipple retraction, and axillary lymphadenopathy may also be observed (3).

Idiopathic Granulomatous Mastitis (IGM) is a rare chronic inflammatory benign disease of the breast with an unknown etiology. The cause may be the autoimmune process, abnormal hormone levels, infection, or lactation. The most common clinical presentation is a unilateral, palpable breast lump, and nipple retraction of the overlying skin.

Radiologically and clinically, it may mimic breast carcinoma. This case report discusses IGM mimicking breast cancer.

Due to all these findings, it is challenging to differentiate malignancy clinically and radiologically (4). In our case, radiological findings were also perplexing. MRI showed a heterogeneous clustered intensely enhanced non-mass area (Fig. 3), which was suspected to be malignant. On PET-CT imaging, a hypermetabolic nodular mass was identified, which was compatible with a primary malignant breast tumor (Fig. 4). After a US-guided biopsy, IGM was confirmed. Then the patient was started on prednisolone treatment and a regression was observed.

Informed Consent: Written informed consent was obtained from the patient for the publication of the study

Conflict of Interest: No conflict of interest was declared by the authors.

Financial Disclosure: The authors declared that this study has no financial support.

REFERENCES

1. Altintoprak F, Kivilcim T, Ozkan OV. Aetiology of idiopathic granulomatous mastitis. *World J Clin Cases.* 2014 Dec 16; 2(12):852-858.
2. Çalış H, Kilitçi A. Granulomatous mastitis concurrence with breast cancer. *Eur J Breast Health.* 2018 Jan 1; 14(1):58-60.
3. Severs FJ, Guevara L, Sam KQ, Roark A, Benveniste AP, Ebuoma L. Granulomatous mastitis of the breast: A malicious mimic. *Journal of Diagnostic Medical Sonography.* 2018; 34(3):223-228.
4. Soylu Boy FN, Esen Icten G, Kayadibi Y, Tasdelen I, Alver D. Idiopathic granulomatous mastitis or breast cancer? A comparative MRI study in patients presenting with non-mass enhancement. *Diagnostics (Basel).* 2023 Apr 19;13(8):1475.