



UNILATERAL FACIAL NERVE PARALYSIS CAUSED BY DENTAL INFECTION*

DENTAL ENFEKSİYON NEDENİ İLE MEYDANA GELEN TEK TARAFLI FASİYAL SİNİR PARALİZİ*

Yrd. Doç. Dr.Zeynep Burçin GÖNEN*
Doç. Dr. Nükhet KÜTÜK**

Dt. Canay YILMAZ ASAN **
Prof. Dr.Alper ALKAN**

Makale Kodu/Article code: 2262
Makale Gönderilme tarihi: 07.05.2015
Kabul Tarihi: 09.07.2015

ABSTRACT

Peripheral facial nerve paralysis is the most common form of motor cranial neuropathy. The most common cause is idiopathic facial nerve palsy (Bell's palsy) and viral agents, trauma, vascular ischemia, autoimmune inflammatory syndromes, intracranial lesions or infection are the offending factors .

Peripheral facial nerve paralysis results in inability to control facial muscles on the affected side because of the involvement of the facial nerve, which supplies motor response for the muscles of facial expression.

Depending on the location of the involved brunch, an expressionless appearance during smiling, inability to close or wink the eye or close the mouth, droop of the eyebrow or the corner of the mouth, numbness or pain around the ear, temple, mastoid, or angle of the mandible, altered sense of taste, hypersensitivity to sounds, or decreased tearing may be seen.

Treatment depends on clinical examination and appropriate diagnostic tests . However, appropriate treatment is controversial in the literature varying from acupuncture, steroids, antiviral agents , botulinum toxin to surgical techniques . Regardless of the therapy employed, supportive measures should be taken as soon as possible.

We present here a case of unilateral facial paralysis caused by the dental infection of upper left second premolar.

Key Words: Facial, Paralysis, Bell's Palsy, Infection

ÖZ

Periferik fasiyal sinir paralizi, motor kranial nöropatiler içinde en yaygın olanıdır. Bell palsi olarak bilinen idiopatik fasiyal paralizi daha yaygın olmakla birlikte, viral ajanlar, travma, damarsal iskemi, otoimmün inflamatuvar sendromlar, intrakranial lezyonlar veya enfeksiyonlar etiyolojik faktörler arasındadır.

Mimik kaslarının motor hareketlerinden sorumlu fasiyal sinirin tutulumu sonucunda ,periferik sinir paralizi meydana gelir ve bu durum yüz kaslarının kontrolünde yetersizlikle sonuçlanmaktadır. Bu durumda yüzde karakteristik bir şekil bozukluğu gözlenir.

Sinirin etkilenen dalına bağlı olarak, gülme sırasında ifadesiz bir görüntü oluşur. Hasta gözünü kapatamaz veya göz kırpmaya hareketlerini yerine getiremez. Ağız köşesinin ve/veya etkilenen taraftaki kaşın sarktığı görülür. Kulak etrafında, şakak kısmında, mastoid bölgede veya mandibula köşesinde ağrı ve hassasiyet meydana gelir. Tat alma değişiklikleriyle birlikte seslere karşı hassasiyet ve göz yaşarması izlenebilir. Bu belirtiler hastalarda fonksiyonel, estetik, sosyal ve psikolojik problemlere yol açmaktadır.

Fasiyal sinir paralizinin tedavisi, gerekli klinik muayeneler ve teşhise yardımcı testler yapılarak sağlanır. Fasiyal sinir paralizinin tedavisi tartışmalı olup literatürde bir çok farklı tedavi yöntemlerinden bahsedilmektedir. Akupunktur, steroid tedavisi, antiviral ajanların kullanılması, botulinum toksin enjeksiyonu ve cerrahi teknikler bu yöntemler arasında sayılabilir. Tedavi seçeneği ne olursa olsun, önemli olan en kısa sürede destekleyici tedaviye başlanmasıdır.

Bu çalışmada sol üst premolar diştten kaynaklanan dental enfeksiyon sonucunda fasiyal paralizi gelişen bir olgu bildirilmektedir.

Anahtar kelimeler: Fasiyal paralizi, Bell paralizi, Enfeksiyon

* Erciyes Üniversitesi, Genom ve Kök Hücre Merkezi/ Diş Hekimliği Fakültesi, Ağız Diş ve Çene Cerrahisi AD

** Erciyes Üniversitesi, Diş Hekimliği Fakültesi, Ağız, Diş ve Çene Cerrahisi AD

* **This study was presented in 7th Oral and Maxillofacial Surgery Society-ACBID Congress, 29 May-2 June, 2013, Antalya, Turkey, as a poster presentation**



INTRODUCTION

Peripheral facial nerve paralysis is the most common form of motor cranial neuropathy. The most common cause is idiopathic facial nerve palsy (Bell's palsy) ^{1, 2}, and viral agents, trauma, vascular ischemia, autoimmune inflammatory syndromes, intracranial lesions or infection are the offending factors.³

Peripheral facial nerve paralysis results in inability to control facial muscles on the affected side^{2,3} because of the involvement of the facial nerve, which supplies motor response for the muscles of facial expression. The inability to control these muscles gives a characteristic facial distortion to the patient.⁴ Depending on the location of the involved branch, an expressionless appearance during smiling, inability to close or wink the eye or close the mouth, droop of the eyebrow or the corner of the mouth, numbness or pain around the ear, temple, mastoid, or angle of the mandible, altered sense of taste, hypersensitivity to sounds, or decreased tearing may be seen.⁵⁻⁷ These symptoms may impose devastating cosmetic, functional, social, and psychological effects on an affected patient.⁸

Treatment depends on clinical examination, understanding of facial nerve anatomy, and appropriate diagnostic tests.⁹⁻¹¹ However, appropriate treatment is controversial in the literature varying from acupuncture, steroids,¹² antiviral agents,¹³ botulinium toxin¹⁴ to surgical techniques.⁷ Regardless of the therapy employed, supportive measures should be taken as soon as possible.

We present here a case of unilateral facial paralysis caused by the dental infection of upper left second premolar.

CASE REPORT

A 40-year old male patient was referred to Erciyes University, Department of Oral and Maxillofacial Surgery with the complaint of progressively increasing pain, swelling on the left buccal side, and restriction of face movements. He had not received any treatment for his current condition before. Clinical and radiographic examinations revealed swelling of the left superior buccal side, related to the upper left second premolar with a deep caries (Figures 1). In facial nerve

function examination, limitation of the facial nerve motor functions on the left side was observed. The patient was unable to elevate the left eyebrow and to wrinkle the left side of his forehead (Figure 2), and also smiling or whistling was impossible (Figure 3). When he attempted to tightly close the eyelids, only the sclera of the eyeball was visible as in the case of Bell's sign (Figure 4). His medical history was unremarkable, and used no medications. The onset time of the facial movement restriction and tooth pain, swelling were at the same day. There was no additional etiologic factor of patient that may be a reason of facial nerve paralysis. The possible reason of facial nerve paralysis was the severe odontogenic infection in the same side of the face. The patient was started on ampicillin+sulbactam combination (1 gr Duocid®, Pfizer, İstanbul, Turkey) intravenously with 8 hours intervals, and non-steroid anti-inflammatory oral tablet (100 mg Majezik®, Sanovel, İstanbul, Turkey) for pain. The offending tooth was extracted, and the drainage of the abscess was performed intraorally. 80 mg prednisolone oral tablet was prescribed to the patient for the first three days. The dose was reduced to 40 mg, 20 mg, and 10 mg, respectively for the following 3 days; and 5 mg prednisolone was prescribed for the last three days. Eye protection, exercise and massage were recommended to the patient and he was advised to keep the area warm during the treatment. After 10 days, complete resolution of the paralysis was observed clinically (Figures 5-6). After 3 years of follow up there was no sign of either odontogenic infection or any other reason for the facial nerve paralysis in radiographic examination (Figure 7).

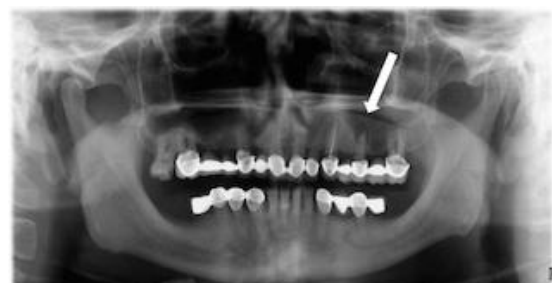

Figure 1. White arrow shows the left premolar tooth with radiolucent apical lesion, which caused left buccal abscess formation.



Figure 2. The patient was unable to elevate the left eyebrow in facial nerve motor function examination. (published with the patient's consent)

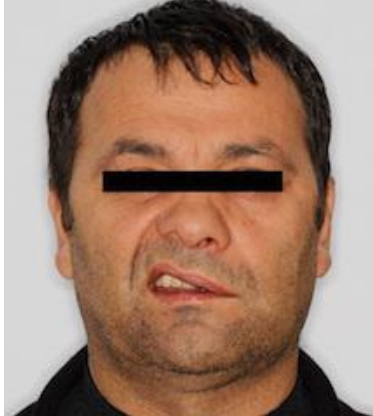

Figure 3. The patient was not able to smile and whistle. (published with the patient's consent)

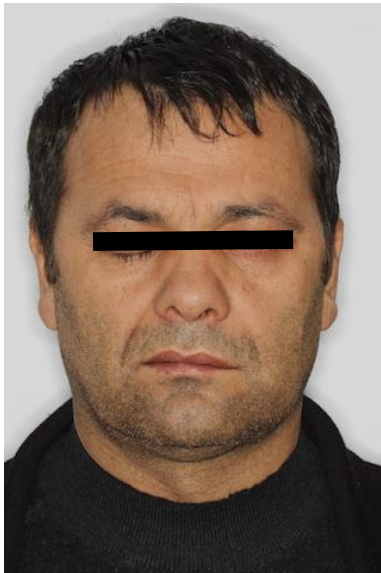

Figure 4. When the patient closes the eyelids, the Bell's sign was observed. (published with the patient's consent)

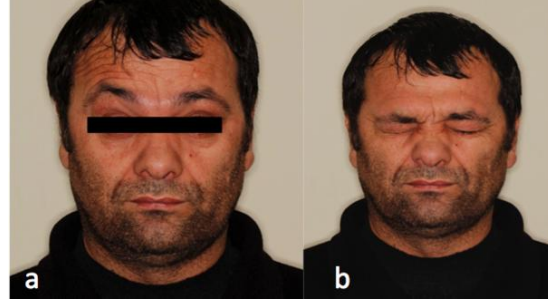

Figure 5-**A**. The patient was able to elevate left eyebrow and wrinkle his forehead after the therapy. (published with the patient's consent)
B. The patient was able to close both eyelids tightly after therapy. (published with the patient's consent)

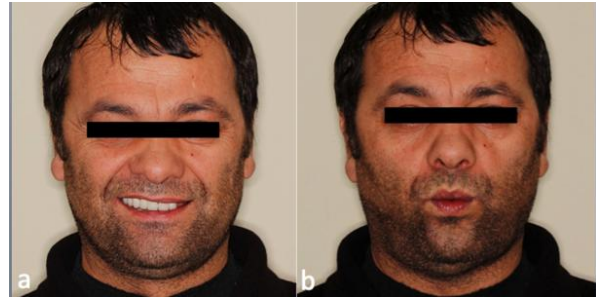


Figure 6**A**. Image of the patient when smiling after left facial nerve paralysis resolution. (published with the patient's consent)
B. Image of the patient when whistling after left facial nerve paralysis resolution. (published with the patient's consent)

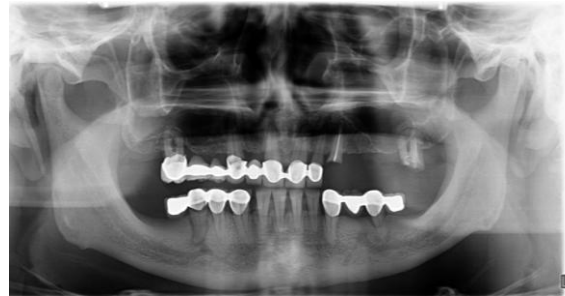

Figure 7. Postoperative radiographic image of the patient. White arrow shows the extraction socket after 3 years of follow up

DISCUSSION

Facial nerve paralysis (FNP) with a dental origin has rarely been reported, and has generally been related to local anesthetic blocks,¹⁵⁻¹⁸ or to direct/indirect surgical trauma to the nerve.¹⁹ Local anesthetic blocks may cause direct trauma to the

nerve, resulting in damage to the nerve fibers by dental needle during anesthesia. Dental needle trauma may also cause hemorrhage which leads compression and fibrosis resulting in injury of the nerve fibers.¹⁷

Dental procedures such as mandibular third molar surgery^{4,20} or root canal treatment²¹ have been reported to cause facial nerve paralysis. However, dental infections have been rarely reported to be related with this complication.²² Odontogenic infections most commonly involve the mandibular molar teeth.²³

Bobbit et al.²² reported a case of facial nerve paralysis related to an orofacial infection caused by an impacted third molar tooth. The authors reviewed the literature to explore the relationship between dental infection and FNP, and found only two references that were approximately 20 years old.^{20, 24} Al-Muharraqi³ et al. reported a case of infected lower third molar in which unilateral FNP occurred within hours of the development of a left sided swelling. Surgical removal of the offending tooth with the drainage of the abscess produced significant improvement in facial nerve function, and total resolution occurred with the prescription of antibiotics, NSAIDs, and dexamethasone with a reducing dose. In the case presented here, the patient had unilateral facial paralysis caused by the infection of a maxillary tooth, leading to the formation of a buccal/sub mucous abscess. The infection did not form a prominent extraoral swelling that may induce compression to the nerve, and facial nerve paralysis developed simultaneously with the other symptoms of the infection. Therefore, the potential mechanism of the FNP is unlikely to solely be related to the 'nerve compression theory' in this particular case. Toxicity may also be a contributing factor. Yet, the exact mechanism remains unclear, as it is not possible to biopsy the nerve.

Treatment of facial nerve paralysis is often symptomatic and includes steroids.⁷ Eye protection, exercise, massage and keeping warm of the affected side should be suggested to the patient as the supportive treatment. Persistent cases are treated with invasive methods such as decompression of the facial nerve.²⁵ In general, a gradually reducing dose of prednisolone, 60-80 mg/d for 1 week is administered.²⁶ Given the increasing evidence implying that the main cause of Bell's palsy is latent herpes

viruses (herpes simplex virus type 1 and herpes zoster virus), the use of oral prednisone with acyclovir in patients with moderate to severe facial palsy within 72 hours, was supported.⁸ In our case, because the patient had no history of herpetic lesions, no acyclovir treatment was started. 80 mg prednisolone oral tablet was recommended for the first three days, and the dose was gradually decreased during the following 10 days. Eye protection, exercise and massage with the advice of keeping warm of the affected side consisted our supporting treatment. At the end of the 10 days regimen, the functions of expression muscles completely improved, simultaneously with the eradication of the infection.

In conclusion, facial nerve paralysis related to dental infection is a rare condition. Complete resolution of the situation can be accomplished with the prompt elimination of the infection, along with the administration of corticosteroids. Because the outcomes of facial nerve paralysis can be devastating emotionally for the patients, the treatment should not be delayed. Therefore, dental practitioners should be familiar with this uncommon complication of orofacial infections and with the treatment options.

REFERENCES

1. Steiner I, Mattan Y. Bell's Palsy And Herpes Viruses: To (Acyclo)Vir Or Not To (Acyclo)Vir? J Neurol Sci 1999; 170: 19-23.
2. Tazi M, Soichot P, Perrin D. Facial Palsy Following Dental Extraction: Report Of 2 Cases. J Oral Maxillofac Surg 2003; 61: 840-4.
3. Al-Muharraqi MA, O'Sullivan EC. Unilateral Facial Nerve Paralysis Following An Infected Lower Third Molar. Int J Oral Maxillofac Surg 2010; 39: 192-5
4. Vasconcelos BC, Bessa-Nogueira RV, Maurette PE, Carneiro SC. Facial Nerve Paralysis After Impacted Lower Third Molar Surgery: A Literature Review And Case Report. Med Oral Patol Oral Cir Bucal 2006;11:175-8
5. Atzema C, Goldman RD . Should We Use Steroids To Treat Children With Bell's Palsy?. Can Family Physician 2006; 52:313-4
6. Ahmed A . When Is Facial Paralysis Bell Palsy? Current Diagnosis And Treatment. Cleve Clin J Med 2005; 72:398-401



7. Finsterer J. Management Of Peripheral Facial Nerve Palsy. Eur Arch Otorhinolaryngol 2008; 265: 743-52
8. Holland NJ, Weiner GM. Recent Developments In Bell's Palsy. BMJ 2004; 329: 553-7.
9. Cockerham K, Aro S, Liuw, Et Al. Application Of MEMS Technology And Engineering In Medicine: A New Paradigm For Facial Muscle Reanimation. Expert Rev Med Devices 2008; 5:371-81
10. Myckatyn TM, Mackinnon SE. The Surgical Management Of Facial Nerve Injury. Clin Plast Surg 2003; 30: 307-18
11. Rabie AN, Ibrahim AM, Kim PS, Medina M, Upton J, Lee BT, Lin SJ. Dynamic Rehabilitation Of Facial Nerve Injury: A Review Of The Literature. J Reconstr Microsurg 2013; 29: 283-96.
12. Nicastrì M, Mancini P, De Seta D, Bertoli G, Prosperini L, Toni D, Inghilleri M, Filipo R. Efficacy Of Early Physical Therapy In Severe Bell's Palsy: A Randomized Controlled Trial. Neurorehabil Neural Repair 2013; 27: 542-51
13. Shahidullah M, Haque A, Islam MR, Rizvi AN, Sultana N, Mia BA, Hussain MA. Comparative Study Between Combination Of Famciclovir And Prednisolone With Prednisolone Alone In Acute Bell's Palsy. Mymensingh Med J 2011; 20: 605-13.
14. Kim J. Contralateral Botulinum Toxin Injection To Improve Facial Asymmetry After Acute Facial Paralysis. Otol Neurotol 2013; 34: 319-24
15. Ling KC. Peripheral Facial Nerve Paralysis After Local Dental Anesthesia. Oral Surg Oral Med Oral Pathol 1985; 60:23-4.
16. Bernsen PL. Peripheral Facial Nerve Paralysis After Local Upper Dental Anaesthesia. Eur Neurol 1993; 33: 90-1.
17. Pogrel, MA, Bryan J, Regezi JA. Nerve Damage Associated With Inferior Alveolar Nerve Blocks. J Am Dent Assoc 1995; 126:1150-5.
18. Tzermpos FH, Cocos A, Kleftogiannis M, Zarakas M, Iatrou I. Transient Delayed Facial Nerve Palsy After Inferior Alveolar Nerve Block Anesthesia. Anesth Prog 2012; 59:22-7
19. Kapadia SM, Golinko MS, Williams JK. Facial Nerve Paralysis And Frey Syndrome In An Infant Following Removal Of An Internal Mandibular Distraction Device. J Craniofac Surg 2013; 24:961-3.
20. Gray RL. Peripheral Facial Nerve Paralysis Od Dental Origin. Br J Oral Surg 1978; 16: 143-50.
21. Kruse A, Hellmich N, Luebbers HT, Grätz KW. Neurological Deficit Of The Facial Nerve After Root Canal Treatment. Oral Surg Oral Med Oral Pathol Oral Radiol Endod 2009; 108: e46-8
22. Bobbitt TD, Subach PF, Giordano LS, Carmony BR. Partial Facial Nerve Paralysis Resulting From An Infected Mandibular Third Molar. J Oral Maxillofac Surg 2000; 58: 682-5.
23. Tozoğlu S, Ertaş Ü, Büyükkurt Mc, Yavuz S, Uslu H, Kaya Ö. Role Of Socioeconomic Factors In Maxillofacial Abscess Of Odontogenic Origin. Atatürk Üniv Diş Hek Faki Derg 2009; 19: 26-30
24. Hamlyn JF. Acute Hemiplegia In Childhood Following A Dental Abscess. Br J Oral Surg 1978;16: 151-5
25. Fisch U. Surgery for Bell's palsy. Arch Otolaryngol 1981; 107:1-11.
26. Tiemstra JD, Khatkhate N. Bell's Palsy: Diagnosis And Management. Am Fam Physician 2007; 76:997-1002

Yazışma Adresi

Dt.Canay YILMAZ ASAN
ERCIYES UNIVERSITY
FACULTY OF DENTISTRY
DEPARTMENT OF ORAL&MAXILLOFACIAL
SURGERY
MELİKGAZİ/KAYSERİ/TÜRKİYE
Tel: +903522076666/29175
Fax: +903524380657
e-mail: dtcanayyilmaz@windowslive.com

