



A case report of vaginal fibromyoma in a bitch

Rabia Buse AKSU^{1,a*}, Bahar GEZER^{1,b}, Çağla Nur KÜÇÜKBEKİR^{1,c}, Mehmet Fatih ÖZBEZEK^{1,d}, Zeynep GÜNAY UÇMAK^{2,e}, İsmail KIRŞAN^{2,f}, Ashhan BAYKAL^{2,g}, Merve YILMAZ^{2,h}, Damla HAKTANIR^{3,i}, Funda YILDIRIM^{3,j}, Barış HALAÇ^{4,k}, Ayşe Ilgın KEKEÇ^{4,l}

¹Istanbul University-Cerrahpaşa, Institute of Graduate Studies, Istanbul, Turkey

²Istanbul University-Cerrahpaşa, Faculty of Veterinary Medicine, Department of Obstetrics and Gynecology, Istanbul, Turkey

³Istanbul University-Cerrahpaşa, Faculty of Veterinary Medicine, Department of Pathology, Istanbul, Turkey

⁴Istanbul University-Cerrahpaşa, Faculty of Veterinary Medicine, Department of Microbiology, Istanbul, Turkey

ID 0000-0002-2572-4289^a;0000-0001-8410-893X^b;0000-0002-9687-1702^c;0009-0003-5375-8130^d;0000-0003-2530-1291^e;0000-0003-0780-0118^f;0000-0002-2107-1874^g;0000-0002-6985-9150^h;0000-0001-5171-1927ⁱ;0000-0001-9755-8198^j;0000-0002-3067-9937^k;0000-0002-0821-8376^l

MAKALE BİLGİSİ / ARTICLE INFORMATION:

Geliş / Received:

20 Aralık 23

20 December 23

Revizyon / Revised:

04 Nisan 24

04 April 24

Kabul / Accepted:

15 Mayıs 24

15 May 24

Anahtar Sözcükler:

Fibromiyom

Köpek

Vajina

Keywords:

Fibromiyoma

Dog

Vagina

©2024 The Authors.

Published by Veteriner

Hekimler Derneği. This is

an open access article

under CC-BY-NC license.

(<https://creativecommons.org/licenses/by-nc/4.0>)



ABSTRACT

A 5-year-old, intact female Caucasian Shepherd dog was brought to our clinic with complaints of ongoing vaginal bleeding, weakness, loss of appetite, and a vaginal mass for a month. According to the anamnesis, the vaginal mass had rapidly increased in size over the last month, and there was ulceration and bleeding on the mass. In the examination, it was determined that the mass originated from the ventrolateral surface of the vagina, and an abscess-like structure was also found cranially to this mass. The mucous membranes were light pink, the palpable lymph nodes were of average size, the furs were matte, and the vaginal area was dirty with blood. The dog's hemogram and biochemical test results were found to be within normal reference ranges; hence, it was decided to treat the dog surgically. The tissue obtained after vaginal mass excision was examined microbiologically and histopathologically. The mass, initially thought to be an abscess based on its smaller size and macroscopic examination, was determined to have a sterile content and to be an inflammatory infiltration rather than an abscess. It was concluded that detailed clinical examination and histopathological analysis can establish the diagnosis of all tumoral cases like this, and successful treatment can be achieved through surgical intervention.

Bir köpekte görülen vajinal fibromiyom olgusu

ÖZET

5 yaşında dişi, kısırlaştırılmamış Kafkas çoban köpeği 1 aydır devam eden vajinal kanama, halsizlik, iştahsızlık ve vajinal kitle şikâyeti ile kliniğimize getirildi. Anamnezde vajinal kitlenin son 1 ayda hızla büyüdüğü, kitle üzerinde yara ve kanamaların oluştuğu bilgisi alındı. Klinik muayenede kitlenin vajenin ventrolateral yüzeyinden köken aldığı ve bu kitlenin kranialinde de apse benzeri bir yapının olduğu tespit edildi. Mukozal membranların açık pembe renkte, palpe edilebilen lenf yumrularının normal boyutlarda, tüylerin mat, vajinal bölgenin kan ile bulaşık olduğu görüldü. Hemogram ve biyokimyasal test sonuçlarının normal referans aralıklarında olduğu tespit edilen köpeğin cerrahi yolla tedavisine karar verildi. Vajinal kitle ekstirpasyonu sonrasında alınan doku mikrobiyolojik ve histopatolojik olarak incelendi. Fibromiyom teşhis edilen hastadaki daha küçük ve makroskobik bakıda apse olduğu düşünülen kitlenin ise steril içeriğe sahip olduğu ve apse değil yangılı infiltrasyon olduğu belirlendi. Bunun gibi tümöral olguların detaylı klinik muayene ve histopatolojik analiz ile tanısının konulabileceği ve cerrahi müdahale ile de başarıyla sağaltılabileceği sonucuna varıldı.

How to cite this article: Aksı RB, Gezer B, Küçükbeğir ÇN, Özbezek MF, Günay Uçmak Z, Kırşan İ, Baykal A, Yılmaz M, Haktanır D, Yıldırım F, Halaç B, Kekeç AI. A case report of vaginal fibromyoma in a bitch. Vet Hekim Der Derg 95(2): 158-163, 2024. DOI: vetheder.1407423

* Sorumlu Yazar e-posta adresi / Corresponding Author e-mail address: rbuse.erdogan@hotmail.com

1. Introduction

Tumours seen in the female reproductive system have two sources; one originates from the ovaries and the other from the tubular genital tract (1-3). It is crucial to differentiate whether these neoplasms are benign or malignant and distinguish them from other conditions, such as hyperplasia, granulation tissue, or abscesses, as it can alter the treatment approach and prognosis (4). Tumours of the vagina and vulva are rare in dogs, accounting for about 2.5-3% of all canine tumours. Among specific tumours in the reproductive region, the incidence of vaginal tumours is 41%, and vulvar tumours stand at 34.2% (5,6). Approximately 70-80% of vaginal/vulvar tumours are benign. Leiomyoma, fibropapilloma, fibroma, fibroleiomyoma, lipoma, peripheral nerve tumor, fibrous histiocytoma, melanoma, myxoma, and myxofibroma are reported as benign vaginal/vulvar tumours (7). Leiomyoma, fibroma or fibroleiomyoma, and TVT (transmissible venereal tumour) are the most commonly reported benign neoplasms of the canine reproductive system (8). On the other hand, 27-30% of vaginal/vulvar tumours are malignant. The age at which these tumours occur ranges from 2 to 18 years. There is no specific breed predisposition (9,10). Malignant tumours are more common in large-breed dogs. Clinical signs associated with these tumours include perineal swelling, visible mass from the vulva, vulvar discharge, dysuria, licking of the vulva, polyuria, and polydipsia (7). Diagnosis involves physical examination, biopsy, vaginoscopy, and histopathological examination of the tissue for differential diagnosis. Surgery is an option for the treatment of vaginal/vulvar tumours, followed by two doses of chemotherapy post-operation. The prognosis is considered good for benign and non-metastatic cases (6,10,11). In the conducted studies (12), the numbers of estrogen, progesterone, and epidermal growth factor receptors in vaginal tumours were evaluated, and based on these assessments, the use of steroids as a treatment method has also been considered. This case discusses clinical approaches taken for the diagnosis and treatment of vaginal abscesses and fibromyoma observed in an intact female dog.

2. Case Story

A 5-year-old, intact female Caucasian Shepherd dog was brought to the clinic with complaints of ongoing vaginal bleeding, weakness, loss of appetite, and a vaginal mass for a month. According to the history, the vaginal mass had rapidly increased in size over the last month, and there were reports of ulceration and bleeding on the mass. In the examination, it was determined that the mass originated from the ventrolateral surface of the vagina, and an abscess-like structure was also found cranially to this mass. The mucous membranes were light pink, the palpable lymph nodes were of average size, the furs were matte, and the vaginal area was dirty with blood. Surgical intervention was decided as a treatment. Before the surgery, a blood test was conducted to assess anesthesia risk. The hemogram and biochemical test results were within normal reference ranges. The dog was administered on isotonic saline solution (0.9% NaCl) at a dose of 20 ml/kg/15 min via intravenous route before to the operation (Polifleks, Polifarma, Türkiye). As suggested in the KIRSAN method, a mixture of 1 ml adrenaline (Adrenalin Codex 0.5 mg/1 ml, Galen Pharmaceuticals, Istanbul, Türkiye) and 9 ml of saline (Polifleks, Polifarma, Türkiye) to be locally applied to the surgical area was cooled at +4°C in a refrigerator for 30 minutes before the operation (13,14). For premedication, atropine sulfate (Teknovet Atropin, Teknovet Pharmaceuticals, Istanbul, Türkiye) was administered subcutaneously at a dose of 0.02 mg/kg, and for induction propofol (Propofol 200 mg/20 mL, Fresenius Kabi Pharmaceuticals, Istanbul, Türkiye) was given intravenously at a dose of 6-8 mg/kg. After intubation, the anesthesia was maintained with isoflurane at a dose of 3.5-4% (Isoflurane USP, Piramal Critical Care, USA) with 2-2.5% oxygen. The dog was positioned in a dorsoventral Trendelenburg position, a cushion was placed transversely under the caudal abdomen near the pelvis, and the pelvic region was elevated. The tail was secured to the dog's back after exposing the perineum. Aseptic and antiseptic procedures were performed in the area. Urinary catheterization was applied to prevent urethral damage before the surgery. Hemostatic forceps were attached dorsally, ventrally, and laterally to limit the section of the protruded vagina. A diluted and cooled adrenaline mixture was injected into the submucosal and tissue depths along the incision boundaries. The purpose was to constrict the vessels in the area with effect of both adrenaline and cold, thus preventing bleeding. The cutting process commenced using an electrosurgical unit that combined cutting and coagulation (Blend-2 mode) with an electrically activated blade electrode set at 80 watts. The mass was removed by dissecting deep into

the dorsal, ventral, and lateral aspects. The wound edges were apposed and sutured with Connell sutures as described in the KIRSAN method (13). Absorbable suture material (Monocryl No:0, Medeks, Istanbul, Türkiye) was used for all sutures. The sample taken from the smaller mass was sent to the microbiology laboratory for identification of the causative agent. The morbid substance delivered to the laboratory was first planted in nutrient broth and incubated in a microaerobic environment at 37°C for 24 hours. Gram staining was performed on the liquid cultures obtained and no bacterial growth was found as a result of gram staining. The liquid culture was transferred to Blood agar and incubated at 37°C for 24 hours. As a result of microbiological examination, no agent growth was detected in the abscess content and it was determined that the content was sterile. Also, extirpated vaginal masses were examined histopathologically. Tissue samples obtained during the surgery were fixed in 10% formalin, underwent routine tissue processing, sections were taken at 5 µm thickness, and stained with hematoxylin-eosin stain. The tissue sections were stained using a staining kit based on the principle of trichrome staining, specifically Masson-Trichrome Goldner (Katalog no. 04-011802, Bio Optica, İtalya), to demonstrate the distribution of connective and muscle tissue. The preparations were examined under a Nikon Eclipse Ci-L microscope, and digital micrographs were obtained using the Nikon DSQi2 camera system. All images were enhanced using Macromedia Fireworks 8 software with the same settings. Macroscopically, the tumoural mass appeared as two parts, measuring 2.5 and 6 cm in diameter, firm and elastic in consistency, nodular in form, with a pale-white cut surface and a slight hemorrhagic appearance near one area (Figure 1). In the microscopic examination of tissue sections, loose fibrous connective tissue covering wide areas (Figure 2.a) and intermittently collagen-rich dense fibrous connective tissue (Figure 2.b) were observed, intertwined with benign-appearing, highly cellular, with indistinct borders, eosinophilic cytoplasm, cigar-shaped nuclei (tapered ends), and small nucleoli, monotonous spindle myocyte fascicles (Figure 2.c). Some sections exhibited ulceration on the surface, while beneath the surface, areas of neutrophilic leukocyte infiltration, hemorrhage, vascularization, and fibrotic areas were identified. Sections stained with the Masson-Trichrome kit highlighted the connective tissue in green and the myocyte fascicles in red (Figure 2.d and 2.e). Based on the histopathological features exhibited by the lesion, it was diagnosed as a fibromyoma, defined as a benign tumor of muscle and connective tissue.

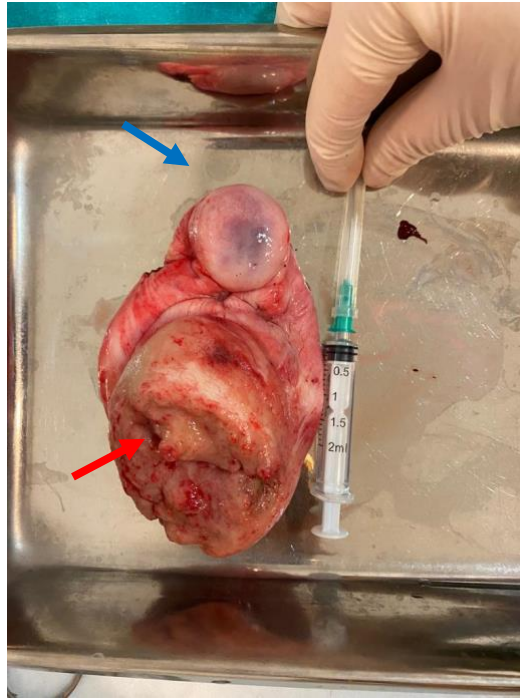


Figure 1: The extirpated vaginal mass. Blue arrow: smaller mass, red arrow: vaginal tumor

Şekil 1: Ekstirpe edilen vajinal kitle. Mavi ok: küçük kitle, kırmızı ok: vajinal tümör

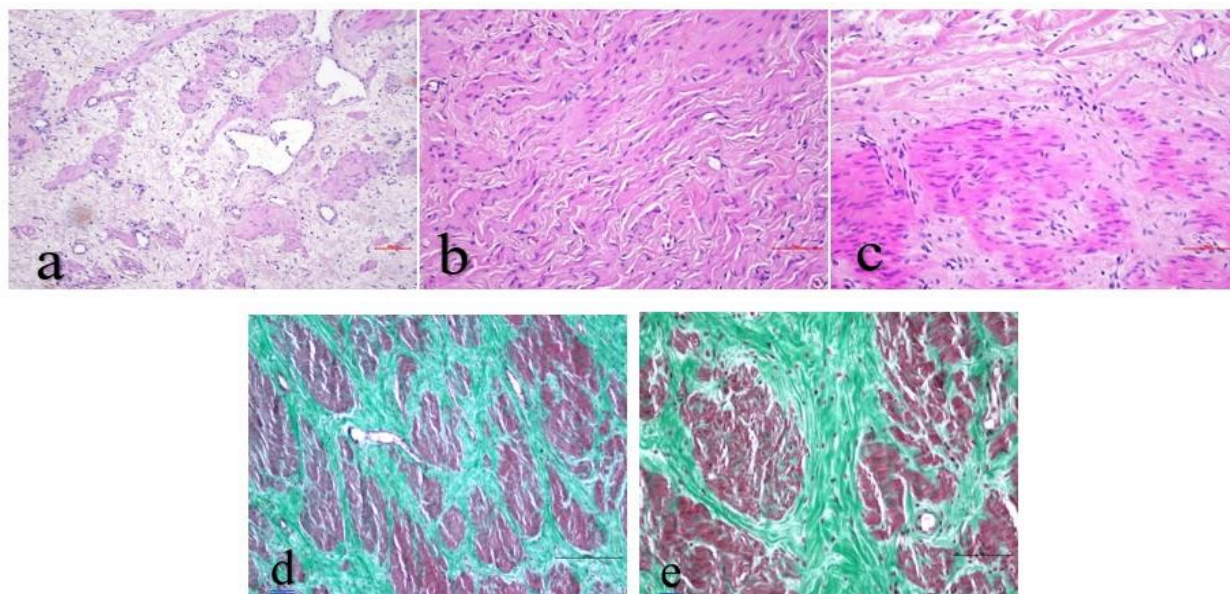


Figure 2: (a) Irregular myocyte fascicles, stained darker pink, were observed within the loose edematous connective tissue, H&E staining, Scale Bar: 100µm. (b) Dense fibrous connective tissue composed of coarse irregular collagen and hyperchromatic nuclei fibrocytes, H&E staining, Scale Bar: 70µm. (c) Within the background of young connective tissue characterized by lightly stained pink collagen fibers and prominent nuclei fibroblasts, myocyte fascicles with eosinophilic cytoplasm and cigar-shaped nuclei were observed, H&E staining, Scale Bar: 70µm. (d) Myocyte fascicles stained in red were observed among coarse collagen fibers stained in green, Masson-Trichrome staining, Scale Bar: 200µm. (e) Myocyte fascicles stained in red were observed among coarse collagen fibers stained in green, Masson-Trichrome staining, Scale Bar: 90µm

Şekil 2: (a) Oldukça gevşek ödemli bağ doku içerisinde daha koyu pembe boyanan düzensiz miyozit fasikülleri, H&E boyaması, Bar: 100µm. (b) Kaba düzensiz kolajen ve hiperkromatik ince çekirdekli fibrositlerden oluşan sıkı fibröz bağ doku, H&E boyaması, Bar: 70µm. (c) Daha açık pembe renkte boyanan hafif düzensiz kolajen iplikler ve iri çekirdekleri göze çarpan fibroblastların oluşturduğu genç bağ dokunun oluşturduğu zeminde eozinofilik sitoplazmalı, puro şeklinde çekirdeğe sahip miyozit fasikülleri, H&E boyaması, Bar: 70µm. (d) Yeşil renkte boyanan kaba kolajen iplikler arasında kırmızı renkte boyanan miyozit fasikülleri, Masson-Trichrome boyaması, Bar: 200µm. (e) Yeşil renkte boyanan kaba kolajen iplikler arasında kırmızı renkte boyanan miyozit fasikülleri, Masson-Trichrome boyaması, Bar: 90µm

The dog was fed with wet food to avoid the constipation for two days following the surgery. For one week, it received injections of ceftriaxone (Equiceft, Tüm Ekip İlaç, İstanbul, Türkiye) at a dose of 30 mg/kg administered intramuscularly. The suture line was cleaned daily with isotonic saline solution (0.9% NaCl, Polifleks, Polifarma, Türkiye). Activity was restricted for three days, and cold compresses were applied to the area. The dog was in a good health on the postoperative 10th day.

3. Discussion and Conclusion

Many pathologies such as congenital and acquired abnormalities, benign or malignant neoplasms, trauma, and abscesses, among others, can affect the reproductive organs (vagina, vestibule, clitoris, and vulva) in dogs and cats, leading to their illness. Most of these pathologies may develop due to genetic predisposition, aging, certain past illnesses, or iatrogenic causes, obesity, hormonal medications, and whether the animal is sexually active (13). Contrary to previous studies, in this case, the dog was not elderly, not obese, had not mated before, did not use hormonal medication, and had no history of illness. However, it was presented with complaints of a vaginal mass, suggesting that vaginal masses could occur independently of these symptoms. In the presented case of the Caucasian Shepherd Dog, contrary to what the researchers' report (7) indicated about a higher prevalence of malignant tumours in large-breeds, a benign vaginal tumour has been identified. Vaginal neoplasms can be confused with vaginal hyperplasia/prolapse cases. Vaginal hyperplasia and prolapse present as lobulated and soft formations, whereas vaginal neoplasms are solid

and firm nodules, often associated with the mucosa, which helps distinguish them from vaginal hyperplasia/prolapse. Additionally, it should be differentiated from clinical conditions like clitoral hypertrophy, vaginal abscess, and hematoma. Advanced investigations after the examination are necessary to differentiate vaginal hyperplasia/prolapse from vaginal masses (15). Consistent with the researchers' report, in our case, the mass palpated on the ventrolateral surface of the vagina was firm and lobulated. In the traditional surgical approach, horizontal U-shaped stitches are placed at the base of the excised mass with absorbable sutures intertwined through each other. Then, the mass is resected by electrocautery. The exposed fresh wound edges are apposed, preventing adhesions and septum formation on the vaginal wall (13-15). In the KIRSAN method, traditional sutures used for ligation are either not used at all or used in very few numbers. Therefore, reducing the risk of suture complications during and after surgery and lowering costs. The KIRSAN method speeds up the patient's healing process, enhances its well-being, and involves minimal or no bleeding during or after the operation. In the presented case, unlike the traditional treatment method, applying the KIRSAN method, as in the researchers' report (13,16), shortened the anesthesia duration during the operation and accelerated the recovery process. The most appropriate treatment for vaginal masses, regardless of whether they are benign or malignant, is surgical intervention. Radiotherapy may be attempted for metastases of the mass in inaccessible areas (1,2). Iatrogenic injury to the urethra or accidental injury to other perineal structures are possible surgical complications. As reported by researchers (4), catheterization was performed in the presented case to prevent damage to the urethra before the operation. Vaginal fibroids are typically described as tumours composed of regular smooth muscle cells. Microscopic examination of these tumours reveals regular smooth muscle cells within a smooth and dense collagen matrix. The cells often appear spindle-shaped or star-shaped and exhibit a regular structure (17). Such tumours are generally considered benign or non-cancerous and rarely tend to become malignant. The histopathological structures observed in the presented case are consistent with those of the researchers (17). It was concluded that tumor cases, along with masses resembling abscesses macroscopically, can be diagnosed through detailed clinical examination and histopathological analysis. Additionally, it was determined that these cases can be successfully treated with a novel surgical intervention technique.

Conflict of Interests

The authors declared that there is no conflict of interest.

Acknowledgement

A part of this case report's abstract was presented as a poster presentation at the 10th National & 4th International Turkish Society of Veterinary Gynecology Congress.

Funding

During this study, no financial and/or moral support has been received from any pharmaceutical company directly related to the research topic, any company supplying and/or producing medical equipment, tools, and materials, or any commercial firm that could adversely influence the decision-making process related to the study evaluation.

Authors' Contributions

Motivation / Concept: İsmail KIRŞAN, Zeynep GÜNAY UÇMAK

Design: İsmail KIRŞAN, Zeynep GÜNAY UÇMAK

Control / Supervision: İsmail KIRŞAN, Zeynep GÜNAY UÇMAK, Rabia Buse AKSU

Data Collection and / or Processing: Merve YILMAZ, Mehmet Fatih ÖZBEZEK, Çağla Nur KÜÇÜKBEKİR

Analysis and / or Interpretation: Barış HALAÇ, Ayşe Ilgın KEKEÇ, Damla HAKTANIR, Funda YILDIRIM

Literature Review: İsmail KIRŞAN, Rabia Buse AKSU, Aslıhan BAYKAL

Writing Manuscript: Rabia Buse AKSU, Zeynep GÜNAY UÇMAK

Critical Review: Bahar GEZER, Zeynep GÜNAY UÇMAK

Ethical Approval

The data, information and documents presented in this article have been obtained within the framework of academic and ethical standards. Ethical statements have been obtained from the authors, affirming that all information, documents, evaluations, and conclusions are presented in accordance with scientific ethical and moral principles.

References

1. Susaneck SJ. Tumors of the female reproductive tract. In: Collins, F. (Ed), Oncology notes. Comparative Oncology Unit, Colorado State University, 1981.
2. Barrett RE, Theilen GH. Neoplasms of the canine and feline reproductive tracts. In: Kirk RW, editor. Current veterinary therapy VI. Philadelphia, London, Toronto, W.B. Saunders Co., 1977. p. 1263-1267.
3. Bostock DE, Owen LN. A colour atlas of neoplasia in the cat, dog and horse. London, United Kingdom, Wolfe Medical Publications Ltd. 1975. p. 62-79.
4. Kang TB, Holmberg DL. Vaginal leiomyoma in a dog. Canadian Veterinary Journal. [serial online] 1983 [cited 2023 Dec 13]; Aug 24(8):258-60. Available from: URL: <https://www.ncbi.nlm.nih.gov/pmc/articles/PMC1790397/>
5. Johnston SD, Kustritz MVR, Olsan PNS. Disorders of the canine vagina, vestibule, and vulva. In: Kersey R, editor. Canine and feline theriogenology. 1st ed. W.B. Saunders Company, Philadelphia; 2001. p.225-242.
6. Alaçam E. Üreme Organlarının Tümörleri. In: Alaçam E, editor. Köpek ve Kedilerde Üreme Süreci ve Sorunları. 1st ed. Medisan, Ankara; 2008. p.121-126.
7. Köse AM, Ozsoy SY, Dogruer G. Bir Köpekte Vajinal Leyomiyosarkom. Atatürk Üniversitesi Veteriner Bilimleri Dergisi. 2017;12(1):80-83.
8. Balamurugan B, Sivasudharsan L. Surgical correction of vaginal fibroma in a Spitz she dog. Haryana Veterinarian. 2021;60(2): 307-308.
9. Erer H, Kıran MM. Veteriner Onkoloji. 3rd ed. Damla Ofset, Konya; 2005. p. 83-114.
10. McEntee MC. Reproductive oncology. Clinical Techniques in Small Animal Practice. [serial online] 2002 [cited 2023 Dec 13]; Aug;17(3):133-49. Available from: URL: <https://pubmed.ncbi.nlm.nih.gov/12476817/>
11. England GCW. Diseases of the reproductive system. In: Dunn JK, editor. Textbook of Small Animal Medicine. 1st ed. WB Saunders Company, Philadelphia; 1999. p.574-612.
12. Günay Uçmak Z, Ateş A, Erdoğan Bamaç Ö, Öztürk Gürgen H, Kırşan İ, Tek Ç, Küçükbekir ÇN, Kurban İ. Determination of estrogen receptor, progesterone receptor and epidermal growth factor receptor in canine vaginal tumors and vaginal fold prolapse: A preliminary study. Journal of Istanbul Veterinary Sciences. 2022;6(1):35-41.
13. Kırşan İ. Köpeklerde vajinal hiperplazi ve prolapsus. TVJD. Eğitim Seminerleri. 2020.
14. Wykes PM, Olson PN. Vagina, vestibule and vulva. In: Slatter D, editor. Textbook of small animal surgery. 3rd ed. Philadelphia, W. B. saunders; 2003. p.1502-10.
15. Arnold S. Erkrankungen von vagina, vestibulum und vulva. In: Niemand HG, Suter PF, editors. Praktikum der Hundeklinik. 8th ed. Berlin, Blackwell-Wissenschafts-Verlag; 1994. p 863-6.
16. Kırşan İ. Kedi ve köpeklerde vajina, vestibulum ve klitoris'in cerrahi hastalıkları. In: Tekeli T, editor. Kedi ve Köpeklerde Jinekolojik ve Obstetrik Operasyonlar. 1st ed. Ankara, Türkiye Klinikleri; 2022. p. 45-80.
17. Stewart CJR, Amanuel B, Brennan BA, Jain S, Rajakaruna R, Wallace S. Superficial cervico-vaginal myofibroblastoma: a report of five cases. Royal Collage of Pathologists of Australasia. Pathology. 2005;37(2), pp. 144-148.