

COMPARATIVE EVALUATION OF ARTICULAR EMINENCE INCLINATION AND MANDIBULAR CONDYLE FRACTAL DIMENSIONS OF DIFFERENT TYPES OF EDENTULISM

Farklı Dişsizlik Türlerindeki Mandibuler Kondil Fraktal Boyutları ve Artiküler Eminens Eğimlerinin Karşılaştırmalı Değerlendirilmesi

Mehmet Fatih ŞENTÜRK¹  Emine Şebnem KURSUN ÇAKMAK²  Seval BAYRAK³ 
Beste İNCEOĞLU⁴  Handan ANKARALI⁵ 

- ¹ Department of Oral and Maxillofacial Surgery, Faculty of Dentistry, Ankara Yıldırım Beyazıt University, ANKARA, TÜRKİYE
² Department of Oral and Maxillofacial Radiology Faculty of Dentistry, Ankara Yıldırım Beyazıt University, ANKARA, TÜRKİYE
³ Department of Oral and Maxillofacial Radiology, Faculty of Dentistry, Bolu Abant İzzet Baysal University, BOLU, TÜRKİYE
⁴ Ministry of Health, Department of Health Quality, Accreditation and Employee Rights ANKARA, TÜRKİYE
⁵ Department of Biostatistics and Medical Informatics, Faculty of Medicine, İstanbul Medeniyet University, İSTANBUL, TÜRKİYE

ABSTRACT

Objective: To estimate if a correlation exists between edentulousness type and changes in the articular eminence inclination (AEI) and to compare these data with the trabecular structure of the mandibular condyle using fractal analysis.

Material and Methods: A total of 88 panoramic radiographs and 176 temporomandibular joints (TMJ) of four groups (n=22), which were divided according to dental status, were evaluated according to the AEI and fractal dimensions (FD) of the temporomandibular joints by one radiologist using the ImageJ (National Institutes of Health. MD, USA) program, retrospectively. The conformity of the values with normal distribution was evaluated using the Shapiro-Wilk test. A one-way ANOVA model was used while comparing the edentation status and relationships between FDs, and AEI measurements were assessed using Pearson's correlation analysis. The level of statistical significance was taken as $p<0.05$. The SPSS (ver. 23) statistics package was used for calculations.

Results: No correlation was detected between AEI, FD, and edentate status. However, a negative relation between AEI and FD in unilateral edentate groups on the opposite sides was estimated.

Conclusion: The excess chewing force in the dentate side and the increase in AEI due to the movement area of the condyle narrows increased the amount of resorption in the TMJ.

Keywords: Articular eminence inclination, edentulism, fractal dimension, mandibular condyle

ÖZ

Amaç: Dişsizlik türü ile artiküler eminens eğim (AEE) farkları arasında bir korelasyon olup olmadığının tespiti ve bu verilerin fraktal analiz ile saptanan mandibuler kondilin trabeküler yapısı ile karşılaştırılmasıdır.

Gereç ve Yöntemler: Dişsel durumlarına göre sınıflandırılan 4 gruba (n=22) ait toplamda 88 adet panoramik radyografteki 176 adet temporomandibular eklem (TME), AEE ve fraktal boyut (FB) açısından Image J (National Institutes of Health. MD, USA) programı kullanarak bir radyoloji uzmanı tarafından değerlendirildi. Değerlerin normal dağılıma uygunluğu Shapiro-Wilk testi kullanılarak değerlendirildi. Dişsizlik durumu ve FB/AEE ilişkisi karşılaştırılırken tek yönlü ANOVA modeli ve Pearson korelasyon analizi kullanıldı. İstatistiksel anlamlılık düzeyi $p<0.05$ olarak alındı. Hesaplamalarda SPSS (ver. 23) istatistik paketi kullanıldı.

Bulgular: AEE, FB ve dişsizlik durumu arasında korelasyon saptanmadı. Ancak tek taraflı dişsiz grupların karşı tarafında AEE ile FB arasında negatif bir ilişki olduğu saptandı.

Sonuç: Dişli taraftaki çiğneme kuvvetinin fazla olması ve kondilin hareket alanının daralmasına bağlı AEE artışı TME'deki rezorpsiyon miktarını artırmıştır.

Anahtar Kelimeler: Artiküler eminens eğimi, dişsizlik, fraktal boyut, mandibuler kondil



Correspondence / Yazışma Adresi:

Department of Oral and Maxillofacial Radiology, Faculty of Dentistry, Bolu Abant İzzet Baysal University, BOLU, TÜRKİYE

Phone / Tel: +905434876694

Received / Geliş Tarihi: 09.01.2024

Dr. Seval BAYRAK

E-mail / E-posta: dtseval@hotmail.com

Accepted / Kabul Tarihi: 13.05.2024

INTRODUCTION

The temporomandibular joint (TMJ) is a complex diarthrodial joint consisting of two articular areas, the mandible's condyle and the temporal bone's articular eminence (AE). The posterior slope of the AE, known as the articular surface, plays a role in the biomechanics of the TMJ by determining the pathways of the condyle-disc complex and types of movements (1-5). The AE, which begins to develop at the age of 6 years, completes most of its development at the age of 20 years. It has been reported that the normal values of the AE slope, which shows great individual differences and various values, are usually between 30 and 60 degrees, but can be seen up to 94 degrees (6,7). Small differences can be seen in the right and left regions of the same individual in articular eminence inclination (AEI) and can be affected by many factors such as sex, facial profile, condyle shape, condyle position, TMJ disease, tooth wear, and tooth loss (8-13).

Muscles strengthen the bone by creating functional stress on the bone surface and preventing mineral loss. Tooth loss, on the other side, induces a decrease in muscle mass and muscle tone, resulting in modifications in chewing function and changes in AEI (14-16). In the literature, it has been reported that AEI is decreased in total edentulous patients and unilateral tooth loss compared with dentate patients and that there is a change in AEI, even in single tooth loss (17-20).

Deteriorations in the biomechanics of the chewing system cause a decrease in the functional load on the bone. The condyle adapts to these changing functional loads and conditions over time. As a result, changes occur both in the shape and external structure of the condyle and the internal structure such as the number of trabeculae and its architecture (21,22). The determination of these changes in the internal structure of the condyle is necessary for the identification of joint diseases (23).

Fractal analysis is a method that evaluates the complexity of irregular and complex objects quantitatively. The value obtained as a result of this calculation is the fractal dimension (FD). In the literature, this method has been widely used in the quantitative assessment of the complexity of the trabecular structure of bone (24).

This study aimed to assess whether there is a correlation between edentation status and AEI changes and also compare these findings with the trabecular structure of the mandibular condyle by using fractal analysis. We hypothesized that different edentulism situations would affect AEI which the change the mandibular condyle pathway and structure. Specifically, we aimed to evaluate the structure of the condyle using fractal analysis.

MATERIALS AND METHODS

The sample size for this study was calculated using specific software (G*Power 3.1.7 for Windows; Heinrich Heine, Universitat Dusseldorf, Dusseldorf, Germany), and the F test for four independent groups was used with an alpha-type error of 0.05, and a beta power of 0.95 for all variables. A previous study was used to determine the specific effect size, which was found as 1.25 (17)

The Clinical Research Ethics Committee of Bolu Abant İzzet Baysal University approved the current retrospective study (Decision no: 2022/152). We retrospectively analyzed 176 joints of 88 patients with panoramic radiographs who were attended by Bolu Abant İzzet Baysal University Dentistry Faculty for various purposes between the years of 2015 and 2021. Panoramic radiographs of patients aged over 20 years due to AEI developmental implications were included in the study. The other inclusion criteria was the well quality panoramic radiographs which provide the analysis of both TMJs. Individuals with a fracture or pathologic area that inhibited measurements, using medication that would interrupt bone turnover, had conditions that affected bone metabolism, and individuals who received conservative or surgical treatment for temporomandibular disease were excluded from the study. No patient had any progressional malformation or history of trauma. This information was obtained from the retrospective review of medical records from the databases of the hospital. The patients were divided equally into four different groups, which were separated according to the edentation status of the patients' mandibles: type I (n=22), two-sided edentulous field positioned behind the remaining natural teeth; type II (n=22), one-sided edentulous field positioned behind the remaining natural teeth; type III (n=22), totally edentulous; type IV (n=22), totally dentate.

All radiographs were taken using the same radiographic device (Soredex Cranex, Germany) with standard exposure parameters of 68 kVp and 10 mA. Calculations were performed by a radiologist with 16 years of experience.

Calculation of AEI

The sagittal contours of both sides of the AE and glenoid fossae could be viewed on the monitor. The "orbitale" (the lowest point in the border of the orbit) and the "porion" (the highest point in the border of the auditory meatus) were specified on both left and right sides and a Frankfurt horizontal line was composed by connecting these marks on each side. The most superior point on the glenoid fossa roof and the most inferior tip on the AE were recognized and a second plane to define the mean condylar path inclination (CPI) was composed by connecting the two marks. Using these two lines, the

AEI was analyzed using the top-roof line technique (25), which was the angle between the CPI line and the Frankfurt horizontal line (Figure 1).

Fractal Analysis of TMJ

The images were processed using the Image J (National Institutes of Health, MD, USA) software for fractal analysis with a box-counting algorithm using White and Rudolph's technique (26). Panoramic radiographs were converted to tagged image file formats (TIFFs) because of their high resolution. First, standardized square regions of interest (ROIs) of 84 x 84 pixels were chosen

inside the cortical edges of both mandibular condyles (Figure 1).

Gaussian blur was used to distract brightness differences due to overlying soft tissues and varying thicknesses of bone. The resulting image was then subtracted from the original image. Bone marrow spaces and trabeculae were distinguished with the addition of a 128 gray value to each pixel location. After applying binary, erode, dilate, invert, and skeletonizing processes, FD values were calculated. In Figure 2, the stages of fractal analysis are demonstrated.

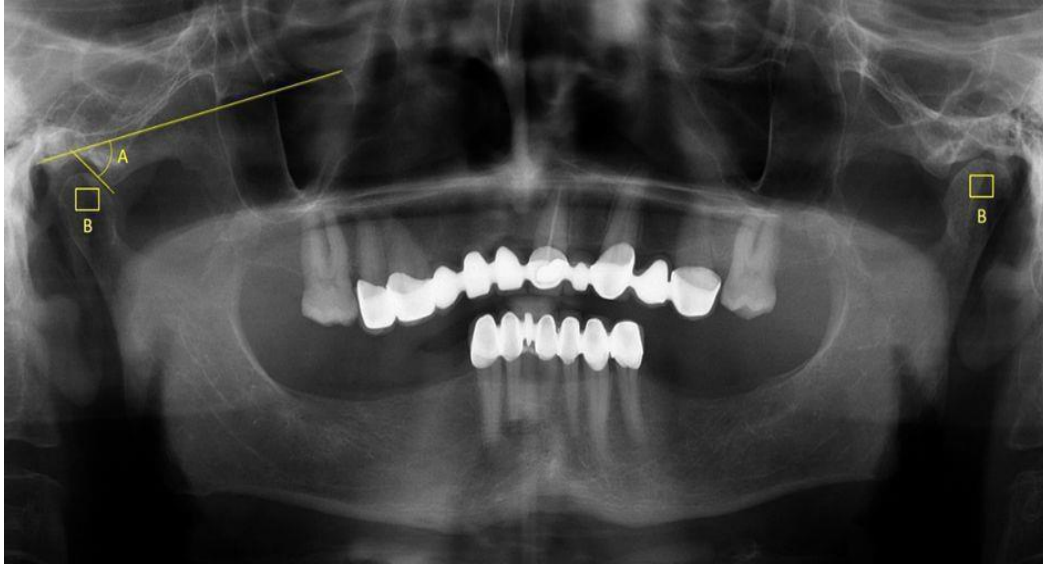

Figure 1: A: Angle of sagittal condylar guidance, B: Selection of the regions of interest of TMJs on both sides.




Figure 2: Steps of fractal analysis method using Image J program.

A: ROI after the application of a Gaussian blur filter (Gaussian blur is a low-pass filter, attenuating high frequency signals); **B:** Subtraction of region of interest from the background; **C:** Addition of 128 gray values to each pixel location; **D:** Image resulting from conversion to a binary image (Binary images are images that have been quantised to two values, usually denoted 0 and 1, but often with pixel values 0 and 255, representing black and white); **E:** Image resulting from erosion (Decreasing the number of several pixels); **F:** Dilatation (Adding pixels to the boundaries of objects in an image); **G:** Image resulting from inversion (Reversing the values of pixels); **H:** Skeletonization. (Removing pixels from the edges of objects until they are reduced to single-pixel-wide shapes)

Statistical Analysis

The conformity of the values obtained with normal distribution was evaluated using the Shapiro-Wilk test. A one-way analysis of variance (ANOVA) model was used while comparing the edentation status and relationships between fractals, and inclination measurements were evaluated using Pearson's correlation analysis. The level of statistical significance was determined as $p < 0.05$. The SPSS (ver. 23) program was employed for calculations.

RESULTS

The mean age of the individuals analyzed in this research was 52.5 years (range, 37-66). Table 1 shows

the number of individuals in the classes of edentation status and the total number of individuals by sex.

The mean measured value for the AEI and FD in the entire study population was 50.0 degrees (range, 32-60), and 1.311 (range, 1.043-1.542), respectively.

According to the AEI and FD of the edentation classes, no statistically significant differences were detected between each edentation class and the mean measurements of FD and AEI inclination ($p \geq 0.05$). In Table 2, the mean measurements of each edentation group are demonstrated.

Table 1: The number of individuals in classes of edentation status according to sexes and the total number of individuals

Classification	Sex				Total	
	Male		Female		n	%
	n	%	n	%		
Type I	12	30.8	10	20.4	22	25
Type II	13	33.3	9	18.4	22	25
Type III	6	15.4	16	32.7	22	25
Type IV	8	20.5	14	28.6	22	25
Total	39	100	49	100	88	100

Table 2: Comparison results of edentation classes in terms of mean of FD and AEI

	Classification	n	Mean	SD	Min	Max	p
FD of both sides	Type I	22	1.339	.109	1.072	1.542	0.066
	Type II	22	1.343	.103	1.043	1.522	
	Type III	22	1.281	.087	1.086	1.467	
	Type IV	22	1.281	.107	1.083	1.466	
AEI of both sides	Type I	22	48.785	8.237	38.216	70.709	0.446
	Type II	22	48.723	7.275	34.870	59.372	
	Type III	22	51.530	6.845	41.108	63.040	
	Type IV	22	51.001	6.551	32.929	59.609	

FD: Fractal dimension, AEI: Articular eminence inclusion, SD: Standart deviation, Min: Minimum, Max: Maximum, AE: Articular eminence

According to the sides of edentation classes in terms of AEI and FD measurements, no difference was estimated between both sides of the type I and III group in terms of AEI and FD ($p \geq 0.05$). In the type II group, a statistically significant difference was estimated between dentate and edentulous sides in terms of AEI

and FD ($p \leq 0.05$). However, in type II, AEI measurements were found slightly higher and FD measurements were found slightly lower on the dentate side when compared with the opposite edentulous side ($p \geq 0.05$). In type IV group, the mean value of the left

AEI was detected higher than the right side with statistical significance ($p \leq 0.05$) (Table 3).

According to the sex of edentation classes in terms of AEI and FD measurements, in the type IV group, the left

AEI of female patients was statistically steeper than the right side ($p = 0.012$). No statistically significant difference was estimated in the other dentate groups. In Table 4, FD and AEI measurement results are shown in each edentulous group of both male and female patients. According to the comparison of AEI and FD measurements of each group, a negative correlation was detected in the type II group between right-side FD and left-side AEI ($p \geq 0.05$).

Among all TMJ measurements, regardless of sex and edentulous status, left AEI was found statistically higher than the right side ($p = 0.002$), but no difference was estimated between right and left FD ($p \geq 0.05$). The details of the measurements are shown in Table 5.

Table 3: Comparison of FD and AEI of the dentate groups according to sides

Classification	Sides	Mean	P*
Type I	Right FD	1.352	0.397
	Left FD	1.327	
	Right AEI	48.926	0.709
	Left AEI	48.644	
Type II	Right FD	1.416	0,023
	Left FD	1.270	
	Right AEI	45.944	0.010
	Left AEI	51.502	
Type III	Right FD	1.305	0.346
	Left FD	1.258	
	Right AEI	51.208	0.600
	Left AEI	51.852	
Type IV	Right FD	1.299	0.383
	Left FD	1.264	
	Right AEI	49.271	0.012
	Left AEI	52.732	

FD: Fractal dimension; AEI: Articular eminence inclusion

Table 4: Mean measurements of FD and AEI in each edentation class according to sexes

Classification	Sex		N	Mean	SD	Minimum	Maximum
Type I	Male	FD	12	1.391	.066	1.309	1.542
		AEI	12	50.529	9.116	40.699	70.709
	Female	FD	10	1.277	.120	1.072	1.410
		AEI	10	46.692	6.914	38.216	58.205
Type II	Male	FD	13	1.337	.131	1.043	1.522
		AEI	13	47.687	5.594	37.960	56.325
	Female	FD	9	1.351	.049	1.284	1.422
		AEI	9	50.220	9.366	34.870	59.372
Type III	Male	FD	6	1.281	.058	1.180	1.354
		AEI	6	52.159	8.555	41.108	62.373
	Female	FD	16	1.282	.098	1.086	1.467
		AEI	16	51.294	6.402	41.176	63.040
Type IV	Male	FD	8	1.307	.147	1.083	1.466
		AEI	8	50.480	8.287	32.929	59.567
	Female	FD	14	1.267	.078	1.131	1.382
		AEI	14	51.299	5.664	39.599	59.609

FD: Fractal dimension, AEI: Articular eminence inclusion, SD: Standart deviation, Min: Minimum, Max: Maximum, AE: Articular eminence

Table 5: Descriptive values of FD and AEI measurements in study population

	N	Mean	SD	Min	Max	p
Right Side of FD	88	1.320	.131	.971	1.606	0.002*
Left Side of FD	88	1.302	.151	.896	1.673	
Right Side of AEI	88	48.837	8.137	30.194	67.900	
Left Side of AEI	88	51.182	7.959	33.560	73.517	

FD: Fractal dimension, AEI: Articular eminence inclusion, SD: Standart deviation, Min: Minimum, Max: Maximum, AE: Articular eminence

* statistically significance

DISCUSSION

The degrees of AEI determine the extent of the rotation of the disc on the condyle, as well as the condyle path of motion (25). It is undisputed that the TMJ is the most complicated joint in the body and its form becomes more complex because of the closeness to the dentition, muscles, and other oral structures (15). This study aims to assess the effect of edentulous types on AEI and the

trabecular structure of the mandibular condyle and also to compare these factors within each other. We hypothesized that different edentulism situations would affect AEI with the change of mandibular condyle pathway and structure and these findings would lead to finally change in the trabecular structure in the condyle. However, results showed no correlation between AEI, FD and edentate status. So, our hypothesis was rejected.

This was due to the lack of information regarding the duration of edentulousness of patients which affects bony components and trabecular structure. Another reason may be the use of panoramic radiography for AEI measurements. There may be minimal measurement errors due to panoramic radiographic image distortion and magnification.

Earlier research demonstrated that tooth wear and loss could lead to a detrimental impact on the TMJ such as destruction of the AE, and could expedite the advancement of degenerative joint disease (15,16,27). Also, masticatory load on the TMJ surfaces leads to adaptation changes in trabecular bone characteristics such as architecture and the number of trabeculae changes. Estimation of these bone alterations is crucial to identify the level of osteoarthritic changes (23). When compared with the cortical counterpart, trabecular bone is more appropriate for the estimation of bone alterations due to the higher metabolic activity (28).

In TMJ imaging, cone beam computed tomography (CBCT) is known to be better in diagnostic efficacy than conventional imaging but this imaging modality cannot necessarily replace conventional methods due to higher radiation exposures and nonroutine clinical use. Fractal analysis, which is a technique of defining complex shapes such as the trabecular structure of bone, is superior to conventional imaging such as panoramic radiographs deriving more information for physicians about trabecular bone because the bone changes cannot be seen with the naked eye (29). Two-dimensional radiographs were proved to be effective in the fractal analysis of bone quality consisting of connectivity, microstructure, density, and anisotropy when compared with histomorphometric analysis (30).

A large number of studies have been carried out to date regarding the morphology of TMJ components, but there is little information on the relationship between one side missing posterior teeth and the osteoarthritic alterations in the TMJ, such as flattening of the AE in contemporary populations (27). In the current study, we selected panoramic radiographs of patients aged over 20 years due to AEI developmental implications. AEI development is documented to be 45% completed when the primary dentition is completed, 70-72% of the development has occurred when the age is nearly 10 years, and 90-94% of the development is complete by the age of 20 years (6).

Appropriate ROI and scanning protocol selection are important in the estimation of articular bone detriment and osteoarthritic alteration in the TMJ region. Lee et al. stated that linear ROI selection was found inadequate in the calculation of fractal dimensions, and Jolley et al. stated that FD might also be affected by minimum alterations in exposure parameters such as kVp, exposure time, and projection angle (31,32). For these

reasons, in the current approach, panoramic radiographs were acquired at standard exposure factors, and standardized ROIs were chosen as 84x84-pixel squares within the cortical boundaries of left and right mandibular condyles.

Lack of occlusal anchorage is an effective determinant for degenerative alterations of the TMJ, which finally leads to bone contour differentiation and flattening of the AE. Our results demonstrated that AEI was negatively correlated with FD and exhibited slightly lower results on the edentate side. However, these results did not reach statistical significance.

Fang et al. found that unilateral edentate patients showed lower AEIs, smaller craniocervical angles, and a lower percentage of the occlusal plane passing through the overlap of the first and second cervical vertebrae (18). Another perspective, by Zabarovic et al., evidenced that the steeper inclination in males in comparison with females, approved the sexual dimorphism however, was not statistically significant (33).

Zheng et al. published a comprehensive review regarding the structure and function of TMJ in the edentulous population, as well as the prevalence of TMJ disorder (34). After detailly analysing 44 articles they stated that edentulousness causes the loss of the occlusal relationship, which can cause degenerative changes of TMJ components involving the changes in morphology and bone mass density of condyle, articular fossa, and articular eminence.

According to AEI, our study population showed higher mean measurement results and interval (50 and 32 degrees to 60 degrees) when compared with Chiang et al.'s study population (37.7 and 4 degrees to 58 degrees) (27). Similar to the current measurements, Chiang et al. estimated that the AEI of the dentate group was slightly steeper than that of the edentate group, but this variation was not statistically significant (27).

The AEI was measured in two different ways in the previous studies: best-fit line way and top-roof line way (6,25). In our study, we used the top-roof line way because it was suggested that the top-roof line way represents the AE morphology better.

This study has limitations. The first is the lack of patient information regarding the duration of tooth loss so a longitudinal study is required to analyze whether the time of prosthesis use has a different association with the AEI. The second limitation is the lack of standardization of the prosthesis used by the patients due to the execution of different centers. The third limitation is minimal radiographic image distortion and magnification of panoramic radiography.

Although there are studies on whether AEI changes in different edentulous groups, there is no study examining this by comparing it using fractal analysis. Finally, we can summarize the results of this study by stating that no

correlation was detected between AEI, FD, and edentate status. However, a negative relation was estimated between AEI and FD in unilateral edentate groups on the opposite sides. Articular eminence forms the S-shaped condyle path of the TMJ. AEI towards the occlusal plane depends on age and function. It is important to change this inclination because the path of the condyle will change depending on the AEI. The excess chewing force in the dentate side and the increase in AEI due to the narrowing movement area of the condyle increase the amount of resorption in the TMJ.

Conflict of Interest: The authors have no conflicts of interest to declare.

Researchers' Contribution Rate Statement:
Concept/Design: ESKÇ, MFŞ, SB;
Analysis/Interpretation: Bİ, HA, EŞKÇ; Data
Collection: SB, MFŞ; Writer: Bİ, EŞKÇ, MFŞ; Critical
Review: ESKÇ, MFŞ, SB, Bİ ; Approver: ESKÇ, MFŞ,
SB, Bİ

Support and Acknowledgment: No financial support was received from any institution or person.

Ethical Approval: Clinical Researches Ethics Committee of the Bolu Abant İzzet Baysal University approved the current retrospective study with protocol no: 2022/152.

REFERENCES

1. Laskin DM, Greene CS, Hylander WL. Temporomandibular disorders: An evidence-based approach to diagnosis and treatment. Chicago, Quintessence, 2006.
2. Bermejo-Fenoll A, Puchades-Orts A, Sanchez del Campo F, Panchon-Ruiz A, Herrera-Lara M. Morphology of the meniscotemporal part of the temporomandibular joint and its biomechanical implications. *Acta Anat (Basel)*. 1987;129(3):129-220-226.
3. Hatcher DC, Faulkner MG, Hay A. Development of mechanical and mathematic models to study temporomandibular joint loading. *J Prosthet Dent*. 1986;55(3):377-384.
4. Pandis N, Karpac J, Trevino R, Williams B. A radiographic study of condyle position at various depths of cut in dry skulls with axially corrected lateral tomograms. *Am J Orthod Dentofacial Orthop*. 1991;100(2):116-122.
5. O'Ryan F, Epker BN. Temporomandibular joint function and morphology: Observations on the spectra of normalcy. *Oral Surg Oral Med Oral Pathol*. 1984;58(3):272-279.
6. Katsavrias EG. Changes in articular eminence inclination during the craniofacial growth period. *Angle Orthod*. 2002;72(3):258-264.
7. Jasinevicius TR, Pyle MA, Lalumandier JA, et al. Asymmetry of the articular eminence in dentate and partially edentulous populations. *Cranio*. 2006;24(2):85-94.
8. Costa EDD, Peyneau PD, Roque-Torres GD, et al. The relationship of articular eminence and mandibular fossa morphology to facial profile and gender determined by cone beam computed tomography. *Oral Surg Oral Med Oral Pathol Oral Radiol*. 2019;128(6):660-666.
9. Kranjčić J, Šlaus M, Vodanović M, Peršić S, Vojvodić D. Articular eminence inclination in medieval and contemporary croatian population. *Acta Clin Croat*. 2016;55(4):529-534.
10. Hinton RJ. Changes in articular eminence morphology with dental function. *Am J Phys Anthropol*. 1981;54(4):439-455.
11. Pirttiniemi P, Kantomaa T, Tuominen M, Salo L. Articular disc and eminence modeling after experimental relocation of the glenoid fossa in growing rabbits. *J Dent Res*. 1994;73(3):536-543.
12. Raustia AM, Pirttiniemi P, Salonen MA, Pyhtinen J. Effect of edentulousness on mandibular size and condyle-fossa position. *J Oral Rehabil*. 1998;25(3):174-179.
13. Sa SC, Melo SL, Melo DP, Freitas DQ, Campos PS. Relationship between articular eminence inclination and alterations of the mandibular condyle: A CBCT study. *Braz Oral Res*. 2017;31:e25.
14. Schuster AJ, Pastorino DA, Marcello-Machado RM, Faot F. Influence of age and time since edentulism on masticatory function and quality of life in implant-retained mandibular overdenture wearers: 1-year results from a paired clinical study. *Int J Oral Maxillofac Implants*. 2019;34(6):1466-1474.
15. Granados JI. The influence of the loss of teeth and attrition on the articular eminence. *J Prosthet Dent*. 1979;42(1):78-85.
16. Tallents RH, Macher DJ, Kyrkanides S, Katzberg RW, Moss ME. Prevalence of missing posterior teeth and intraarticular temporomandibular disorders. *J Prosthet Dent*. 2002;87(1):45-50.
17. Unal Erzurumlu Z, Celenk P. A radiological evaluation of the effects of edentulousness on the temporomandibular joint. *J Oral Rehabil*. 2020;47(3):319-324.
18. Fang TH, Chiang MT, Hsieh MC, Kung LY, Chiu KC. Effects of unilateral posterior missing-teeth on the temporomandibular joint and the alignment of cervical atlas. *PLoS One*. 2020;15(12):e0242717.
19. Csadó K, Márton K, Kivovics P. Anatomical changes in the structure of the temporomandibular joint caused by complete edentulousness. *Gerodontol*. 2012;29(2):111-116.
20. Oruba Z, Malisz P, Sendek J, et al. Flattening of the articular eminence is associated with the loss of occlusal support: Radiological study. *Aust Dent J*. 2020;65(1):53-57.
21. Geraets WG. Comparison of two methods for measuring orientation. *Bone*. 1998;23(4):383-388.
22. Yi WJ, Heo MS, Lee SS, et al. Direct measurement of trabecular bone anisotropy using directional fractal dimension and principal axes of inertia. *Oral Surg Oral Med Oral Pathol Oral Radiol Endod*. 2007;104(1):110-116.
23. Arsan B, Köse TE, Çene E, Özcan İ. Assessment of the trabecular structure of mandibular condyles in patients with temporomandibular disorders using fractal analysis. *Oral Surg Oral Med Oral Pathol Oral Radiol*. 2017;123(3):382-391.
24. Demiralp K, Kurşun-Çakmak E, Bayrak S, et al. Trabecular structure designation using fractal analysis technique on panoramic radiographs of patients with bisphosphonate intake: A preliminary study. *Oral Radiol*. 2019;35(1):23-28.
25. Sümbüllü MA, Çağlayan F, Akgül HM, Yılmaz AB. Radiological examination of the articular eminence morphology using cone beam CT. *Dentomaxillofac Radiol*. 2012;41(3):234-240.
26. White SC, Rudolph DJ. Alterations of the trabecular pattern of the jaws in patients with osteoporosis. *Oral Surg Oral Med Oral Pathol Oral Radiol Endod*. 1999;88(5):628-635.

27. Chiang MT, Li TI, Yeh HW, et al. Evaluation of missing-tooth effect on articular eminence inclination of temporomandibular joint. *J Dental Sci.* 2015;10(4):383-387.
28. Fazzalari NL, Parkinson IH. Fractal properties of subchondral cancellous bone in severe osteoarthritis of the hip. *J Bone Miner Res.* 1997;12(4):632-640.
29. Dougherty G, Henebry GM. Fractal signature and lacunarity in the measurement of the texture of trabecular bone in clinical CT images. *Med Eng Phys.* 2001;23(6):369-380.
30. Majumdar S, Lin J, Link T, et al. Fractal analysis of radiographs: Assessment of trabecular bone structure and prediction of elastic modulus and strength. *Med Phys.* 1999;26(7):1330-1340.
31. Lee KI, Choi SC, Park TW, You DS. Fractal dimension calculated from two types of region of interest. *Dentomaxillofac Radiol.* 1999;28(5):284-289.
32. Jolley L, Majumdar S, Kapila S. Technical factors in fractal analysis of periapical radiographs. *Dentomaxillofac Radiol.* 2006;35(6):393-397.
33. Zabarović D, Jerolimov V, Carek V, et al. The effect of tooth loss on the TM-joint articular eminence inclination. *Coll Antropol.* 2000;24 Suppl 1:37-42.
34. Zheng H, Shi L, Lu H, et al. Influence of edentulism on the structure and function of temporomandibular joint. *Heliyon.* 2023;9(10):e20307.