



An Unexpected Cause of Abdominal Pain in Pregnancy: A Case Report

Gebelikte Karın Ağrısının Beklenmeyen Bir Nedeni: Olgu Sunumu

Fatma Zehra KURNUÇ¹ , Deniz BALSAK^{2*} , Pelin OYARDI¹ 

¹Department of Obstetrics and Gynecology, Siirt Training and Research Hospital, Siirt, Türkiye

²Department of Obstetrics and Gynecology, Siirt Medical Faculty, Siirt, Türkiye

Geliş Tarihi (Received): 13.01.2024

Kabul Tarihi (Accepted): 06.02.2024

Yayın Tarihi (Published): 30.04.2024

Abstract

Acute abdomen during pregnancy is a condition that requires rapid diagnosis and treatment and threatens both maternal and fetal health. Adnexal masses may present different clinical presentations during pregnancy. The important thing is rapid diagnosis and application of the appropriate treatment method. Adnexal torsion should be kept in mind in the differential diagnosis of patients presenting with acute abdomen during pregnancy. Early diagnosis and treatment are vital for organ-preserving surgery.

In this article, we presented the successful treatment of a patient with laparoscopy surgery who applied to our clinic due to acute abdomen and was diagnosed with left ovarian torsion at 12 weeks' gestation.

Keywords: Acute Abdominal Pain, Ovarian Torsion, Pregnancy.

&

Öz

Gebelikte akut batın tablosu, hızlı tanı ve tedavi edilmesi gereken ve hem maternal hem de fetal sağlığı tehdit eden bir durumdur. Adneksial kitleler gebelikte farklı klinik tablolar sergileyebilmektedirler. Önemli olan hızlı tanı ve uygun tedavi yönteminin uygulanmasıdır. Gebelik sırasında akut batın kliniği ile başvuran hastalarda ayırıcı tanıda adneksiyal torsiyon mutlaka akılda tutulmalıdır. Erken tanı ve tedavi organ koruyucu cerrahi yapılması açısından hayati öneme sahiptir.

Bu yazıda kliniğimize akut batın nedeniyle başvuran 12 haftalık gebelik ile birlikte sol over torsiyon tespit edilen olgunun laparoskopik cerrahi ile başarılı bir şekilde tedavisini sunduk.

Anahtar Kelimeler: Gebelik, Akut Karın Ağrısı, Over Torsiyonu.

Atıf/Cite as: Kurnuç FZ, Balsak D, Oyardı P. An Unexpected Cause of Abdominal Pain in Pregnancy: A Case Report. Abant Med J. Nisan 2024;13(1):41-43. doi:10.47493/abantmedj.1419107

Copyright © Published by Bolu Abant İzzet Baysal University, Since 2022 – Bolu

*Sorumlu Yazar (Corresponding Author): Deniz Balsak, e-mail: denizbalsak@gmail.com



This work is licensed under a Creative Commons Attribution-NonCommercial-NoDerivatives 4.0 International License.

Introduction

Adnexal torsion during pregnancy is a rare obstetric emergency. It can easily be misdiagnosed since the patients often have nonspecific clinical features. Early detection and therapy is essential to preserve the ovary.

Here we present our experience with of adnexal torsion in the first trimester, managed by laparoscopic approach.

Case report:

A 24-year-old healthy woman, gravida 7 para 6, admitted to the emergency room of Diyarbakır ministry of health maternity hospital with a gradually worsening right lower quadrant pain, nausea and emesis. Her abdominal examination was significant with rebound and guarding. She was a febrile, hemodynamically stable. White blood cell count in her CBC was 12,600 /mCL. Ultrasonography revealed a single viable fetus of 12 week of gestation and simple cyst located in the right adnexa with the measurement of 8x7x6 cm. no free fluid was reported. Doppler flow to the right adnexa was found to be deteriorated. Considering the clinical findings, she was diagnosed as adnexal torsion and laparoscopy was immediately performed.

Intraoperative findings included a gravid uterus, a normal appendix and abdominal organs and a right ovarian cyst of approximately 8 cm. her right ovary had a bluish hue in consequence of twisting twice at the infundibulopelvic ligament. Detorsion of the twisted adnexa was carefully performed by blunt probes, nevertheless, the cyst was punctured and the cyst contents- approximately 200 ml of yellow simple fluid- was aspirated. After the homeostasis was controlled, the operation was completed.

The patient, whose postoperative condition was normal, was discharged home after preventive treatment against uterine contractions. The following day. The pregnancy has continued uneventfully to date.

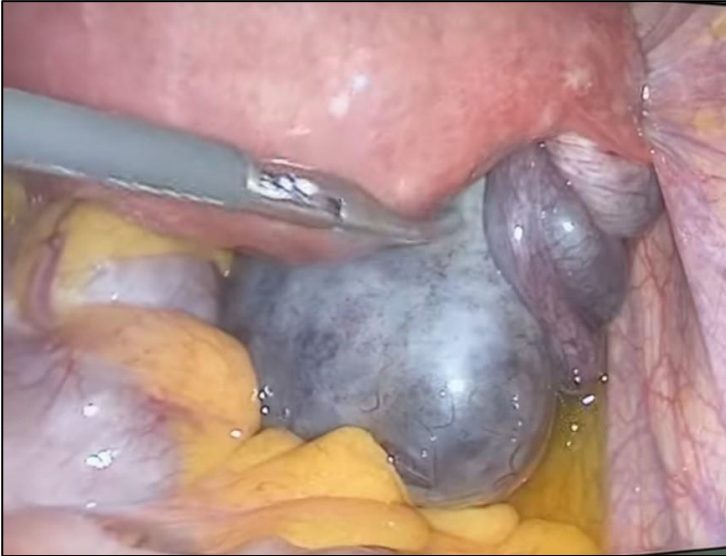


Figure 1: Itraoperative view of torsioned over

Discussion

The most common complaint of pregnancy is abdominal pain and pelvic discomfort. Symptoms of torsion arise similarly in both pregnant and nonpregnant patients such as right sided pelvic pain with or without nausea and vomiting (1,2). Uterine rupture, urethral or renal colic, HELLP syndrome, appendicitis and leiomyoma necrosis should be excluded in the differential diagnosis. Alterations in common presentation of serious acute abdominal events are expected owing to the state of pregnancy. Pregnancy also changes normal biochemical parameters. All these factors can lead to unsuccessful or delayed diagnosis (1).

Among gynecological emergencies, adnexal torsion accounts for 3% of all surgical interventions (2). The incidence of ovarian torsion during pregnancy is 1:10,000 to 5:10,000 pregnancies; 16% of pregnancies are achieved by ovulation induction and complicated by ovarian hyperstimulation. (3,4). The highest incidence is in the first trimester. As the size of the adnexal mass increase, it has tendency to twist and be unable to unwind

itself accordant with the changing situation of the adnexal mass and gravid uterus. Adnexal torsion is more common between the 10th and 17th weeks of gestation, this is probably due to the transport of adnexal masses by the pregnant uterus through the pelvic cavity together with a larger surrounding environment in the second trimester (5). The right ovary is torsioned more often than the left. In our case of 12-week-gestation, a simple cyst caused torsion of the right adnexa reluctant with the literature.

Widespread use of pelvic ultrasonography with Doppler evaluation brings with early diagnosis of adnexal torsion. The ovary twists around its pedicle and torsion occurs resulting in the circulatory stasis. Sonographic findings associated with the diagnosis of adnexal torsion include unilateral ovarian enlargement, peripheral cystic structures of the ovary, marked stromal edema, decreased or absent Doppler flow in pelvic fluid and ovary, and these were mostly detected in our patient (2).

Previous studies have shown that laparoscopy is not associated with an increased risk of spontaneous miscarriage or preterm birth (6). Laparoscopic surgery during pregnancy is shown to provide shorter hospital stay as well as decreased maternal and fetal morbidity (7). Therefore, we preferred laparoscopic intervention in this case. Detorsion of twisted adnexas should be considered as the first step in treatment. Since progesterone is secreted from the corpus luteum gravidita. It is important to protect the adnexa in pregnant women, especially in the first 12 weeks of pregnancy. Detorsion of hemorrhagic adnexa has no danger of thromboembolic complications, as well (8). The twisted adnexa were carefully detorsioned in our patient. However, the cyst perforated, so preventive progesterone treatment continued during postoperative period. In a study, Zweizig et al. (8) showed that overall morbidity was 12% in the salpingo-oophorectomy group and 3% in the conservatively treated control group.

In conclusion, Adnexal torsion should be considered in case of abdominal pain during pregnancy. Delayed diagnosis leads to a decreased chance of ovarian preservation. Laparoscopy allows appropriate surgical treatment with low fetal and maternal morbidity.

Informed Consent: Written consent was obtained from the patient.

Conflict of Interest: Authors declared no conflict of interest.

Financial Disclosure: Authors declared no financial support.

Author Contributions: Idea/Concept: FZK, DB; Design: DB, PO; Supervision: FZK, DB; Funding: FZK, DB, PO; Materials: FZK, DB, PO; Data Collection/Processing: FZK, DB, PO; Analysis/Interpretation: FZK, DB, PO; Literature Review: FZK, PO; Drafting/Writing: FZK, PO; Critical Review: FZK, DB, PO. The authors have accepted responsibility for the entire content of this manuscript and approved its submission.

References

1. Chandrachan E, Arulkumaran S. Acute abdomen and abdominal pain in pregnancy. *Obstetrics, Gynaecology and Reproductive Medicine*. 2008;18(8):205-12.
2. Rackow BW, Patrizio P. Successful pregnancy complicated by early and late adnexal torsion after in vitro fertilization. *Fertil Steril*. 2007;87(3):697.e9-12.
3. Djavadian D, Braendle W, Jaenicke F. Laparoscopic oophoropexy for the treatment of recurrent torsion of the adnexa in pregnancy: case report and review. *Fertil Steril*. 2004;82(4):933-6.
4. Condous G, Khalid A, Okaro E, Bourne T. Should we be examining the ovaries in pregnancy? Prevalence and natural history of adnexal pathology detected at first-trimester sonography. *Ultrasound Obstet Gynecol*. 2004;24(1):62-6.
5. Yen CF, Lin SL, Murk W, Wang CJ, Lee CL, Soong YK, et al. Risk analysis of torsion and malignancy for adnexal masses during pregnancy. *Fertil Steril*. 2009;91(5):1895-902.
6. Cagino K, Li X, Thomas C, Delgado D, Christos P, Acholonu U Jr. Surgical Management of Adnexal Masses in Pregnancy: A Systematic Review and Meta-analysis. *J Minim Invasive Gynecol*. 2021;28(6):1171-1182.e2.
7. Mathevet P, Nessah K, Dargent D, Mellier G. Laparoscopic management of adnexal masses in pregnancy: a case series. *Eur J Obstet Gynecol Reprod Biol*. 2003;108(2):217-22.
8. Zweizig S, Perron J, Grubb D, Mishell DR Jr. Conservative management of adnexal torsion. *Am J Obstet Gynecol*. 1993;168(6 Pt 1):1791-5.