

## Current approaches, significance and prognostic impact of lumbar ligament flavum preserving surgeries

*Ligament flavum koruyucu cerrahinin güncel yaklaşımları, önemi ve prognoza etkisi*

Baran Can Alpergin, Murat Zaimoğlu, Ömer Mert Özpişkin, Elif Gökalp, Murat Büyüktepe, Fatih Yakar, Ümit Eroğlu

Posted date:16.01.2024

Acceptance date:20.03.2024

### Abstract

**Purpose:** The aim of this study is to evaluate the use of flavum-preserving surgeries in lumbar disc herniation surgery, compare their clinical outcomes with standard microdiscectomy techniques, and demonstrate the transflaval microdiscectomy technique.

**Material and methods:** Between 2020 and 2023, a total of 48 patients who underwent transflaval microdiscectomy and 48 patients who underwent standard microdiscectomy at a single center were included in the study. Epidemiologic characteristics of the groups were described, and from the preoperative and postoperative 12 months visual analog scale scores for leg pain (LPVAS) and back pain (BPVAS) were retrospectively analyzed.

**Results:** There is no significant difference between the groups in preoperative mean LPVAS scores ( $p=0.474$ ) and there is no significant difference between the groups in postoperative mean LPVAS scores ( $p=0.598$ ). There is no significant difference between the groups in preoperative mean BPVAS scores ( $p=0.608$ ). However, there is a significant difference between the groups in postoperative mean BPVAS scores ( $p<0.001$ ). This result indicates transflaval microdiscectomy surgery shows better clinical outcomes in follow-up in terms of back pain compared to standard microdiscectomy surgery. In Group 1 (transflaval group), recurrence occurred in 3 patients, while in Group 2 (microdiscectomy), 4 patients experienced recurrence. During the reoperation of patients with recurrence, none of the patients in Group 1 exhibited epidural fibrosis, whereas all patients in Group 2 showed signs of epidural fibrosis. Additionally, during reoperation, no patient in Group 1 experienced dural injury, while dural injury occurred in 2 patients in Group 2.

**Conclusion:** Preserving the ligamentum flavum structure and minimizing its damage during lumbar microdiscectomy surgery results in less axial pain and improved clinical outcomes during follow-ups.

**Keywords:** Ligamentum flavum, ligamentum flavum preserving surgery, transflaval microdiscectomy.

Alpergin BC, Zaimoglu M, Ozpiskin OM, Gokalp E, Buyuktepe M, Yakar F, Eroglu U. Current approaches, significance and prognostic impact of lumbar ligament flavum preserving surgeries. Pam Med J 2024;17:432-439.

### Öz

**Amaç:** Bu çalışmanın amacı, lomber disk hernisi cerrahisinde flavum koruyucu cerrahilerin kullanımını değerlendirmek, klinik sonuçlarını standart mikrodiskektomi teknikleri ile karşılaştırmak ve transflaval mikrodiskektomi tekniğini göstermektir.

**Gereç ve yöntem:** 2020-2023 yılları arasında tek bir merkezde transflaval mikrodiskektomi uygulanan toplam 48 hasta ve standart mikrodiskektomi uygulanan 48 hasta çalışmaya dahil edildi. Grupların yaş ve cinsiyet özellikleri tanımlandı ve bacak ağrısı (LPVAS) ve sırt ağrısı (BPVAS) için ameliyat öncesi ve sonrasındaki 12 ay boyunca izlenerek VAS skorları retrospektif olarak analiz edildi.

**Bulgular:** Ameliyat öncesi ortalama LPVAS skorlarında gruplar arasında ve ameliyat sonrası ortalama LPVAS skorlarında anlamlı fark bulunamadı (Sırasıyla  $p=0,474$  ve  $p=0,598$ ). Ameliyat öncesi ortalama BPVAS skorlarında gruplar arasında da anlamlı bir fark gözlenmedi ( $p=0,608$ ). Ancak ameliyat sonrası ortalama BPVAS skorlarında gruplar arasında anlamlı bir fark saptandı ( $p<0,001$ ) Bu sonuç, transflaval mikrodiskektomi ameliyatının standart mikrodiskektomi ameliyatına kıyasla bel ağrısı açısından takipte daha iyi klinik sonuçlar gösterdiğini ortaya koymaktadır.

Baran Can Alpergin, M.D. Ankara University, School of Medicine, Department of Neurosurgery, Ankara, Türkiye, e-mail: balpergin@gmail.com (<https://orcid.org/0000-0002-3575-0480>)

Murat Zaimoğlu, Asst. Prof. Ankara University, School of Medicine, Department of Neurosurgery, Ankara, Türkiye, e-mail: m.zaimoglu.neurosurgery@gmail.com (<https://orcid.org/0000-0001-5330-1251>)

Ömer Mert Özpişkin, M.D. Ankara University, School of Medicine, Department of Neurosurgery, Ankara, Türkiye, e-mail: omerozpiskin@gmail.com (<https://orcid.org/0000-0002-8261-1766>) (Corresponding Author)

Elif Gökalp, M.D. Ankara University, School of Medicine, Department of Neurosurgery, Ankara, Türkiye, e-mail: elifgokalpmd@gmail.com (<https://orcid.org/0000-0001-7022-4286>)

Murat Büyüktepe, Specialist, Ankara University, School of Medicine, Department of Neurosurgery, Ankara, Türkiye, e-mail: muratbuyuktepe@hotmail.com (<https://orcid.org/0000-0002-2599-8087>)

Fatih Yakar, Assoc. Prof. Pamukkale University, School of Medicine, Department of Neurosurgery, Denizli, Türkiye, e-mail: yakarneurosurgery@gmail.com (<https://orcid.org/0000-0001-7414-3766>)

Ümit Eroğlu, Assoc. Prof. Ankara University, School of Medicine, Department of Neurosurgery, Ankara, Türkiye, e-mail: umitkovikeroğlu@hotmail.com (<https://orcid.org/0000-0001-8623-071X>)

Grup 1'de (transflaval cerrahi grubu) 3 hastada nüks görülürken, Grup 2'de (mikrodissektomi grubu) 4 hastada nüks görüldü. Nüks görülen hastaların yeniden ameliyatı sırasında, Grup 1'deki hiçbir hastada epidural fibrozis görülmezken, Grup 2'deki tüm hastalarda epidural fibrozis belirtileri görüldü. Ayrıca, yeniden ameliyat sırasında Grup 1'deki hiçbir hastada dural yaralanma görülmezken, Grup 2'deki 2 hastada dural yaralanma meydana gelmişti.

**Sonuç:** Lomber mikrodissektomi ameliyatı sırasında ligamentum flavum yapısının korunması ve hasarının en aza indirilmesi, takiplerde daha az aksiyel ağrı ve daha iyi klinik sonuçlarla sonuçlanır.

**Anahtar kelimeler:** Ligamentum flavum, ligamentum flavum koruyucu cerrahi, transflaval mikrodissektomi.

Alpergin BC, Zaimoğlu M, Özpişkin ÖM, Gökalp E, Büyüktepe M, Yakar F, Eroğlu Ü. Ligament flavum koruyucu cerrahinin güncel yaklaşımları, önemi ve prognoza etkisi. Pam Tıp Derg 2024;17:432-439.

## Introduction

Intervertebral disc degeneration is a chronic process that naturally occurs as a consequence of aging, influenced by genetic factors, mechanical stress, and axial loading on the spine [1]. One of the most commonly encountered conditions following lumbar disc degeneration is lumbar disc herniation (LDH). LDH is a condition that presents with symptoms of lower back pain and leg pain and can be treated through conservative or surgical methods [2]. There are several methods and approaches defined and currently in use for the surgical treatment of LDH's. The most common surgical techniques today include standard open discectomy, standard open microscopic discectomy, percutaneous tubular microscopic discectomy, biportal endoscopic discectomy, and uniportal endoscopic discectomy [3-5].

The Ligamentum Flavum (LF) is a ligament that extends between two adjacent laminae and consists of two layers, namely the superficial and deep layers. It attaches to the facet joints on the lateral side, interspinous ligament on the medial side and is a yellow-colored, elastic ligament [6]. LF serves as a ligament that resists hyperflexion movement in the spine, thus limiting this motion and assisting in stabilizing the spine. However, it should be noted that due to this mechanical stress, ligamentum flavum hypertrophy and ossification can develop, which may be a contributing factor to lumbar spinal stenosis [7, 8]. The LF was typically damaged during standard LDH surgery. However, it should be noted that preserving the structure of the LF or minimizing its damage is crucial in preventing post-surgical adhesions and reducing the development of epidural fibrous tissue [9, 10].

There are various methods and techniques defined for performing LDH surgery while preserving the LF. In these techniques, typically following a sharp dissection applied to the LF, a window extending into the epidural space is created by reflecting the LF to one side (laterally or caudally), and the microsurgical discectomy procedure is then carried out through this window [11, 12]. In our LF preserving LDH surgery technique, which we refer to as Transflaval Lumbar discectomy, we create a window using suspension sutures from both sides after making a longitudinal incision on LF. After removing the sequestered disc fragment through the resulting opening, we suture the created LF layers. This way, a transverse incision is not made, and we believe that it better preserves the mechanical resistance against flexion movement of the LF.

## Material and methods

### Study population

Between 2020 and 2023, a total of 96 patients who underwent LDH surgery at our institution were included in the study. All patients in the study population had undergone surgery due to sequestered disc herniation at the L5-S1 level. Among them, 48 patients (28 males and 20 females) were operated on using the transflaval microdiscectomy technique (Group 1), while 48 patients (27 males and 21 females) underwent surgery using the standard microscopic discectomy technique (Group 2). Group 1 consists of patients who underwent surgery using the transforaminal microdiscectomy method, while Group 2 serves as the control group and consists of patients who underwent standard microdiscectomy.

The age and gender characteristics of all patients, Visual Analog Scale (VAS) scores

recorded 24 hours before surgery, VAS scores at 12 months postoperatively, and recurrence rates at postoperative period were noted. When calculating preoperative and postoperative VAS scores, leg pain VAS (LP-VAS) and back pain VAS (BP-VAS) were calculated for each group.

### Statistical analysis

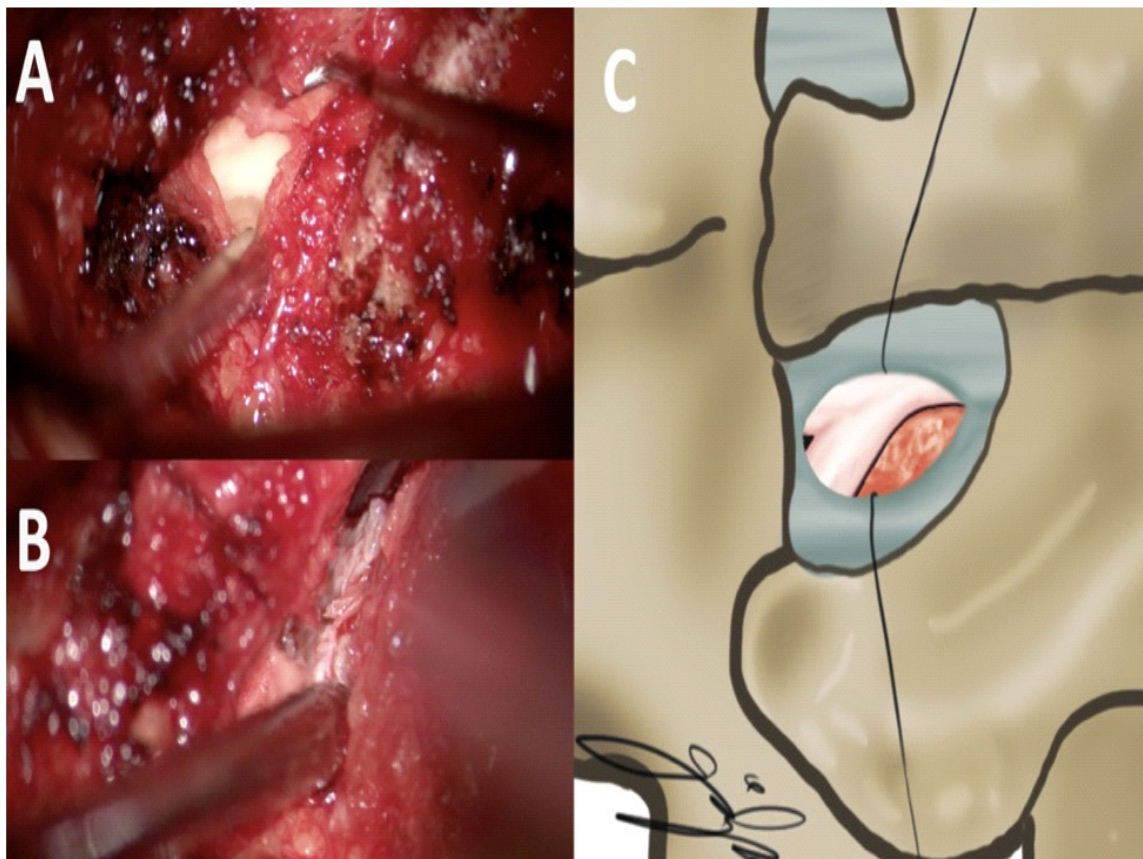
Statistical analyses were conducted using IBM SPSS Statistics version 22.0 for Windows (IBM, Armonk, NY). The results were evaluated with a 95% confidence interval, and the  $p$ -value  $<0.05$  was considered significant.

This retrospective study was approved by Ankara University Faculty of Medicine Clinical Research Ethics Committee.

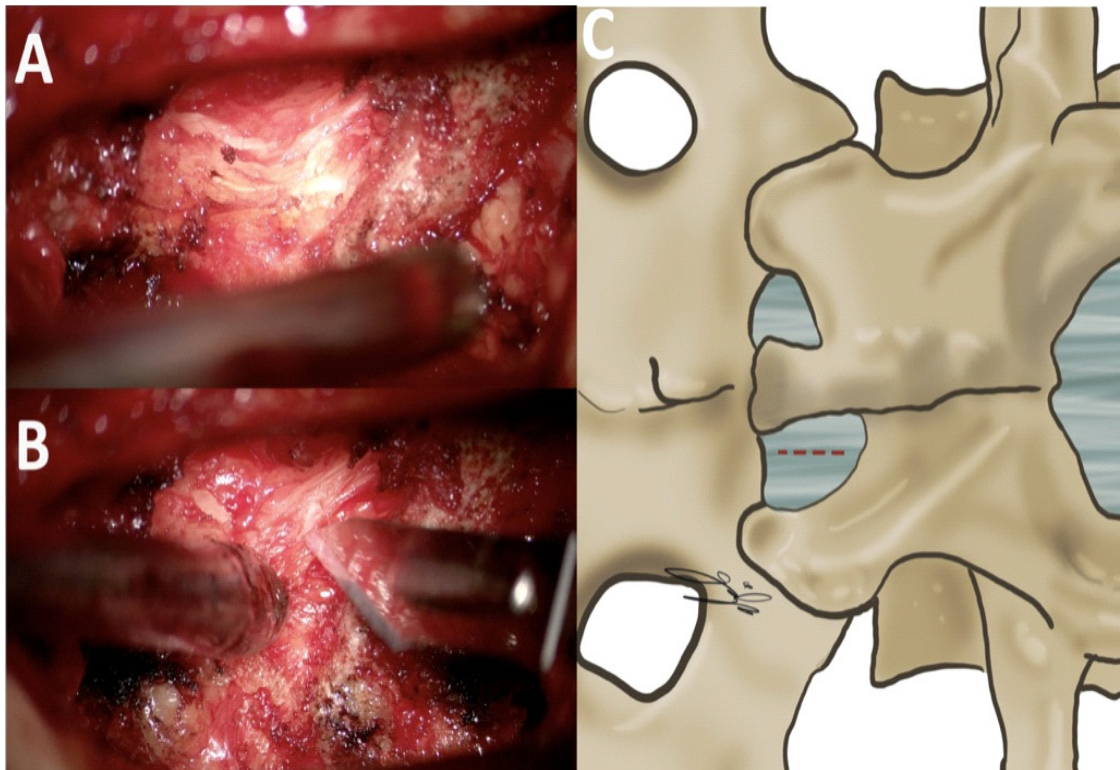
### Operative technique for transflaval lumbar discectomy

After ensuring appropriate surgical sterilization conditions and draping in a prone position, a midline skin incision was

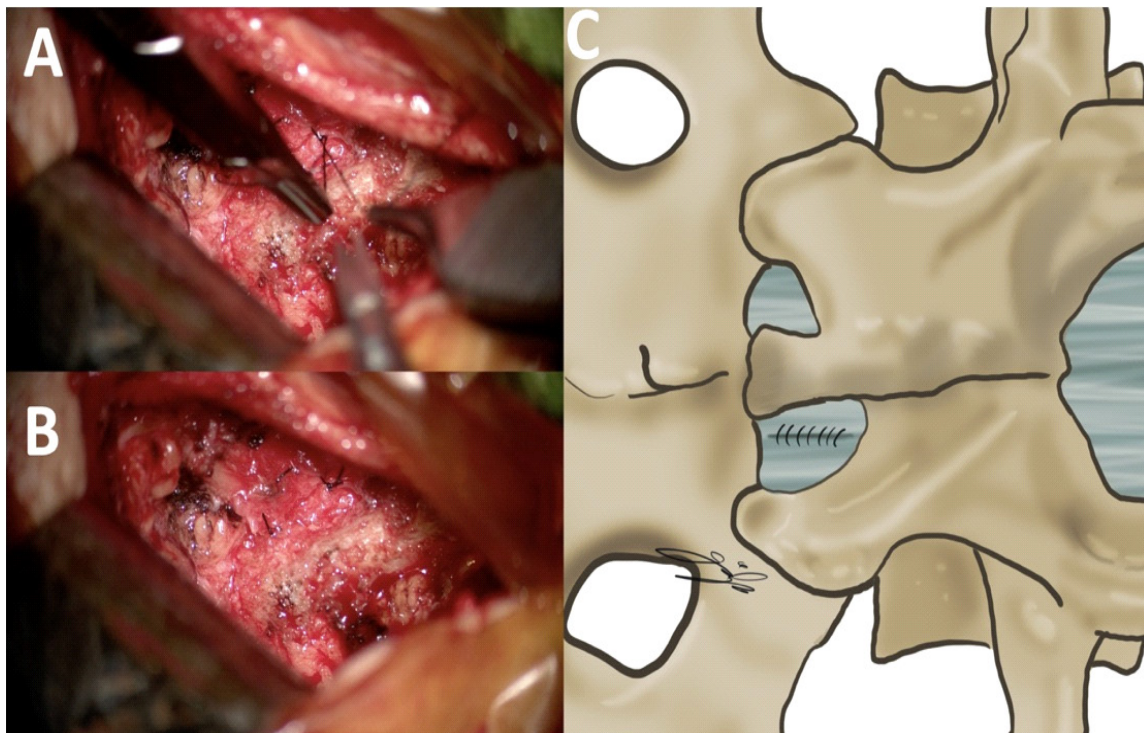
made to accommodate the L5-S1 disc space. Subsequently, unilateral subperiosteal dissection of the muscles attached to the spinous process and lamina was performed. Using a microscope, the ligamentum flavum (LF) structure extending between the laminae was identified without performing laminectomy, and a 1-centimeter incision was made parallel to the LF fibers (Figure 1). The two LF leaves created with this incision were suspended using 4/0 Vicryl sutures, and a window extending into the epidural space was formed (Figure 2). Looking through this window, the traversing S1 root and the fragmentary disc tissue situated laterally to S1 root were identified with the use of a microdissector and a micro nerve hook (Figure 2). Sequestrectomy was performed using microforceps, and after confirming that the root was relieved, the LF defect was sutured with 4/0 Vicryl suture (Figure 3). After suturing the muscles, fascia, and skin in their anatomical planes, the surgery was completed.



**Figure 1.** A, demonstration of the Ligamentum Flavum under the surgical microscope, B and C show the surgical image and illustration of Ligamentum Flavum incision, respectively. Laminectomy has not been performed, and thus, no damage has been made to the attachment area of the ligamentum flavum to the lamina



**Figure 2.** A creation of a window extending into the epidural space after the incision of Ligamentum Flavum and its suspension with sutures. In B, sequestered disc material located laterally to the Root can be observed. C is an illustration showing the creation of a window with sutures after the incision of the Ligamentum Flavum. Sequestered disc fragment located laterally to root is illustrated in red colour



**Figure 3.** A and B, surgical image demonstrating the suturing of the Ligamentum Flavum after sequestrectomy. C is an illustration depicting after the suturing process

## Results

Group 1 consists of 48 patients, 28 males and 20 females, with a mean age of 41.3. Group 2 consists of 48 patients, 27 males and 21 females, with a mean age of 42.8. There is no significant difference between the two groups in terms of gender and age,  $p=0.837$  and  $p=0.554$ , respectively.

In Group 1, lumbar disc herniation recurrence occurred in 3 out of the 48 patients (6.25%) during postoperative follow-ups within the first year. Due to recurrence occurring before the 12<sup>th</sup> month, these cases underwent reoperation and were not included in the postoperative 12-month follow-up. Therefore, preoperative LPVAS and BPVAS scores were calculated for 48 patients in Group 1, whereas postoperative LPVAS and BPVAS scores were calculated for the remaining 45 patients, as three patients were excluded due to recurrence. Similarly, in Group 2, recurrence occurred in 4 patients (8.33%) within the first year, leading to their exclusion from the postoperative 12-month follow-up. Consequently, preoperative scores for Group 2 were calculated for 48 patients, while postoperative scores were calculated for 44 patients, excluding those with recurrence.

In the preoperative period, mean VAS scores (LPVAS) were assessed for Group 1, with a value of 7.27, and for Group 2, with a mean preoperative LPVAS score of 7.13. The mean LPVAS scores evaluated at postoperative 12<sup>th</sup> month were 1.84 for Group 1 and 1.75 for Group 2. There is no significant difference between the groups in preoperative mean LPVAS scores ( $p=0.474$ ) and there is no significant difference between the groups in postoperative mean LPVAS scores ( $p=0.598$ ). This result indicates that the transflaval or standard microdiscectomy method does not show differences in clinical outcomes in postoperative leg pain.

The mean BPVAS score, assessed for the evaluation of severity of back pain, was found to be 4.58 for Group 1 and 4.42 for Group 2 at preoperative period. When the BPVAS score was assessed at postoperative 12<sup>th</sup> month, it was found to be 1.44 for Group 1 and 2.84 for Group 2. There is no significant difference between the groups in preoperative mean BPVAS scores ( $p=0.608$ ). However, there is a significant difference between the groups in

postoperative mean BPVAS scores ( $p<0.001$ ). This result indicates that patients who underwent transflaval microdiscectomy surgery show better clinical outcomes in follow-up in terms of back pain compared to patients who underwent standard microdiscectomy surgery.

In Group 1, recurrence occurred in 3 patients within first year, and in Group 2 recurrence occurred in 4 patients within first year. All these patients underwent reoperation with using the standard microdiscectomy method. Among the 3 patients in the first group who underwent reoperation, none showed intraoperative cerebrospinal fluid (CSF) leakage related to dural injury. However, in the second Group, 2 out of the 4 patients who underwent reoperation exhibited CSF leakage associated with intraoperative dural injury. Furthermore, none of the 3 patients in the first group, who experienced a recurrence, exhibited observations of epidural fibrosis during the surgery for recurrence, whereas all 4 patients in the second group exhibited areas of epidural fibrosis during the reoperation procedure.

## Discussion

The condition of lumbar disc herniation and its association with leg pain has been a subject of debate since ancient Greek times [13]. Surgical interventions to the lumbar spine began in the 18<sup>th</sup> century, but the first established and documented lumbar discectomy surgery was performed by Truumees et al. [13] in 1932. From the subsequent years to the present, LDH surgery has undergone significant changes and developments with the introduction of surgical microscopes, and the utilization of tubular retractors as well as the performance of tubular surgeries (Micro-endoscopic discectomy) with Video-assisted techniques by Butler et al. [14].

In lumbar disc surgery, regardless of the surgical approach chosen (microscopic or endoscopic techniques), the preservation of the LF structure has been debated and researched for its potential to reduce postoperative epidural fibrosis, facilitate revision surgeries, and be associated with better postoperative outcomes [10-12]. Studies investigating the relationship between obtaining better clinical outcomes after surgeries with preserved LF structure have shown that epidural fibrotic tissue can cause neural irritation, and depending on the size of

the scar tissue, it can even create mass effects, resulting in both radicular and axial pain [15-17]

In one of the studies conducted to address these problems, it was found that preserving the LF structure during lumbar discectomy surgery is associated with radiologically less development of epidural fibrosis and better postoperative clinical outcomes [12]. In another study on this topic, it was observed that surgeries performed with LF preservation resulted in less epidural fibrosis at postoperative 6-month follow-up evaluations, indicating that this technique acts as a natural physical protective barrier [11]. In a series that follow-ups were documented for 2 years with using Visual Analog Scale (VAS) scores and Oswestry Disability Index (ODI), it was demonstrated that postoperative clinical outcomes obtained after LF-preserving surgeries were associated with better results when assessed using these scales [18]. In a series of 78 patients in which the LF structure was preserved and an endoscopic approach was used, it was demonstrated that the endoscopic lumbar discectomy technique resulted in better clinical outcomes when performed with the preservation of the LF structure [19].

Various LF preserving surgical techniques have been described in the literature. In a method described as the Ozer et al. [11] technique, the LF is opened using a circular incision, anchored to the sacrum with a needle, and after completing the discectomy, the surgery is completed by performing LF sutures. In another described technique, the LF structure is cut from the lateral part near the facet joint and folded medially to create a window, followed by the discectomy procedure [20]. In another described technique, the LF is lifted as a three-sided flap and, with the help of a retractor, is pulled medially to perform the surgery [10]. In our technique, we divide the LF longitudinally into two pieces with an incision and then suspend those pieces with a suture. We believe that this incision, being parallel to the LF fibers, causes less damage to the LF fibers and is more suitable for preserving their function, as it avoids creating a perpendicular incision on the flexion force arm that resists hyperflexion forces. Moreover, the omission of laminectomy and the preservation of the attachment area of the ligamentum flavum to the lamina contribute to the preservation of

resistance against hyperflexion forces.

It is possible to find many articles on epidural fibrosis in the literature as it is a highly studied topic. Especially after microdiscectomy operation, epidural fibrosis rates and methods to reduce these numbers can be found in a large number of articles. For example, in the experimental study conducted by Keskin et al. [21] in rats, it was noticed that the use of berberine in vivo significantly reduced epidural fibrosis. Similarly, Dayanır et al. [22] addressed the same issue through ozone, while many different research teams have studied the effects of systemic or local use of different molecules and pharmaceutical agents on epidural fibrosis [23, 24]. In our series, when comparing flavum-preserving surgery with standard surgery, no comparison has been made radiologically regarding the development of epidural fibrosis. The reason for this is the non-application of control MRI examinations during follow-ups in patients without symptoms that would raise suspicion of recurrence. However, during intraoperative observations in patients with recurrence, it has been observed that epidural fibrosis is more commonly encountered in patients undergoing standard microdiscectomy compared to those undergoing transflavum microdiscectomy. Additionally, due to these adhesions, dural injury has been found to be more frequent in cases with recurrence during reoperation in patients who underwent standard microdiscectomy.

The study's limitations include the relatively short postoperative follow-up period of 12 months and the use of a relatively small patient population. More definitive conclusions can be drawn through investigations with extended follow-up intervals and larger cohorts of patients.

In conclusion, preserving the ligamentum flavum structure and minimizing its damage during lumbar microdiscectomy surgery results in less axial pain, a lower incidence of epidural fibrosis, a reduced risk of dural injury in reoperations following the development of recurrence, and improved clinical outcomes during follow-ups.

**Conflict of interest:** No conflict of interest was declared by the authors.

## References

- Dowdell J, Erwin M, Choma T, Vaccaro A, Latridis J, Cho SK. Intervertebral disk degeneration and repair. *Neurosurgery* 2017;80:46-54. <https://doi.org/10.1093/neuros/nyw078>
- Blamoutier A. Nerve root compression by lumbar disc herniation: a french discovery? *Orthop Traumatol Surg Res* 2019;105:335-338. <https://doi.org/10.1016/j.otsr.2018.10.025>
- Feng F, Xu Q, Yan F, et al. Comparison of 7 surgical interventions for lumbar disc herniation: a network meta-analysis. *Pain Physician* 2017;20:863-871.
- Jiang HW, Chen CD, Zhan BS, Wang YL, Tang P, Jiang XS. Unilateral biportal endoscopic discectomy versus percutaneous endoscopic lumbar discectomy in the treatment of lumbar disc herniation: a retrospective study. *J Orthop Surg Res* 2022;17:30. <https://doi.org/10.1186/s13018-022-02929-5>
- Zuo R, Jiang Y, Ma M, et al. The clinical efficacy of biportal endoscopy is comparable to that of uniportal endoscopy via the interlaminar approach for the treatment of L5/S1 lumbar disc herniation. *Front Surg* 2022;9:1014033(e1-11). <https://doi.org/10.3389/fsurg.2022.1014033>
- Askar Z, Wardlaw D, Choudhary S, Rege A. A ligamentum flavum-preserving approach to the lumbar spinal canal. *Spine (Phila Pa 1976)*. 2003;28:385-390. <https://doi.org/10.1097/01.BRS.0000085100.10349.15>
- Salimi H, Suzuki A, Habibi H, et al. Biglycan expression and its function in human ligamentum flavum. *Sci Rep* 2021;11:4867(e1-13). <https://doi.org/10.1038/s41598-021-84363-x>
- Hirabayashi S. Ossification of the ligamentum flavum. *Spine Surg Relat Res* 2017;1:158-163. <https://doi.org/10.22603/ssrr.1.2016-0031>
- Lee U, Kim CH, Kuo CC, et al. Does preservation of ligamentum flavum in percutaneous endoscopic lumbar interlaminar discectomy improve clinical outcomes? *Neurospine* 2019;16:113-119. <https://doi.org/10.14245/ns.1938008.004>
- Aydin Y, Ziyal IM, Duman H, Türkmen CS, Başak M, Sahin Y. Clinical and radiological results of lumbar microdiscectomy technique with preserving of ligamentum flavum comparing to the standard microdiscectomy technique. *Surg Neurol* 2002;57:5-13(discussion13-14). [https://doi.org/10.1016/s0090-3019\(01\)00677-2](https://doi.org/10.1016/s0090-3019(01)00677-2)
- Ozer AF, Oktenoglu T, Sasani M, Bozkus H, Canbulat N, Karaarslan E, Sungurlu SF, Sarioglu AC. Preserving the ligamentum flavum in lumbar discectomy: a new technique that prevents scar tissue formation in the first 6 months postsurgery. *Neurosurgery* 2006;59:126-133. <https://doi.org/10.1227/01.NEU.0000220078.90175.E6>
- Özay R, Ogur T, Durmaz HA, Turkoglu E, Caglar YS, Sekerci Z, Sorar M, Hanalioglu S. Revisiting ligament-sparing lumbar microdiscectomy: when to preserve ligamentum flavum and how to evaluate radiological results for epidural fibrosis. *World Neurosurg* 2018;114:378-387. <https://doi.org/10.1016/j.wneu.2018.02.186>
- Truumees E. A history of lumbar disc herniation from Hippocrates to the 1990s. *Clin Orthop Relat Res* 2015;473:1885-1895. <https://doi.org/10.1007/s11999-014-3633-7>
- Butler AJ, Munakomi S, Donnally III CJ. Discectomy. Available from: <https://www.ncbi.nlm.nih.gov/books/NBK544281>. Accessed Aug 13, 2023
- Kwon WK, Kelly KA, McAvoy M, et al. Full endoscopic ligamentum flavum sparing unilateral laminotomy for bilateral recess decompression: surgical technique and clinical results. *Neurospine* 2022;19:1028-1038. <https://doi.org/10.14245/ns.2244344.172>
- Cruccu G, Aziz TZ, Garcia Larrea L, et al. EFNS guidelines on neurostimulation therapy for neuropathic pain. *Eur J Neurol* 2007;14:952-970. <https://doi.org/10.1111/j.1468-1331.2007.01916.x>
- Cemil B, Tun K, Kaptanoglu E, et al. Use of pimecrolimus to prevent epidural fibrosis in a postlaminectomy rat model. *J Neurosurg Spine* 2009;11:758-763. <https://doi.org/10.3171/2009.6.SPINE08580>
- Li J, Ma Q, Wu J, Zhao P, Li T, Li J. Dose preservation of ligament flavum really help prevent postoperative epidural fibrosis and improve outcome in microdiscectomy? *J Clin Neurosci* 2020;80:331-335. <https://doi.org/10.1016/j.jocn.2020.06.013>
- Li S, Xia H, Han C. Retrospective analysis on correlation factors of preserving the ligamentum flavum in microendoscopic discectomy. *Clin Neurol Neurosurg* 2015;139:46-50. <https://doi.org/10.1016/j.clineuro.2015.08.018>
- Song J, Park Y. Ligament-sparing lumbar microdiscectomy: technical note. *Surg Neurol* 2000;53:592-596(discussion596-597). [https://doi.org/10.1016/s0090-3019\(00\)00231-7](https://doi.org/10.1016/s0090-3019(00)00231-7)
- Keskin E, Töngge Ç, Kaya M, Işık E. Evaluation of the effects of berberine in the prevention of epidural fibrosis in rats: an experimental research. *Saudi Med J* 2022;43:370-377. <https://doi.org/10.15537/smj.2022.43.4.20210918>
- Dayanır H, Dayanır D, Emmez G, et al. Medical ozone treatment on prevention of epidural fibrosis in the rat model. *Niger J Clin Pract* 2023;26:1197-1203. [https://doi.org/10.4103/njcp.njcp\\_161\\_23](https://doi.org/10.4103/njcp.njcp_161_23)

23. Keskin E, Yilmaz Can E, Aydın HA, et al. The preventative effect of of Ro5-4864 (peripheral benzodiazepine receptor agonist) on spinal epidural fibrosis after laminectomy in a rat model. *Neurol Res* 2021;43:1107-1115. <https://doi.org/10.1080/01616412.2021.1949689>
24. Yue Z, Hu B, Chen Z, et al. Continuous release of mefloquine featured in electrospun fiber membranes alleviates epidural fibrosis and aids in sensory neurological function after lumbar laminectomy. *Mater Today Bio* 2022;17:100469(e1-13). <https://doi.org/10.1016/j.mtbio.2022.100469>

**Ethics committee approval:** This retrospective study was approved by Ankara University Faculty of Medicine Clinical Research Ethics Committee on October 18, 2023, with the confirmation number I09-622-23.

#### **Authors' contributions to the article**

B.C.A. and M.Z. constructed the main idea and hypothesis of the study. O.M.O. and E.G. developed the theory and arranged/edited the material and method section. M.B. has done the evaluation of the data in the results section. Discussion section of the article was written by B.C.A.

F.Y. and U.E. reviewed, corrected and approved. In addition, all authors discussed the entire study and approved the final version.