

Case report

## Inguinal hernia containing ovary and fallopian tube with Nuck duct cyst: A case report

### Over, fallopian tüp ve Nuck kanal kisti içeren inguinal fitik olgusu; Olgu sunumu.

Emel Kıyak Çağlayan<sup>1</sup> , Kasım Çağlayan<sup>2</sup> , Fatin R. Polat<sup>2</sup> 

Namık Kemal University Medical Faculty, Departments of Obstetrics and Gynecology<sup>1</sup> and General Surgery<sup>2</sup>, Tekirdağ, Türkiye

**Corresponding address:** Dr. Kasım Çağlayan, [kasimcaglayan@hotmail.com](mailto:kasimcaglayan@hotmail.com)

**How to cite:** Çağlayan EK, Çağlayan K, Polat FR. Inguinal hernia containing ovary and fallopian tube with Nuck duct cyst:

A case report J Surg Arts: 2024;17(2):54-56.

Received: 12.02.2024

Accepted: 21.03.2024

#### ABSTRACT

Gynecological structures such as ovaries and tubal structures are rarely seen in the inguinal hernia sac. Nuck canal cyst with hernia sac is much rarer. Nuck canal should be kept in mind in the differential diagnosis of inguinal region cysts in women. When gynecological structures such as ovaries and tubes in the hernia sac are considered normal, they should be reduced and repaired with hernia mesh.

In this study, a case of inguinal hernia with ovarian and tubal tissue in the sac along with a nuchal canal cyst is presented.

**Keywords:** Inguinal hernia; Nuck cyst; ovary; tubal tube

#### ÖZET

İnguinal herni kesesinde over, tubal yapı gibi jinekolojik yapılar nadiren görülür. Herni kesesi ile birlikte Nuck kanal kisti ise çok daha nadir görülür. Kadınlarda inguinal bölge kitlerinde ayırıcı tanıda Nuck kanal akılda bulundurulmalıdır. Herni kesesinde bulunan over, tuba gibi jinekolojik yapılar normal olarak değerlendirildiğinde redükte edilmeli ve herni meş ile onarılmalıdır.

Bu çalışmada Nuck kanal kisti ile birlikte kese içinde over ve tuba dokusu olan inguinal herni olgusu sunulmaktadır.

**Anahtar kelimeler:** İnguinal herni; Nuck cyst; over; tubal tüp

#### INTRODUCTION

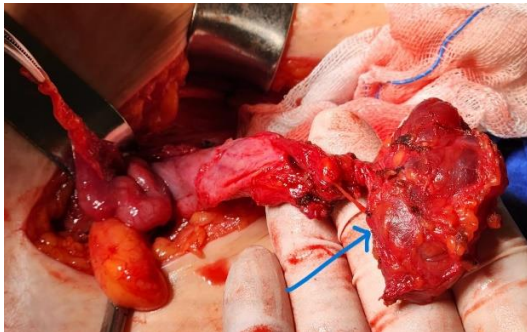
Inguinal hernias are one of the most common benign diseases in general surgery. The hernial sac mostly contains omentum and small intestines. Rarely, the appendix, ovaries, tubal tube, and bladder may be found within the hernial sac. Ovary and fallopian tubes are frequently seen in the pediatric

age group and are often associated with reproductive system malformation (1). In female, incomplete closure of the nuck canal usually causes inguinal hernia, which usually contains the fallopian tubes, ovaries and uterus (2). Nuck duct cyst typically manifests itself as swelling in the inguinal or genital area (3).

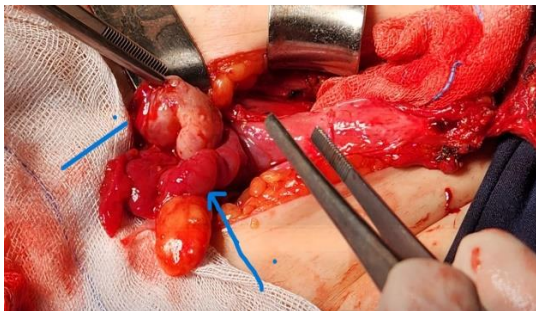
In this study, the patient was admitted due to swelling in the right groin and was operated on with the preliminary diagnosis of incarcerated inguinal hernia; A patient with an intraoperative nuck canal cyst and an ovary and tubal tube in the hernia sac is presented.

### CASE

A 41-year-old female patient presented to the general surgery outpatient clinic with a complaint of a palpable mass in the right groin. During the physical examination, a soft, well-defined, non-reducible mass with a diameter of 2 cm was palpated in the right inguinal region. No change in the size of the mass was observed with the Valsalva maneuver. An ultrasound revealed a 15 mm defect in the right inguinal region. The patient was diagnosed with incarcerated right inguinal hernia and underwent surgery. During exploration, a cystic mass of approximately 2 cm was palpated at the site where the mass was felt (Figure 1). The cystic lesion was freed and excised through blunt and sharp dissection. Simultaneously, an indirect hernia sac was identified in the patient. Palpation of the hernia sac revealed a round lesion of approximately 1.5 cm with moderate firmness. The hernia sac was opened, revealing ovarian tissue and fallopian tube (Figure 2). Gynecology consultation was requested. Upon confirming the normality of the ovary and fallopian tube, they were reduced into the abdominal cavity. After high ligation, the Lichtenstein hernioplasty procedure was performed. The patient was discharged on the first postoperative day.



**Figure 1:** Intraoperative view of the Nuck canal cyst.



**Figure 2:** View of the ovary and fallopian tube after the intraoperative hernia sac.

### DISCUSSION

The presence of unusual organs in the content of an inguinal hernia sac is a rare occurrence. Inguinal hernia sacs may contain intraabdominal organs, including the stomach (4). Studies on inguinal hernias by Güreer et al. in 1950 reported the presence of the appendix vermiformis in the hernia sac at a rate of 0.51%, appendicitis in femoral hernia sacs at 5%, and fallopian tubes and ovaries in inguinal hernias at a rate of 2.9%, with the bladder found at a rate of 0.36% (4). Inguinal hernias containing ovaries and fallopian tubes are a rare condition in reproductive-age women. When herniation of the ovary and fallopian tube occurs, it is often associated with developmental defects of the genital organs (5). The literature suggests that approximately 71% of such cases are observed in the population under the age of 5 (4).

The presence of gynecological structures in inguinal hernias is generally associated with developmental anomalies of the genital system, such as Müllerian aplasia or dysplasia, and primary amenorrhea. Most cases containing ovaries and tubes are indirect inguinal hernias, but they have also been identified in incarcerated direct hernias (4). In a review study by Prodromidou et al. about half of the cases (53%) were reported in women of reproductive age (18-45 years), indicating that the migration of gynecological structures into the inguinal canal may result from the relaxation of pelvic ligaments (6). In the presented case, preoperative ultrasound of the inguinal region did not provide insights into the structures within the inguinal hernia sac.

In this study, a case was presented where an inguinal hernia sac contained the ovary and fallopian tube, along with a Nuck canal cyst. The Nuck canal, first described by anatomist Anton Duck in 1691, is the male equivalent of the processus vaginalis and usually closes in the first year of life (3). Sometimes inadequate closure leads to the formation of a Nuck canal cyst, termed female hydrocele, first described in a woman by Coley in 1892. Although mostly idiopathic, this anomaly can also result from trauma, inflammation, or infection causing obstruction of lymphatic drainage. The frequency of occurrence is reported to be around 1% in the literature (3,7).

Nuck canal cysts clinically present as a painful or painless swelling in the inguinal or genital region in women. In the differential diagnosis, pathologies such as inguinal hernias, lymphadenopathies, cold abscesses, endometriosis in round ligaments, ganglion cysts, varices of the round ligament, leiomyomas or lipomas, Bartholin cysts, neurofibromas, post-traumatic/postoperative hematomas, and other conditions are considered (3,8).

The first-choice imaging modality is ultrasound. On ultrasound, Nuck canal cysts appear as thin-walled anechoic or hypoechoic lesions that do not change in size with the Valsalva maneuver. In

complex cases, other imaging methods such as computed tomography and magnetic resonance imaging are used for differential diagnosis (8, 9, 10).

The treatment method for Nuck canal cysts is excision (3, 7). In the presented case, after opening the hernia sac and reducing the ovary and fallopian tube into the abdomen, high ligation was performed. Subsequently, a Lichtenstein mesh hernioplasty was applied.

In conclusion, the presence of ovaries and fallopian tubes within an inguinal hernia sac is occasionally observed in early childhood and rarely in older women. Making a definitive preoperative diagnosis through physical examination or imaging methods is not always possible. The hernia sac should always be explored before reduction.

### REFERENCES

1. Amir W, Zafarullah S, Waheed MR, Anwar, Asghar MS. Obstructed inguinal hernia containing with an ovarian cyst:a case report. *J Pak Med Assoc.* 2023;73(6):1302-1304.
2. Saini R, Bains L, Kaur T, Lal P, Pal V, Beg MY, et al. Ovarian inguinal hernia- a possibility in URCS syndrome. *J Ovarian Res.* 2021;14(1):114.
3. Kohlhauser M, Pirsch JV, Maier T, Viertler C, Fegerl R. The Cyst of thr Canal of Nuck: Anatomy, Diagnostic and Treatment of a Very Rare Diagnosis- A Case Report of an Adult Woman and Narrative Review of the Literature. *Medicina(Kaunas).* 2022;58(10):1353.
4. Gurer A, Ozdogan M, Ozlem N, Yildirim A, Kulacoglu H, Aydin R.Uncommon content in groin hernia sac. *Hernia.* 2006;10(2):152.
5. Kokcu A, Malazgirt Z, Cetinkaya MB, Tosun M. Presence of a uterine horn and fallopian tüpe within an indirect hernial sac: report of a rare case. *Hernia* 2010;14(3):325-327.
6. Prodromidou A, Machairas N, Garoufalia Z, et al. Ovarian inguinal hernia. *Ann R Coll Surg Engl.* 2020;102(2):75-83.
7. Topal U, Sarıtaş AG, Ülkü A, Akçam AT, Doran F. Cyst of the canal Nuck mimicking inguinal hernia. *Int J Surg Case Rep.* 2018;52:117-119.
8. Fikatas P, Megas IF, Mantouvalou K, et al. Hydroceles of the canal of nuck in adults-diagnostic, treatment and results of a rare condition in females. *Clin Med.* 2020;12(9):4026.
9. Sarkar S, Panja S, Kumar S. Hydrocele of the canal of nuck (female hydrocele):A rare differential for inguino-labial swelling. *Clin Diagn Res.* 2016;10(2):PD21-2.
10. Polat FR. Bilateral giant inguinoscrotal hernia with hydrocele: a case report. *J Surg Arts.* 2021;14(2):82-85.