




Contracaecum rudolphii Hartwich, 1964 (Nematoda: Anisakidae) in a white pelican (*Pelecanus onocrotalus*) in Türkiye

Mustafa KÖSE¹ 
Mustafa Volkan YAPRAKÇI¹ 
Mehmet Fatih BOZKURT¹ 

¹Afyon Kocatepe University, Faculty of
Veterinary Medicine, Department of
Parasitology, Afyonkarahisar, Türkiye

²Afyon Kocatepe University, Faculty of
Veterinary Medicine, Department of
Surgery, Afyonkarahisar, Türkiye

³Afyon Kocatepe University, Faculty of
Veterinary Medicine, Department of
Pathology, Afyonkarahisar, Türkiye



Received/Geliş Tarihi: 04.04.2024
Accepted/Kabul Tarihi: 17.09.2024
Publication Date/Yayın Tarihi: 29.12.2024

Corresponding author/Sorumlu Yazar:
Mustafa KÖSE
E-mail: mkose@aku.edu.tr

Cite this article: Köse M, Yaprakçı MV,
Bozkurt MF. *Contracaecum rudolphii*
Hartwich, 1964 (Nematoda: Anisakidae)
in a white pelican (*Pelecanus*
onocrotalus) in Türkiye. *Vet Sci Pract.*
2024;19(3):183-186.

Atif: Köse M, Yaprakçı MV, Bozkurt MF.
Türkiye'de bir beyaz pelikanda
(*Pelecanus onocrotalus*) *Contracaecum*
rudolphii Hartwich, 1964 (Nematoda:
Anisakidae). *Vet Sci Pract.*
2024;19(3):183-186.



Content of this journal is licensed under a Creative
Commons Attribution-NonCommercial 4.0
International License.

ABSTRACT

Two injured and exhausted white pelicans were brought to Afyon Kocatepe University Animal Hospital Surgery Clinic by Nature Conservation and National Parks officials. An open wound and a fracture of the right-wing radius-ulna bones were detected due to gunshot wound in one of the pelicans. The fracture was operated with intramedullary pin fixation. In the post-mortem examination of the pelican that died one day after the operation, 249 nematodes were found in the proventriculus. On parasitological examination, the nematodes were identified as *Contracaecum rudolphii* and in pelicans for the first time in Türkiye. In the coprological examination of the second pelican, *Contracaecum* sp. eggs were detected. Complete recovery was achieved with anthelmintic and supportive treatment.

Keywords: *Contracaecum rudolphii*, pelican, Türkiye.

ÖZ

Doğa koruma ve Milli Parklar yetkilileri tarafından Afyon Kocatepe Üniversitesi Hayvan Hastanesi Cerrahi Kliniği'ne yaralı ve bitkin iki beyaz pelikan getirildi. Pelikanlardan birinde ateşli silah yaralanmasına bağlı açık yara ve sağ kanat radius-ulna kemiklerinde kırık tespit edildi. Operasyona alınan pelikan intramedüller pin fiksasyonu ile tedavi edildi. Operasyondan bir gün sonra ölen pelikanın post-mortem incelemesinde proventrikulusta 249 adet nematoda rastlandı. Parazitolojik muayenede nematodların *Contracaecum rudolphii* olduğu ve Türkiye'de ilk kez pelikanlarda görüldüğü belirlendi. İkinci pelikanın koprolojik muayenesinde ise *Contracaecum* sp. yumurtaları tespit edildi. Antelmintik ve destekleyici tedavi ile tam iyileşme sağlandı.

Anahtar Kelimeler: *Contracaecum rudolphii*, pelican, Türkiye.

INTRODUCTION

Anisakid nematodes of the genus *Contracaecum* (Railliet and Henry, 1912) are parasites of piscivorous birds, penguins, marine mammals and some species are zoonotic. It is seen mostly in pelicans, cormorants, penguins and seals in wetlands, freshwater and marine ecosystems around the world.^{1,2} *Contracaecum* is found usually in the proventriculus of piscivorous and pinnipeds, the definitive hosts and has a heteroxeneous life cycle. The worm eggs are released into the water with the definitive host's feces, and the developing larvae are ingested by copepods, the intermediate host. Fish that eat copepods carrying *Contracaecum* larvae serve as paratenic hosts. The larvae remain in capsules in the intestinal wall, mesentery, liver and internal organs without developing in the paratenic host. When infected fish are consumed by piscivorous birds and marine mammals, 4th instar larvae develop and subsequently reach

the mature stage.^{3,4} It has been reported that the parasite can cause pathological disorders in fish, birds and mammals and economic losses in commercial fisheries. In piscivorous birds, these parasites cause bleeding, serious ulcerative eosinophilic granulomas in proventricular mucosa, weight loss and even death. People who consume raw or undercooked infected fish experience symptoms of vomiting, diarrhoea and abdominal pain.^{3,5}

CASE PRESENTATIONS

Two male young white pelicans (*Pelecanus onocrotalus*) were brought to Afyon Kocatepe University Animal Hospital Surgery Clinic by Natur Conservation and National Parks officials (Figure 1a). Initial examination of the pelicans, revealed that their body weight was 4.7 and 5.6 kg, respectively, they were hypothermic (35.6°C and 36.5°C), and lethargic with weak vital signs. During the radiographic and orthopedic clinical examination, in one pelican an open wound, a gunshot-related fracture in the right-wing radius-ulna bones, and a radio-opaque foreign body thought to be pellets were detected (Figure 1b).

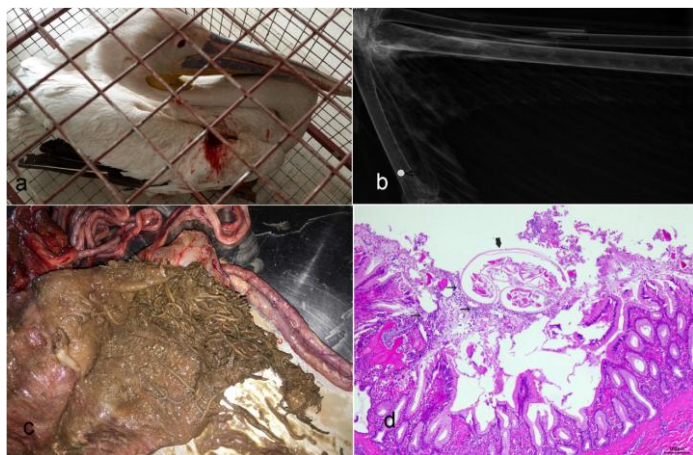


Figure 1. a. White pelican (*Pelecanus onocrotalus*), b. A fracture of the right-wing radius-ulna bones and a pellet (arrows), c. Nematodes (*C. rudolphii*) in proventriculus, d. Histopathological findings; heterophile leukocyte infiltration (thin arrows) and mouthparts of *C. rudolphii* (Thick arrow) (HE staining).

Both pelicans were kept under observation for 3 days, with intravenous fluid replacement, as well as antiparasitic and antibacterial treatments (levamisole at 20mg/ml orally and enrofloxacin at 15 mg/ml intramuscularly). The bone fracture was repaired with 3.0 and 4.0 Steinmann intramedullary pin fixation, the wing was bandaged, and fluid replacement was continued in the postoperative period.

However, the bird died for an unknown reason the day following the operation. Post-mortem examination revealed that the nutritional status was poor, the mucous membranes were pale and dull. Moreover, a severe decrease in body fat, especially the fat layers around the heart was noted. The chest muscles and extremity muscles were atrophic. On cut section of proventriculus, 249 nematodes were found (Figure 1c). The proventriculus mucosa was hyperemic with small hemorrhages. Representative tissue samples were taken from all organs, fixed in buffered neutral formaldehyde solution, and processed routinely for histopathological examination. Microscopically section of proventriculus showed disruption in the integrity of mucosa along with heterophile leukocyte infiltration. Cross section of parasites along with cellular infiltration was also observed in the proventricular mucosa (Figure 1d).

For the specific identification of adult nematodes collected from the proventriculus, worms were examined under a stereo-microscope. The worms were then dehydrated, coated with carbon, examined under a scanning electron microscope and photographed (Figure 2a,b,c). The examined nematodes were identified as *Contraecaecum rudolphii* Hartwich, 1964 according to the morphology of the labia/interlabia, the distribution of the distal papillae and the morphology of the tip of the spicules and the diagnostic key.⁶⁻⁹

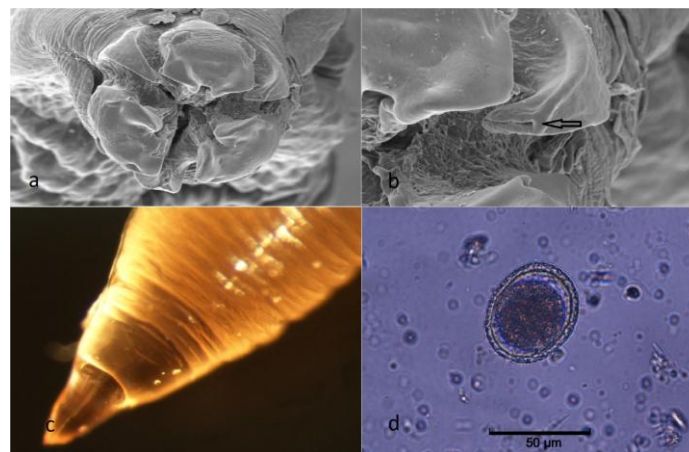


Figure 2. a. Cephalic extremity of *C. rudolphii* (SEM) b. Interlabium with bifid tip (Arrow) (SEM) c. Female tail (Stereo-Microscopy) d. *Contraecaecum* sp. egg (55X45 µm).

No signs of trauma were observed in the clinical and radiographic examination of the second pelican. However, on faecal examination, large number *Contraecaecum* sp. eggs were identified (Figure 2d). The pelican regained full health after antiparasitic and antibiotic treatment and rehabilitation.

DISCUSSION

Although *Contracaecum* sp. larvae were reported in previous studies^{10,11} from fish in Türkiye, *C. rudolphii* larvae were detected in only one study.¹² Similarly *Contracaecum* spp. were detected in the digestive tract of a Dalmatian pelican brought to Bursa Uludağ University Animal Hospital, but species identification could not be made.¹³

In this study, *C. rudolphii* was detected in the proventriculus of a white pelican for the first time from Türkiye. Similar to the present observation the previous histo-pathological studies on proventriculus of infected piscivorous birds revealed attachment sites of adult nematodes, deep mucosal ulcers covering areas of necrosis, and inflammations of varying severity and depth. Histopathological examinations have reported severe granulomatous inflammations that expand and destroy the lamina propria and gastric glands. Additionally, small ulcerated areas and eosinophilic granulomas have been reported. Section of the parasites were surrounded by desquamations and mononuclear inflammatory cell infiltrations were detected in some areas of the proventriculus surface epithelium and submucosal glandular epithelium.^{5,9,13-15}

In conclusion, the anisakid nematode *C. rudolphii* was detected from a white pelican for the first time in Türkiye, that caused severe pathological disorders and even death when in large number.

Peer-review: Externally peer-reviewed.

Author Contributions: Parasitological examination – SEM.; Design, Data Collection and/or Processing, Analysis and/or Interpretation, Literature Search, Writing Manuscript – MK.; Materials, Surgical and medical treatment, Critical Review – MVY.; Macro and histopathological examination, Critical Review – MFB.

Declaration of Interests: The authors declare that there is no conflict of interest.

Funding: The authors declared that this study has received no financial support.

Hakem Değerlendirmesi: Dış bağımsız.

Yazar Katkıları: Fikir- MK., MVY.; Tasarım- MK., MVY.; Denetleme- MK.; Kaynaklar- MK.; Veri Toplanması

ve/veya İşlemesi- MK., MVY., MFB.; Analiz ve/ veya Yorum- MK., MVY., MFB.; Literatür Taraması- MK.; Yazıyı Yazan- MK.; Eleştirel İnceleme- MK., MVY., MFB.

Çıkar Çatışması: Yazarlar çıkar çatışması olmadığını beyan ederler

Finansal Destek: Yazarlar, bu çalışma için finansal destek olmadığını beyan etmiştir.

REFERENCES

- Anderson RC. Nematode parasites of vertebrates: Their development and transmission. 2nd ed. New York, Cabi Publishing; 2000.
- Cammilleri G, D'Amelio S, Ferrantelli V, et al. Identification of *Contracaecum rudolphii* (Nematoda: Anisakidae) in Great Cormorants *Phalacrocorax carbo sinensis* (Blumenbach, 1978) from Southern Italy. *Vet Sci*. 2023;10(3):194.
- Dziekonska-Rynko J, Rokicki J. Life cycle of the nematode *Contracaecum rudolphii* Hartwig, 1964 (sensu lato) from northern Poland under laboratory conditions. *Helminthologia*. 2007;44(3):95-102.
- Moravec F. Experimental studies on the development of *Contracaecum rudolphii* (Nematoda: Anisakidae) in copepod and fish paratenic hosts. *Folia Parasitol*. 2009;56(3):185-193.
- Sreedevi C, Prasuna K, Lavanya K, Kanaka Swarna Latha K. *Contracaecum rudolphii* Hartwich, 1964 (Nematoda: Anisakidae) in a wild spot-billed pelican (*Pelecanus philippensis*): a case report. *J Parasit Dis*. 2017;41(4):959-962.
- Amato JFR, Monteiro CM, Amato SB. *Contracaecum rudolphii* Hartwich (Nematoda, Anisakidae) from the Neotropical Cormorant, *Phalacrocorax brasilianus* (Gmelin) (Aves, Phalacrocoracidae) in southern Brazil. *Rev Bras Zool*. 2006; 23(4):1284-1289.
- Barus V, Sergeeva TP, Sonin MD, Ryzhikov KM. Helminths of fish-eating birds of the Palearctic region I. First ed. Prague: Springer Science+Business Media Dordrecht; 1978.
- Caffara M, Tedesco P, Davidovich N, et al. Molecular and morphological studies on *Contracaecum rudolphii* A and *C. rudolphii* B in great cormorants (*Phalacrocorax carbo sinensis*) from Italy and Israel. *Parasitology*. 2023;150(11):1040-1051.
- Hyeon-Cheol K, Nam-Soo K, Hwa-Young S, et al. Morphological Study of *Contracaecum rudolphii* (Nematoda: Anisakidae) from White Pelican. *J Vet Clin*.

2010;27(1):11-16.

10. Aydođdu A, Emence H, İnnal D. Gölbaşı baraj gölü (Bursa)'ndeki eğrez balıkları (*Vimba vimba* L. 1758)'nda görülen helmint parazitler. *Türkiye Parazitol Derg.* 2008;32(1):86-90.

11. Özkan Y, Aksakal E, Ođuz MC. The determination of comparative prevalence, mean intensity and abundance according to fish size parameters of recorded nematode larvae of horse Mackerel (*Trachurus trachurus*, L. 1758). *Bibad.* 2010;3(1):145-147.

12. İnnal D, Stavrescu-Bedivan M, Öztürk MO, Özmen O. First Record of *Contracaecum rudolphii* Hartwich, 1964 in *Carassius gibelio* (Bloch, 1782) From Turkey. *Aquat Sci Eng.* 2020;35(1):1-5.

13. Girişgin AO, Alasonyalılar-Demirer A, Girişgin O. A case of *Contracaecum* sp. (Ascaridida: Anisakidae) infection in Dalmatian Pelican (*Pelecanus crispus*). *Kafkas Univ Vet Fak Derg.* 2012;18(Supl. A):227-229.

14. Rokicki J, Soltysiak Z, Dziekorska-Rynko J, Borucinska J. Pathology associated with *Contracaecum rudolphii* (Nematoda: Anisakidae) infection in the great cormorant *Phalacrocorax carbo* (L. 1758). *Helminthologia.* 2011;48(1):29-35.

15. Burdevic B, Vucicevic I, Bogunovic D, et al. Pathological and parasitological findings in serbian great cormorants infected by *Contracoecum rudolphii* sensu lato. *Acta Vet (Beogr).* 2024;74(3):473-483.