

Spinal cord involvement detected by FDG PET/CT in a patient with Non-Hodgkin's lymphoma

© Gökçe Yavan^{1*} © Pinar Pelin Özcan² © Zehra Pinar Koç³

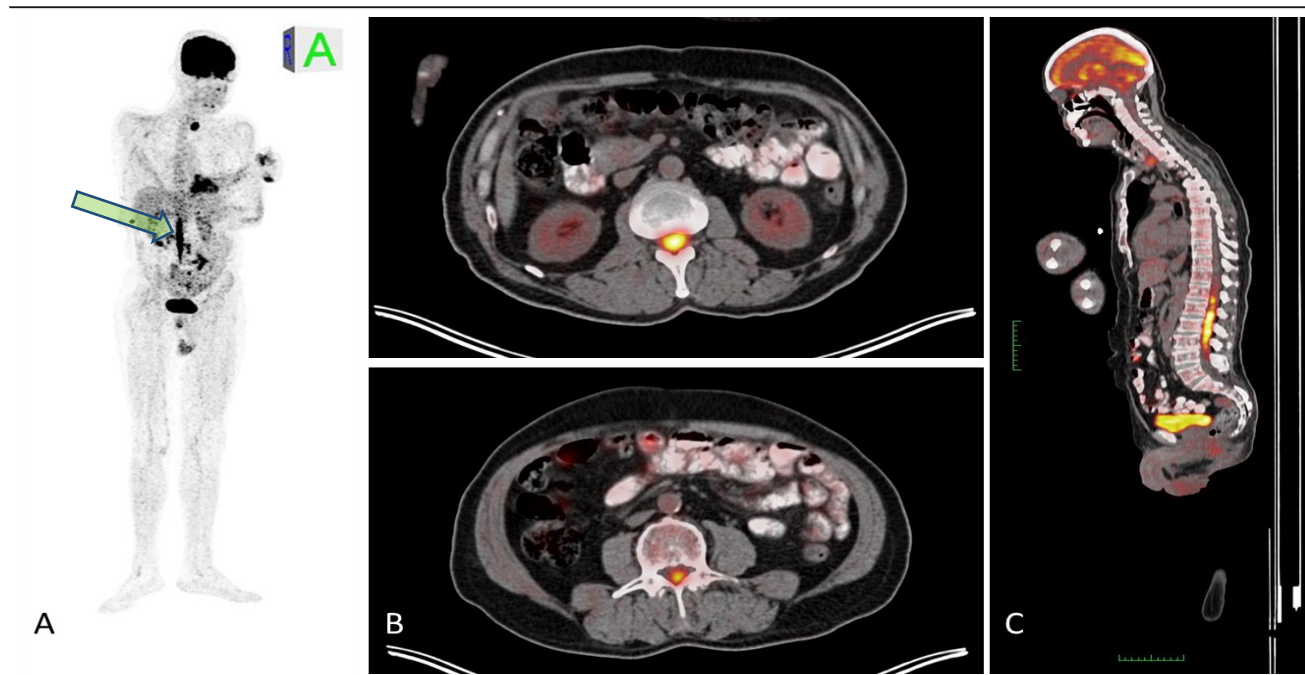
*Corresponding Author

^{1,2,3}Mersin University, Faculty of Medicine, Department of Nuclear Medicine, Mersin, Turkey

Abstract

A 66-year-old male patient, who was followed up and treated due to the diagnosis of diffuse large B-cell lymphoma, applied to the clinic due to complaints of severe neuropathic type pain in the right hip radiating to the leg for about 1 month and inability to walk even with support. For suspicion of disease spread, the patient was planned to undergo an F-18 labeled Fluorodeoxyglucose (F18 FDG) positron emission tomography/computed tomography (PET/CT) scan. The FDG PET/CT scan showed that the diffuse linear FDG uptake in the spinal cord involvement from L1 to L5.

Keywords: Non-Hodgkin's lymphoma, spinal cord, metastasis, FDG, PET/CT.



Address for Correspondence: Gökçe Yavan, Mersin University Training and Research Hospital, Clinic of Nuclear Medicine, Mersin, Turkey

Phone: + 90-324-2410000/22522 **E-mail:** gyavan95@gmail.com **ORCID ID:** <https://orcid.org/0000-0002-7332-6293> **Received:** 08.04.2024

Accepted: 13.05.2024 **Published:** 14.05.2024

Figure 1: FDG PET/CT scan showed intramedullary abnormal increased FDG uptake in a diffuse linear manner along the spinal foramen from L1 to L5 level in MIP (maximum intensity projection) in A and sagittal plane cross-sectional images in C. This involvement in the spinal canal is seen in transaxial sections in B, at the level of L2 in the upper image and L5 in the lower image. This finding observed in the spinal canal suggests perineural lymphomatous infiltration with alternative diagnoses such as primary nerve sheath neoplasm or, less likely, focal inflammatory nerve diseases. In the subsequent thoracolumbar Magnetic Resonance Imaging examination, signal increases suggestive of metastasis were detected at the same levels as the medulla spinalis and conus medullaris. Leptomeningeal involvement is a rare neurological symptom of systemic lymphoma. Definitive diagnosis is often difficult and requires nerve biopsy (1). FDG PET/CT has an important role in detecting spinal involvement of lymphoma and preventing aggressive procedures such as histopathological evaluation (2-8).

Peer-review: Externally peer-reviewed.

Authorship Contributions

Concept: G.Y., P.P.O., **Design:** P.P.O., **Supervision:** G.Y., P.P.O., Z.P.K., **Data Collection and/or Processing:** G.Y., P.P.O., Z.P.K., **Analysis and/or Interpretation:** G.Y., P.P.O., Z.P.K., **Literature Review:** G.Y., **Writer:** G.Y.

Conflict of Interest: No conflict of interest was declared by the authors.

Financial Disclosure: The authors declared that this study has received no financial support.

References

1. Durán, C., Infante, J. R., Serrano, J., Rayo, J. I., García, L., Domínguez, M. L., & Sánchez, R. (2009). Neurolymphomatosis: diagnóstico de extensión y valoración de la respuesta al tratamiento mediante PET-TAC [Neurolymphomatosis: diagnosis of extension and assessment of response to treatment with PET-CT]. *Revista española de medicina nuclear*, 28(6), 295–298. <https://doi.org/10.1016/j.rem.n.2009.07.002>
2. Dong, Qian MD; Wong, Ka Kit MBBS; Avram, Anca M. MD. Sacral Nerve Root Neurolymphomatosis Diagnosed on FDG-PET/CT and Magnetic Resonance Imaging. *Clinical Nuclear Medicine* 33(1):p 30-31, January 2008. | DOI: 10.1097/RLU.0b013e31815c5020
3. Kajáry, K., Molnár, Z., Mikó, I., Barsi, P., Lengyel, Z., & Szakáll, S., Jr (2014). Neurolymphomatosis as a late relapse of non-Hodgkin's lymphoma detected by 18F-FDG PET/CT: a case report. *Revista española de medicina nuclear e imagen molecular*, 33(1), 39–42. <https://doi.org/10.1016/j.rem.n.2013.03.004>
4. Salm, Liesbeth P.a; Van der Hiel, Berniesa; Stokkel, Marcel P.M.b. Increasing importance of 18F-FDG PET in the diagnosis of neurolymphomatosis. *Nuclear Medicine Communications* 33(9):p 907-916, September 2012. | DOI: 10.1097/MNM.0b013e3283561881
5. White, Jessica D. MD, MPH*; Clarke, Michelle J. MD†; Paludo, Jonas MD‡; Feldman, Andrew L. MD§; Sener, Ugur T. MD||. Spinal Meningeal Mass Lesion: A Rare Presentation of Primary Dural Follicular Lymphoma. *The Neurologist* 29(2):p 122-125, March 2024. | DOI: 10.1097/NRL.0000000000000535
6. Yang, C., Zhuo, H. & Zou, L. Nasal-Type Extranodal Natural Killer/T Cell Lymphoma with Meningeal Involvement: A Case Report and Literature Review. *Indian J Hematol Blood Transfus* 36, 381–383 (2020). <https://doi.org/10.1007/s12288-019-01234-2>
7. Lin, Y., Pan, Y. H., Li, M. K., Zong, X. D., Pan, X. M., Tan, S. Y., & Guo, Y. W. (2021). Clinical presentation of gastric Burkitt lymphoma presenting with paraplegia and acute pancreatitis: A case report. *World journal of gastroenterology*, 27(45), 7844–7854. <https://doi.org/10.3748/wjg.v27.i45.7844>

8. Ganeshalingam, R., Roach, P., & Schembri, G. P. (2019). Diffuse Large B-Cell Lymphoma Recurring as Neurolymphomatosis on FDG PET/CT. *Clinical nuclear medicine*, 44(2), 145–147. <https://doi.org/10.1097/RLU.0000000000002388>

© Author(s) 2022. This work is distributed under <https://creativecommons.org/licenses/by-sa/4.0/>

