

Necrotic Enteritis in a Budgerigar Flock

Mustafa KABU^{1*}, Mehmet Fatih BOZKURT², Durmuş Fatih BAŞER¹, Cenker Çağrı CINGI¹

¹Department of Internal Medicine, Faculty of Veterinary Medicine, Afyon Kocatepe University, 03200, Afyonkarahisar, TURKEY

²Department of Pathology, Faculty of Veterinary Medicine, Afyon Kocatepe University, 03200, Afyonkarahisar, TURKEY

Dear Editor;

Etiology of Necrotic Enteritis is associated with *Clostridium perfringens*. However, predisposing factors are crucial for overgrowing and developing of *C. perfringens* (Opengart 2008). A lot of and varying underlying causes for necrotic enteritis have been identified, which are dietary factors, immune status and stress, intestinal physiopathology, and coccidiosis (Opengart 2008, Stanley ve ark. 2014).

The diseases occurs in a budgerigar flock. Disease were revealed in 314 Budgerigar, 32 birds dead according to the condition. At the anamnesis; diarrhea, feather loss and sudden death were detected. At clinical examination; loss of appetite, lethargy, fatigue, diarrhea, incoordination which accompany standing on roosts. In newborns, weakness, unusual feather growth and also sudden death were observed.

At pathological examination, necropsy was performed on eight budgerigar. Organ specimens were taken systemically and fixed in formalin solution. After routine tissue processing, specimens were blocked in paraffin and slices were taken sequently. Afterwards, slides were stained with Haematoxiline and Eosine (HE) and investigated with light microscopy. At microscopical investigation which necrosis was performed on seven birds that priority defects were detected in the gut. On the other hand, lung lesions pointed out in one bird. Degeneration, shortened and bluntness in villus and excessive epithelia desquamation were observed due to necrosis. Inflammation which contain rare heterophil and mostly mononuclear cells in lamina propria. Also atrophy and necrosis were seen in glands of gut. however no agents were visible in the tissues even though necrotic enteritis was detected. As a result, diseases which are related with necrotic enteritis is major effective syndroms can cause death either in adults or in new borns in budgerigars.

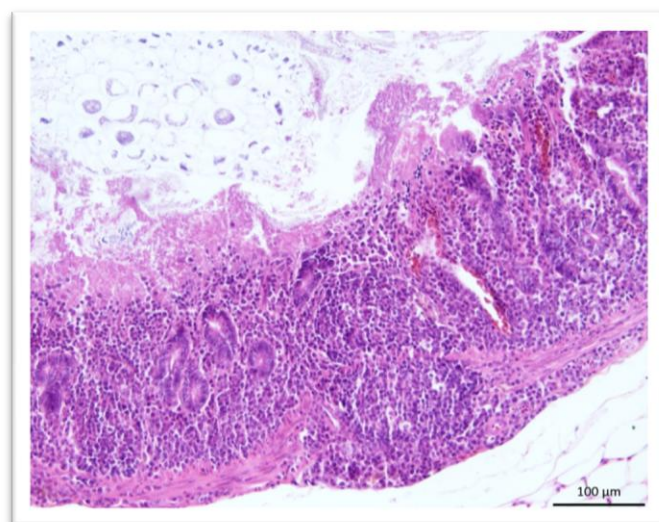


Figure 1. Microscopic appearance of gut; Villousnecrosis, mononuclear cell infiltration from lamina propria till serosa and glandular hyperplasia.

KAYNAKLAR

Opengart, K. Necrotic enteritis, in Diseases of Poultry, Ed; Y. M. Saif, A. M. Fadly, J. R. Glisson, L. McDougald, L. K. Nolan, and D. E. Swayne, 12. Baskı, Wiley-Blackwell Publishing, Ames, IA.2008, pp. 872–877.

Stanley D, Wu S, Rodgers N, Swick RA, Moore RJ. Differential Responses of Cecal Microbiota to Fishmeal, Eimeria and Clostridium perfringens in a Necrotic Enteritis Challenge Model in Chickens. 2014; 9(8): 1-10.