

# Pankreatikobilyer Semptomları Olan Hastalarda İnsidental Olarak Saptanan Jukstapapiller Divertiküllerin MRCP Bulguları

MRCP Findings of Incidentally Detected Juxtapapillary Diverticula in Patients With Pancreaticobiliary Symptoms

Elif Peker<sup>1</sup>, Esra Özkavukcu<sup>2</sup>, Nuray Haliloğlu<sup>2</sup>, Ayşe Erden<sup>2</sup>

<sup>1</sup> Şanlıurfa Eğitim ve Araştırma Hastanesi Radyodiagnostik Bölümü  
<sup>2</sup> Ankara Üniversitesi Tıp Fakültesi, Radyodiagnostik Anabilim Dalı

**Amaç:** Pankreatikobilyer semptomları olan hastaların MRCP incelemelerinde insidental olarak saptanan 24 jukstapapiller divertikülün (JPD) MRCP bulgularının sunulması ve bunların pankreatik kanal, safra yolları ve pankreas üzerine olan etkilerinin belirlenmesi.

**Hastalar ve Yöntemler:** 1-T MR ünitesinde elde edilen ve arşivlenmiş MRCP görüntüleri iki radyolog tarafından tekrar değerlendirilmiştir. Saptanan JPD'lerin yerleşimi ve boyutları, safra kesesinde veya koledokta taş varlığı, safra kanallarında veya pankreatik kanalda dilatasyon ve ana safra kanalında JPD'ye bağlı olarak oluşan deviasyon not edilmiştir. İntrahepatik safra yolları, koledok, pankreatik kanal, safra kesesi ve pankreas parankimi eşlik eden pankreatikobilyer hastalıklar yönünden değerlendirilmiştir.

**Bulgular:** Saptanan tüm JPD'ler (n=24) duodenum 2. bölümünün medial kesiminde yerleşimliydi. JPD'lerin ortalama çapı 2.25 cm ölçülmüştür. Aksiyel T2-ağırlıklı FSE görüntülerde divertiküllerin %95.8'inde (n=23/24) hava-sıvı seviyesi tespit edilmiştir. Kolesistektomi hikayesi olan 6 hasta değerlendirilmeden çıkartıldığında hastaların %44.4'ünde (n=8/18) safra kesesinde taş tespit edilmiştir. Hastaların %45.8'inde (n=11/24) koledokta dilatasyon, %58.3'ünde (n=14/24) intrahepatik safra yollarında dilatasyon, %45.8'inde de (n=11/24) pankreatik kanalda dilatasyon saptanmıştır. Hastaların %12.5'inde (n=3/24) koledokta deviasyon izlenmiştir. Üç olguda (%12.5, n=3/24) koledokolitiazis saptanmıştır.

**Sonuç:** JPD'lerin saptanmasında ve pankreatikobilyer sistem üzerine olan etkilerinin değerlendirilmesinde MRCP faydalı bir radyolojik yöntemdir. Çalışmamızdaki olgu sayımız fazla olmasa da JPD'nin pankreatikobilyer semptomlara yol açtığını öne sürmekteyiz.

**Anahtar Sözcükler:** *Kolanjiyopankreatografi, Manyetik Rezonans, Duodenum, Divertikül, Jukstapapiller Divertikül, Pankreatikobilyer Semptomlar*

**Aim:** To describe the MRCP imaging features of 24 juxtapapillary diverticula (JPD) which were incidentally found on the MRCP studies of the patients with pancreaticobiliary symptoms, and to determine whether they effect pancreatic or biliary ducts, gall bladder, and pancreas.

**Materials and Methods:** Archived MRCP images which were obtained by a 1-T MR unit, were re-evaluated by two radiologists. The location and size of the JPD were noted. Intrahepatic biliary ducts, common bile duct (CBD), main pancreatic duct, gallbladder, and pancreatic parenchyma were evaluated to reveal any associated pancreatobiliary disease. Presence of gallbladder stones or choledocholithiasis, dilatation of bile ducts or pancreatic duct, deviation of the CBD caused by the JPD were noted.

**Results:** All of the JPD (n: 24) were located medially at the second part of the duodenum. The mean diameter of JPD was 2,25 cm. Axial T2-weighted FSE images demonstrated air-fluid levels in 95.8% (n=23/24) of the diverticula. Excluding the six patients with previous cholecystectomy, gallbladder stones were detected in 44.4% (n=8/18) of the patients. CBD was dilated in 45.8% (n=11/24), intrahepatic biliary ducts were dilated in 58.3% (n=14/24), and pancreatic duct was dilated in 45.8% (n=11/24) of the patients. CBD deviation was observed in 12,5% (n=3/24) of the patients. Three patients (12,5%, n=3/24) had choledocholithiasis.

**Conclusion:** MRCP is a useful radiological method in determining the JPD, as well as their effects on the pancreatobiliary system. Even though this is study with a small number of patients, we can still postulate that the JPD can cause changes leading to pancreaticobiliary symptoms.

**Key Words:** *Cholangiopancreatography, Magnetic Resonance, duodenum; diverticulum; juxtapapillary diverticulum; pancreaticobiliary symptoms*

Received: 19.07.2010 • Accepted: 25.10.2010

Corresponding author

Uz.Dr. Elif Peker  
Şanlıurfa Eğitim ve Araştırma Hastanesi Radyodiagnostik  
Anabilim Dalı  
Phone : +90 414 31 43 / 299  
Gsm : +90 505 319 11 99  
E-mail Address : elifozyurek0@yahoo.com

Duodenal diverticula are very common extraluminal mucosal outpouchings of the duodenal wall which are usually located at the second or third parts of the duodenum (1, 2). They are usu-

ally found incidentally during various radiological procedures and rarely become complicated (3). Duodenal diverticula located within a 2-3 cm radius of the ampulla of Vater are called

juxtapapillary diverticula (JPD). They may cause mass effect on the distal part of the common bile duct and lead to pancreaticobiliary symptoms (3).

Magnetic resonance cholangiopancreatography (MRCP) can be used as a non-invasive method for the visualization of JPD, as well as their effects on the biliary system. Herein, we present the MRCP findings of 24 cases with JPD which were incidentally found on the MRCP studies of the patients referring with pancreaticobiliary symptoms, and try to determine whether they cause any effect on pancreaticobiliary system.

## Materials and Methods

### Study Patients

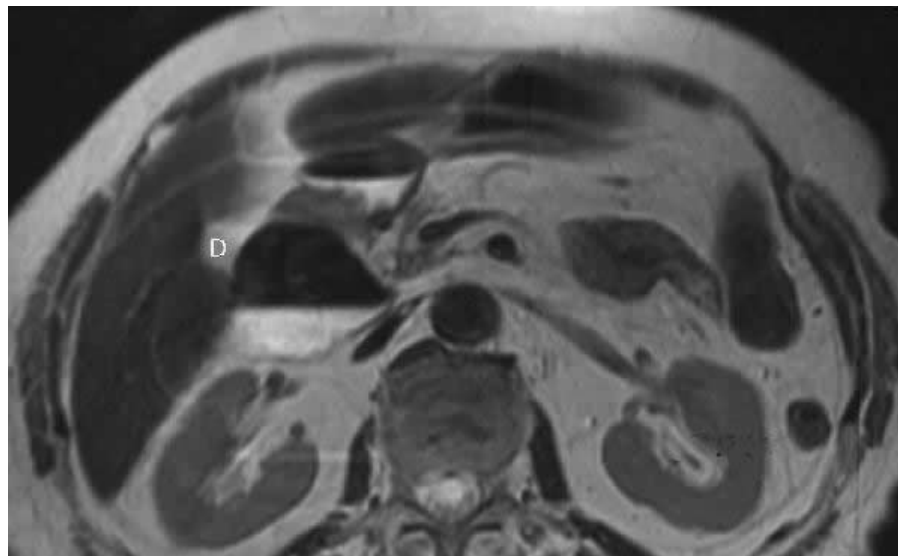
A total of 25 patients with JPD (18 female, 7 male; age range 40–86 years, mean 72 years) who underwent MRCP examinations in our radiology department between January 2002 and May 2009 were enrolled. One patient who had a large tumor of the pancreatic head was excluded from the study. The study patients were identified from the archive of MRCP reports. All the patients were referred to the MR unit for the evaluation of pancreaticobiliary disease (i.e. they had elevated liver enzymes or cholestatic parameters like alkaline phosphatase [ALP] or gamma-glutamyl transferase [GGT]).

### MRCP Technique

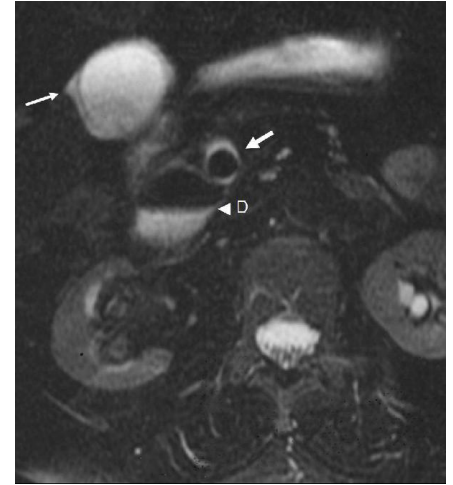
All MRCP examinations were performed using a torso phased-array coil, on a 1-T MRI unit (Signa LX Horizon, GE Medical Systems, Milwaukee, WI, USA). Heavily T2-weighted MRCP slabs were obtained in the coronal or coronal oblique plane using a breath-hold technique. The breath-hold period for each slab was 2 sec. An average of 13 MRCP sections of 20-70 mm thickness were obtained for each patient. Parameters for the thick MRCP slabs were as follows: TR, 1,700-15,000 msec; TE, 900-1,100 msec; bandwidth, 25-31.2 kHz; matrix size, 256 x 224-256; number of excitations (NEX), 0.5-1.0; field of view (FOV), 35-40 cm. Also, axial T2-weighted fast spin-echo (FSE) MR images of the upper abdomen were obtained, for better anatomic orientation. The parameters for the FSE sequence were as follows: TR, variable; TE, 102 msec; echo-train length, 4-18; slice thickness, 8 mm; interslice gap, 1.5 mm; bandwidth, 41.7 kHz; matrix, 320 x 192-224; NEX, 4; FOV, 36 x 27 cm; acquisition time, 2.05–3.44 minutes. All patients had a fasting period of at least six hours before the MRCP examination.

### Review of Data

Archived hardcopy MRCP images were re-evaluated by two radiologists, to-



**Figure 1.** Axial T2-weighted FSE image shows air-fluid level within the periapillary diverticulum (D).

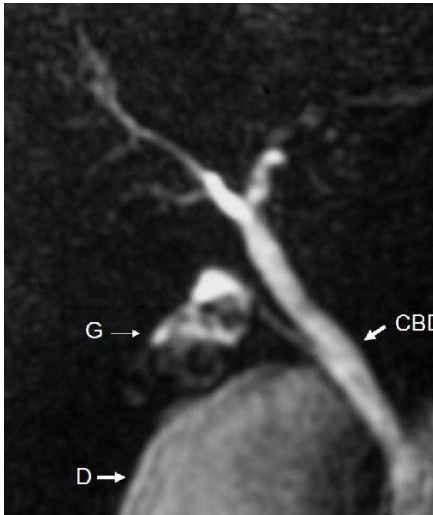


**Figure 2.** Axial T2-weighted FSE image reveals gallbladder wall thickening, pericholecystic fluid (thin arrow), choledocholithiasis (thick arrow) and periapillary diverticulum (D) with air-fluid level.

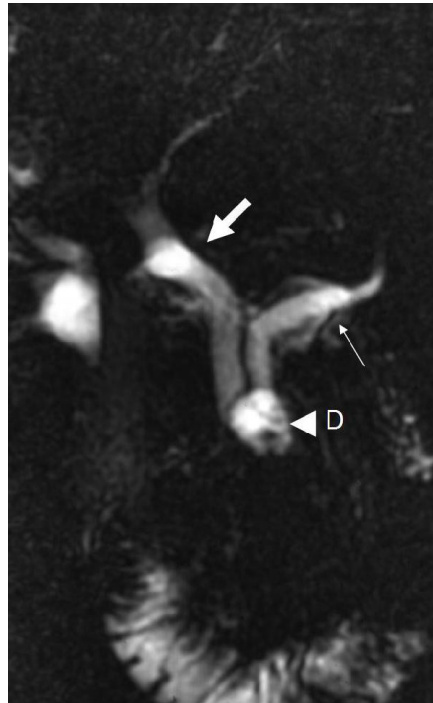
gether retrospectively. Once the JPD was seen, the location and the size of the JPD were noted. Only the largest measurement of the diameter of the diverticulum was taken into account, regardless of the imaging plane (coronal or axial) that the measurement was made. The intrahepatic biliary ducts, CBD, main pancreatic duct, gallbladder, pancreatic parenchyma were evaluated to reveal any associated pancreaticobiliary disease. The presence of gallbladder stones or choledocholithiasis, dilatation of the bile ducts or the pancreatic duct, deviation of the CBD caused by the JPD were noted. Pancreatic duct diameter larger than 2 mm was accepted as pancreatic duct dilatation. The upper limit for the caliber of the CBD was accepted as 7 mm for patients at or under the age of 60. For the patients older than 60 years, one millimeter each for a decade was added to this upper limit. Six of the patients (n=6/24, 25%) had undergone cholecystectomy operation. For patients with a history of cholecystectomy, 9 mm was considered to be the upper limit of CBD.

## Results

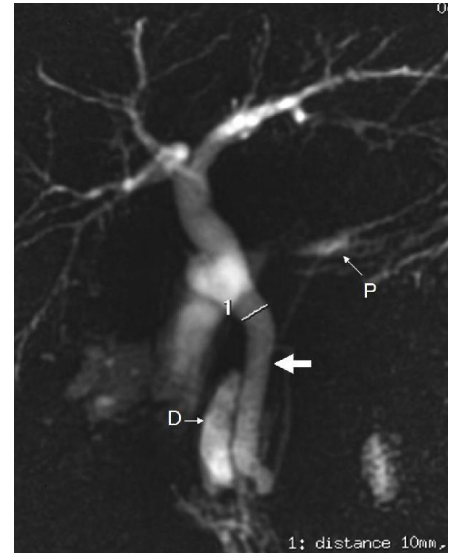
All of the JPD (n: 24) were located medially at the second part of the duodenum. The diameters of the diverticula ranged between 1–4,5 cm (mean di-



**Figure 3.** Thick slab MRCP image reveals deviation of the distal CBD due to the peripapillary diverticulum (D). The lumen of the gallbladder (G) is filled with stones and the fluid content and volume of the gallbladder is diminished secondary to chronic cholecystitis (porcelain gallbladder) (CBD: Common bile duct).



**Figure 4.** Thick slab MRCP image shows marked dilatation of the CBD (thick arrow) and the pancreatic duct (thin arrow) with an abrupt stenosis at the distal end of the ducts due to the presence of a juxtapapillary diverticulum (D).



**Figure 5.** Thick slab MRCP image shows a diverticulum (D) located in the peripapillary region. There is marked dilatation of the CBD with abrupt deviation at the distal part (thick arrow). Mild intrahepatic biliary duct dilatation is also revealed. Pancreatic duct (P) is normal (CBD: Common biliary duct).

iameter: 2,25 cm). Axial T2-weighted FSE images demonstrated air-fluid levels in 95.8% (n=23/24) of the diverticula (Fig. 1). Gallbladder stones were detected in 44.4% (n=8/18) of the patients without cholecystectomy. Gallbladder wall thickening and pericholecystic fluid was present in 22.2% (n=4/18) of the patients (Fig. 2). One patient (5.5%, n=1/18) had diffuse wall thickening of gallbladder with calcifications (chronic cholecystitis and porcelain gallbladder) (Fig. 3) and 2 patients (11.1%, n=2/18) had findings consistent with fundal adenomyomatosis. The CBD was dilated in 45.8% (n=11/24) of all the study patients (Fig. 4). Mild intrahepatic biliary ductal dilatation was detected in 58.3% (n=14/24) of the patients. Pancreatic duct was mildly dilated in 45.8% (n=11/24) of the patients. Pancreatic atrophy was noted in only one patient (4.1%, n=1/24). Four patients (16.6%, n=4/24) had pancreatic side branch dilatations. Deviation of the distal CBD by the diverticulum was observed in 12,5% (n=3/24) of the patients (Fig. 3, 5). Three patients one of which had previous cholecystectomy had choledocholithiasis (12,5%, n=3/24).

## Discussion

Duodenum is the second most common location for the gastrointestinal diverticula, after colon. It is difficult to estimate the true prevalence of the duodenal diverticula in the general population; the prevalence on barium meal examination ranges from 0.16 to 6%, prevalence at endoscopic retrograde cholangiopancreatography (ERCP) ranges from 5–32.8% and a rate of 23% has been reported at autopsy (1, 4).

JPD are the extraluminal mucosal herniations of the duodenal wall from a potentially weak spot, arising within a radius of 2–3 cm from the papilla of Vater (1, 2). They are usually asymptomatic and incidentally detected (2). Only 10% of the JPD cases undergo cross-sectional imaging due to pancreaticobiliary symptoms (2).

The etiology of JPD is postulated to be the disordered duodenal motility (1). Progressive weakening of the intestinal wall with the advancing age, and an in-

crease in the intraluminal pressure may result in diverticula formation (5). Histopathologically, they are similar to the pulsion diverticula of the gastrointestinal system, and the walls of the diverticula are composed of mucosa and submucosa with scattered smooth muscle (1).

The prevalence of JPD increases with age. They are rarely seen before 40 years of age (4, 6) and usually diagnosed between the ages of 56–70 (1). Being consistent with the literature, we had no patients under 40 years in our study group. The mean age of our patients was 72. There is a slight women dominance among JPD patients (6). We also found a greater rate of females among our patients with JPD (n=18/24).

JPD may cause biliary stasis by compressing the distal end of the CBD or may induce reflux of gut bacteria into the bile ducts (7). Lotveit et al. (8) suggested that the pressure of the Oddi sphincter may be decreased in association with the duodenal diverticula, leading to a reflux of gut bacteria. Despite the manometric data of Lotveit (8), Kennedy et al. (9) insisted on that there is still a functional stasis within



the bile duct; and infection of a stagnant system may be easier than an incompetent system (9). B-glucuronidase-producing bacteria are much likely to be depicted in the bile of the patients with JPD and CBD stones, than the patients with CBD stones but without diverticula (10). Bacterial derived B-glucuronidase converts conjugated bilirubin back into its unconjugated state, which can precipitate as calcium bilirubinate (11) explaining the relative likelihood of pigment stones in patients with JPD (12). Primary and recurrent choledocholithiasis seem to be much more frequent in the patients with JPD (6, 9, 13-17). It has been shown that 40% of the patients who have CBD stones, have also JPD (18). Patients with choledocholithiasis were found to be 2,6 times more likely to have a JPD than the patients without stones (9). Similarly, when a JPD is seen at duodenoscopy, it is estimated that there is a chance for over than 50% for a bile duct stone to be present (9). In our study group, three of the patients (12,5%, n=3/24) had choledocholithiasis, one of them with a history of cholecystectomy. One of these three patients had cholecystolithiasis, whereas the gallbladder of the third patient was normal.

Sitouridis et al. found that JPD may cause deviation at the distal part of the CBD (3). We have observed a deviation of the distal CBD by JPD in 12,5% (n=3/24) of the study patients. None of these patients had choledocholithiasis, but one of them had dilatation of CBD, intrahepatic bile ducts, and pancreatic duct without any history of cholecystectomy. The diameter of the JPD of the patients with deviation of the CBD was larger (2.5 cm, 4.5 cm, and 4.5 cm) than the mean diameter (2,25 cm) of JPD in our study group.

Several authors have suggested that there is a relation between JPD and cholecystolithiasis (6, 13, 14, 19-23). On the contrary, some authors did not support this finding (24, 18). Egawa et al. (25) found that cholecystolithiasis was significantly more common

with the JPD with a diameter of 20 mm or more, than with the smaller ones. Gallbladder stones were detected in 44.4% (n=8/18) of the patients without cholecystectomy in our study group. Considering that the patients who had previous cholecystectomy probably had had cholecystolithiasis, the real cholecystolithiasis rate among JPD patients must be even higher.

The relation between JPD and pancreatitis is not clear. There are publications in the literature pointing out the effect of JPD in the pathogenesis of pancreatitis (26, 27, 28, 21). But it is not clear whether pancreatitis is caused by the JPD, or associated bile duct stones (1). It is proposed that the compression of the pancreatic duct by the diverticulum itself, or ampullary dysfunction secondary to JPD may cause pancreatitis (1). Uomo et al. (21) have found that idiopathic acute pancreatitis is significantly more common in JPD patients than in controls, and suggested that the presence of JPD should be searched especially in elderly patients, before defining an acute pancreatitis episode as idiopathic. Also, Leivonen et al. (22) found that the patients with JPD had idiopathic pancreatitis twice as often as controls, but this difference was not statistically significant. Kirk et al. (19) and Lobo et al. (1) were unable to show that the diverticula were the cause of the pancreatic obstruction and they both commented that there is not enough evidence to propound that JPD contribute significantly to the pathogenesis of pancreatitis. Zoepf et al. (6) also did not support a correlation for JPD with acute or chronic pancreatitis. We have observed mild pancreatic ductal dilatation in 45.8% (n=11/24) of our cases. Four patients (16.6%, n=4/24) had pancreatic side branch dilatations. Pancreatic atrophy was noted in only one patient (4.1%, n=1/24). No patient showed any sign of acute pancreatitis. Considering that our findings about pancreas or pancreatic duct can also be associated with the advanced age of our patients, it is really hard to say that the JPD can cause dilatation of the pancreatic duct.

This subject needs further studies with greater number of patients, and a control group consisting of patients in the same age group.

ERCP is a technically difficult procedure for JPD patients, thus the overall success rate of ERCP in patients with JPD is usually lower than the patients without JPD (1, 4, 6). MRCP can be useful in patients with JPD, especially for whom ERCP is technically difficult. It can demonstrate the biliary and pancreatic ducts and is proven to be useful in the detection of pancreatic disorders (29). Therefore, the indications of diagnostic ERCP can be reduced by using MRCP in these patients, and ERCP can be preserved for therapeutic purposes, or for problematic cases to confirm the MRCP findings.

The detection rate of the JPD by MRCP depends on the size and fluid content of the diverticulum (3). Routine MRCP studies without secretin injection has a low sensitivity for the detection of JPD. Secretin stimulation can be helpful because the secreted pancreatic fluid fills the diverticulum and makes it more visible (3, 30). Nevertheless, duodenal diverticula are usually easily recognized on MRI studies when completely or partially filled with gas (2). Because of their close relationship with the pancreatic head, duodenal diverticula can be potentially misinterpreted as cystic pancreatic lesions, if their content is purely fluid (31). In addition, it can be difficult to distinguish the diverticulum from the bowel lumen if it is filled with fluid. In our study, we noticed that air-fluid level was the most common feature that helped us to notice the duodenal diverticula and to differentiate it from a cystic pancreatic mass. Axial T2-weighted FSE sequences were the most useful sequences to demonstrate the air-fluid levels of the diverticula (95.8%, n=23/24). Thus, axial T2-weighted FSE images were the best images to show JPD and to differentiate them from pancreatic lesions. If the diagnosis of JPD is in doubt, careful examination of images for the pres-

ence of air-fluid level, or repeating the examination after oral administration of a cup of water or changing the patient's position may be helpful. Also, some authors recommend follow-up imaging or an upper gastrointestinal barium examination to confirm the diagnosis of a duodenal diverticulum (31). Maziotti et al. (2) suggested oral administration of a supermagnetic iron oxide contrast agent when pre-contrast images show superimposition of bowel-loop fluids.

There are some limitations of our study. One of them is the small number of

cases. In addition, we did not have a control group and due to the retrospective nature of our study we could not correlate the presence of JPD with another imaging modality, or with pathology. To determine the exact relationship between JPD and pancreatobiliary diseases, further studies with larger number of patients, including control groups are needed.

In conclusion, MRCP can be a useful radiological method to determine the presence, location, and size of the JPD, as well as their effects on the CBD and any associated pancreatobiliary dis-

eases. Axial T2-weighted images are the most useful sequence in demonstrating the air-fluid levels within the diverticula, which we think is the most common and important feature of JPD. JPD may cause deviation of the distal CBD by mass effect which may be a predisposing factor to pancreatobiliary symptoms. Gallbladder stones, biliary or pancreatic ductal dilatations are quite common in patients with JPD referring with pancreatobiliary symptoms. CBD deviation and choledocholithiasis are the other possible findings, but with a lesser probability.

## REFERENCES

1. Lobo DN, Balfour TW, Iftikhar SY, Rowlands BJ. Periapillary diverticula and pancreatobiliary disease. *Br J Surg* 1999; 86:588-597.
2. Mazziotti S, Costa C, Ascenti G, Gaeta M, Pandolfo A, Blandino A. MR Cholangiopancreatography Diagnosis of Juxtapapillary Duodenal Diverticulum Simulating a Cystic Lesion of the Pancreas: Usefulness of an Oral Negative Contrast Agent. *Am J Roentgenol* 2005; 185:432-435.
3. Tsitouridis I, Emmanouilidou M, Goutsaridou F, Kokozidis G, Kalambakas A, Papastergiou C, Tsantiridis C. MR cholangiography in the evaluation of patients with duodenal periampullary diverticulum. *Eur J Radiol* 2003; 47:154-160.
4. Boix J, Lorenzo-Zuniga V, Ananos F, Domenech E, Morillas RM, Gassull MA. Impact of Periapillary Duodenal Diverticula at Endoscopic Retrograde Cholangiopancreatography: A Proposed Classification of Periapillary Duodenal Diverticula. *Surg Laparosc Endosc Percutan Tech* 2006; 16:208-211.
5. Ackermann W. Diverticula and variations of the duodenum. *Ann Surg* 1943; 117:403-413.
6. Zoepf T, Zoepf DS, Arnold JC, Benz C, Riemann JF. The relationship between juxtapapillary duodenal diverticula and disorders of the biliopancreatic system: analysis of 350 patients. *Gastrointest Endosc* 2001; 54:56-61.
7. Tham TCK, Kelly M. Association of Periapillary Duodenal Diverticula with Bile Duct Stones and with Technical Success of Endoscopic Retrograde Cholangiopancreatography. *Endoscopy* 2004; 36: 1050-1053.
8. Lotveit T, Osnes M, Aune S, Larsen. Studies of the choledochoduodenal sphincter in patients with and without juxtapapillary duodenal diverticula. *Scand J Gastroenterol* 1980; 15:875-880.
9. Kennedy RH, Thompson MH. Are duodenal diverticula associated with choledocholithiasis? *Gut* 1988; 29:1003-1006.
10. Skar V, Skar AG, Bratlie J, Osnes M. Beta-glucuronidase activity in the bile of gallstone patients both with and without duodenal diverticula. *Scand J Gastroenterol* 1989; 24:205-212 (abstract).
11. Tazuma S. Epidemiology, pathogenesis and classification of biliary stones (Common bile duct and intrahepatic). *Best Pract Res Clin Gastroenterol* 2006; 20:1075-83.
12. Lotveit T, Foss OP, Osnes M. Biliary pigment and cholesterol calculi in patients with and without juxtapapillary duodenal diverticula. *Scand J Gastroenterol* 1981; 16:241-244 (abstract).
13. Kim M-H, Myung SJ, Seo DW, Lee SK, Kim YS, Lee MH et al. Association of periampullary diverticula with primary choledocholithiasis but not with secondary choledocholithiasis. *Endoscopy* 1998; 30:601-604 (abstract).
14. De Koster E, Denis P, Mante M, Otero J, Nyst J, Jonas C, et al. Juxtapapillary duodenal diverticula: association with biliary stone disease. *Acta Gastroenterol Belg* 1990; 53:338-343 (abstract).
15. Miyazawa Y, Okinaga K, Nishida K, Okano T. Recurrent common bile duct stones associated with periampullary duodenal diverticula and calcium bilirubinate stones. *Int Surg* 1995; 80:120-124 (abstract).
16. Lotveit T, Osnes M, Larsen S. Recurrent biliary calculi: duodenal diverticula as a predisposing factor. *Ann Surg* 1982; 196:30-32.
17. Hall RI, Ingoldby CJH, Denyer ME. Periapillary diverticula predisposing to primary rather than secondary stones in the common bile duct. *Endoscopy* 1990; 22:127-128 (abstract).

18. Hagege H, Berson A, Pelletier G, Fritsch J, Choury A, Liguory C, Etienne JP. Association of juxtapapillary diverticula with choledocholithiasis but not with cholecystolithiasis. *Endoscopy* 1992; 24:248-251 (abstract).
19. Kirk AP, Summerfield JA. Incidence and significance of juxtapapillary diverticula at endoscopic retrograde cholangiopancreatography. *Digestion* 1980; 20:31-35 (abstract).
20. Leinkram C, Roberts-Thomson IC, Kune GA. Juxtapapillary duodenal diverticula. Association with gallstones and pancreatitis. *Med J Aust* 1980; 1:209-210 (abstract).
21. Uomo G, Manes G, Ragozzino A, Cavallera A, Rabitti PG. Periapillary extraluminal duodenal diverticula and acute pancreatitis: an underestimated etiological association. *Am J Gastroenterol* 1996; 91:1186-1188 (abstract).
22. Leivonen MK, Halttunen JAA, Kivilaakso EO. Duodenal diverticulum at endoscopic retrograde cholangiopancreatography: analysis of 123 patients. *Hepatogastroenterology* 1996; 43:961-966 (abstract).
23. Kimura W, Nagai H, Kuroda A, Muto T. No significant correlation between histologic changes of the papilla of Vater and juxtapapillary diverticulum. Special reference to the pathogenesis of gallstones. *Scand J Gastroenterol* 1992; 27:951-956.
24. Novacek G, Walgram M, Bauer P, Schofl R, Gangl A, Potzi R. The relationship between juxtapapillary duodenal diverticula and biliary stone disease. *Eur J Gastroenterol Hepatol* 1997; 9:375-379 (abstract).
25. Egawa N, Kamisawa T, Tu Y, Sakaki N, Tsuruta K, Okamoto A. The role of juxtapapillary duodenal diverticulum in the formation of gallbladder stones. *Hepatogastroenterology* 1998; 45:917-20 (abstract).
26. Shemesh E, Friedman E, Czerniak A, Bat L. The association of biliary and pancreatic anomalies with periampullary duodenal diverticula. Correlation with clinic presentations. *Arch Surg* 1987; 122:1055-1057.
27. Osnes M, Lotveit T. Juxtaminopapillary diverticulum associated with chronic pancreatitis. *Endoscopy* 1977; 8:106-108 (abstract).
28. Carey LC. Pathophysiologic factors in recurrent acute pancreatitis. *Jpn J Surg* 1985; 15:333-340 (abstract).
29. Mortelé KJ, Wiesner W, Zou KH, Ros PR, Silverman SG. Asymptomatic nonspecific serum hyperamilasemia and hyperlipasemia: spectrum of MRCP findings and clinical implications. *Abdom Imaging* 2004; 29:109-14.
30. Ono M, Kamisawa T, Tu Y, Egawa N. MRCP and ERCP in Lemmel Syndrome. *J Pancreas* 2005; 6:277-278.
31. Macari M, Lazarus D, Israel G, Megibow A. Duodenal diverticula mimicking cystic neoplasm of the pancreas: CT and MR imaging findings in seven patients. *Am J Roentgenol* 2003; 180:195-199.