

A Case of *Dispharynx nasuta* (Rudolphi, 1819) In a Long-eared Owl (*Asio otus*)

Mahmut Sinan EREZ^{1*}, Mehmet Fatih BOZKURT², Mustafa Volkan YAPRAKÇI³, Ahmet GÖKSU¹, Esmâ KOZAN¹

¹Department of Parasitology, Faculty of Veterinary Medicine, University of Afyon Kocatepe, AFYONKARAHİSAR

²Department of Pathology, Faculty of Veterinary Medicine, University of Afyon Kocatepe, AFYONKARAHİSAR

³Department of Surgery, Faculty of Veterinary Medicine, University of Afyon Kocatepe, AFYONKARAHİSAR

*Corresponding author e-mail: mserez@aku.edu.tr

ABSTRACT

Cachexia and dehydration were detected as the clinical sign and sudden death occurred in a long-eared owl which was brought to Veterinary Health Practice and Research Center of Afyon Kocatepe University by officers of National Parks. As a result of necropsy, ingluvitis, proventriculitis, *esophagitis* and the parasites were detected throughout these organs. Furthermore, mild purulent bronchopneumonia, wide hemorrhages in lungs, severe hyperaemia among all tissues and organs were detected in the long-eared owl. After examination of one parasite which was sent to parasitology laboratory, it was diagnosed as *Dispharynx nasuta*. This case is the first report of *Dispharynx nasuta* from an owl in Turkey.

Keywords: *Dispharynx nasuta*, Helminth, Nematode, Owl, Turkey

Kulaklı Orman Baykuşunda (*Asio otus*) *Dispharynx nasuta* (Rudolphi, 1819) Olgusu

ÖZ

Milli Parklar görevlilerince Afyon Kocatepe Üniversitesi Veteriner Sağlık Uygulama ve Araştırma Merkezine getirilen kulaklı orman baykuşunda klinik olarak kaşeksi ve dehidrasyon tespit edilmiş ve ani ölüm gerçekleşmiştir. Nekropsi sonucunda ingluvitis, proventriculitis, *esophagitis* ve bu organlarda parazitlere rastlanmıştır. Bunun yanında baykuşta, orta şiddette purulent bronkopnömoni, akciğerlerde geniş kanamalar, tüm doku ve organlarda şiddetli hiperemi tespit edilmiştir. Parazitoloji laboratuvarına gönderilen 1 tane parazitinin incelenmesi neticesinde *Dispharynx nasuta* olduğu teşhis edilmiştir. Bu olgu Türkiye'de baykuşlarda ilk bildirim olmuştur.

Anahtar Kelime: *Dispharynx nasuta*, Helminth, Nematod, Baykuş, Türkiye.

INTRODUCTION

Long-eared owl is recorded as one of ten owl species which belongs to Strigidae and Tytonidae families in Turkey (Kizirođlu 1989). Long-eared owls usually feed on rodents and isopods (Marti 1976). Owls can be exposed to parasitic infections by eating various infected intermediate hosts which are present in their feed owing to their nutrition habits. *Dispharynx nasuta* is a pathogenic, acuaroid nematode which is found in proventriculus, esophagus and intestines of various avian species (Rickard 1985, Carreno 2008). Male parasites are 7-8.3 mm in length and 230-315 μm in width, female parasites are 9-10.2 mm in length and 360-565 μm in width respectively. Embryonated eggs are excreted with faeces of infected animals. Embryonated eggs release larvae in 4 days after they are taken orally by the pill bugs or sow bugs and larvae become infective in 26 days. Larvae reach sexual maturity 27 days after ingestion of infected intermediate host by avians and start to release embryonated eggs (Norton and Ruff, 2003). Proventricular ulcers, thickening of the proventricular walls and maceration are observed in severe infections (Norton and Ruff, 2003). Multifocal hemorrhagic, extreme mucous and mononuclear inflammatory lesions can occur. Weakness is the remarkable sign of clinically affected animals (Morishita and Schaul, 2007).

Although there is a limited number of reports on owl parasites in the world, the prevalence of *Synhimantus* spp was found to be highest in a study on 6 owl species in Spain (Ferrer et al. 2004). In another study in Spain, 8 nematode species were detected in owls and one of them was *Synhimantus laticeps* (Sanmartin et al. 2004). *Synhimantus affinis* was detected from 4 owl species in Italy (Santoro et al. 2012). There is no information on helminth parasites of owls in Turkey. Seventeen female and eight male nematodes were taken out from proventriculus and identified as *Dispharynx nasuta* as a result of necropsy of a wild male pigeon in Turkey (Gıcık 1997). As a result of faeces examination through domestic chickens in Van region, %2 of the helminths were reported as *Dispharynx nasuta* (Orunç and Biçek, 2009). It was recorded that 1 female 2 male nematodes as *Synhimantus laticeps* which was taken out from gizzard during postmortem examination of a female sparrowhawk in Samsun province (Umur et al. 2010). *Synhimantus laticeps* was detected in 4.77% of the 21 hawks during postmortem examination in Bursa (Tezel et al. 2015). 12 female and 1 male nematodes were collected from gizzard of a kestrel and identified as *Synhimantus laticeps* in Ankara (Aştı et al. 2017).

CASE REPORT

The long-eared owl was brought to Afyon Kocatepe University Veterinary Health Application and Research Center by National parks officers due to cachexia and dehydration and died without responding to the treatment which was applied. One parasite was collected from proventriculus during necropsy and sent to parasitology laboratory for examination. Then samples were taken systematically from tissues and organs and fixed in 10% neutral-buffered formaldehyde solution for histopathological examination. Samples were embedded in paraffin according to avian tissue processing. Sections with a thickness of 4-5 microns were taken with a microtome and stained with Hematoxylin-eosin (HE). Microscopic examination revealed numerous cross-sections of parasites at various diameters in the crop mucosa (4A). Epithelium was found as desquamate into the lumen of epithelial mucosa and crop glands. Disruption of epithelial integrity and microscopic ulcerations were observed in some regions (thick arrow). Crop glands were partly seen as cystic and cystic-dilate in appearance and hyperplasia of mucosal epithelium was observed. Inflammatory cell infiltration was observed around the cystic-dilate crop cysts, and they consisted of mild heterophile, leukocytes and lymphocytes(4B). Parasite sections and embryonated eggs were detected in the epithelial mucosa of proventriculus (4C) as an inside of villus and degenerative changes associated with necrosis were observed in the glands (4D). One parasite which was taken from proventriculus and sent to parasitology laboratory was fixed in 70% boiling alcohol and then examined with a microscope after made pellucid with lactophenol. According to related articles (Gıcık 1997, Zhang et al. 2004), the parasite which has 10.3 mm in length and 3.05 mm in width was identified as a female *Dispharynx nasuta*. Eggs of the parasite were measured 21.08x41.75 μm averagely. Anterior (Figure 2) and posterior (Figure 1) of the parasite and the photos of its eggs (Figure 3) were taken. A most distinguishing feature of *Dispharynx* is the presence of cords starting at the anterior end and continuing towards the back and ending without anastomosis by going forward again near the esophagus. This case is the first report from a long-eared owl in Turkey.

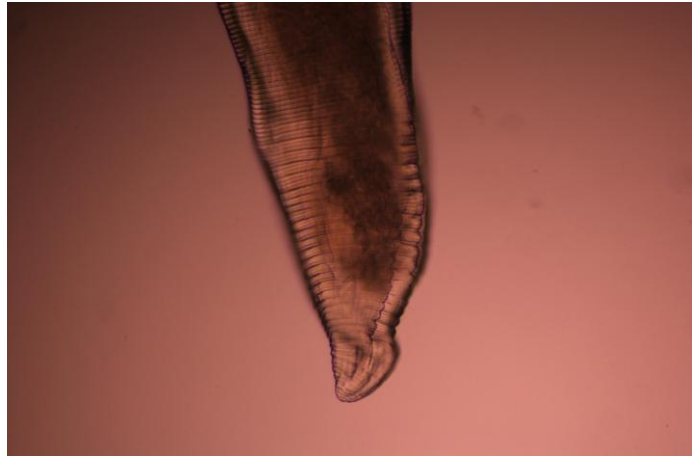


Figure 1. Posterior end of *Dispharynx nasuta* (Female)

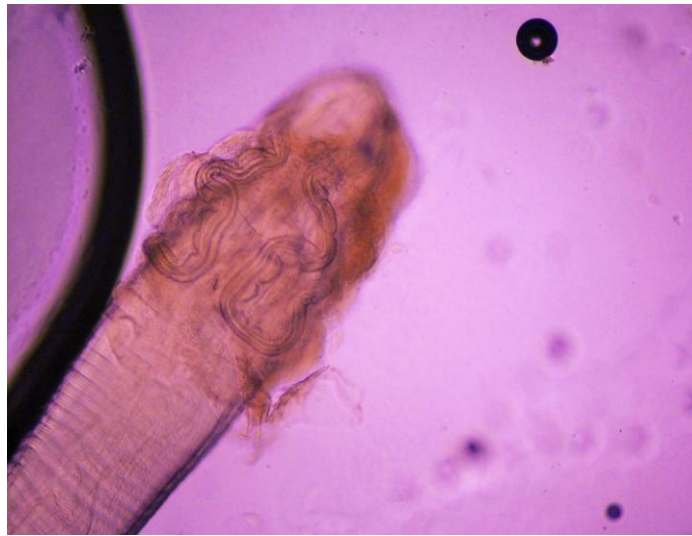

Figure 2. Anterior end of *Dispharynx nasuta* (Female)

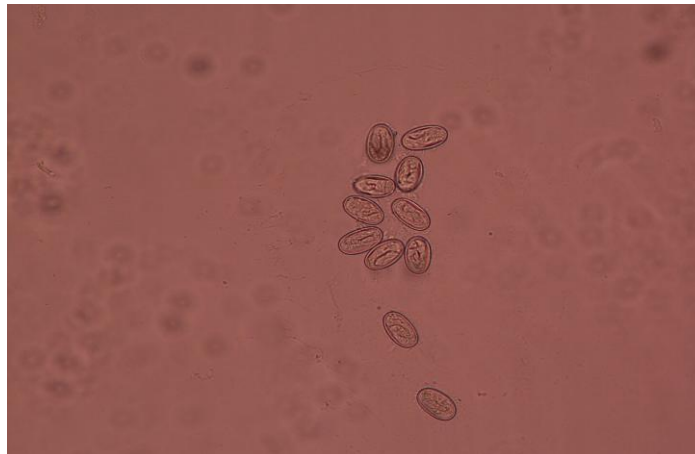

Figure 3. Eggs of *Dispharynx nasuta*

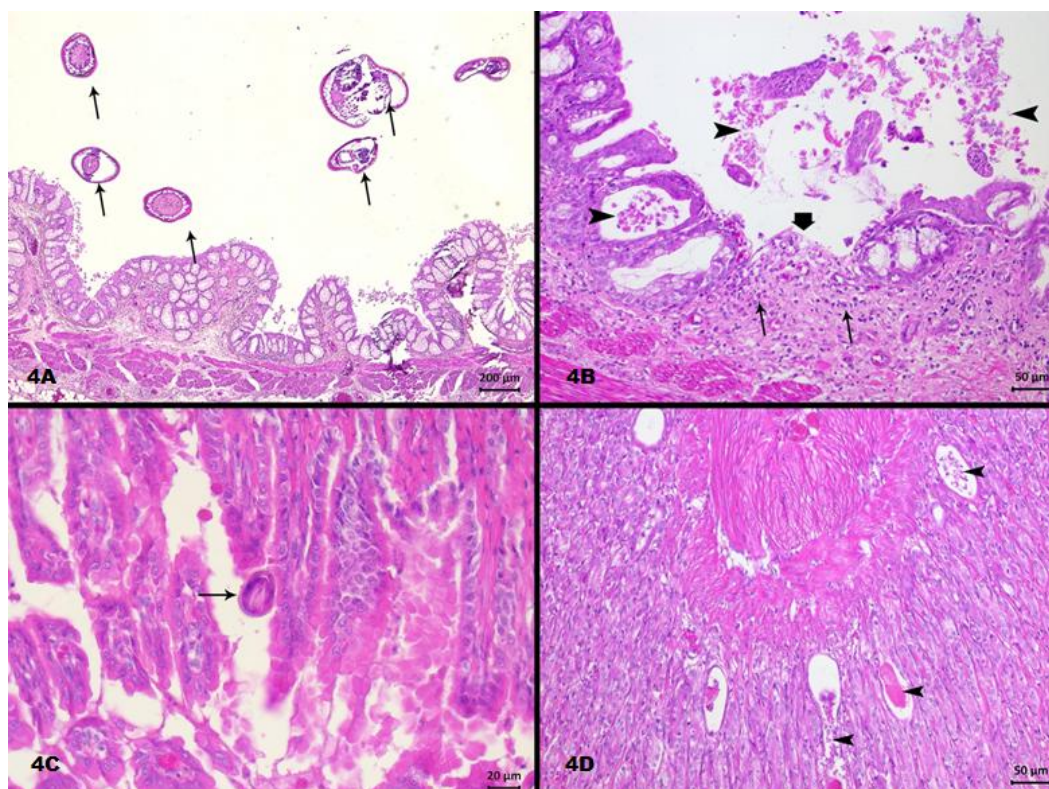


Figure 4A. Cross sections of numerous parasites from the crop (arrows) **4B.** Epithelial desquamation in the mucosa of crop and the lumen of glands (arrow heads), ulcer (thick arrow) and inflammatory cell infiltration which is consisting of heterophile, leukocytes and lymphocytes in the lamina propria. **4C.** *Embryonated* parasite egg in the mucosa of proventriculus (arrow) **4D.** Necrosis and cystic appearance in the proventriculus glands (arrow heads). **HE.** Bar= Actual length.

DISCUSSION AND RESULTS

Some authors reported that *Dispharynx*, a member of Acuariidae family, which contains more than twenty genus, is the subgenus of *Synhimantus* (Zhang et al. 2004). *Dispharynx*, which is more important in hunting birds, causes inflammation and thickening by occurring nodules in the wall of proventriculus (Güralp 1974). In this case, it was determined that the parasite caused significant damage to the digestive system and therefore it was observed to have importance in term of wild birds. According to some authors, *Dispharynx* is the subgenus of *Synhimantus* genus. A most distinguishing feature of *Dispharynx* is that cords starts at the anterior end and continuing towards the back then ending without anastomosis by going forward again near the esophagus. In this case, it was determined that cords were without anastomose. Although pre-digestive system lesions which were seen in this case is not lethal but combined with

respiratory system lesions and cage stress, it is thought that they can play an important role in the death of owl. Considering the feeding patterns of owls, it is observed that owls also eat insects which are intermediate hosts of parasitic infections. There is no clear information about the infection status of these animals because there are not many studies in Turkey to determine the status of parasitic infections in wild birds. This case is the first report of *Dispharynx nasuta* in owls in Turkey.

REFERENCES

- Aştı C, Cengiz G, Sarımehtetoğlu HO. A case of *Synhimantus (Synhimantus) laticeps* (Rudolphi, 1819) Railliet, Henry and Sisoff, 1912 (*Nematoda, Acuariidae*) in common kestrel (*Falco tinnunculus*). Ankara Üniv Vet Fak Derg. 2017; 64: 65-68.
- Carreno RA. *Dispharynx*, *Echinuria* and *Streptocara*. In: *Parasitic Diseases of Wild Birds*. Eds. Atkinson CT, Thomas

- NJ, Hunter B.** Blackwell Publishing Ltd., Ames, Iowa. 2008; pp. 326-342.
- Ferrer D, Molina R, Castella J, Kinsella JM.** Parasitic helminths in the digestive tract of six species of owls (Strigiformes) in Spain. *The Veterinary Journal.* 2004; 167: 181-185.
- Gıcık Y.** Yabani bir güvercinde (*Columba livia*) *Dispharynx nasuta* (Rudolphi, 1819) olgusu. *Ankara Üniv Vet Fak Derg.* 1997; 44(1-3): 93-95.
- Güralp N.** Helmintoloji. *Ankara Üniversitesi Veteriner Fakültesi Yayınları* 307. 1974; pp. 515-516.
- Kızıroğlu İ.** Türkiye Kuşları, *The Birds of Turkey*, OGM Yay., Gazi, Ankara. 1989; pp. 314.
- Marti CD.** A review of prey selection by the Long-eared owl. *Condor* 1974; 78: 331.
- Morishita TY, Schaul JC.** Parasites of Birds. In: *Flynn's Parasites of Laboratory Animals*. Ed: Baker D.G. Second Edition American College of Laboratory Animal Medicine. Blackwell Publishing. 2007; pp. 249
- Norton, R.A. and Ruff, M.D.** Nematodes and acanthocephalans. In: **Saif, Y.M., Barnes, H.J., Glisson, J.R., Fadly, A.M., McDougald, L.R., and Swayne, D.E.** (eds.). *Diseases of Poultry*. 11th ed. Iowa State University Press, Ames, Iowa. 2003; pp. 931-961.
- Rickard LG.** Proventricular lesions associated with natural and experimental infections of *Dispharynx nasuta* (Nematoda: Acuariidae). *Can J Zool.* 1985; 63: 2663-2668.
- Oruç Ö, Biçek K.** Van Yöresi Tavuklarında Paraziter Fauna Tespiti. *Türkiye Parazitoloji Dergisi.* 2009; 33 (2): 162-164.
- Sanmartin ML, Alvarez F, Barreiro G, Leiro J.** Helminth fauna of Falconiform and Strigiform birds of prey in Galicia, Northwest Spain. *Parasitol Res.* 2004; 92: 255-263.
- Santoro M, Mattiucci S, Nascetti G, Kinsella JM, Prisco FD, Troisi S, D'Alessio N, Veneziano V, Aznar FJ.** Helminth Communities of Owls (Strigiformes) Indicate Strong Biological and Ecological Differences from Birds of Prey (Accipitriformes and Falconiformes) in Southern Italy. *PLoS ONE.* 2012; 7(12): e53375.
- Tezel M, Girişgin AO, Birlik S, Yıldırımhan HS, Şenlik B.** Helminths of the digestive tract in *Buteo buteo* (Falconiformes: Falconidae) in Bursa Province of Northwest Turkey. *Turk J Zool.* 2015; 39: 323-327.
- Umur Ş, Beyhan YE, Pekmezci GZ, Açıcı M, Gürler AT.** First record of *Synbimantus (S.) laticeps* (Rudolphi, 1819) Railliet, Henry et Sisoff, 1912 (Nematoda, Acuariidae) in *Accipiter nisus* (Aves, Accipitridae) in Turkey. *Ankara Üniv Vet Fak Derg.* 2010; 57: 139-142.
- Zhang L, Brooks DR, Causey D.** Two species of *Synbimantus (Dispharynx)* Railliet, Henry and Sisoff, 1912 (Nematoda: Acuarioidea: Acuariidae), in passerine birds from the area de conservacion guanacaste, Costa Rica. *J Parasitol.* 2004; 90(5): 1133-1138.