

Early colon carcinoma of the appendix associated with adenomatous polyposis coli: a case report

Adenomatöz polipozis koli ile ilişkili apendiksin erken kolon karsinomu; olgu sunumu

Reşit Doğan Köseoğlu, Arzu Ensari, Yaşar Ayva

Department of Pathology, Ankara University School of Medicine

Adenomatous polyposis coli (APC) is an autosomal dominant disorder characterized by the presence of hundreds of adenomatous polyps in colon. However, in this syndrome, appendiceal localization of the polyps and malignant transformation in appendiceal polyps are very rare. We report here, a case of adenomatous polyposis coli showed foci of intra mucosal cancer in the appendiceal polyp and some colonic polyps.

Key words: **adenomatous polyposis coli, appendiceal malignancy, early colon carcinoma.**

Adenomatöz polipozis koli kolonda yüzlerce adenomatöz polip varlığı ile karakterli otozomal dominant bir hastalıktır. Bununla beraber bu sendromda poliplerin apendiks vermiformis lokalizasyonu ve apendiks lokalizasyonlu poliplerde malign transformasyon çok nadirdir. Burada, apendiks vermiformis lokalizasyonlu polip ve kolondaki bazı poliplerde intramukozal kanser odakları gösteren bir adenomatöz polipozis koli olgusunu sunuyoruz.

Anahtar kelimeler: **adenomatöz polipozis koli, apendiks tümörü, erken kolon kanseri.**

The polypoid lesions in adenomatous polyposis coli (APC) are also encountered in other regions of gastrointestinal tract. However, appendiceal polyps related with APC, particularly malign ones have been very rarely reported in the literature (1). Besides, since first description of primary adenocarcinoma in appendix vermiformis in 1882 by Berger, less than 300 cases associated with or without APC have been reported worldwide (2-7).

We report here a case of appendiceal early carcinoma associated with APC in a 39 year-old-male patient.

Case report

A 39-year-old male was admitted with a two weeks history of difficulty in passing stools, tenesmus and lower abdominal pain. On physical examination, there was bilateral lower abdominal tenderness and digital rectal examination revealed a mass in the distal rectum. Laboratory investigation including tumor marker levels was normal. Colonoscopic examination was impossible due to lumen obstruction caused by the rectal mass. Abdominal computerized tomography showed a mass in the rectum. Appendiceal enlargement was also observed. A rectal biopsy was performed. Histopathologically, adenomatous polyp showing focal superficial carcinomatous change was determined. Low anterior resection and appendectomy were performed.

Operation material consisted of 41 cm long rectosigmoidectomy specimen and 8 cm long appendectomy material. On gross examination, multiple pedunculated polyps were observed in the rectum (Figure 1a). The largest polyp was

Received: 09.21.2004 Accepted: 01.10.2005

Corresponding author:

Reşit Doğan Köseoğlu
Gaziosmanpaşa Üniversitesi Tıp Fakültesi
Patoloji Anabilim Dalı, Dekanlık Binası
60030, Tokat, Turkey
Phone : (356) 212 17 46-1182
Fax : (356) 213 31 79
E-mail : residdogan@hotmail.com

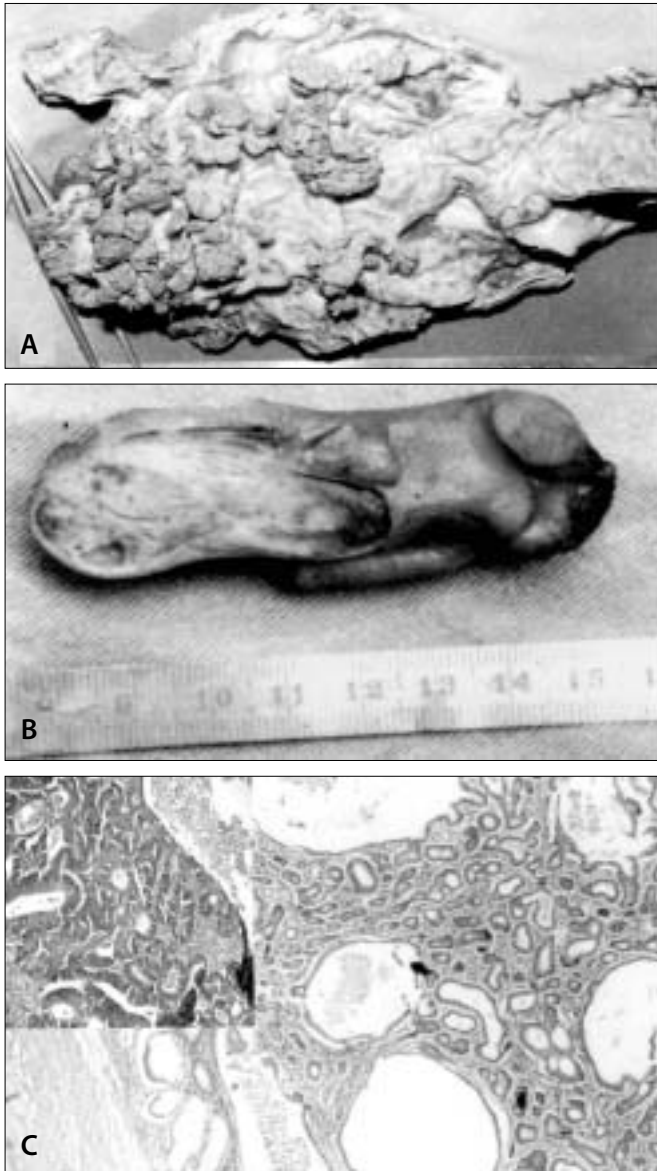


Figure 1a. Multiple polyps in the rectosigmoidectomy. 1b. The appearance of cut-section of sessile polyp in the appendix vermiformis. 1c. Adenomatous polyp in the lumen of appendix vermiformis. Inset shows the focus of intramucosal carcinoma in the appendiceal polyp (H-E, x40).

4 x 3 x 3 cm in dimensions with a partially villous surface. Thirty-eight polyps were present in the rectosigmoidectomy material. Grossly, the distal part of the appendix was large due to a sessile polypoid mass measuring 2 x 2 x 1 cm in the lumen (Figure 1b).

Most of the polyps including the appendiceal polyp showed microscopic features of tubular adenoma (Figure 1c). Only four colonic polyps were interpreted as tubulovillous adenoma. The surface and crypt epithelium of all polyps showed moderate to severe dysplasia. Focal superficial carcinomatous changes were noted in three of colonic polyps and the appendiceal polyp (Figure 1c).

The patient was performed colonoscopy after the surgery. The colonoscopy revealed multiple polyps spreading throughout the remaining part of colon. Total colectomy was offered to the patient. However, the patient refused second operation. Approximately five years later, a tumoral mass was detected in the splenic flexura of colon during patient's follow up. The former colectomy of the patient was completed to the total. On macroscopic examination, a 10x10 cm ulcero-vegetant tumoral mass was observed in the complementary colectomy material. Microscopically, moderate differentiated adenocarcinoma was determined. Tumor infiltrated to the serosa. In addition to tumoral lesion, eighty-three polyps were observed in the colectomy material. All polyps were adenomatous character and most of these polyps had the features of tubular adenoma. The others showed the characteristics of tubulovillous adenoma. Especially, in tubulovillous polyps, the foci of intra mucosal carcinoma were observed. After the second operation, the patient is alive and at close follow-up. The family history of our case was not present.

Discussion

In APC, adenomatous polyps may be seen in other regions of gastrointestinal tract, especially gastric fundus and duodenum (8). However, appendiceal involvement is rare in APC. Malignant transformation in appendiceal polyp was also very rare. Collins' review of 71000 human appendectomy species revealed 33 benign and six malign neoplastic appendiceal lesions in association with APC (9). We determined only a few cases of appendiceal adenocarcinoma related with APC reported in the literature (10-12). Although, most of APC patients have family history, about 20% of the cases are sporadic and have no demonstrable family history. In these cases, the spontaneous mutations are responsible for the development of neoplastic lesions. APC is usually diagnosed between the ages of 25 and 45 (1). The number of polyps is usually between 500 and 2500 in the vast majority of APC cases and must exceed 100 to be able to diagnose as APC (13). The polyps are usually type of tubular adenoma. The risk of malignant transformation in APC approaches 100% within 10-20 years from the diagnosis (1,13). At the first presentation time of our patient, we determined intramucosal carcinoma in the appendiceal polyp and three colonic polyp. Today, pull through procedure is the preferred operation in the treatment of the APC patients. In addition, the patients should be close followed up with regular upper gastrointestinal endoscopic examinations. Unfortunately, in our patient, colonoscopic examination could not be applied before the first operation. After the detection of multiple adenomatous polyps

in the rectum, colonoscopy and upper gastrointestinal endoscopy was performed in our case.

The malignant and benign epithelial tumors of the appendix are often associated with other primary alimentary or non-alimentary tract tumors (6,14). But, synchronous polypoid involvement of the colon and the appendix is rare in patients of APC. Furthermore, the malignant transfor-

mation in the appendiceal polyp associated with APC has been reported very rarely in the literature (11).

In conclusion, if a neoplastic lesion is determined in any part of gastrointestinal tract including appendix vermiformis, whole gastrointestinal tract must be investigated via endoscopy to rule out any synchronous neoplastic lesion.

References

1. Parker GM, Stollman NH, Rogers A. Adenomatous polyposis coli presenting as adenocarcinoma of the appendix. *Am J Gastroenterol* 1996;91:801-2.
2. Gilhorne RW, Johnston DH, Clark J et al. Primary adenocarcinoma of the vermiform appendix: report of a series of ten cases and review of the literature. *Br J Surg* 1984;71:553-5.
3. Harris GJ, Urdaneta LF, Mitros FA. Adenocarcinoma of the vermiform appendix. *J Surg Oncol* 1990;44:218-24.
4. Hannanel N, Powsner E, Wolloch Y. Primary appendiceal neoplasms. *Isr J Med Sci* 1993;29:733-4.
5. Hartley JE, Drew PJ, Qureshi A et al. Primary adenocarcinoma of the appendix. *J R Soc Med* 1996;89:111-3.
6. Gattuso P, Reddy V. Primary adenocarcinoma of the appendix: A review. *Military Medicine* 1990;155:343-5.
7. Ozakyol AH, Saricam T, Kabukcuoglu S et al. Primary appendiceal adenocarcinoma. *Am J Clin Oncol* 1999;22:458-9.
8. Kadmon M, Tandara A, Herfarth C. Duodenal adenomatosis in familial adenomatous polyposis coli. A review of the literature and results from the Heidelberg Polyposis Register. *Int J Colorectal Dis* 2001;16:63-75.
9. Collins DC. 71000 human appendix specimens: a final report summarizing forty years' study. *Am J Proctocol* 1963;14:365-81.
10. Seddon JA. Adenocarcinoma of the appendix associated with multiple adenocarcinomas of the colon. *Am Surgeon* 1965;31:180-3.
11. Maisel B, Foot NC. Multiple polyposis of the colon with malignant change involving colon and appendix. *Ann Surg* 1947;126:262-9.
12. Mibu R, Itoh H, Iwashita A, et al. Carcinoma in situ of the vermiform appendix associated with adenomatosis of the colon. *Dis Colon Rectum* 1981;24:482-4.
13. James M, Crawford MD. The gastrointestinal tract: Tumors of the small and large intestines-Familial adenomatous polyposis coli. In: Schoen FJ, 5th ed. *Robbins Pathologic Basis of Diseases*. Philadelphia: Saunders. 1994: p. 813-4.
14. Wolff M, Ahmed N. Epithelial neoplasms of the vermiform appendix (exclusive of carcinoid) Cystadenomas, papillary adenomas, and adenomatous polyps of the appendix. *Cancer* 1976;37:2511-22.

