



Deep Femoral Artery Injury After Conversion Hip Arthroplasty: A Case Report

Kalça Artroplastisi Dönüşümü Sonrası Derin Femoral Arter Yaralanması: Bir Olgu Sunumu

Alparslan UZUN¹ , Murat BİRİNCİ¹ , Cengiz EROL² , İbrahim AZBOY¹ 

¹ Istanbul Medipol University, School of Medicine, Department of Orthopaedics and Traumatology, Istanbul, Türkiye

² Istanbul Medipol University, School of Medicine, Department of Interventional Radiology, Istanbul, Türkiye

Geliş Tarihi (Received): 31.05.2024

Kabul Tarihi (Accepted): 21.10.2024

Yayın Tarihi (Published): 31.12.2024

Abstract

68-year-old male patient is admitted to hospital due to hip pain. He had undergone a surgery for left pertrochanteric fracture 18 days ago in another hospital. A locked plate was used for osteosynthesis which have failed immediately after mobilization. Single stage revision was performed due to implant failure and acute implant related infection. Hematoma formation and persistent wound drainage developed. Angiography identified an injury of deep femoral artery. Angiographic embolization was performed.

If patient experiences recurrent swelling, hematoma and persistent wound drainage, vascular injury should be considered. Angiography should be carried out for early diagnosis. Angiographic embolization provides effective treatment.

Keywords: Hematoma, Deep Femoral Artery, Ct Angiography, Angiographic Embolization, Prosthetic Joint Infection.

&

Öz

68 yaşındaki erkek hasta, kalça ağrısı şikayetiyle hastaneye başvurdu. Hasta, başka bir hastanede 18 gün önce sol taraflı pertrokanterek kırık nedeniyle cerrahi operasyon geçirmişti. Osteosentez için kilimli plak kullanılmış, ancak mobilizasyon sonrası implant hemen başarısız olmuştur. İmplant başarısızlığı ve akut implant ilişkili enfeksiyon nedeniyle tek aşamalı revizyon uygulanmıştır. Hematom oluşumu ve kalıcı yara akıntısı gelişmiştir. Anjiyografi, derin femoral arter yaralanmasını tespit etmiş ve anjiyografik embolizasyon yapılmıştır.

Eğer hastada tekrarlayan şişlik, hematoma ve kalıcı yara akıntısı görülürse, vasküler yaralanma düşünülmelidir. Erken tanı için anjiyografi yapılması gerekir. Anjiyografik embolizasyon etkili bir tedavi sağlar.

Anahtar Kelimeler: Hematom, Derin Femoral Arter, BT Anjiyografi, Anjiyografik Embolizasyon, Protez Eklem Enfeksiyonu.

Atıf/Cite as: XXXX

Copyright © Published by Bolu Abant İzzet Baysal University, Since 2022 – Bolu



Introduction

Vascular injuries are rare but devastating complications in total hip arthroplasty (THA). The risk of vascular injury should be kept in mind due to the proximity of major vessels when performing THA. The prevalence of vascular injury in primary THA was reported to be 0.08-0.5% [1]. Due to the more complex nature of revision THA the risk is even higher (0.2% - 1.2%) [2]. The most common causes for vascular injury are retractor compression, direct penetration during acetabular reaming, screw, and PMMA thermal necrosis [1]. Depending on the level and location of vascular injury, it may cause excessive bleeding compartment syndrome, functional loss, hypotensive shock, and even death [3]. Postoperative follow-up may reveal the condition, with the patient showing general deterioration, resistant anemia, hypotension, progressive swelling, hematoma formation, persistent wound drainage and severe pain.

In this case report, a patient who underwent revision THA due to implant failure and infection, persistent hematoma and bleeding caused by pseudoaneurysm of the deep femoral artery will be discussed. The patient was informed that the data concerning the case would be submitted for publication and informed consent was obtained.

Case Presentation

A 68-year-old male patient with known hypertension, hyperlipidemia, and benign prostatic hyperplasia was admitted in our clinic due to increasing left hip pain for two days. He had undergone open reduction and internal fixation operation with locked plate and screw for left pertrochanteric fracture 18 days earlier in another center (Figure 1a).

On physical examination, swelling, erythema, increased warmth and redness were observed around the skin incision. Hip joint movements were painful and limited. Vascular and neurologic examination was normal in the lower extremity. The Oxford hip score was 3. It was learned that the patient's body temperature had been subfebrile in recent days.

The C-reactive protein (CRP) was 20.4 mg/L, erythrocyte sedimentation rate (ESR) was 53 mm/hour, and Hemoglobin (Hb) was 12.3 gr/L. Pelvis X-ray showed implant insufficiency and loss of reduction (Figure 1b). Due to suspicion of implant related infection joint aspiration was performed under fluoroscopy, which revealed hemopurulent material (Figure 1c).

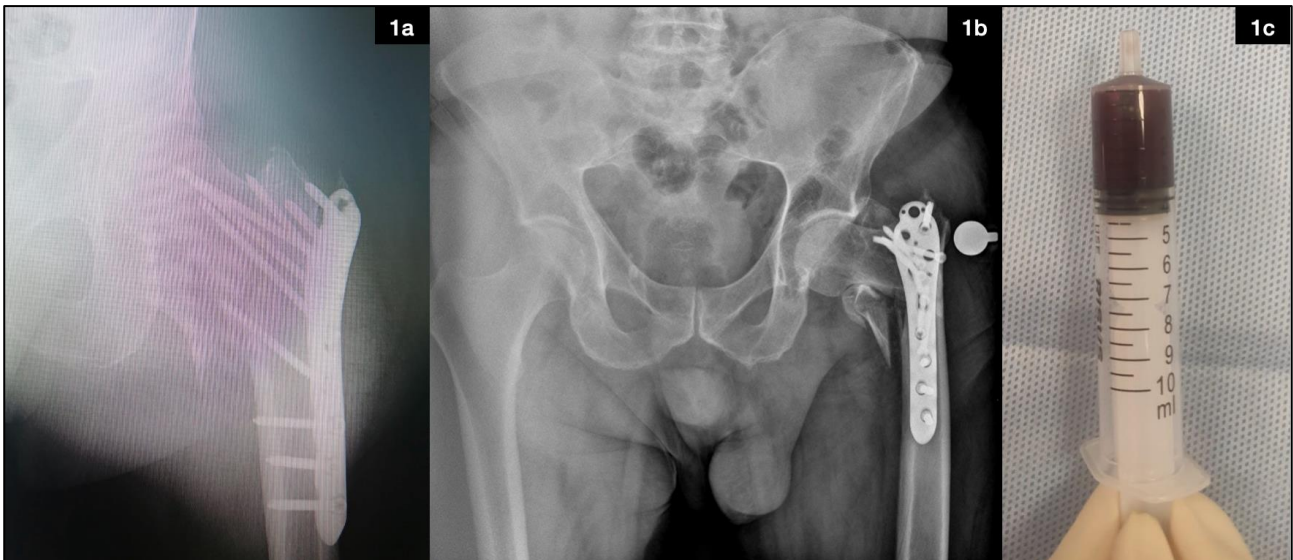


Figure 1.

Cell count showed 96.5% polymorphonuclear leukocyte (PMNL) and a white blood cell (WBC) count of 24,223. Oxacillin-resistant *Staphylococcus epidermidis* was identified in culture.

Additionally, since the patient had a urinary catheter in place since the first surgery, a complete urinalysis and urine culture were also ordered to detect possible urinary tract infection. The urinalysis showed 3+ leukocytes, and the culture revealed growth of *Candida parapsilosis*. Antibiotherapy was tailored as Rifampicin 300 mg

BID, Teicoplanin 800 mg OD, and Fluconazole 200 mg OD. A single-stage revision surgery was planned for treatment.

Previous incision was used and extended for posterior exposure. Plate and screws were loose and removed. Necrotic and infected tissues were removed by performing extensive debridement. The wound was irrigated with Crystalline, Hydrogen peroxide, Chlorhexidine, Betadine, and Serum physiologic. The surgical team was sterilized again, and the surgical equipment was replaced with new ones. Then, an appropriate cementless total hip prosthesis was implanted (Wagner SL revision femoral stem and Trilogy IT acetabular cup, Zimmer Biomed, Warsaw, Indiana, US). One cable was wrapped around the diaphysis to hold the displaced bone fragment in place (Figure 2a).

A hemovac drain was placed. The drain was removed when the amount of drainage decreased to 20 ml/day on the third postoperative day. The patient's general condition was good. There was no fever or discharge at the wound or any other pathological examination finding. On the 7th day, swelling and discharge started at the incision site. Since the hemoglobin values were unstable, repeated ES transfusions were performed.

The next day, as the swelling and discharge increased, the patient was taken back to the operating room for hematoma evacuation. Approximately 1 liter of organized hematoma was evacuated, and two hemovac drains were placed (Figure 2b).

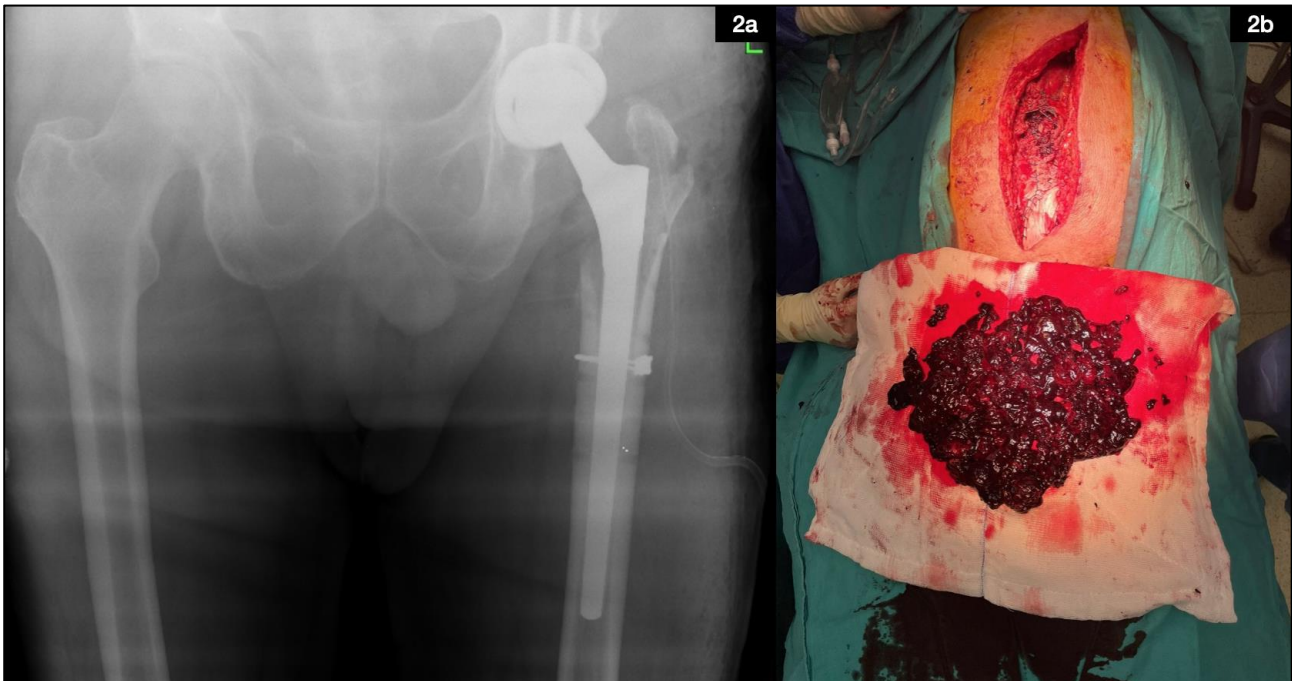


Figure 2.

During postoperative follow-ups, the patient's drainage output remained above 200 ml/day for 6 days. We administered i.v. tranexamic acid 1 gr TID for one month to decrease bleeding. Due to unstable hemoglobin levels, a total of 6 units of packed red blood cells were transfused. As bleeding continued, a CT angiography was performed and showed a pseudoaneurysm at the level of the cable fixation on the femoral diaphysis due to injury to the deep femoral artery branch. Transarterial embolization of the pseudoaneurysm via n-butyl cyanoacrylate glue was performed under angiography by interventional radiology (Figure 3).

After the embolization, the patient's general condition improved, and the bleeding decreased. Hemovac drains were removed on the second day after the embolization. Hemoglobin levels remained stable. However, swelling, wound drainage and fever has started again after 2 days. The CRP levels increased up to 291 mg/dL. Klebsiella Pneumonia growth was seen in a blood culture taken in the intensive care unit. Clinical and radiological findings indicated an acute postoperative prosthetic joint infection. A second single stage exchange was performed on the 6th day after embolization. Tissue samples were taken for culture. Klebsiella Pneumonia was identified. Antibiotics were tailored as Teicoplanin 400 mg OD, Rifampicin 300 mg BID and Meropenem 1 gr TID according to identified organism. CRP levels returned to normal. Antibiotics were planned to be administered in this regimen intravenously for 2 months and oral with Rifampicin 300 mg BID

and Doxycycline 100 mg BID for 6 months after iv therapy was done. The patient's general condition improved, was discharged on the 22nd day after the last surgery.

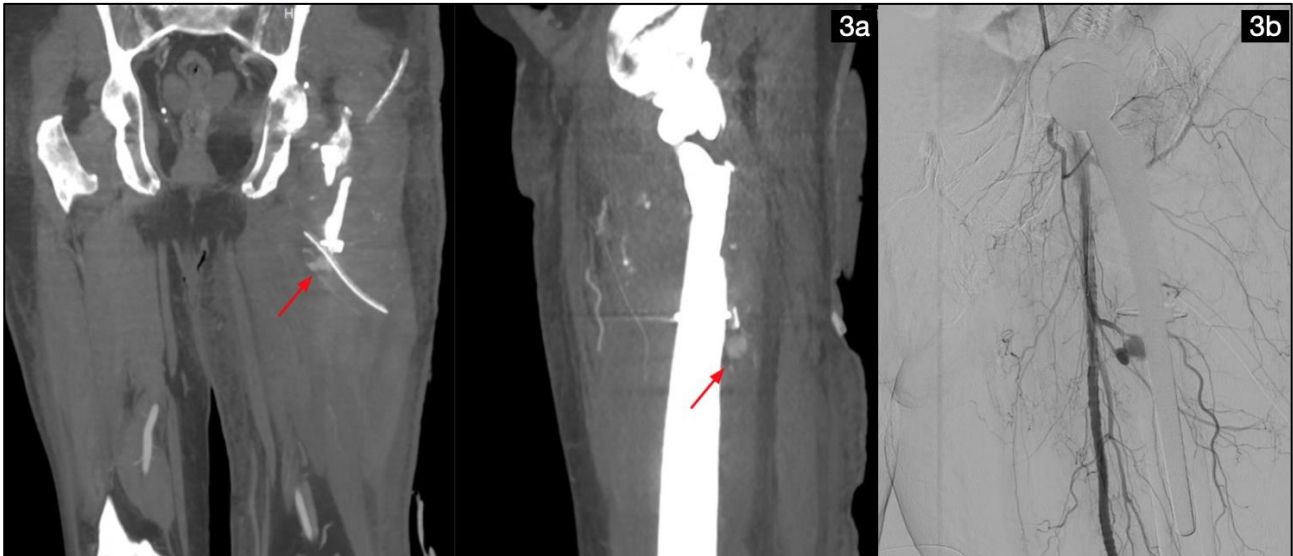

Figure 3.

Discussion

Although vascular injury is a rare complication after THA, it may have serious consequences. In revision surgeries, it is 2.4 times more common than in primary cases [1]. The most frequently injured vessels are the superior gluteal artery and deep femoral arteries [4]. Vascular injuries are more common around acetabulum compared to femoral region. In this presented case we encountered bleeding of a pseudoaneurysm of deep femoral artery. The deep femoral artery is more susceptible to injury in the proximal femur, as it runs near the diaphysis and between the muscles. The most common causes for vascular injury are retractor compression, direct penetration during acetabular reaming, screw, and PMMA thermal necrosis [1]. We were able to find a total of 4 published studies on deep femoral artery pseudoaneurysms in total hip arthroplasty. In one of these [5], the injury was thought to be secondary to intraoperative hip manipulation. In another [6], the authors attributed injury from the osteotome. According to Baker S et al., failure of the revision hardware and subsequent migration of the implants led to damage to the PFA and pseudoaneurysm formation [7]. And the last one was thought to be due to either inappropriate and aggressive placement of Hohmann retractors or aggressive exposure of the femur and acetabulum [8]. In our case the vessel may be damaged during cable insertion as the vessel is close to the femur.

Clinical suspicion should arise when there is an increasing swelling, a palpable mass, excessive bleeding from the drains and hemodynamic instability. However, in some situations symptoms appear late, and diagnosis may be delayed. Hence close monitoring of patients regarding bleeding symptoms is paramount to diagnose any vascular injury without delay.

Various radiological imaging methods such as Doppler ultrasound, CT angiography, MR angiography and conventional angiography can be used to diagnose vascular injuries. CT angiography is successful in revealing the vascular anatomy in detail and locating the active bleeding focus, because of its high spatial and temporal resolution. It has also the capability of being able to show the pathology that causes bleeding and help to guide the appropriate treatment.

Treatment methods vary depending on the type and location of the vascular injury. Conservative methods, endovascular intervention with angiography using embolization or stenting, primary repair and excision, are commonly used treatment options. These options should be evaluated based on the patient's clinical condition, the need for reoperation, and the damage to other anatomical structures. In our case, although we evacuated hematoma we could not find a significant bleeding focus during surgery. In cases of deep-seated bleeding, angiographic treatment methods should be considered. In the presented case, the patient's bleeding stopped and his hemodynamic status stabilized after angiographic embolization.

Bleeding after joint arthroplasty subsequently causes persistent wound drainage and hematoma which serves as a highly nutrient medium for growing microorganisms. Especially if there is a fascial defect, it can lead to prosthetic joint infections (PJI). In a study by Parvizi et al. [9] with 234 primary total knee or hip arthroplasty patients, prolonged wound drainage was present in 31% of PJI cases compared to control group (3%) and hematoma was present in 14% of PJI cases while this rate was 1% in the control group (for both comparison $p=0.0001$). Galat et al. reported the rate of developing PJI as 10.5% within 2 years in patients undergoing surgery to evacuate hematoma within 30 days after hip arthroplasty, while this rate was 0.8% in patients who did not require hematoma evacuation [10]. In our case, hematoma and persistent wound drainage inevitably caused acute postoperative PJI. We proceed with a single stage exchange and antibiotics for treatment. Patient is free of infection and happy with the current clinical condition at the first year follow-up.

Informed Consent: Written consent was obtained from the participants.

Conflict of Interest: Authors declared no conflict of interest.

Financial Disclosure: Authors declared no financial support.

Author Contributions: Idea/Concept: A.U.,M.B.,C.E.,İ.A.; Design: A.U.,M.B.,C.E.,İ.A.; Supervision: A.U.,M.B.,C.E.,İ.A.; Funding: A.U.,M.B.,C.E.,İ.A.; Materials: A.U.,M.B.,C.E.,İ.A.; Data Collection/Processing: A.U.,M.B.,C.E.,İ.A.; Analysis/Interpretation: A.U.,M.B.,C.E.,İ.A.; Literature Review: A.U.,M.B.,C.E.,İ.A.; Drafting/Writing: A.U.,M.B.,C.E.,İ.A.; Critical Review: A.U.,M.B.,C.E.,İ.A. The authors have accepted responsibility for the entire content of this manuscript and approved its submission.

References

1. A. Troutman, M. J. Dougherty, A. I. Spivack, ve K. D. Calligaro, "Updated strategies to treat acute arterial complications associated with total knee and hip arthroplasty", *J Vasc Surg*, c. 58, sy 4, ss. 1037-1042, Eki. 2013, doi: 10.1016/j.jvs.2013.04.035.
2. N. B, M. Rp, V. K, ve Z. R, "The mechanisms of severe arterial injury in surgery of the hip joint", *Clinical orthopaedics and related research*, sy 141, Haz. 1979, Erişim: 24 Haziran 2023. [Çevrimiçi]. Erişim adresi: <https://pubmed.ncbi.nlm.nih.gov/477093/>
3. N. A. Shoenfeld, S. A. Stuchin, R. Pearl, ve S. Haveson, "The management of vascular injuries associated with total hip arthroplasty", *J Vasc Surg*, c. 11, sy 4, ss. 549-555, Nis. 1990.
4. A. F. Mavrogenis, G. Rossi, E. Rimondi, P. Ruggieri, ve M. Mercuri, "Embolisation for vascular injuries complicating elective orthopaedic surgery", *Eur J Vasc Endovasc Surg*, c. 42, sy 5, ss. 676-683, Kas. 2011, doi: 10.1016/j.ejvs.2011.04.009.
5. C. Hall, W. S. Khan, S. I. Ahmed, ve D. H. Sochart, "A rare case of arterial avulsion presenting with occult blood loss following total hip arthroplasty: a case report", *J Med Case Rep*, c. 3, s. 9320, Ara. 2009, doi: 10.1186/1752-1947-3-9320.
6. M. Nozawa, M. Irimoto, K. Maezawa, T. Hirose, K. Shitoto, ve H. Kurosawa, "False aneurysm of the profunda femoris artery after total hip arthroplasty", *J Arthroplasty*, c. 15, sy 5, ss. 671-674, Ağu. 2000, doi: 10.1054/arth.2000.4643.
7. S. Baker, M. K. Huddleston, T. M. Goodwin, R. Voskuil, ve C. Sanders, "Left Profunda Femoral Artery Pseudoaneurysm After Revision Total Hip Arthroplasty", *Arthroplast Today*, c. 6, sy 4, ss. 906-910, Kas. 2020, doi: 10.1016/j.artd.2020.09.004.
8. S. Huynh, A. Kayssi, K. Koo, D. Rajan, O. Safir, ve T. L. Forbes, "Avulsion injury to the profunda femoris artery after total hip arthroplasty", *J Vasc Surg*, c. 64, sy 2, ss. 494-496, Ağu. 2016, doi: 10.1016/j.jvs.2015.08.088.
9. J. Parvizi, E. Ghanem, A. Joshi, P. F. Sharkey, W. J. Hozack, ve R. H. Rothman, "Does 'excessive' anticoagulation predispose to periprosthetic infection?", *J Arthroplasty*, c. 22, sy 6 Suppl 2, ss. 24-28, Eyl. 2007, doi: 10.1016/j.arth.2007.03.007.
10. D. D. Galat, S. C. McGovern, D. R. Larson, J. R. Harrington, A. D. Hanssen, ve H. D. Clarke, "Surgical treatment of early wound complications following primary total knee arthroplasty", *J Bone Joint Surg Am*, c. 91, sy 1, ss. 48-54, Oca. 2009, doi: 10.2106/JBJS.G.01371.