

# Spontaneous Urethrocutaneous Fistula in Child with Spastic Cerebral Palsy: A Case Report

Sinan Kilic<sup>1</sup>, Samed Verep<sup>2</sup>

<sup>1</sup>Department of Pediatric Surgery, Gebze Yuzyil Hospital, Gebze, Kocaeli, Türkiye

<sup>2</sup>Department of Urology, Gebze Yuzyil Hospital, Gebze, Kocaeli, Türkiye

Submitted: 2023-09-20

Accepted: 2023-12-24

## Correspondence

Op. Dr. Sinan Kılıç, MD  
Department of Pediatric Surgery,  
Gebze Yuzyil Hospital, Gebze,  
Kocaeli, Türkiye

E-mail: [dr.sinankilic@yahoo.com](mailto:dr.sinankilic@yahoo.com)

## ORCID

S.K. [0000-0003-3454-5538](https://orcid.org/0000-0003-3454-5538)

S.V. [0000-0002-1086-6380](https://orcid.org/0000-0002-1086-6380)

## Abstract

Urethrocutaneous fistulas are complications that usually seen after hypospadias repair. Spontaneous urethrocutaneous fistulas are extremely rare disorders unless related to the surgery of hypospadias. These fistulas are not associated with hypospadias repair, infection and trauma. While there are few cases reported in adults, there are no cases reported in children. Urethrocutaneous fistulas may rarely be encountered post-trauma, infection or due to weakness of spongy tissue of penis as well as.

Children with spastic cerebral palsy often face various problems due to prolonged hospitalizations. Pressure ulcers are among the most common of these issues. Urinary catheterization is frequently performed in these patients for urine monitoring. A 6-year-old male patient with cerebral palsy developed a urethrocutaneous fistula while being monitored in the pediatric intensive care unit. Pre-existing unnoticed partial prepuce and weakness in the corpus spongiosum were present in the patient. We suspect that the development of the urethrocutaneous fistula is attributed to frequent urethral catheterization and the development of decubitus ulcer in the penile region. Since a similar case is not found in the pediatric literature, our aim is to present this case for reference.

**Key words:** Cerebral Palsy; Hypospadias; Urethral fistula; Decubitus ulcer.

## INTRODUCTION

Urethrocutaneous fistulas are an undesirable opening in the penile skin through which urine can leak. The condition may be congenital or develop as a complication of an infection, injury, or surgery. Urethrocutaneous fistulas are rare but recognised disorders. There is currently no universally accepted classification for these disorders. Urethral fistulas can be classified into two forms: congenital and acquired (1). Congenital urethral fistulas are rarely reported anomalies

and are generally associated with anorectal malformations. They occur due to two main causes: either a rupture in the embryonic urethra located after a congenital blockage or a partial insult in the embryonic development, resulting in the failure of the mesoderm to surround the forming groove where the fistula develops (1, 2).

Acquired urethral fistulas are generally reported to result from various clinical conditions such as neoplasms, trauma, or infection-related complications (3). Straddle

**Cite:** Kilic S, Verep A. Spontaneous Urethrocutaneous Fistula in Child with Spastic Cerebral Palsy: A Case Report. The New Journal of Urology. 2024;19(1):38-41. doi: [10.33719/nju1363695](https://doi.org/10.33719/nju1363695)

injury and blunt penile trauma are the most commonly recognized forms of urethral trauma leading to urethral fistulas (3). Complications after some types of penile surgery such as circumcision and corporal-spongial and corporal-saphenous shunts for priapism, may also include urethral fistulas (4). Additionally, urethrocutaneous fistulas are one of the most frequently observed complications of hypospadias surgery, often necessitating repeated surgical interventions. Urethrocutaneous fistulas have been reported to be observed in 7,5% of cases after complex hypospadias repair (5,6). Cerebral palsy (CP) is a neurological condition affecting brain development and leading to abnormalities in muscle tone, movement, and motor skills. Its treatment requires a comprehensive approach, including neurological rehabilitation to address issues with muscle tone and the implementation of physical and occupational therapies. Managing associated conditions such as epilepsy, cognitive impairment, visual and hearing impairments, and disruptions in growth and gastrointestinal function is also integral to treatment process (7).

It is known that children who require frequent hospitalizations often experience problems associated with prolonged immobility in the same posture and frequent infections.

We present this case due to its rarity as a complication and the absence of reported cases of spontaneous urethrocutaneous fistula in children.

### CASE REPORT

A 6-year-old male patient was diagnosed with microcephaly and CP shortly after birth. He underwent surgery for a cleft palate. Due to the prolonged hospitalization, a tracheostomy was initially performed, and percutaneous endoscopic gastrostomy (PEG) tube was inserted for nutritional purposes.

Like many children with cerebral palsy, this patient continues his life with a home ventilator and requires periodic monitoring in the intensive care unit due to episodes of pneumonia. During his hospitalization in intensive care unit due to respiratory distress and pneumonia, urine output monitoring was conducted using a urethral catheter. As a result of the urine output monitoring, a spontaneous fistula developed in the penoscrotal region (Figure 1). No bacterial infection was demonstrated in the urinary analysis. The patient underwent surgery for fistula repair and also because of the possibility of infection. A cystofix catheter was inserted to ensure urinary drainage until the fistula healed (Figure 2). The operation involved cutting the ventral penile skin. It was

observed that the penile urethra was completely destroyed up to the penoscrotal region (Figure 3). A new urethral orifice was created in the penoscrotal area (Figure 4). Debridement was performed on infected tissues. Subsequently, the plan was to perform a vesicostomy or Mitrofanoff procedure, but due to the family's refusal, the patient's condition continued to be monitored in its current state.

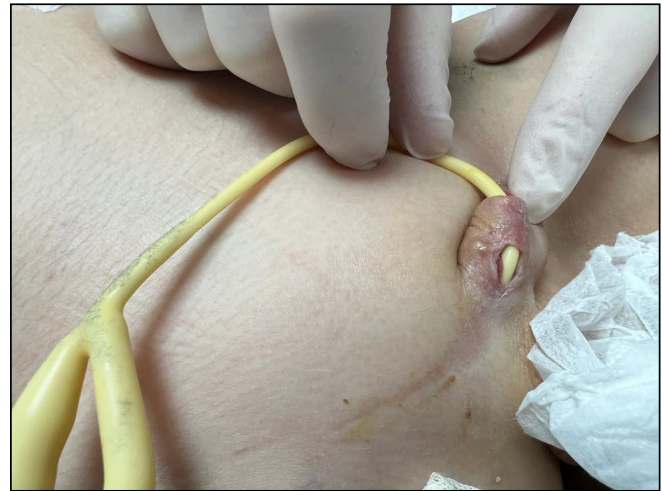


Figure 1. Urethral fistula in the penoscrotal region.

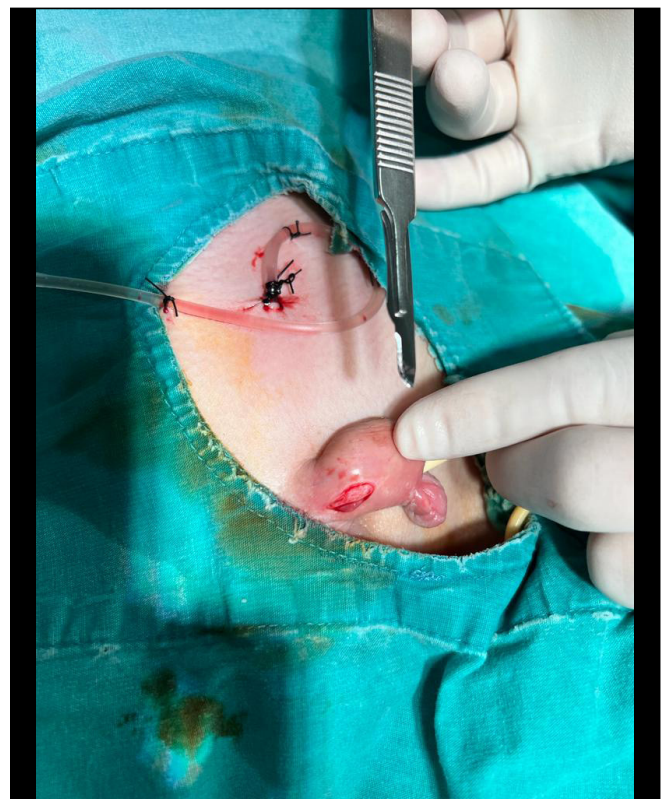
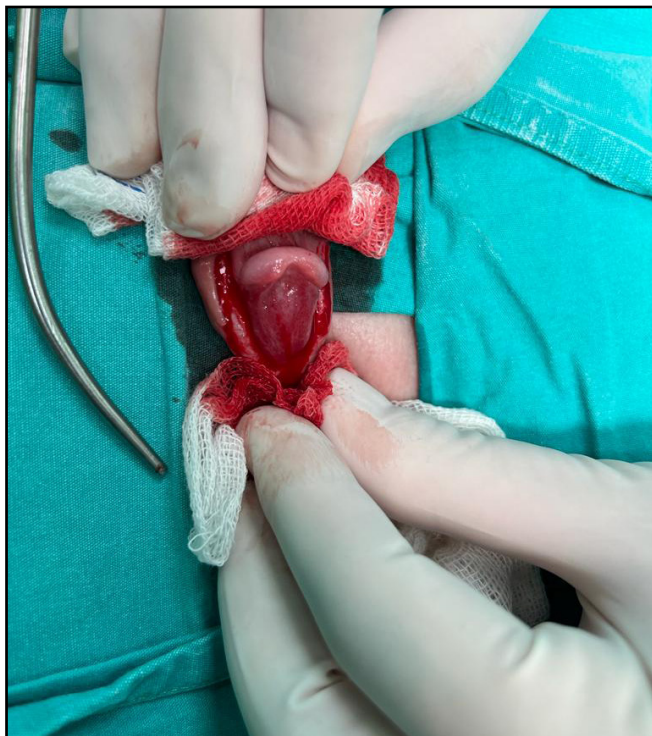
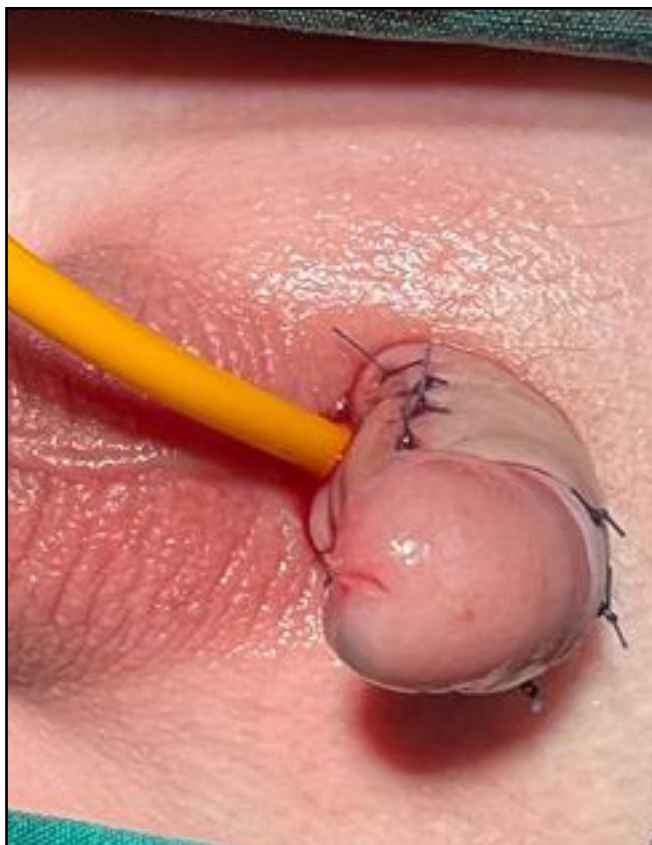


Figure 2. At the beginning of the operation, a cystofix catheter was inserted under ultrasound guidance.



**Figure 3.** Corpus spongiosum was hypoplastic and the distal urethra was completely destroyed.



**Figure 4.** After the repair of fistula and new urethra.

## DISCUSSION

Undoubtedly, the occurrence of the spontaneous ventral urethral fistula can be attributed to the underdevelopment of the corpus spongiosum during fetal development. Hence, to investigate the origin of this spontaneous ventral urethral fistula, we needed to delve into the mechanisms underlying the congenital hypoplasia of the corpus spongiosum. The causes of fetal anomalies can generally be categorized into genetic and environmental factors. In this particular case, it appears that environmental factors played a significant role in the pathogenesis of the patient's congenital deformity. Considering the potential risk factors during pregnancy and the presence of congenital hypoplasia of the corpus spongiosum at birth (8,9).

Children with cerebral palsy frequently experience pneumonia. Due to pneumonia or other respiratory failure, these patients require intensive care and have prolonged hospital stays. Without adequate and regular changes in posture, pressure ulcers can develop. While pressure ulcers commonly occur on the back and extremities, they can also appear in atypical areas such as the penis (10). Although we cannot definitively determine the exact cause in this patient, we suspect that it is a complication related to a pressure sore or an infection. It is likely that underlying hypoplasia of the corpus spongiosum, which is congenital in nature, contributed to its occurrence. Urethral fistulas often occur as a result of straddle injuries and blunt penile trauma. Additionally, certain penile surgeries like circumcision, as well as corporal-spongial and corporal-saphenous shunts for priapism, can lead to complications including urethral fistulas. It is worth noting that retracting a urethral catheter with a balloon can potentially result in the inadvertent cutting of the urethra resulting in multiple parts.

Spontan or non-congenital urethrocutaneous fistula is extremely rare and no cases have been reported in children. This anomaly was previously reported in only two cases in adults (11). One report was about a severely infected young man due to poorly controlled diabetes and the second report concerned a healthy man with unknown etiology (12). It seems plausible to conclude that the patient was born with congenital defect of hypoplasia of corpus spongiosum. The authors should more clearly state that although the cause of this anomaly is not definitively known, there are several theories which have been proposed.

This patient likely had a partial preputium, and there was also weakness in the associated corpus spongiosum. We believe that the development of a decubitus ulcer, following frequent catheterization and immobility due to

spastic cerebral palsy, led to the subsequent development of a urethrocutaneous fistula.

**Ethics approval and consent to participate:** Not applicable.

**Consent for publication:** Consent for publication was obtained from the family of the patient.

**Availability of data and material:** Not applicable.

**Competing interests:** The authors declare that there is no conflict of interest.

**Funding:** There is not any grant information and other sources of financial support .

**Authors' contributions:** Not applicable.

**Acknowledgements:** Not applicable.

## REFERENCES

- Ochsner MG, Joshi PN. Urethrocavernosus fistula. *J Urol.* 1982 Jun;127(6):1190. [https://doi.org/10.1016/s0022-5347\(17\)54291-3](https://doi.org/10.1016/s0022-5347(17)54291-3)
- Santangelo K, Rushton HG, Belman AB. Outcome analysis of simple and complex urethrocutaneous fistula closure using a de-epithelialized or full thickness skin advancement flap for coverage. *J Urol.* 2003 Oct;170(4 Pt 2):1589-92; discussion 1592. <https://doi.org/10.1097/01.ju.0000084624.17496.29>
- Palaniswamy R, Rao MS, Bapna BC, Chary KS. Urethro-cavernous fistula from blunt penile trauma. *J Trauma.* 1981 Mar;21(3):242-3. <https://doi.org/10.1097/00005373-198103000-00009>
- De Stefani S, Savoca G, Ciampalini S, Stener S, Gattucio I, Belgrano E. Urethrocutaneous fistula as a severe complication of treatment for priapism. *BJU Int.* 2001 Oct;88(6):642-3. <https://doi.org/10.1046/j.1464-4096.2001.02400.x>
- Amukele SA, Stock JA, Hanna MK. Management and outcome of complex hypospadias repairs. *J Urol.* 2005 Oct;174(4 Pt 2):1540-2; discussion 1542-3. <https://doi.org/10.1097/01.ju.0000176420.83110.19>
- Hardwicke JT, Bechar JA, Hodson J, Osmani O, Park AJ. Fistula after single-stage primary hypospadias repair- A systematic review of the It is likely that this patient had. *J Plast Reconstr Aesthet Surg.* 2015;68(12):1647-55. <https://doi.org/10.1016/j.bjps.2015.07.024>
- Gulati S, Sondhi V. Cerebral Palsy: An Overview. *Indian J Pediatr.* 2018;85(11):1006-1016. <https://doi.org/10.1007/s12098-017-2475-1>
- Grandhi TM, Shelley O, Ray AK, McGregor JR. Dorsal urethral fistula: case report and review of literature. *Urology.* 2004;63(1):175-6. <https://doi.org/10.1016/j.urology.2003.09.031>
- Yucel M, Kabay S, Sahin L, Koplay M, Yalcinkaya S, Cucioglu T, Hatipoglu NK. Posttraumatic ventral urethral fistula: a case report. *Cases J.* 2009 Sep 3;2:8644. <https://doi.org/10.1186/1757-1626-0002-0000008644>
- Graham HK, Rosenbaum P, Paneth N, Dan B, Lin JP, Damiano DL, Becher JG, Gaebler-Spira D, Colver A, Reddihough DS, Crompton KE, Lieber RL. Cerebral palsy. *Nat Rev Dis Primers.* 2016 Jan 7;2:15082. <https://doi.org/10.1038/nrdp.2015.82>
- Akman RY, Cam K, Akyuz O, Erol A. Isolated congenital urethrocutaneous fistula. *Int J Urol.* 2005 Apr;12(4):417-8. <https://doi.org/10.1111/j.1442-2042.2005.01050.x>
- Kanuck DM, Zgonis T, Jolly GP. Necrotizing fasciitis in a patient with type 2 diabetes mellitus. *J Am Podiatr Med Assoc.* 2006 Jan-Feb;96(1):67-72. <https://doi.org/10.7547/0960067>