

Treatment of upper eyelid agenesis in a Scottish Fold cat using cauterization and modified holtz- celsus surgical technique

Burak Gürkaş¹, Murat Karabağlı¹, Tuğba Kurt

Case Report

Volume: 8, Issue: 2
August, 2024
Pages: 155-158

¹.Department of Surgery, İstanbul University-Cerrahpaşa, Faculty of Veterinary Medicine, İstanbul, Türkiye.

Gürkaş, B. ORCID ID: 0000-0001-8320-4372; Karabağlı, M. ORCID ID: 0000-0002-3936-1730; Kurt, T. ORCID ID: 0000-0002-1467-2145

Article History

Received: 27.05.2024
Accepted: 09.06.2024
Available online:
17.06.2024

ABSTRACT

A six-month-old, female Scottish fold cat was presented to our Surgery Department of the Faculty of Veterinary Medicine, University of İstanbul-Cerrahpaşa due to complaints of blepharospasm, keratitis and epiphora in right eyes present since birth. In the ocular examination, lacking a part of the palpebra in the right eye and secondary trichiasis were observed. Palpebral defects and secondary trichiasis were repaired using an epilation, cauterization and modified Holtz-Celsus surgical technique. This technique provided a good cosmetic appearance and functional outcome to the patient.

Keywords: agenesis, cat, coloboma, eyelid, trichiasis

DOI: <https://doi.org/10.30704/http-www-jivs-net.1490932>

To cite this article: Gürkaş, B., Karabağlı, M., & Kurt, T. (2024). Treatment of upper eyelid agenesis in a Scottish Fold cat using cauterization and modified holtz- celsus surgical technique. *Journal of İstanbul Veterinary Sciences*, 8(2), 155-158.
Abbreviated Title: J. İstanbul vet. sci.

Introduction

Chylot Eyelids are mobile skin folds that move thanks to muscles and protect the eye against external dangers by covering the eyeball (Page et al., 2016). Feline eyelid agenesis describes a congenital condition in which patients are born with a deformed eyelid. In other words; eyelid agenesis describes colobomas on the eyelids (Esson & Calvarese, 2022). The term coloboma is most commonly used for ophthalmic conditions resulting from the congenital absence of any ocular tissue which have been reported in humans, peregrine falcons, cheetahs, snow leopards, sheep, goats and cats (Warren et al., 2020). Eyelid coloboma may be unilateral or bilateral, symmetrical or asymmetrical. It may be associated with other ocular anomalies such as microphthalmia, persistent pupillary membrane (PPM), choroidal and optic nerve colobomas, retinal dysplasia, and dermoids (Etemadi et al., 2013). Lateral involvement of the upper eyelids is typical in cats (Warren et al., 2020). Although its

etiology is unknown, conditions such as recessive genetic disorders and teratogenic effects have been reported (Demir & Karagözoğlu, 2019). Eyelid coloboma causes clinical findings such as blepharospasm, epiphora, and irregular corneal surface caused by trichiasis (Etemadi et al., 2013). Medical treatments often include treatment of inflammatory or ulcerative lesions, as well as the application of a topical lubricant to protect the corneal surfaces (Esson & Calvarese, 2022). Surgical treatments include; the Mustardé technique, lip-to-lid technique, Roberts-Bistner technique, bucket handle technique and cryo-epilation technique (Beel, 2015). This report, describes the use of epilation cauterization and modified Holtz-Celsus surgical technique to treatment of unilateral congenital eyelid coloboma in a cat. This technique has simply achieved both functional and cosmetic success.

*Corresponding Author: Burak Gürkaş
burakgurkas@gmail.com

<https://dergipark.org.tr/en/pub/http-www-jivs-net>



This work is licensed under the [Creative Commons Attribution 4.0 International License](https://creativecommons.org/licenses/by/4.0/).

Case description

A six-month-old female Scottish fold cat with blepharospasm, keratitis, epiphora and photophobia was referred to the Surgery Department of the Faculty of Veterinary Medicine, University of Istanbul-Cerrahpaşa. In the ophthalmic examination, it was observed that a part of the right upper palpebrae and its edges were unilaterally absent, and the skin hairs were in contact with the corneas, causing keratitis and blepharospasm (Figure 1). The palpebral fissures were not completely closed during blinking and causing epiphora. There is also congenital micropthalmia and mucopurulent discharge was observed in the left eye. Using of appropriate surgical procedures was planned to correct to all these ocular malformations and situations.

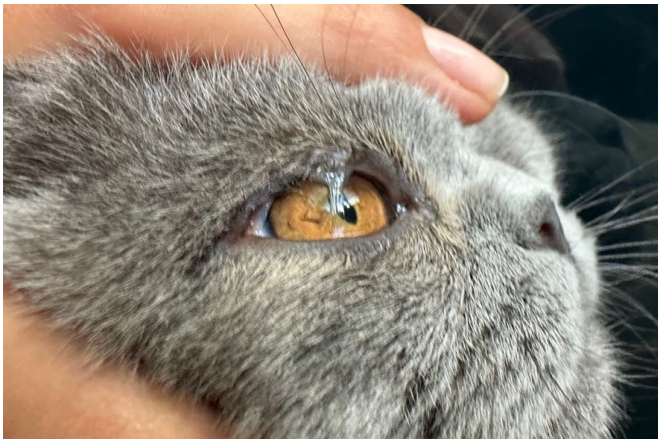

Figure 1. Lateral part of the upper palpebrae and its edges absent and trichiasis

General anaesthesia was carried out with medetomidin hydrochloride (0.08 ml/kg, IV, Domitor, Zoetis, Turkey) and ketamine hydrochloride (5mg/kg IV, Ketalar®, Pfizer, Turkey) followed by 2% isoflurone (Forane®, Abbott, Turkey) in oxygen. Analgesia was provided by meloxicam (0.2mg/kg, SC, Melox, Nobel, Turkey) 30 minutes before surgery. Amoxicillin clavulanic acid (12.5 mg/kg SC, Synulox, Zoetis, Turkey) was administered during to surgery.

Initially, the hairs in contact with the cornea were removed. The skin area which we extracted the hair follicles were cauterized to a depth of 3 mm (Figure 2). The patient's left eye was extirpated in the same operation. An Elizabethan collar was worn to the patient and discharged. Antibiotic eye drop and artificial tear drops were prescribed for ten days. The patient returned to our clinic with the same complaints in the right eye one month after the operation. The left eye extirpation area was healed uneventfully.

During the ocular examination, the same symptoms were observed again, and using a different

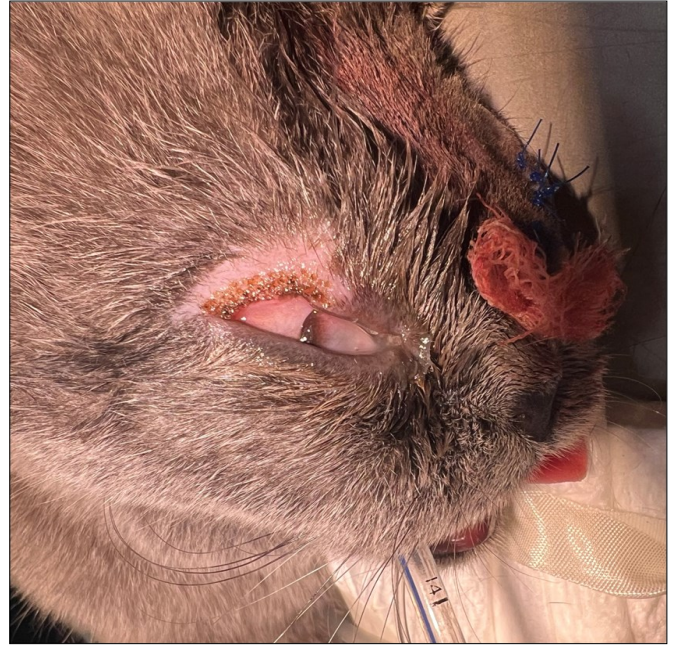


Figure 2. The skin area which we extracted the hair follicles were cauterized.

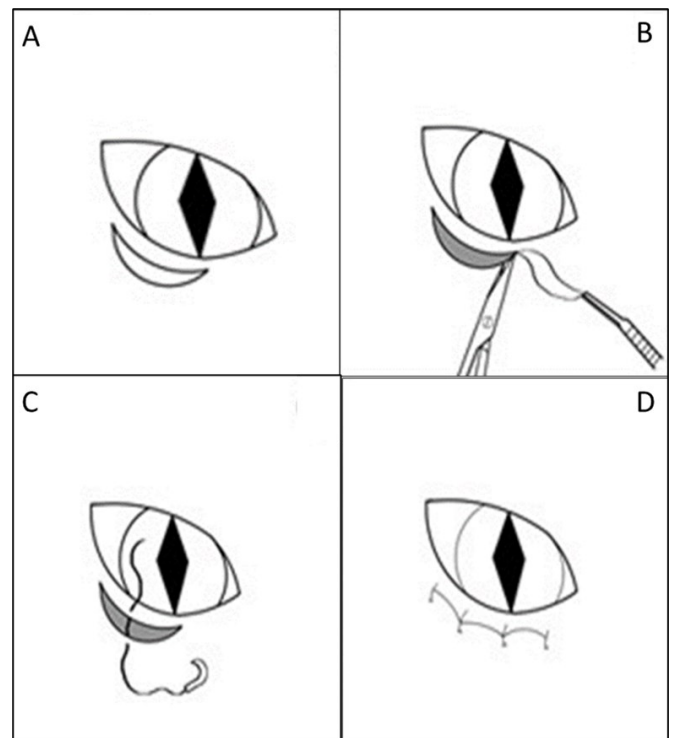


Figure 3. Modified Holtz-Celsus surgical technique (Diaz & Grundon, 2015). A) An initial incision is made with a scalpel blade 2mm from, but parallel to, the lid margin, extending along the area plus 2mm to 3mm either side. B) A second curve incision is applied ventral of the first incision, at a varying distance depending on the size of the damage, and the intervention tissue is resected. C-D) The wound is closed with simple interrupted sutures.

surgical technique was decided. In this operation; epilation, cauterization and modified Holtz-Celsus surgical technique (Figure 3) were applied together. A small piece of skin was removed, and the operation

line was stitched using a simple separate stitch technique with 4/0 PGA. When the stitches were removed at 10th post-operative day, ocular examination findings were normal. Antibiotic eye drop use was ceased but the artificial tear drops use were continued. No recurrence was observed in the patient's right eye in postoperative 1st, 3rd and 6th month follow-ups (Figure 4).



Figure 4. Patient's right eye in postoperative 1st, 3rd and 6th month follow-ups.

Discussion

Congenital eye anomalies are less common than other organ anomalies. Eyelid agenesis is one of the important anomalies of the eye and the most common area in cats is the upper eyelid, especially the lateral part (Demir & Karagözoğlu, 2019). In this case, agenesis was diagnosed in the lateral 1/3 of the right upper eyelid.

There is no breed predisposition. Eyelid agenesis can occur alone or with other ocular disorders such as microphthalmia, dermoids, PPM, lacrimal gland aplasia, retinal dysplasia and anophthalmia (Etemadi et al., 2013). In our case, while there is agenesis of the upper eyelid in the right eye, microphthalmia was

present in the left eye. Various medical treatment options are available for eyelid agenesis in cats (Woerdt, 2004). Patients with mild eyelid defects may only need to apply artificial tear lubricating ointment or gel (Warren et al., 2020). However, since it is difficult to get a response to medical treatment in eyelid anomalies, surgical methods are generally preferred (Demir & Karagözoğlu, 2019). Trichiasis can be resolved with various epilation procedures (Warren et al., 2020).

If the defective area is smaller than 1/3 of the eyelid width, primary closure after wedge-shaped excision is the ideal treatment, whereas complex techniques are required for larger defects (Whittaker et al., 2010). These are the applicable operating techniques in severe cases; direct surgical closure or partial-thickness eyelid repair for small defects, Roberts- Bistner technique, bucket handle technique and cryo-epilation, lip commissure to eyelid transposition, sliding skin graft, switch flap reconstruction, modified Mustarde technique and combined with Stades subdermal collagen injection (Warren et al., 2020).

Since our patient had agenesis in the lateral 1/3 of the upper eyelid and the case was considered mild, simple surgical procedures were preferred. The direction of the hair on the eyelid was towards the cornea, so at first epilation and cauterization were applied to the parts close to the eye, but it was unsuccessful. Because of these to slightly tighten the palpebral skin but not prevent the eye from closing, a small piece was removed using the modified Hotz-Celsius technique in the second operation, which is also used in entropion patients. Considering the patient's condition and these operation techniques applied together; it has been observed that possible complications are minimized due to the small incision line.

In conclusion, a large number of upper eyelid reconstruction options are available. When evaluating them and choosing the appropriate one, it is necessary to select the method that gives the best result and causes the least damage.

References

- Beel, J. (2015, November 23). Bilateral upper eyelid coloboma in a cat: surgical treatment. Retrieved from <https://www.vettimes.co.uk/article/bilateral-upper-eyelid-coloboma-in-a-cat-surgical-treatment/>
- Demir, A., & Karagözoğlu, G. S. (2019). Reconstruction of bilateral upper eyelid coloboma in a domestic shorthaired cat using roberts and bistner technique. *Kocatepe Veterinary Journal*, 12(2), 213-220.
- Diaz, J., & Grundon, R. (2015, July 13). Diagnosis and treatment of entropion in felines. Retrieved from <https://www.vettimes.co.uk/app/uploads/wp-post-to-pdf-enhanced-cache/1/diagnosis-and-treatment-of-entropion-in-felines.pdf>
- Esson, D. W., & Calvarese S. (2022). *Eyelid agenesis*. In D.W. Esson, S.Calverese (ed) *Clinical atlas of canine and feline ophtalmic disease 2th ed.* (pp. 62). California, USA: Wiley- Blackwell.
- Etemadi, F., Fard, R. M. N., Tamimi, N., Rezaei, M., Vahedi, S. M., Golshahi, H. & Seyed, A. J. (2013). Coincidence of upper eyelid coloboma with posterior synechia in a cat: a case report. *Journal of Veterinary Science & Technology*, 4(4), 139.
- Page, L., Gruaz, M., & Praag, E. (2016, May). Newborn rabbit with a congenital upper eyelid agenesis and a cephalocele. Retrieved from http://www.medirabbit.com/EN/Eye_diseases/Congenital/Colobome_bilat_en.pdf
- Warren, C., Grodzanic, S., & Reinstein, S. (2020). Use of free oral mucosal graft for treatment of feline eyelid agenesis in seven patients. *Veterinary Ophthalmology*, 23(4), 659-667.
- Whittaker, C. J. G., Wilkie, D. A., Simpson, D. J., Deykin, A., Smith, J. S., & Robinson, C. L. (2010). Lip commissure to eyelid tansposition for repair of feline eyelid agenesis. *Veterinary Ophthalmology*, 13(3), 173-178.
- Woerdt, A. (2004). Adnexal surgery in dogs and cats. *Veterinary Ophthalmology*, 7(5), 284-290.