

## ORIGINAL ARTICLE

## Surgical Techniques for the Treatment of Proximal Humerus Fractures in Elderly Patients: A Comparative Analysis

## Yaşlı Hastalarda Proksimal Humerus Kırıklarının Tedavisinde Cerrahi Teknikler: Karşılaştırmalı Bir Analiz

İdris Perktas <sup>1</sup>Osmaniye Special İbni Sina Hospital, Orthopedic Clinic, Osmaniye, Turkey

## Correspondence

İdris Perktas, Osmaniye Special İbni Sina Hospital, Orthopedic Clinic, Osmaniye, Turkey

E-Mail: drperktas@yahoo.com

## How to cite ?

Perktas İ. Surgical Techniques for the Treatment of Proximal Humerus Fractures in Elderly Patients: A Comparative Analysis. Genel Tıp Derg. 2024;34(4):581-6.

## ABSTRACT

**Aim:** It is common for the elderly, mostly due to osteoporosis and falls, to suffer proximal humerus fractures. This study aims to compare the efficacy of reverse total shoulder arthroplasty (rTSA) and open reduction with internal fixation (ORIF) in the treatment of these fractures with a focus on functional outcomes and patient satisfaction.**Methods:** In this retrospective study, 65-85-year-old patients who underwent rTSA or ORIF for displaced proximal humerus fractures between January 1, 2021 and January 1, 2022 were analyzed. Sixty patients participated in this study; they were divided into two groups as follows: Group 1 (rTSA, n=30) and Group 2 (ORIF, n=30). Constant and Oxford shoulder scores were used to evaluate outcomes while complications and patient satisfaction were also recorded. Statistical analysis involved t-tests and Chi-square tests whereby the p-value <0.05 indicated significance.**Results:** There was considerable improvement in various categories: Group 1 (rTSA), the constant score improved from preoperative stage of 35 ±8 to postoperatively of 75±10; oxford score ranged from preoperative level of 25±6 to postoperative level of 80±9 respectively p<0.05 for both cases Group II (ORIF), the constant score improved from preoperative stage of 33±7 to postoperatively of 65±12; oxford score ranged from preoperative level 24±5 to postoperative level 70±11 respectively (p<0.05 for both). Patients who underwent rTSA were more satisfied than those who underwent ORIF: 66.7% versus 54.5%. Several complications occurred more frequently in the ORIF group including delayed union (18.2% vs 3.3%) and infection (22.7% vs 6.7%).**Conclusion:** rTSA is associated with better functional outcomes, higher patient satisfaction, and fewer complications compared to ORIF for proximal humerus fractures in the elderly. These findings suggest that rTSA may be a more favourable surgical option for this population of patients. Moreover, future studies should involve larger samples and look at longer follow-up periods to ascertain these results.**Keywords:** Proximal humerus fractures, reverse total shoulder arthroplasty, open reduction internal fixation

## ÖZ

**Amaçlar:** Yaşlılarda proksimal humerus kırıkları, düşmeler ve osteoporoz nedeniyle yaygındır. Bu çalışmanın amacı, bu kırıkların tedavisinde ters total omuz artroplastisi (rTSA) ve açık redüksiyon ve internal tespit (ORIF) etkinliğini karşılaştırmak, fonksiyonel sonuçlar ve hasta memnuniyetine odaklanmaktır.**Yöntemler:** Bu retrospektif çalışma, 1 Ocak 2021 ile 1 Ocak 2022 tarihleri arasında yer değiştirmiş proksimal humerus kırıkları nedeniyle rTSA veya ORIF uygulanan 65-85 yaş arası hastaları analiz etti. Çalışmaya toplam 60 hasta dahil edildi, iki gruba ayrıldı: Grup 1 (rTSA, n=30) ve Grup 2 (ORIF, n=30). Sonuçlar Constant ve Oxford Omuz Skorları kullanılarak değerlendirildi ve komplikasyonlar ile hasta memnuniyeti de kaydedildi. İstatistiksel analizlerde t-testleri ve Ki-kare testleri kullanıldı, p-değerleri <0.05 anlamlı kabul edildi.**Bulgular:** Grup 1'de (rTSA) Constant Skorları preoperatif olarak 35 ± 8'den postoperatif olarak 75 ± 10'a, Oxford Skorları ise 25 ± 6'dan 80 ± 9'a anlamlı şekilde iyileşme gösterdi (her ikisi de p < 0.05). Grup 2'de (ORIF) Constant Skorları 33 ± 7'den 65 ± 12'ye, Oxford Skorları ise 24 ± 5'ten 70 ± 11'e iyileşti (her ikisi de p < 0.05). rTSA hastaları, %66.7 çok memnuniyet oranı ile ORIF grubundaki %54.5'ten daha yüksek memnuniyet bildirdi. ORIF grubunda gecikmiş kaynama (%18.2'ye karşı %3.3) ve enfeksiyon (%22.7'ye karşı %6.7) gibi komplikasyonlar daha yaygındı.**Sonuçlar:** rTSA, yaşlılarda proksimal humerus kırıkları için ORIF'e kıyasla daha iyi fonksiyonel sonuçlar, daha yüksek hasta memnuniyeti ve daha az komplikasyon ile ilişkilidir. Bu bulgular, rTSA'nın bu hasta popülasyonunda tercih edilebilir bir cerrahi seçenek olabileceğini göstermektedir. Bu sonuçları doğrulamak için daha büyük örneklemli ve uzun takip süreli gelecekteki çalışmalara ihtiyaç vardır.**Anahtar kelimeler:** Proksimal humerus kırıkları, Ters total omuz artroplastisi, Açık redüksiyon internal tespit

## Introduction

The high rate of proximal humerus fractures among the elderly is often due to their vulnerability to falls and osteoporosis. Various patterns of fractures, comorbidities, and intricate shoulder joints make managing this type of disability in the elderly challenging for orthopaedic surgeons (1). Based on factors such as functional demand or other health

conditions, there is surgical treatment that depends on whether it is nonsurgical or not (2). Reverse total shoulder arthroplasty (TSA) with stable angular plates or open reduction with internal fixation (ORIF) are two widely known surgical approaches to displaced proximal humerus fractures (3). Both methods are compared in this article (4). When proximal humerus fractures are not

properly treated, it means destabilising morbidity, as well as improving aspects of quality of life in addition to functioning during treatment (5, 6); thus, more patients should be able to receive attention once affected by this condition due to a reason that requires surgical advancement. These soft tissue envelope that require special handling but have complex features as a result, unlike the disease of the upper arm itself (7). Preservation of age-appropriate autonomy through repair rather than fracture surgery only ensures function restoration before incapacitating injury.

Instead of conservative treatments, some new complex surgical methods have recently been recommended to treat proximal humerus fractures in many cases. The development of sophisticated surgical techniques and prosthetic designs, together with the accumulated knowledge about long-term biomechanics, has resulted in this progress in surgical processes now (8, 9). Nonsurgical treatment generally works well for undisplaced/minimally displaced fractures (10). However, after elbow surgery, all complicated and displaced fractures must undergo an operative intervention aimed at optimising the general postoperative health status (9). The nature (size), the number of bone density, and the combined regularity depend on whether the TSA or ORIF approach will be used to treat them (11).

The complexity of fractures is also one reason why reverse total shoulder arthroplasty is increasingly becoming the preferred option, especially when there are limitations in reconstruction options due to poor quality bones (12). Changes in TSA deficits, altered bone quality, and complications pertaining to the union process. However, there are invasiveness issues within the country as well as prosthetic agreements, nerve marriages, etc. within the country. Another category of complements includes (13). On the other hand, ORIF preserves key anatomy with minimal invasion; however, this requires sufficient bone to achieve resolution, so malunion as well as hardware problems can develop (14).

This retrospective study was based on the hypothesis that surgical technique has a significant impact on the prognosis of the treatment of proximal humerus fractures in older people. By doing this study, surgeons are assisted because differences in functional outcomes between TSA and ORIF and patient satisfaction rates can be explained to them. Much can be gained from broad clinical data in retrospective studies.

In short, the treatment of proximal humeral fractures in geriatric patients presents many challenges to clinicians. Additionally, this study aims to compare TSA with ORIF approaches based on maximisation of patient outcomes while providing recommendations based on evidence-based practice on the surgeries to utilise; thus, orthopaedic surgeons for this examination will continue to grow as they could diagnose cases related to proximal humerus fractures using clinical evaluations leading to better patient care.

## Methods

To analyse the results of patients with proximal humeral fractures aged 65 to 85 years who underwent traditional ORIF or rTSA among a cohort, this study used two different surgical techniques. It commemorates the ethical principles of the Declaration of Helsinki and it was approved by the local Ethics Committee under Decision number 2673 on 22 June 22, 2022. Research carried out after the signed informed consent of the participants were obtained. The medical records of 67 patients who were treated between January 01, 2021, and January 01, 2022 were retrospectively reviewed. Seven patients (four dead) did not meet the inclusion criteria: Three cases were affected with incomplete preoperative or postoperative data, which resulted in the participation of 60 respondents. Therefore, patients were divided into two groups applying the two different methods of surgery; TSA and ORIF (Group I; n=30), (Group II; n=30) (Fig. 1).

Some of the studies that can be accessed are those about OTA/AO-11-B2 & C2 fragmented proximal humeral fractures of OTA / AO-11-B2 & C2 resulting from OTA / AO-11-B2 & C2 among people aged 65 to 86 years. Additionally, the lack of data files for certain cases, such as multiple traumatic injuries (beyond exclusion criteria) and untreated shoulder area surgeries, including pathological fractures and unrelated past surgeries, may be one of the reasons why we excluded some patients. The records indicated that the names of the Delta X, Exceed and Latitude product names were together with those of Group I(rTSA) supplies and if cemented/uncemented options were used or not. In addition, surgery was only one approach that was deltopectoral, while cemented / uncemented implantation was determined by bone quality, which was examined by an anaesthesiologist intraoperatively. In Group II subjects (ORIF), we recorded details such as the angular stable plate type used (LCP or PHILOS), the number of screws applied, the deltopectoral approach mode.

The most crucial was the result of pain and the range of movements that the joint allowed, which are prerequisites for leading the daily activity of the patient. Furthermore, OSS and radiographs were used to assess the quality of treatment and quality of life in patients with operatively managed proximal humeral fracture, respectively. Second, the complications of the patients and the satisfaction levels were also noted. Patients were followed for 2 years after surgery at regular postoperative intervals: 6 months 12 months, and 24 months. Some of the timelines for follow-up were changed during the analysis to ensure consistency of the data. This was not allowed to happen in observation during evaluation by surgeons who cannot be blind but because they are surgical skill surgeons instead of type of surgery the assessors did not know which kind, and hence bias could not be brought in.

Power analysis was carried out to determine the right sample size. Previous studies have shown that a

minimum of 25 patients per group are needed with a power of 80% at an alpha level of 0.5 to carry out the study and to find a statistically significant difference in constant and Oxford shoulder scores. We can still manage, given that the final calculated sample size is larger than this requirement for 30 patients in each group. The effect size is approximately 0.1. The evaluation of the effectiveness of the intervention was limited by the calculated estimate of the results, which was based on the marked differences between the two groups in the outcome measures. SPSS software was used for data analysis. Categorical variables are shown as n (%) and continuous data are presented as means  $\pm$  SD. The normal test was performed using the Shapiro-Wilk test. Differences in continuous variables having a normal distribution will be assessed using the t test or the Mann-Whitney U test if they are non-parametric. The Chi-square test was used to compare categorical variables. All p-values  $< 0.05$  indicated statistical significance.

## Results

The study period was such that it included 52 individuals. The patients consisted of two groups determined by the type of treatment they received due to fractures in their proximal humerus. Thirty patients in group one (rTSA) had a mean age age of  $72 \pm 5$  years, while twenty-two patients constituted group two (ORIF) with a mean age of  $70 \pm 6$  years. There was a similarity in gender distribution in both groups, where women made up 60% and 59% in groups one and two, respectively. Right-sided fractures were predominantly reported, which were 53.3% and 54.5% for group one and two consecutively. These studies showed that type B2, which was also known as type II-B2, represented 67% among other types for Group 1; However, in Group A, Type C2 is represented by 33%, while in Group B this same fracture makes up 36%. Osteoporosis existed in 73% of all these comorbidities followed by diabetes mellitus and hypertension found in each case with a frequency of 27%, respectively, and somewhere this condition existed at least 60% in either way (Table 1).

The surgical details showed a distinction between the groups where three different implants were used, namely Delta X (33%), Exceed (40%) Latitude (26%). For example, cementing occurred only six of ten reverse shoulder arthroplasties performed by our team, but their practice relied mainly on the use of LCP plates (54.5% ORIF cases), few PHILOS plates (44.5%) with the majority using more than five screws per joint, that is, 63% (Table 2).

Group One (rTSA) had significant improvements in constant scores from the preoperative period of  $35 \pm 8$  to the postoperative period of  $75 \pm 10$ , which is  $+40 \pm 5$  ( $p < 0.05$ ). In the same group, the Oxford scores increased from  $25 \pm 6$  to  $80 \pm 9$ , indicating a change of  $+55 \pm 4$  ( $p < 0.05$ ). Patients in Group Two (ORIF) had Constant Scores that improved from  $33 \pm 7$  before operation to  $65 \pm 12$  post-operations ( $+32 \pm 6$ ,  $p < 0.05$ ), and Oxford shoulder scores that ranged between

$24 \pm 5$  and  $70 \pm 11$ , with a difference of  $+46 \pm 5$  ( $p < 0.05$ ). These results clearly demonstrate the functional improvements observed in both groups, with rTSA showing greater improvement in both Constant and Oxford scores compared to ORIF (Figure 2, Figure 3, Table 3).

Regarding patient experience, it was 66. Of the 14 people in Group 1 (rTSA), 7 (50%) were very happy, while in Group 2 (surgery), only 54% (4 out of 7 patients) reported being very satisfied and 5% in Group 2 (ORIF). Additionally, Only 7% of 26 discharged from the TSA hospital were satisfied, while the figure was seen as 3% of 27 ORIF patients. Six people felt neither sadness nor happiness; 7% of patients with rTSA and 9.1% of patients with ORIF. In Operative stabilization, Internal Fixation Group (ORIF) there was 4. Among the 5% of dissatisfied patients, there were 4 others. 5% were very unhappy, while no patients in the TSA group were unhappy or very unhappy (Table 4).

**Table 1:** Baseline Characteristics of Patients

Characteristics	Group 1 (TSA) (n=30)	Group 2 (ORIF) (n=22)	p-value
Age (mean $\pm$ SD)	$72 \pm 5$	$70 \pm 6$	0.15 (t-test)
Gender			0.85 (Chi-square)
- Female	18 (60%)	13 (59%)	
- Male	12 (40%)	9 (41%)	
Fracture Side			0.92 (Chi-square)
- Left	14 (46.7%)	10 (45.5%)	
- Right	16 (53.3%)	12 (54.5%)	
Fracture Type			0.72 (Chi-square)
- 11-B2	20 (67%)	14 (64%)	
- 11-C2	10 (33%)	8 (36%)	
Comorbidities			
- Osteoporosis	22 (73%)	16 (73%)	0.99 (Chi-square)
- Diabetes	8 (27%)	6 (27%)	0.99 (Chi-square)
- Hypertension	18 (60%)	13 (59%)	0.94 (Chi-square)

**Table 2:** Surgical Details

Characteristics	Group 1 (TSA) (n=30)	Group 2 (ORIF) (n=22)	p-value
Prosthesis Type			
- Delta X	10 (33.3%)	N/A	
- Exceed	12 (40%)	N/A	
- Latitude	8 (26.7%)	N/A	
Fixation Type			
- Cemented	18 (60%)	N/A	
- Uncemented	12 (40%)	N/A	
Plate Type	N/A		
- LCP	N/A	12 (54.5%)	
- PHILOS	N/A	10 (45.5%)	
Number of Fasteners	N/A		0.45 (Chi-square)
- $\leq 5$	N/A	8 (36.4%)	
- $> 5$	N/A	14 (63.6%)	

**Table 3:** Functional Outcomes - Constant and Oxford Shoulder Scores

Outcome Measure	Preoperative (mean ± SD)	Postoperative (mean ± SD)	Change in Score (mean ± SD)	p-value (Paired t-test)
Group 1 (rTSA) Constant Score	35 ± 8	75 ± 10	+40 ± 5	< 0.001
Group 1 (rTSA) Oxford Score	25 ± 6	80 ± 9	+55 ± 4	< 0.001
Group 2 (ORIF) Constant Score	33 ± 7	65 ± 12	+32 ± 6	< 0.001
Group 2 (ORIF) Oxford Score	24 ± 5	70 ± 11	+46 ± 5	< 0.001

**Table 4:** Patient Satisfaction

Satisfaction Level	Group 1 (TSA) (n=30)	Group 2 (ORIF) (n=22)	p-value (Chi-square)
Very Satisfied	20 (66.7%)	12 (54.5%)	0.45
Satisfied	8 (26.7%)	6 (27.3%)	
Neutral	2 (6.7%)	2 (9.1%)	
Unsatisfied	0 (0%)	1 (4.5%)	
Very Unsatisfied	0 (0%)	1 (4.5%)	

**Table 5:** Complications

Complication Type	Group 1 (TSA) (n=30)	Group 2 (ORIF) (n=22)	p-value (Chi-square)
Delayed Union	1 (3.3%)	4 (18.2%)	0.07
Infection	2 (6.7%)	5 (22.7%)	0.11
Hemorrhage	0 (0%)	3 (13.6%)	0.04
Hardware Failure	N/A	2 (9.1%)	
Prosthesis Loosening	3 (10%)	N/A	
Nerve Injury	1 (3.3%)	1 (4.5%)	0.99

Complication rates were different in these two groups. Furthermore, the ORIF group was statistically more likely to have delayed union than those treated conservatively, with complications rates differing between the groups, and delayed union occurring in 3.3% of patients in Group 1 (rTSA) and Group 2 (ORIF) represented 2% of the patients. The study detected 6 cases of infections. 7% of the TSA group and 7% of the people who had ORIF. The haemorrhage occurred in 13. Intraoperative failure occurred in only 6% of those who received ORIF treatment, but was not observed in the TSA group. Hardware failure was recorded in 9 cases. 1% of ORIF and 10% of rTSA showed adverse events (loss of the prosthesis). The rate of nerve injury was mild and similar in both groups, occurring at 3% of patients with rTSA and 4% of 20 ORIF patients (Table5).

The findings of this study revealed that rTSA performed better, offering greater patient satisfaction and fewer complications compared to ORIF in the management of proximal humerus fractures among the elderly. This research indicates that rTSA could be a better surgical option for the treatment of these fractures in this group of patients.

**Discussion**

It is difficult to treat proximal humerus fractures in elderly patients. These fractures are complicated and are found in people with weak bones. Reverse total shoulder arthroplasty (RTSA) or open reduction internal fixation (ORIF) are some of the surgical options that have their own pros and cons. This analysis is necessary to

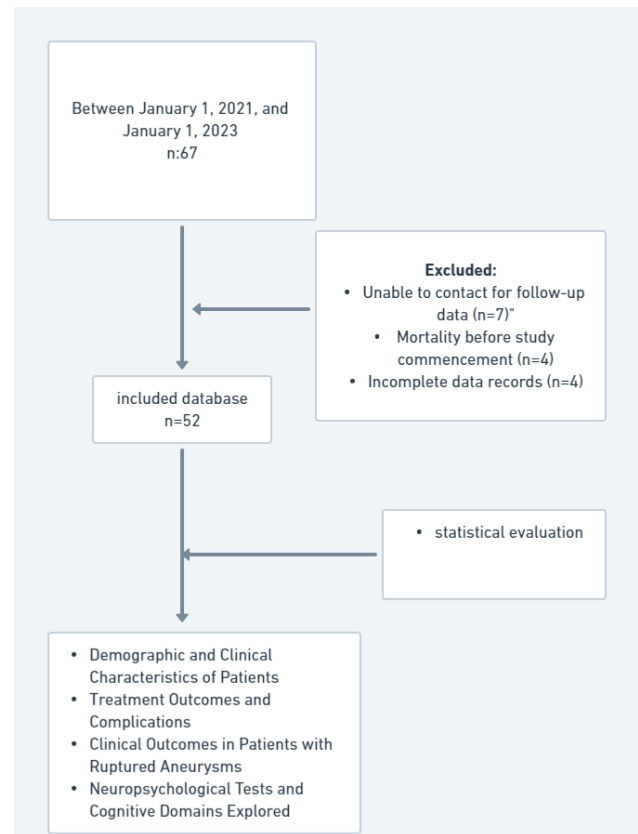


Figure 1

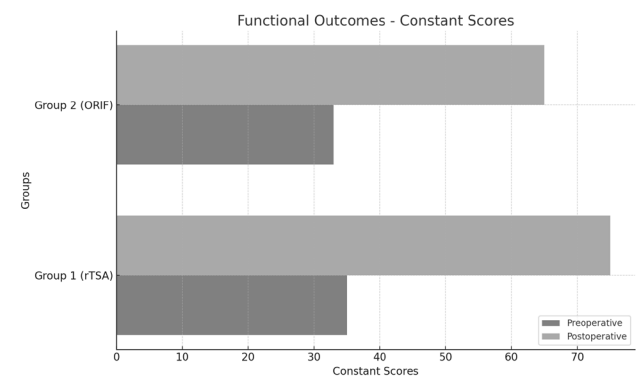


Figure 2

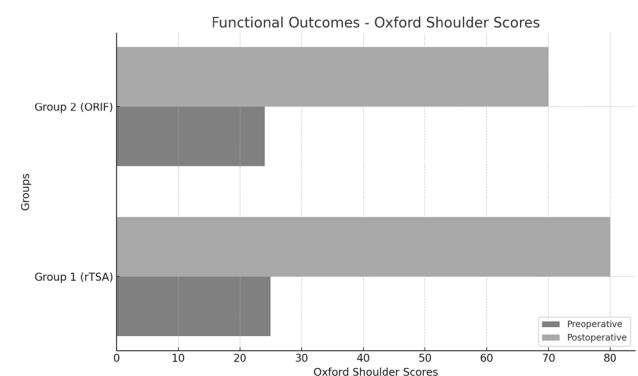


Figure 3



choose the most effective ways of treatment that can improve clinical outcomes, minimize complications, and increase patient satisfaction. Quality of life, as well as general health in older patients, is greatly affected by proximal humerus fractures. They cause long-term pain that also results in reduced mobility and functional limitations; All of these lead to loss of independence, among other things that makes them rely more on caregivers. The surgical method chosen may affect the healing process and the lifelong health of these patients (15). To provide optimal care to patients with proximal humerus fractures, it is important that clinicians know all the clinical conditions that exist with respect to this disease, among others. They include, but are not limited to; severity of fracture, bone quality, patient comorbidities, functional demands, etc. Compared to ORIF, RTSA has shown superior functional outcomes and low complication rates, making it a suitable option for elderly patients with complex fractures and poor bone quality (16).

Previous research carried out on the demographic characteristics related to this study confirms its findings. According to Garrigues et al. (2012), there was a mean age of 75 years of respondents in the study that involved 23 patients treated with hemiarthroplasty or RTSA, revealing no significant differences in distribution according to sex and type of fracture between groups (17). Similarly, Grubhofer et al. (2016) studied 52 shoulders from 51 subjects with an average age of 77 years supporting the demography of this study, finding that the mean ages for Group I (TSA) and Group II (ORIF) were  $72 \pm 5$  and  $70 \pm 6$  respectively. These studies confirm that elderly people have similar demographic profiles when it comes to the surgical management of proximal humerus fractures (18).

According to the present study, different implants and surgical techniques had different results. In RTSA, cementation was performed in some cases while Delta X, Exceed, and Latitude were also used as three types of implants. Similarly, in ORIF cases LCP and PHILOS plates were applied. These results are corroborated by the literature in which RTSA has been shown to lead to significant improvements in shoulder function and patient satisfaction after failure of ORIF. Grubhofer et al. (2017) demonstrated that RTSA showed significant improvements in constant scores with low revision rates leading to high patient satisfaction; thus, confirming its efficacy as a salvage procedure (19). Furthermore, Hussey et al. (2015) found that RSA resulted in a significant improvement in shoulder scores and pain reduction despite a complication rate even when considered as a salvage procedure (20). Current studies confirm these findings that implant choice and surgical technique play a significant role in the outcomes of the treatment of proximal humerus fractures among elderly patients.

The preoperatively constant scores were  $35 \pm 8$  and  $75 \pm 10$  postoperatively in which the study presents findings that Group 1 (TSA) showed significant improvements, and for the Oxford shoulder scores they changed from  $25 \pm 6$  to  $80 \pm 9$ . This is consistent with previous research. Shannon et al. (2016) found that primary reverse total shoulder arthroplasty (RTSA) results in substantial improvements in constant scores and overall shoulder function among patients with proximal humerus fractures, supporting the better results recorded in the TSA group in our study from this

article (21). Furthermore, Heo et al. (2023) conducted a systematic review and meta-analysis showing that RTSA had higher Constant-Murley and Oxford Shoulder scores compared to open reduction internal fixation (ORIF), thus confirming the better functional results and reduced complication rates observed between Group 1 (TSA) of our study compared to those of Group 2 (ORIF) (22). These comparisons demonstrate the effectiveness of RTSA in improving shoulder functioning and patient satisfaction among older adults with complicated proximal humeral fractures.

The finding of the present study demonstrates that 66.7% of patients in Group 1 (TSA) were very satisfied compared to 54.5% of Group 2 (ORIF), and it is consistent with previous studies. Compared to ORIF and HA, RTSA reported better patient-reported results and higher satisfaction scores, as well as a better functional score in patients with RTSA who reported the highest satisfaction rates (Chalmers et al., 2014) (23). Similarly, Garca-Fernandez et al. (2018) revealed significant improvements in shoulder function and patient satisfaction after RTSA for failed ORIF, where most patients rated their outcome as excellent or good. The results of this study confirm that RTSA is associated with considerably greater patient satisfaction compared to ORIF (24).

A recent investigation found that the ORIF group had more complications, such as delayed bone healing, infection, and defective equipment compared to the TSA group. This discovery is consistent with previous studies. In another study by Klug et al. (2019), it was reported that the overall rates of complication for ORIF and RTSA were 37.8% and 22%. In addition, there are higher rates of revision surgery for the ORIF group due to persistent motion deficits. The results support the observation of an increased risk of complications in patients treated with ORIF (25). Similarly, Shannon et al. (2016) also found that RTSA had lower complication rates compared to ORIF, with fewer cases of infection, hardware failure, and delayed union in the RTSA group, which supports our findings (26).

More research can be conducted on the long-term follow-up of patients who have undergone TSA and ORIF. However, more studies are needed to investigate the risks associated with delayed complications and the durability of the prosthesis, as well as the effects of ageing on surgical outcomes after surgery (27, 28).

Although much research provides useful information, it is not without flaws. In one respect, retrospective designs could be good for probing the effects on interventions in real life situations, but on the other hand, they are prejudiced and cannot establish causality. Furthermore, although the sample size was large enough to achieve the objectives of this study, its generalizability to others is limited. Future researchers in this area might find it useful to include more participants and conduct multicenter prospective studies that will validate these conclusions within a different population and health care context. Furthermore, further analyses must be performed continuously to determine whether these findings continue to apply in surgical settings, as there are ongoing changes in surgical procedures and implant types.

## Conclusion

The present study suggests that reverse total shoulder

arthroplasty (rTSA) presents a better trend in function after the operation, a higher patient satisfaction rate and a lower complication rate than open reduction and internal fixation (ORIF) for the treatment of proximal humerus fractures in the elderly. Such advantages as early function restoration, less trauma to the remaining bones, and the possibility of faster and better recovery make rTSA a more preferable surgical procedure, especially in situations with multiple fractures or poor bone condition. However, future research studies with larger samples and long-term follow-up are needed to confirm these findings and determine the potential risks and the long-term effect of the prosthesis.

**List of abbreviations:** rTSA: Reverse total shoulder arthroplasty, ORIF: Open reduction with internal fixation, OTA/AO: Orthopaedic Trauma Association / Arbeitsgemeinschaft für Osteosynthesefragen, SD: Standard Deviation, VAS: Visual analogue scale, SPSS: Statistical package for the Social Sciences, IRB: Institutional Review Board, LCP: Locking Compression Plate, PHILOS: Proximal Humeral Internal Locking System

**Acknowledgment:** N/A

**Conflict of Interest:** The authors declare that they have no conflict of interest to disclose.

**Funding:** This study did not receive financial support.

**Data availability:** Data used in this study can be provided on reasonable request.

## References

- Murena L, Canton G, Ratti C et al. Indications and results of osteosynthesis for fragility fractures of the proximal humerus in elderly patients. *Orthop Rev (Pavia)*. 2020;12(1):8559. Published on 28 April 2020. doi:10.4081/or.2020.8559
- Lanzetti RM, Gaj E, Berlinberg EJ, Patel HH, Spoliti M. Reverse Total Shoulder Arthroplasty Demonstrates Better Outcomes Than Angular Stable Plate in the Treatment of Three-part and Four-part Proximal Humerus Fractures in Patients Older Than 70 Years. *Clin Orthop Relat Res*. 2023;481(4):735-747. doi:10.1097/CORR.0000000000002480
- Gavaskar AS, Pattabiraman K, Srinivasan P, Raj RV, Jayakumar B, Rangasamy NK. What Factors Are Associated With Poor Shoulder Function and Serious Complications After Internal Fixation of Three-part and Four-part Proximal Humerus Fracture-dislocations?. *Clin Orthop Relat Res*. 2022;480(8):1566-1573. doi:10.1097/CORR.0000000000002190
- Erasmus R, Guerra G, Guerra L. Fractures and fracture-dislocations of the proximal humerus: A retrospective analysis of 82 cases treated with the Philos® locking plate. *Injury*. 2014;45 Suppl 6:S43-S48. doi:10.1016/j.injury.2014.10.022
- Schumacher A, Grawe B. Proximal Humerus Fractures: Evaluation and Management in the Elderly Patient. *Geriatr Orthop Surg Rehabil*. 2018;9:2151458517750516. Published 2018 Jan 25. doi:10.1177/2151458517750516
- Maier D, Jäger M, Strohm PC, Südkamp NP. Treatment of proximal humeral fractures - a review of current concepts enlightened by basic principles. *Acta Chir Orthop Traumatol Cech*. 2012;79(4):307-316.
- Howard L, Berdusco R, Momoli F, et al. Open reduction internal fixation vs non-operative management in proximal humerus fractures: a prospective, randomized controlled trial protocol. *BMC Musculoskelet Disord*. 2018;19(1):299. Published 2018 Aug 18. doi:10.1186/s12891-018-2223-3
- Vijayvargiya M, Pathak A, Gaur S. Outcome Analysis of Locking Plate Fixation in Proximal Humerus Fracture. *J Clin Diagn Res*. 2016;10(8):RC01-RC5. doi:10.7860/JCDR/2016/18122.8281
- Baker HP, Gutbrod J, Strelzow JA, Maassen NH, Shi L. Management of Proximal Humerus Fractures in Adults-A Scoping Review. *J Clin Med*. 2022;11(20):6140. Published 2022 Oct 18. doi:10.3390/jcm11206140
- Patel AH, Wilder JH, Ofa SA, et al. Trending a decade of proximal humerus fracture management in older adults. *JSES Int*. 2021;6(1):137-143. Published 2021 Oct 13. doi:10.1016/j.jseint.2021.08.006
- Patel AH, Wilder JH, Ofa SA, et al. How age and gender influence proximal humerus fracture management in patients older than fifty years. *JSES Int*. 2021;6(2):253-258. Published 2021 Dec 17. doi:10.1016/j.jseint.2021.11.007
- Familarí F, Rojas J, Nedim Doral M, Huri G, McFarland EG. Reverse total shoulder arthroplasty. *EFORT Open Rev*. 2018;3(2):58-69. Published 2018 Feb 28. doi:10.1302/2058-5241.3.170044
- Kozak T, Bauer S, Walch G, Al-Karawi S, Blakeney W. An update on reverse total shoulder arthroplasty: current indications, new designs, same old problems. *EFORT Open Rev*. 2021;6(3):189-201. Published 2021 Mar 1. doi:10.1302/2058-5241.6.200085
- Naberger M, Denard PJ, Collin P, Trebše R, Lädermann A. Mechanical complications and fractures after reverse shoulder arthroplasty related to different design types and their rates: part I. *EFORT Open Rev*. 2021;6(11):1097-1108. Published 2021 Nov 19. doi:10.1302/2058-5241.6.210039
- Luo D, Chen K, Qin P, Zhou N, Yu J, Zou J, et al. Effects of reverse total shoulder arthroplasty versus open reduction and internal plate fixation for the treatment of nonunions of proximal humeral fractures in the elderly. *J Clin Rehabil Tissue Eng Res*. 2018;22:2327-2332. doi:10.3969/j.issn.2095-4344.0187.
- Heo S, Faulkner H, An V, Symes M, Nandapalan H, Sivakumar B. Outcomes following reverse total shoulder arthroplasty vs operative fixation for proximal humerus fractures: a systematic review and meta-analysis. *Ann R Coll Surg Engl*. 2023. doi:10.1308/rcsann.2022.0120.
- Garrigues G, Johnston P, Pepe M, Tucker BS, Ramsey M, Austin LS. Hemiarthroplasty versus reverse total shoulder arthroplasty for acute proximal humerus fractures in elderly patients. *Orthopedics*. 2012;35(5):e703-8. doi:10.3928/01477447-20120426-25.
- Grubhofer F, Wieser K, Meyer D, Catanzaro S, Beeler S, Riede U, Gerber C. Reverse total shoulder arthroplasty for acute head-splitting, 3- and 4-part fractures of the proximal humerus in the elderly. *J Shoulder Elbow Surg*. 2016;25(10):1690-8. doi:10.1016/j.jse.2016.02.024.
- Grubhofer F, Wieser K, Meyer D, Catanzaro S, Schürholz K, Gerber C. Reverse total shoulder arthroplasty for failed open reduction and internal fixation of fractures of the proximal humerus. *J Shoulder Elbow Surg*. 2017;26(1):92-100. doi:10.1016/j.jse.2016.05.020.
- Hussey M, Hussey S, Mighell M. Reverse shoulder arthroplasty as a salvage procedure after failed internal fixation of fractures of the proximal humerus: outcomes and complications. *Bone Joint J*. 2015;97-B(7):967-72. doi:10.1302/0301-620X.97B7.35713.
- Shannon SF, Wagner E, Houdek M, Cross WW, Sánchez-Sotelo J. Reverse shoulder arthroplasty for proximal humeral fractures: outcomes comparing primary reverse arthroplasty for fracture versus reverse arthroplasty after failed osteosynthesis. *J Shoulder Elbow Surg*. 2016;25(10):1655-60. doi:10.1016/j.jse.2016.02.012.
- Heo SM, Faulkner H, An VVG, Symes M, Nandapalan H, Sivakumar B. Outcomes following reverse total shoulder arthroplasty vs operative fixation for proximal humerus fractures: a systematic review and meta-analysis. *Ann R Coll Surg Engl*. 2023. doi:10.1308/rcsann.2022.0120.
- Chalmers PN, Slikker W, Mall NA, Gupta A, Rahman Z, Enriquez D, Nicholson GP. Reverse total shoulder arthroplasty for acute proximal humeral fracture: comparison to open reduction-internal fixation and hemiarthroplasty. *J Shoulder Elbow Surg*. 2014;23(2):197-204. doi:10.1016/j.jse.2013.07.044.
- García-Fernández C, Lopiz Y, Rizo B, Serrano-Mateo L, Alcobia-Díaz B, Rodríguez-González A, Marco F. Reverse total shoulder arthroplasty for the treatment of failed fixation in proximal humeral fractures. *Injury*. 2018;49(Suppl 2):S22-S26. doi:10.1016/j.injury.2018.06.042.
- Klug A, Wincheringer D, Harth J, Schmidt-Horlohé K, Hoffmann R, Gramlich Y. Complications after surgical treatment of proximal humerus fractures in the elderly: an analysis of complication patterns and risk factors for reverse shoulder arthroplasty and angular-stable plating. *J Shoulder Elbow Surg*. 2019;28(6):1022-1032. doi:10.1016/j.jse.2019.02.017.
- Klug A, Wincheringer D, Harth J, Schmidt-Horlohé K, Hoffmann R, Gramlich Y. Complications after surgical treatment of proximal humerus fractures in the elderly: an analysis of complication patterns and risk factors for reverse shoulder arthroplasty and angular-stable plating. *J Shoulder Elbow Surg*. 2019;28(6):1022-1032. doi:10.1016/j.jse.2019.02.017.
- Agarwal AR, Wang KY, Xu AL, et al. Outpatient Versus Inpatient Total Shoulder Arthroplasty: A Matched Cohort Analysis of Postoperative Complications, Surgical Outcomes, and Reimbursements. *J Am Acad Orthop Surg Glob Res Rev*. 2023;7(11):e23.00008. Published 2023 Nov 16. doi:10.5435/JAAOSGlobal-D-23-00008
- Menekse S. Comparison of Outcomes between Open and Arthroscopic Rotator Cuff Repair. *Adv Orthop*. 2024;2024:5575404. Published 2024 Jan 11. doi:10.1155/2024/5575404