

## Estimation of Volume of Ox Brain And Gray and White Matter with Cavalier's Principle

Durmuş BOLAT\*

*Kırıkkale University, Faculty of Veterinary Medicine, Department of Anatomy, Kampus, Kırıkkale, Turkey*

\*Corresponding author e-mail: bolatdurmus@yahoo.com

### ABSTRACT

We estimated the volume values, ratios, and the relationship between brain weight and volumetric values of gray and white matter of the ox brain. Six fresh brains of Holstein-Friesian strain healthy ox (17-20 months old) were used. Fresh weights of the brains were measured using digital weighing. Brains were fixed by immersion method in 10% formalin solution for 3 weeks before measurements of gray and white matter volumes using Cavalieri's principle. The brains were serially cut using a salami slicer machine (Elta GmbH, Roedermark, Germany) with a mean thickness of 8.25 mm from rostral to caudal end and averages of 11 sections were obtained from the brains. The brain volume was  $348.00 \pm 50.48 \text{ cm}^3$ ,  $175.70 \pm 11.11 \text{ cm}^3$  in gray matter volume and  $172.30 \pm 42.90 \text{ cm}^3$  in white matter volume. Volume ratios of gray and white matter were 50.98% and 49.02% respectively. The ratio of brain weight to brain volume was 1. The ratio of gray and white matter in the brain of the ox is similar to that of the gray and white matter in the human brain, but that the sheep and horse are different.

**Keywords:** point counting method, brain volume, weight volume ratio, morphometry, stereology

**Sığırlarda Beyin, Ak Madde ve Gri Maddenin Cavalieri Prensibi ile Hacim Hesaplamaları**

### ÖZ

Bu çalışmada sığır beynindeki gri ve beyaz maddenin hacim değerlerini, oranları ve beyin ağırlığı ile volumetrik değerleri arasındaki ilişkiyi hesapladık. Holstein-Friesian ırklı sağlıklı sığıra ait (17-20 aylık) altı taze beyin kullanıldı. Beynin taze ağırlığı dijital tartım kullanılarak ölçüldü. Cavalieri ilkesini kullanarak gri ve beyaz madde hacimlerinin ölçümünden önce beyinler daldırma yöntemi ile % 10 formalin solüsyonunda 3 hafta tespit edildi. Beyinler rostral'den kaudal'e doğru salam dilimleme makinesi (Elta GmbH, Roedermark, Almanya) ile ortalama 8.25 mm kalınlıkta seri olarak kesildi ve beyinlerden ortalama 11 kesit elde edildi. Beyin hacmi  $348.00 \pm 50.48 \text{ cm}^3$ , gri madde hacmi  $175.70 \pm 11.11 \text{ cm}^3$  ve beyaz madde hacmi  $172.30 \pm 42.90 \text{ cm}^3$  idi. Gri ve beyaz maddenin hacim oranları sırasıyla % 50.98 ve % 49.02' dir. Beyin ağırlığının beyin hacmine oranı 1 idi. Sığır beynindeki gri ve beyaz maddenin oranı insan beynindeki gri ve beyaz cevherinkine benzer, ancak koyunlardan ve atlardan farklıdır.

**Anahtar Kelimeler:** noktalı alan metodu, beyin hacmi, ağırlık hacim oranı, morfometri, stereoloji

To cite this article: Bolat D. Estimation of volume of ox brain and gray and white matter with Cavalier's principle. *Kocatepe Vet J.* (2018) 11(1): 30-34.

## INTRODUCTION

The brain is the most complex organ of the body. It is the center of command that controls everything from basic functions such as information, perception, depot center, heartbeat and breathing to more complex areas such as sex drive and memory mood. The brain consists of two hemispheres connected to each other by corpus callosum (Noyan 1993). When the brain is cut, two different regions, the gray and white matter, are striking. Gray matter has nerve cells, dendrites, axon endings, unmyelinated axons and neuroglia, while white matter forms myelinated nerve extensions and is involved in nerve conduction (Wen and Chklovskii, 2005). The ratio of gray and white matter is of great importance in the search for chronic diseases affecting the central nervous system such as multiple sclerosis and schizophrenia (Sastre-Garriga et al. 2005, Fornito et al. 2009).

The general and cross-sectional anatomy of the brain has been studied in cow (Getty 1975a, Nickel et al. 1975), horse (Getty 1975a, Nickel et al. 1975), sheep (Getty 1975a), donkey (Oto and Haziroglu 2009), goat (Getty 1975a), dog (Miller 1964, Getty 1975b), pig (Getty 1975b) and cat (Getty 1975b). Imaging methods such as magnetic resonance imaging (MRI) or diffusion tensor imaging (DTI) or macroscopic (Bush and Allman, 2003) and microscopic sectioning methods are used in morphometric examinations (Bolat et al. 2012). In the literature search of information on brain volume, gray and white matter volumes and proportional values in cattle was observed to be very limited.

While an interested structure can be determined by the water immersion method, this method is not possible in complex and intertwined biological structures (Cotter et al. 1999). The Cavalieri's principle has been developed to remove this problem from the biological structures and has become a frequently used method in stereology (Bjugn et al. 1989, Bjugn and Gundersen 1993, Turgut et al. 2007, Bolat et al. 2013, Bahar et al. 2013). In this method, the structure of interest is cut at equal intervals and the volume is estimated by calculating the area of each section (Anonymous 2017). In the area of estimation, a measurement ruler is used which is named as the point counting grid and has dots located at even intervals. In this respect, the biological structure of interest and the volumes of the underlying structures forming it are estimated in an objective manner.

In the current study, it was aimed to investigate the volume of whole brain, gray and white matter in cattle by the Cavalieri's principle and the possible relationship between brain weight and volume.

## MATERIALS and METHODS

Six fresh brains of Holstein-Friesian breed healthy male animals (17-20 months old) belonging to Kırıkkale region were used. The data of animals were obtained from breeders such as age, gender and race. Animals were killed in slaughterhouse and then the crania were opened properly and the brains were removed. Fresh weights of the brains were measured using digital weighing. Brains were fixed by immersion method in 10% formolin solution for 3 weeks before measurements of gray and white matter volumes. At the end of this period, the brains were serially cut using a salami slicer machine (Elta GmbH, Roedermark, Germany) with a mean thickness of 8.25 mm from rostral to caudal end and at least 10 sections obtained from each brain. Averages of 11 sections were gained from the brains. The obtained sections were placed on a flat surface according to the section line, and photographs of all sections were taken with a digital camera (Nikon, Japan) along with the millimeter paper (Figure 1). By using the millimeter paper on the photographs, the actual measurements of the brains were introduced to the ImageJ program. With the aid of the grid function of ImageJ program, point counting grid were randomly superimposed on the sections and the points on gray and white matter were counted and averages of 3 different count results were obtained. (Figure 2). The distance between the two points on the grid was determined to be 2.18 mm (Figure 2) in order to reach a reliable coefficient of error value (CE) (Gundersen 1999). In point counting grid, an average of 220 points for each animal's brains, 107 for the gray matter and 105 for the white matter were counted. The volumes are estimated as  $V = t \times a(p) \times \Sigma p$  formula. In this formula,  $V$  is the volume of the structure concerned,  $t$  is the section thickness,  $a(p)$  is the area of the one point on the grid, and  $\Sigma p$  is the sum of the points on the structure of interest. The ratio of brain weight to brain volume was determined using the brain weight / brain volume formula.

### Statistical Analysis

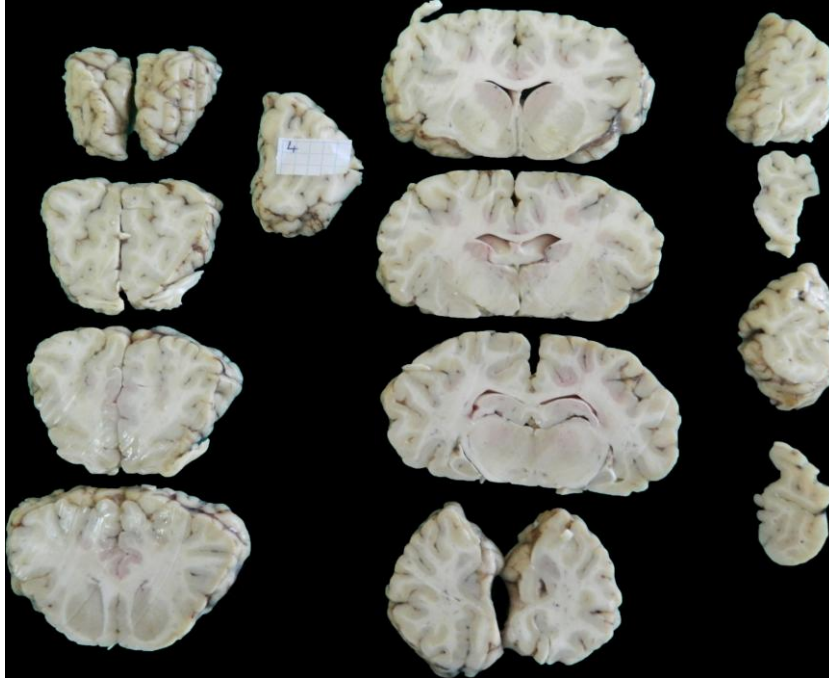
Descriptive statistic was performed using GraphPad Prism version 6.00 for Windows, GraphPad Software, La Jolla California USA, www.graphpad.com.

## RESULTS

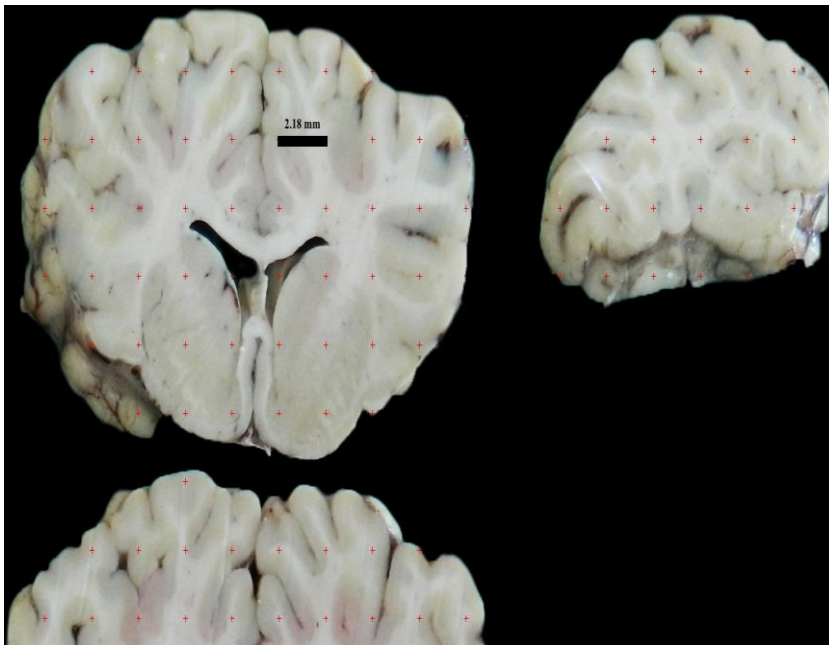
The weight data of the brains used in the study and the gray and white matter volumes determined using the Cavalieri's principle and all the brain volume ratios of these values are given in Table 1.

As a result of the estimation made, it was determined that brain volume of group consisted of 17-20 months old was  $348.00 \pm 50.48 \text{ cm}^3$ ,  $175.70 \pm 11.11 \text{ cm}^3$  in gray matter volume and  $172.30 \pm 42.90 \text{ cm}^3$  in white matter volume (Table 1). When the ratio of the gray matter and white matter volumes to the whole brain volume is

determined, it was seen that these ratios are 50.98% and 49.02% respectively. There was a 1: 1 ratio between gray matter and white matter contained in the brain. The ratio of brain weight to brain volume is 1. 1 gr. brain tissue was found to be equal to the volume of  $1.01 \text{ cm}^3$ .



**Figure 1:** The view of obtained serial sections of the brain.



**Figure 2:** Application of point counting grid on serial sections.

**Table 1.** Morphometric data of the brains used in the study.  
**Tablo 1.** Çalışmada kullanılan beyinlere ait morfolometrik veriler.

Animal no, age (month)wei ght (kg)	Brain weight (gr)	Brain volume (cm <sup>3</sup> )	Gray matter volume (cm <sup>3</sup> )	White matter volume (cm <sup>3</sup> )	Gray matter ratio (%)	White matter ratio (%)	CE value	
							Gray matter	White matter
1, 18, 440	360	318.96	181.34	137.62	56.85	43.15	0.06	0.05
2, 17, 420	325	316.25	162.36	153.90	51.34	48.66	0.07	0.06
3, 17, 415	296	330.92	164.61	166.31	49.74	50.26	0.06	0.04
4, 18, 430	330	337.47	179.88	157.59	53.30	46.70	0.04	0.05
5, 20, 505	395	449.56	191.96	257.59	42.70	57.30	0.03	0.04
6, 18, 435	350	334.88	174.07	160.81	51.98	48.02	0.04	0.06
Mean (± SD)	342,7± 33,89	348,0± 50,48	175,7± 11,11	172,3± 42,90	53,42± 3,06	50,99± 4,713	49,02± 4,713	0,050± 0,009
CV	0.099	0.140	0.063	0.249	0.092	0.096		

## DISCUSSION

Brain volume and gray and white matter volumes in the brain are used in the diagnosis and follow-up of diseases such as schizophrenia and multiple sclerosis in human medicine (Sastre-Garriga et al. 2005, Fornito et al. 2009). In studies conducted on domestic mammals, the volume of the sheep brain was determined to be  $37.74 \pm 0.78 \text{ cm}^3$ , the gray matter volume was  $28.78 \pm 0.55 \text{ cm}^3$ , and the volume of white matter in male sheep was  $10.25 \pm 0.52 \text{ cm}^3$  (Sahin et al. 2001). In the study performed on horse, it was determined that gray matter was  $184.7 \text{ cm}^3$ , white matter was  $168.6 \text{ cm}^3$  and total brain volume was  $363.2 \text{ cm}^3$  (Bahar and Dayan 2014). Mayhew and colleagues reported that the weight of ox brain was 248.8 gr. and volume of the ox brain was  $235.5 \text{ cm}^3$  (Mayhew et al. 1990). In this study, brain weight of ox was  $342,7 \pm 33,89$  and brain volume of ox was determined as  $348.00 \pm 50.48 \text{ cm}^3$ , gray matter volume was  $175.70 \pm 11.11 \text{ cm}^3$  and white matter volume was  $172.30 \pm 42.90 \text{ cm}^3$ . There is a difference between the results of Mayhew et al. (1990) and our results. It is thought that this difference may be caused by strain difference. It was determined that the ox brain and the horse brain showed similar features as volume and gray / white matter ratio. However, when gray and white matter levels are observed, which are about 10 times larger than the volume of the sheep brain, it is seen that both values are close to each other, unlike sheep. In the study conducted in the human, it is stated that the volume ratios of gray and white matter are close to each other when the

transmission routes of cerebrospinal fluid are taken into account (Taki et al. 2011). In the light of these results, it is necessary to investigate the gray and white matter content of mammals, especially the carnivorous and herbivorous brains, and whether their feeding habits have any effect on this.

**Conclusions:** The ratio of gray and white matter in the brain of the ox is similar to that of the gray and white matter in the human brain, but that the sheep and horse are different. The results of this study could shed light on future morphometric studies on gender and aging in the ox brain and the findings are also thought to be the basis of imaging techniques such as Magnetic Resonance Imaging (MRI) and Computed Tomography (CT).

## Acknowledgements

The author thanked Lügen Orgun for her kindly help.

## REFERENCES

- Anonymous2017.** <http://www.stereology.info/cavalieri-estimator/>; Accession date: 11.10.2017.
- Bjugn R, Boe R, Haugland HK.** A stereological study of the ependyma of the mouse spinal cord with a comparative note on the choroid plexus ependyma. *J Anat.* 1989; 166: 171-178.
- Bjugn R, Gundersen HJ.** Estimate of the total number of neurons and glial and endothelial cells in the rat spinal cord by means of the

- optical disector. *J Comp Neurol.* 1993; 328: 406-414.
- Bolat D, Bahar S, Selcuk M, Tipirdamaz S.** Morphometric investigations fresh and fixed rabbit kidney, *Eurasian J Vet Sci.* 2011; 27: 149-54.
- Bolat D, Bahar S, Sur E, Selcuk M, Tipirdamaz S.** Selective gray and white matter staining of the horse spinal cord, *Kafkas Univ Vet Fak Derg.* 2012; 18: 249-54.
- Bolat D, Bahar S, Tipirdamaz S, Selcuk M.** Comparison of the morphometric features of the left and right Horse kidneys: A stereological approach, *Anat Histol Embryol.* 2013; Doi: 10.1111/ahe.12036.
- Bush EC, Allman JM.** The scaling of white matter to gray matter in cerebellum and neocortex, *Brain Behav Evol.* 2003; 61: 1-5.
- Cotter D, Miszkiel K, Al-Sarraj S, Wilkinson ID, Paley M, Harrison MJ, Hall-Craggs MA, Everall IP.** The assessment of postmortem brain volume; a comparison of stereological and planimetric methodologies, *Neuroradiology.* 1999; 41: 493-6.
- Fornito A, Yucel M, Patti J, Wood SJ, Pantelis C.** Mapping grey matter reductions in schizophrenia: an anatomical likelihood estimation analysis of voxel-based morphometry studies, *Schizophr Res.* 2009; 108; 104-13.
- Getty R.** 1975a. *Sissons and Grossmann's The Anatomy of the Domestic Animals*, 5th edition, volume 1, Philadelphia, W.B. Saunders Company, USA, pp: 633-650.
- Getty R.** 1975b *Sissons and Grossmann's The Anatomy of the Domestic Animals*, 5th edition, volume 2, Philadelphia, W.B. Saunders Company, USA, pp: 1671-1686.
- Mayhew TM, Mwamengele GL, Dantzer V.** Comparative morphometry of the mammalian brain: estimates of cerebral volumes and cortical surface areas obtained from macroscopic slices. *J Anat.* 1990; 172: 191-200.
- Miller ME.** 1964. *Anatomy of The Dog*, 3<sup>th</sup>. edition, Philadelphia, Saunders Company, USA.
- Nickel R, Schummer A, Seiferle E.** 1975. *Lehrbuch Der Anatomie Der Haustiere.* Band IV. Verlag Paul Parey, Berlin, Germany.
- Noyan A.** 1993, *Yaşamda ve Hekimlikte Fizyoloji*, 8<sup>th</sup>. edition, Meteksan.
- Oto C, Hazirolu RM.** Macro-anatomical investigation of encephalon in donkey. *Ankara Univ Vet Fak Derg.* 2009; 56: 159-164.
- Sahin B, Aslan H, Unal B, Canan S, Bilgic S, Kaplan S, Tumkaya L.** Brain volumes of the lamb, rat and bird do not show hemispheric asymmetry: a stereological study, *Image Anal Stereol.* 2001; 20: 9-13.
- Sastre-Garriga J, Ingle GT, Chard DT, Cercignani M, Ramio-Torrenta L, Miller DH, Thompson AJ.** Grey and white matter volume changes in early primary progressive multiple sclerosis: a longitudinal study, *Brain.* 2005; 128: 1454-60.
- Taki Y, Thyreau B, Kinomura S, Sato K, Goto R, Kawashima R, Fukuda H.** Correlations among brain gray matter volumes, age, gender, and hemisphere in healthy individuals, *PLoS One* 2011; Doi: 10.1371/journal.pone.0022734.
- Wen Q, Chklovskii DB.** Segregation of the brain into gray and white matter: a design minimizing conduction delays, *PLoS Comput Biol.* 2005; Doi: 10.1371/journal.pcbi.0010078.