



# Reverse Shoulder Arthroplasty in the Treatment of Cuff Tear Arthropathy: Systematic Review

## Omuz Rotator Manşet Yırtığı Artropatisi Tedavisinde Ters Omuz Artroplastisi: Sistemik Derleme

Murat Aşçı

Bilecik Şeyh Edebali University, School of Medicine, Department of Orthopedics and Traumatology, Bilecik, Turkey

### Abstract

**Aim:** In our study, we aimed to examine the results and complications of reverse shoulder prosthesis (RSA) applied after rotator cuff tear arthropathy (CTA) in the light of the current literature.

**Material and Method:** The literature search was conducted simultaneously on 1 April 2024 in the Medline, Cochrane, EMBASE, Google Scholar and Ovid databases using the "reverse total shoulder arthroplasty", "reverse total shoulder prosthesis", "cuff tear arthropathy", "outcomes" and "complications" keywords. Only clinical review published in English in peer-reviewed journals was evaluated. The comparison between preoperative and postoperative clinical scores, as well as range of motion (ROM), was performed using the Wilcoxon–Mann–Whitney test. P values lower than 0.05 were considered statistically significant.

**Results:** 12 articles were included in our study. When comparing the results of the pre- and postoperative examinations, a statistically significant improvement in the range of motion and the functional score was found. It was found that various complications occurred in 21.1% of patients. The most common complication is scapular notching, which occurred in 13.8% of patients. Revision surgery was required in 1.57% of patients. The most common cause of revision was a periprosthetic joint infection.

**Conclusion:** In CTA patients, RSA can achieve both freedom from pain in the shoulder joint and an increase in function. Despite positive results, complications of varying degrees of severity can occur in around one fifth of patients. The lack of Level I studies limits a true understanding of the possibilities and limitations of RSA in the treatment of CTA patients.

**Keywords:** Reverse total shoulder arthroplasty, cuff tear arthropathy, outcomes, complications

### Öz

**Amaç:** Çalışmamızda güncel literatür eşliğinde rotator manşet yırtığı artropatisi (CTA) sonrasında uygulanan ters omuz protezinin (RSA) sonuçlarını ve komplikasyonlarını incelemeyi amaçladık.

**Gereç ve Yöntem:** Yöntemler Literatür taraması 1 Nisan 2024 tarihinde Medline, Cochrane, EMBASE, Google Scholar ve Ovid veritabanlarında "ters total omuz artroplastisi", "ters total omuz protezi", "manşet yırtığı artropatisi", "sonuçlar" ve "komplikasyonlar" anahtar kelimeleri kullanılarak eş zamanlı olarak yapılmıştır. Yalnızca hakemli dergilerde İngilizce olarak yayınlanan klinik araştırmalar değerlendirildi. Preoperatif ve postoperatif klinik skorların yanı sıra eklem hareket açıklığı (ROM) arasındaki karşılaştırma Wilcoxon-Mann-Whitney testi kullanılarak yapıldı. 0,05'in altındaki P değerleri istatistiksel olarak anlamlı kabul edildi

**Bulgular:** Çalışmamıza 12 makale dahil edildi. Ameliyat öncesi ve ameliyat sonrasında yapılan muayenelerde elde edilen sonuçlar karşılaştırıldığında eklem hareket açıklıklarında ve fonksiyonel skorlamalarda istatistiksel olarak anlamlı bir iyileşme olduğu görüldü. Hastaların %21.1'inde çeşitli komplikasyonlar geliştiği gözlemlendi. Komplikasyonların en sık görüleni hastaların %13,8'inde meydana gelen skapular çentiklenmedir. Hastaların %1.57'sinde revizyon ameliyatı gerekti. Revizyonun sık nedeninin periprostetik eklem enfeksiyonu olduğu görüldü.

**Sonuç:** CTA hastalarında RSA ile hem ağrısız omuz eklemi hem de fonksiyonel olarak artış sağlanabilmektedir. Olumlu sonuçlarına karşın hastaların yaklaşık beşte birinde çeşitli şiddetlerde komplikasyon görülebilmektedir. Level I çalışmalarının olmayışı, CTA hastalarının tedavisinde RSA'nın potansiyelleri ve sınırlamalarının gerçek anlamda anlaşılmasını sınırlamaktadır.

**Anahtar Kelimeler:** Ters omuz artroplastisi, manşet yırtığı artropatisi, sonuçlar, komplikasyonlar



## INTRODUCTION

Rotator cuff tear arthropathy (CTA) was first defined by Neer et al. in 1983 as a set of symptoms including proximal migration of the humeral head, degeneration in the glenohumeral joint and rotator cuff failure.<sup>[1]</sup>

After the identification of CTA, treatment methods against this challenging problem continue to develop over the years.<sup>[2]</sup> Total shoulder arthroplasty (TSA) was initially used in CTA treatment but was abandoned due to high rates of implant failure, instability and poor functional outcomes.<sup>[3,4]</sup> Nowadays, the presence of CTA is considered a contraindication for TSA.<sup>[2,5,6]</sup> After the poor results observed in the early period following the use of TSA in CTA treatment, hemiarthroplasty began to be used, but the need to develop new implants persisted due to instability, bone loss and failure to achieve the desired results in joint range of motion.<sup>[7,8]</sup>

Reverse shoulder arthroplasty (RSA), developed by Grammont, is now used in the treatment of CTA to improve patients' quality of life, allow pain-free range of motion (ROM) and improve shoulder function and strength.<sup>[9,10]</sup> This method increases the stability and range of motion of the shoulder by tensing the deltoid muscle more by distalising and medialising the joint rotation centre.<sup>[10-12]</sup> Following the introduction of RSA in the treatment of CTA, its use has gradually increased after promising early results in functional outcomes and patient pain levels.<sup>[13-16]</sup> Despite positive clinical results, as with all shoulder prosthesis surgery, patients undergoing RSA may experience various complications such as instability, periprosthetic fractures, infections and component loosening.<sup>[17,18]</sup>

The aim of this review is to evaluate the clinical and functional outcomes of RSA in CTA patients as well as the complication and revision rates.

## MATERIAL AND METHOD

We conducted a systematic review of the literature according to the PRISMA guidelines. Two independent reviewers (M.G. and U.S.) conducted a blind search. The literature search was conducted simultaneously on 1 April 2024 in the Medline, Cochrane, EMBASE, Google Scholar and Ovid databases using the "reverse total shoulder arthroplasty", "reverse total shoulder prosthesis", "cuff tear arthropathy", "outcomes" and "complications" keywords. Only clinical review published in English in peer-reviewed journals was evaluated.

First, the abstracts of the publications retrieved from the databases were reviewed. Publications without abstracts were excluded from the study. The selected publications were then analysed in detail using the inclusion and exclusion criteria listed in **Table 1**. All clinical studies reporting on the outcomes and complications of RSA administered for the treatment of CTA were included.

**Table 1: Inclusion and exclusion criteria**

Databases screened	Medline, Cochrane, EMBASE, Google Scholar and Ovid
Date of source	April 1, 2024
Language accepted	English
Key words matched	"Reverse total shoulder arthroplasty", "Reverse total shoulder prosthesis", "Cuff tear arthropathy", "Outcomes" and "Complications"
Type of articles excluded	Reviews, case reports, animal studies, cadavers studies, biomechanical studies, tumoral studies
Inclusion criteria	RSA implanted as primary surgery; description of the surgical approach; description of the version of the humeral stem of RSA; preoperative and postoperative information on clinical condition of the patients (using outcomes scores, measuring ROM); description of the follow-up period; detailed information of the complications and their management
Exclusion criteria	Studies on RSA for revision surgery of failed RC repair; failed RSA, RSA in fractures, RSA in instability or failed RSA; follow-up period shorter than 12 months; no information on surgical intervention, complications, clinical outcomes, radiographic outcomes and statistical analysis of the relative results

## Statistical Analysis

All the statistical analyses were performed using SPSS for Mac (IBM SPSS Statistics version 22.0; Chicago, Illinois). The comparison between preoperative and postoperative clinical scores as well as the degrees of anterior elevation, abduction, external rotation and internal rotation ROM was carried out using the Wilcoxon–Mann–Whitney test. P values lower than 0.05 were considered statistically significant.

In all studies, P values <0.5 were considered statistically significant.

## RESULTS

Forty-six articles were eligible for the present study.<sup>[2,13,19-62]</sup> 12 studies that met the inclusion and exclusion criteria were included in our study.<sup>[19-30]</sup> (**Figure 1**). The exclusion reasons of the other 17 articles are explained in **Table 2**.

It was noted that there were no Level I studies among the included studies. There were two Level IV studies<sup>[21,26]</sup> nine Level III studies<sup>[19,20,22,24,25,27-30]</sup> and only one prospective Level II study.<sup>[23]</sup>

## Demographic Data

In the 12 articles we reviewed in our study, 634 shoulders from a total of 623 patients underwent surgery for CTA. Considering the gender distribution, we found that 437 patients were female (70.2%) and 186 patients were male (29.8%). The male to female ratio was 0.42. The involvement of the dominant limb was investigated in five studies, and in these studies 137 of the 193 shoulders operated on were found to be the dominant side.<sup>[19,20,22,23,25]</sup>

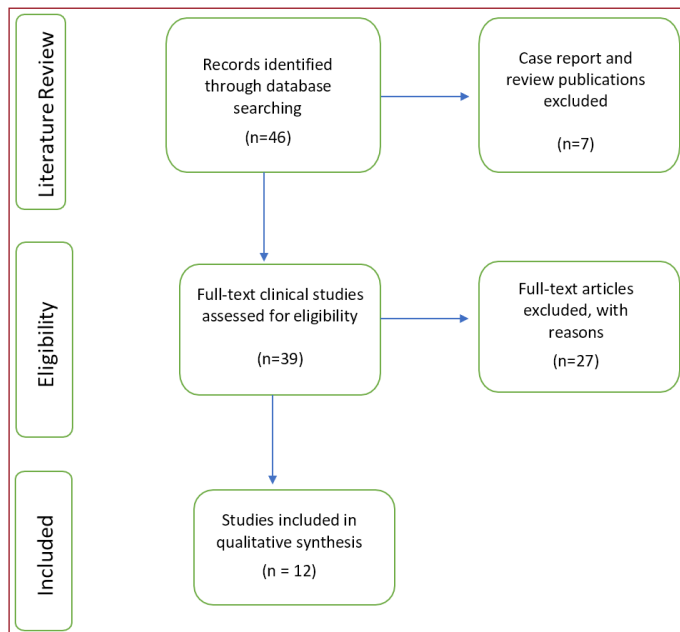


Figure 1

Table 2: Reasons of exclusion of the studies	
Reference	Reason of exclusion
Paszycnyek <sup>31</sup>	The study includes includes fractures
Baram <sup>32</sup>	The study not reports functional outcomes and information on surgical approach;
Lindbloom <sup>34</sup>	The study includes includes fractures
Cabarcas <sup>35</sup>	The study not describes the surgical technique
Waterman <sup>36</sup>	The study included patients who underwent revision arthroplasty.
Silva <sup>38</sup>	The study includes fracture and tendon transfer associated with RTSA.
Testa <sup>39</sup>	The study includes rheumatoid arthritis.
Freislederer <sup>41</sup>	The study not evaluates clinical outcomes
İlyas <sup>42</sup>	The study not describes the surgical technique, ROM and clinical outcomes
İlyas <sup>43</sup>	The study not describes the surgical technique and ROM
Bacle <sup>44</sup>	The study not evaluates ROM
Tornberg <sup>45</sup>	The study not describes the surgical technique, ROM and clinical outcomes
DeLaSelle <sup>46</sup>	The study not evaluates ROM
Stenson <sup>47</sup>	The study not evaluates ROM
Imiolczyk <sup>48</sup>	The study not evaluates ROM
Yoon <sup>50</sup>	The study not evaluates clinical outcomes
Huber <sup>51</sup>	The study not describes the surgical technique and ROM
Kim <sup>53</sup>	The study includes rheumatoid arthritis.
Lehtimäki <sup>13</sup>	The study not describes the surgical technique, ROM and clinical outcomes
Nielsen <sup>2</sup>	The study not describes the surgical technique and ROM
Wanga <sup>54</sup>	The study not describes the surgical technique, ROM and clinical outcomes
Frankle <sup>55</sup>	The study not evaluates clinical outcomes
Ammitzboell <sup>56</sup>	The study not describes the surgical technique and ROM
Shah <sup>73</sup>	The study not describes the surgical technique and ROM, also includes revisions of previous arthroplasty
Sadoghi <sup>58</sup>	The study not evaluates clinical outcomes
Valenti <sup>59</sup>	The study not evaluates clinical outcomes
Chawla <sup>60</sup>	The study not describes the surgical technique and ROM

While the average age at the time of surgery was  $72.2 \pm 3$  years (47-95), the average follow-up time after surgery was  $25.9 \pm 8.3$  months.

### Radiological Examinations

All patients included in the study underwent standard antero-posterior (AP) radiographs of the shoulder before surgery and at the last follow-up examination. In addition to the AP radiographs of the shoulder, radiographs in the Y and Grashey views of the shoulder were also taken in 111 patients who were examined in two articles.<sup>[21-23]</sup>

In the preoperative evaluation phase, magnetic resonance imaging (MRI) was available in addition to radiographs of the shoulder in a total of 181 patients who were examined in the studies by Lee et al. and Saini et al.<sup>[25,29]</sup> It was observed that 314 patients were examined with preoperative Computed Tomography (CT) in five studies.<sup>[20,23,24,29,30]</sup>

### Surgical Approach, Implant Types and Humeral Stem Retroversion

In all patients analysed in the publications included in our study, RSA implantation was performed via the deltopectoral approach.

A single brand of implant was used in the five studies analysed. In these studies: SMR Modular Shoulder System (Systema Multiplana Randelli; Lima-LTO, San Daniele del Friuli, Italy) in 31 patients,<sup>[31]</sup> Equinnox from Exactech (Exactech, Inc., Gainesville, FL, USA) in 89 shoulders of 88 patients<sup>[20,25]</sup> 59 shoulders in 57 patients Aequalis Reverse Prostheses (Houston, TX, USA.<sup>[24]</sup> at the shoulder, Tornier Ascend Flex in 61 patients; (Tornier, Memphis, TN, USA).<sup>[27]</sup> In the studies by Barlow et al. and Nolan et al. no information was provided on implant brand and implant type.<sup>[21,26]</sup> In the other five studies, more than one brand of implant was used and the exact numbers of use were not reported in the studies.<sup>[22,23,28-30]</sup>

In the four articles that we reviewed in our study, no information was provided on the degree of retroversion of the humerus.<sup>[19,24,26,29]</sup> In the other eight studies, detailed information on retroversion of the humeral shaft was provided. Implantation of the humeral shaft was performed in 59 shoulders with a retroversion of  $10^\circ$ <sup>[23,28]</sup> and in 351 shoulders of 342 patients with a retroversion of  $20^\circ$ .<sup>[20-22,25,27,28,30]</sup>

### Rehabilitation

The rehabilitation programme applied in the postoperative phase was not specified in two studies,<sup>[23,29]</sup> and 484 shoulders of 473 patients included in the study were observed in an abduction-supported arm sling for  $3.3 \pm 0.8$  weeks. Passive exercises were started  $1.8 \pm 0.9$  days after surgery, while active range-of-motion exercises were started  $4 \pm 1.7$  weeks after surgery.

### Clinical outcome assessment

Many different scoring systems were used to assess the functional outcome of patients in the pre- and postoperative

phase: Visual Analogue Scale (VAS)<sup>[19-21,24-26,29]</sup> the American Shoulder and Elbow Surgeons Score (ASES)<sup>[21,23-25,29,30]</sup> the Constant–Murley Shoulder Score<sup>[19,21,24,25,27,28,30]</sup> the Subjective Shoulder Value (SSV)<sup>[21,27,28]</sup> the University of California Los Angeles Shoulder Score (UCLA)<sup>[19,20]</sup> the Simple Shoulder Test (SST)<sup>[23,26]</sup> the Shoulder Pain and Disability Index (SPADI)<sup>[22]</sup> and the Disability of Arm Shoulder and Hand Score (DASH).<sup>[20]</sup>

The ROM measurements of the patients were performed before and after the operation and were used to evaluate the functional results. Active forward flexion and external rotation measurements were taken and recorded in all patients. Active abduction measurements were performed in 474 shoulders of 472 patients in five studies.<sup>[19,24,25,28,30]</sup> Patient internal rotation measurements were performed in 502 shoulders of 495 patients, except in the studies by Nolan et al. and Adam et al.

A statistically significant improvement in functional results was observed in the postoperative period in all patients examined in our study (Table 3). At the same time as the improvement in functional results, a significant improvement was observed in all joint ranges of motion (Table 4).

**Table 3: Comparison between preoperative and postoperative clinical scores**

Clinical score	N shoulders	Preoperative	Postoperative	p
VAS	363	6.9±0.7	1.3±0.4	<0.005
ASES	422	30.8±15.7	75.2±23.8	<0.005
CMS	317	32.1±23.4	65.3±18.6	<0.005
SSV	174	34.4±16.3	75.9±24.1	<0.005
UCLA	52	12.9±6.3	29±11.3	<0.005

VAS visual analogue scale, ASES American shoulder and elbow surgeons score, CMS Constant–Murley shoulder score, SSV subjective shoulder value, UCLA University of California, Los Angeles shoulder score. P value: result of the Wilcoxon–Mann–Whitney test

**Table 4: Comparison between preoperative and postoperative range of motion**

Range of Motion	N shoulders	Preoperative	Postoperative	p
Forward flexion	634	72.3±30.1	132.8±16.1	<0.005
Abduction	295	52.9±19.7	106.1±37.8	<0.005
External Rotation	571	21.7±6.7	30.9±9.3	<0.005

P value: result of the Wilcoxon–Mann–Whitney test; Mean±SD

## Complications

All of the studies we analysed described complications as part of our inclusion criteria. Various complications occurred in 126 of 634 operated shoulders (19.8%). The most common complication was scapular notching, which was observed in 88 patients (13.8%). The second most common complication was acromion fracture, which was observed in 12 patients (1.8%). Revision surgery was performed in 10 (1.57%) of the patients involved in the study. Five patients underwent revision surgery due to infection, two patients due to dislocation, one patient due to failed humeral baseplate, one patient due to failed glenosphere and one patient due to loosening of the glenoid component (Table 5).

**Table 5: Complications and revision rate**

Complications	n (%)	Revision (%)
Scapular notching	88 (13.88)	0
Deep vein thrombosis	3 (0.47)	0
Hematoma	2 (0.31)	0
Infection	6 (0.94)	5 (83.3%)
Wound healing problems	3 (0.47)	0
Transitory nerve palsies	2 (0.31)	0
Humerus fracture	1 (0.15)	0
Acromion fracture	11 (1.73)	0
Coracoid process fracture	1 (0.15)	0
Glenoid fracture	1 (0.15)	0
Drill bit breakage	1 (0.15)	0
Central screw breakage	1 (0.15)	0
Failed Baseplate	1 (0.15)	1 (100%)
Metaglene loosening	3 (0.47)	1 (33%)
Failed glenosphere	1 (0.15)	1 (100%)
Dislocation	3 (0.47)	2 (66%)
Heterotopic ossification	2 (0.31)	0

## DISCUSSION

In this systematic review study, we analysed the outcomes of CTA patients treated with RSA. Due to the rather restrictive inclusion and exclusion criteria at the beginning of the study, 12 articles were included in our study.

When analysing the demographic data of the patients, it can be seen that the number of female patients is more than twice as high as that of male patients (70.2% vs. 29.8%). The mean age of patients was 72.7±3 years, and it was found that surgery was frequently performed in the seventh and eighth decades of life. Although dominant limb involvement was not assessed in all studies, the fact that 137 of 193 shoulders examined in the studies in which it was assessed had dominant limb involvement indicates that CTA negatively affects patients' daily lives.

We found that active forward flexion and external rotation were measured in the preoperative and postoperative phases and increased significantly in all articles included in our study. According to the results of the studies, active forward flexion increased from 72.3±30.1° to 132.8±16.1° and active external rotation increased from 21.7±6.7° to 30.9±9.3°. Active abduction was measured in half of the included studies, but increased approximately twofold at postoperative follow-up compared to before (52.9±19.7 vs. 106.1±37.8). The ability to internally rotate also increases in the postoperative phase. In contrast to other movements, however, it could not be statistically analysed as it was measured as the maximum vertebral height that the hand could reach.

As is well known, RSA was first developed by Grammont for the treatment of CTA.<sup>[9]</sup> Over the past 20 years, with the approval of RSA by the Food and Drug Administration (FDA), it has been used for other indications and has become

increasingly popular.<sup>[63]</sup> Our patients were evaluated using ROM, VAS, and various functional scores. When examining the results, we found that the CTA patients with RSA performed according to the technique were pain-free, had increased ROM and thus significantly increased their functional capacity.

The external rotation movement of the patients included in our study increased from  $21.7 \pm 6.7^\circ$  to  $30.9 \pm 9.3^\circ$ . However, in some publications we evaluated, it was observed that external rotation did not improve at a statistically significant level.<sup>[21,22,27]</sup> Loss of external rotation or inability to gain it sufficiently creates a limitation in the functions of the arm, especially in abduction.<sup>[10]</sup> While the deltoid muscle can provide abduction and forward flexion after RSA, it cannot have an effect on external rotation. In CTA patients treated with RSA, the external rotation movement is performed by the teres minor (TM) muscle, and this muscle may be torn and retracted like other muscles forming the posterosuperior part of the rotator cuff, especially in elderly patients.<sup>[64,65]</sup> Therefore, postoperatively in CTA patients planned to undergo RSA. It is important to carefully evaluate the TM muscle in the preoperative MRI examination to determine the external rotation function and to be prepared for muscle transfer in the presence of a retracted tear that will prevent healing.<sup>[10,66,67]</sup>

The amount of retroversion of the humeral component also affects the shoulder's ability to rotate internally and externally. Some authors have suggested a more retroverted implantation of the humeral component may increase the capacity of external rotation. Biomechanical studies have shown that implantation of the humeral stem in retroversion up to  $40^\circ$  increases external rotation without impingement.<sup>[9,12,68-70]</sup> However, it is also known that the ability to internal rotation increases with decreasing humeral retroversion.<sup>[9,12,68]</sup> In more recent studies on this topic, Rhee et al. found that implantation in  $0^\circ$  retroversion was associated with less difficulty in activities of daily living that required internal rotation.<sup>[71]</sup> Similarly, Oh et al. found that the functional scores and range of motion of patients with individualised stems were better than those implanted at  $20^\circ$  retroversion.<sup>[72]</sup> Jassim et al. concluded in a systematic review study that although better external rotation and forward flexion can be achieved after implantation at a retroversion of  $20^\circ$  or more, internal rotation is limited.<sup>[70]</sup>

The incidence of complications is also increasing due to the increase in RSA used for various indications. It is reported that complications can occur in around a quarter of patients.<sup>[44,73-75]</sup> Scapular notch is the most common complication after RSA, it is specific to RSA and has no negative impact on clinical outcomes.<sup>[76,77]</sup> Studies analysing the results of RSA report that it can develop between 10% and 96%.<sup>[76,78,79]</sup> In our study, scapular scarring occurred in 88 of 634 shoulders and was the most common complication. In a study by Zumstein et al, one of the first studies on this

topic, the most common reason for revision was instability, but over the years, as prosthesis designs have evolved and surgical experience has increased, instability has become less common and infection has become the most common complication.<sup>[74]</sup> However, the complications and reasons for revision vary over the years. A total of ten patients underwent revision, and the most common cause was infection, similar to the literature.

The strengths of our study are that it was conducted according to the PRISMA criteria and that it standardised the selection of articles, the data extraction and the evaluation of the results. Another strength is that it was blindly analysed by two independent orthopaedic and traumatology surgeons who were not involved in the study. Finally, the fact that only patients with a follow-up of at least 12 months who underwent RSA due to a CTA were included strengthens our study.

The most important limiting aspect of our study is the lack of high-quality clinical studies due to the absence of Level I studies. Secondly, the fact that only one of the 12 articles included in our study was prospectively designed increases the risk of bias. Another weakness is the inclusion of studies reporting the results of RSA performed both as primary surgery and as revision surgery after cuff repair failure. Finally; 634 shoulders of 623 patients were examined in 12 studies, and it is obvious that larger patient series will be needed for more definitive results.

## CONCLUSION

RSA continues to be used successfully as a safe and effective treatment method for CTA. After the procedure, there is not only a significant reduction in patients' pain levels, but also a significant increase in outcomes in terms of joint range of motion, activities of daily living and functional scores. RSA was developed by Grammont in 1985 for the treatment of CTA and is now used for many indications. Its frequency is increasing, but it should not be forgotten that intra- and perioperative complications can occur, which are associated with high revision rates.

## ETHICAL DECLARATIONS

**Referee Evaluation Process:** Externally peer-reviewed.

**Conflict of Interest Statement:** The authors have no conflicts of interest to declare.

**Financial Disclosure:** The authors declared that this study has received no financial support.

**Author Contributions:** All of the authors declare that they have all participated in the design, execution, and analysis of the paper, and that they have approved the final version.

**Acknowledgement:** I would like to thank Mete Gedikbaş, Ass. Prof. and Utkan Sobay M.D. for their efforts in researching the literature for this study.

## REFERENCES

1. Neer 2nd C, Craig E, Fukuda H. Cuff-tear arthropathy. *J Bone Joint Surgery Am.* 1983;65(9):1232-44.
2. Nielsen KP, Amundsen A, Olsen BS, Rasmussen JV. Good long-term patient-reported outcome after shoulder arthroplasty for cuff tear arthropathy. *JSES Int.* 2022;6(1):40-3.
3. Nwakama AC, Cofield RH, Kavanagh BF, Loehr J. Semiconstrained total shoulder arthroplasty for glenohumeral arthritis and massive rotator cuff tearing. *J Shoulder Elbow Surg.* 2000;9(4):302-7.
4. Franklin JL, Barrett WP, Jackins SE, Matsen III FA. Glenoid loosening in total shoulder arthroplasty: association with rotator cuff deficiency. *J Arthroplasty.* 1988;3(1):39-46.
5. Nam D, Maak TG, Raphael BS, Kepler CK, Cross MB, Warren RF. Rotator cuff tear arthropathy: evaluation, diagnosis, and treatment: AAOS exhibit selection. *J Bone Joint Surgery Am.* 2012;94(6):e34.
6. Feeley BT, Gallo RA, Craig EV. Cuff tear arthropathy: current trends in diagnosis and surgical management. *J Shoulder Elbow Surg.* 2009;18(3):484-94.
7. Zuckerman JD, Scott AJ, Gallagher MA. Hemiarthroplasty for cuff tear arthropathy. *J Shoulder Elbow Surg.* 2000;9(3):169-72.
8. Sanchez-Sotelo J, Torchia ME, O'Driscoll SW. Complex distal humeral fractures: internal fixation with a principle-based parallel-plate technique. *J Bone Joint Surgery Am.* 2007;89(5):961-9.
9. Grammont P, Trouilloud P, Laffay J, Deries X. Etude et réalisation d'une nouvelle prothèse d'épaule. *Rhumatologie.* 1987;39(10):407-18.
10. Petrillo S, Longo U, Papalia R, Denaro V. Reverse shoulder arthroplasty for massive irreparable rotator cuff tears and cuff tear arthropathy: a systematic review. *Musculoskelet Surg.* 2017;101:105-12.
11. Juhan T, Stone M, Jalali O, et al. Irreparable rotator cuff tears: Current treatment options. *Orthop Rev.* 2019;11(3).
12. Grammont P, Baulot E. Delta shoulder prosthesis for rotator cuff rupture. *Orthopedics.* 1993;16(1):65-8.
13. Lehtimäki K, Rasmussen JV, Mokka J, et al. Risk and risk factors for revision after primary reverse shoulder arthroplasty for cuff tear arthropathy and osteoarthritis: a Nordic Arthroplasty Register Association study. *J Shoulder Elbow Surg.* 2018;27(9):1596-601.
14. Boulahia A, Edwards TB, Walch G, Baratta RV. Early results of a reverse design prosthesis in the treatment of arthritis of the shoulder in elderly patients with a large rotator cuff tear. *Orthopedics.* 2002;25(2):129-33.
15. Kim SH, Wise BL, Zhang Y, Szabo RM. Increasing incidence of shoulder arthroplasty in the United States. *J Bone Joint Surgery Am.* 2011;93(24):2249-54.
16. Rittmeister M, Kerschbaumer F. Grammont reverse total shoulder arthroplasty in patients with rheumatoid arthritis and nonreconstructible rotator cuff lesions. *J Shoulder Elbow Surg.* 2001;10(1):17-22.
17. Bohsali KI, Bois AJ, Wirth MA. Complications of shoulder arthroplasty. *J Bone Joint Surgery Am.* 2017;99(3):256-69.
18. Boileau P. Complications and revision of reverse total shoulder arthroplasty. *Orthop Traumatol Surg Res.* 2016;102(1):33-43.
19. Beltrame A, Di Benedetto P, Salviato D, et al. The SMR reverse shoulder arthroplasty in rotator cuff arthropathy management. *Acta Biomed.* 2017;88(Suppl 4):81.
20. Nascimento AT, Claudio GK, Rocha PB. Artroplastia reversa de ombro: Resultados funcionais na artropatia do manguito. *Rev Bras Ortop.* 2020;55:106-11.
21. Nolan BM, Ankersen E, Wiater MJ. Reverse total shoulder arthroplasty improves function in cuff tear arthropathy. *Clin Orthop Relat Res.* 2011;469(9):2476-82.
22. Leung B, Horodyski M, Struk AM, Wright TW. Functional outcome of hemiarthroplasty compared with reverse total shoulder arthroplasty in the treatment of rotator cuff tear arthropathy. *J Shoulder Elbow Surg.* 2012;21(3):319-23.
23. Jobin CM, Brown GD, Bahu MJ, et al. Reverse total shoulder arthroplasty for cuff tear arthropathy: the clinical effect of deltoid lengthening and center of rotation medialization. *J Shoulder Elbow Surg.* 2012;21(10):1269-77.
24. Franceschetti E, Ranieri R, de Sanctis EG, Palumbo A, Franceschi F. Clinical results of bony increased-offset reverse shoulder arthroplasty (BIO-RSA) associated with an onlay 145° curved stem in patients with cuff tear arthropathy: a comparative study. *J Shoulder Elbow Surg.* 2020;29(1):58-67.
25. Lee JH, Chun YM, Kim DS, Lee DH, Shin SJ. Clinical comparison of humeral-lateralized reverse total shoulder arthroplasty between patients with irreparable rotator cuff tear and patients with cuff tear arthropathy. *JSES Int.* 2020;4(3):694-700.
26. Barlow JD, Jamgochian G, Wells Z, et al. Reverse shoulder arthroplasty is superior to hemiarthroplasty for cuff tear arthropathy with preserved motion. *Arch Bone Jt Surg.* 2020;8(1):75.
27. Adam MF, Lädermann A, Denard PJ, Lacerda F, Collin P. Preoperative Diagnosis and Rotator Cuff Status Impact Functional Internal Rotation Following Reverse Shoulder Arthroplasty. *J Shoulder Elbow Surg.* 2024;33(7):1570-6.
28. Holschen M, Kiriazis A, Bockmann B, Schulte TL, Witt KA, Steinbeck J. Treating cuff tear arthropathy by reverse total shoulder arthroplasty: do the inclination of the humeral component and the lateral offset of the glenosphere influence the clinical and the radiological outcome? *Eur J Orthop Surg Traumatol.* 2022;32(2):307-15.
29. Saini SS, Pettit R, Puzitiello RN, et al. Clinical outcomes after reverse total shoulder arthroplasty in patients with primary glenohumeral osteoarthritis compared with rotator cuff tear arthropathy: does preoperative diagnosis make a difference? *J Am Acad Orthop Surg.* 2022;30(3):415-22.
30. Uçan V, Pulatkan A, Sarıkaş M, Kapıcıoğlu M, Bilsel K. Does correction of reverse shoulder arthroplasty angle improve clinical outcomes in cuff tear arthropathy? *Acta Orthop Traumatol Turc.* 2021;55:466-72.
31. Paszicsnyek A, Kriechling P, Razaiean S, Ernstbrunner L, Wieser K, Borbas P. Reverse total shoulder arthroplasty for proximal humeral fractures and sequelae compared to non-fracture indications: a matched cohort analysis of outcome and complications. *J Clin Med.* 2023;12(6):2097.
32. Baram A, Ammitzboell M, Brorson S, Olsen BS, Amundsen A, Rasmussen JV. What factors are associated with revision or worse patient-reported outcome after reverse shoulder arthroplasty for cuff-tear arthropathy? A study from the Danish shoulder arthroplasty registry. *Clin Orthop Relat Res.* 2020;478(5):1089-97.
33. Coscia AC, Matar RN, Espinal EE, Shah NS, Grawe BM. Does preoperative diagnosis impact patient outcomes following reverse total shoulder arthroplasty? A systematic review. *J Shoulder Elbow Surg.* 2021;30(6):1458-70.
34. Lindbloom BJ, Christmas KN, Downes K, et al. Is there a relationship between preoperative diagnosis and clinical outcomes in reverse shoulder arthroplasty? An experience in 699 shoulders. *J Shoulder Elbow Surg.* 2019;28(6):110-7.
35. Cabarcas BC, Gowd AK, Liu JN, et al. Establishing maximum medical improvement following reverse total shoulder arthroplasty for rotator cuff deficiency. *J Shoulder Elbow Surg.* 2018;27(9):1721-31.
36. Waterman BR, Dean RS, Naylor AJ, et al. Comparative clinical outcomes of reverse total shoulder arthroplasty for primary cuff tear arthropathy versus severe glenohumeral osteoarthritis with intact rotator cuff: a matched-cohort analysis. *J Am Acad Orthop Surg.* 2020;28(23):1042-8.
37. Rugg CM, Gallo RA, Craig EV, Feeley BT. The pathogenesis and management of cuff tear arthropathy. *J Shoulder Elbow Surg.* 2018;27(12):2271-83.
38. Silva CM, Teixeira GFD, de Brito GCC, Lacerda MA, Rocha FA. Outcome of reverse shoulder arthroplasty secondary to rotator cuff arthropathy in a low-income population. *BMC Musculoskelet Disord.* 2024;25(1):13.
39. Testa EJ, Glass E, Ames A, et al. Indication matters: effect of indication on clinical outcome following reverse total shoulder arthroplasty—a multicenter study. *J Shoulder Elbow Surg.* Published online 2023.
40. Familiari F, Rojas J, Doral MN, Huri G, McFarland EG. Reverse total shoulder arthroplasty. *EFORT open rev.* 2018;3(2):58-69.
41. Freislederer F, Moroder P, Audigé L, et al. Analysis of three different reverse shoulder arthroplasty designs for cuff tear arthropathy—the combination of lateralization and distalization provides best mobility. *BMC Musculoskelet Disord.* 2024;25(1):204.

42. İlyas G, Egeli E, İpci FB, Gokalp O. The effect of cuff arthropathy stage on sleep disturbance and kinesiophobia in reverse shoulder arthroplasty patients. *BMC Musculoskelet Disord.* 2024;25(1):231.
43. İlyas G, Egeli E, İlyas G, Egeli Sr E. Does Reverse Shoulder Arthroplasty Improve Function and Quality of Life in Patients With Rotator Cuff Tear Arthropathy? *Cureus.* 2023;15(8).
44. Bacle G, Nové-Josserand L, Garaud P, Walch G. Long-term outcomes of reverse total shoulder arthroplasty: a follow-up of a previous study. *J Bone Joint Surg Am.* 2017;99(6):454-61.
45. Tornberg H, Kleinbart EP, Martin K, et al. Disparities in arthroplasty utilization for rotator cuff tear arthropathy. *J Shoulder Elbow Surg.* 2023;32(10):1981-7.
46. De La Selle H, Lascar T, Clappaz P, et al. Reverse Shoulder Arthroplasty for Patients with Massive Rotator Cuff Tears or Cuff Tear Arthropathies at a Minimum Follow-up of 7 Years. *J Shoulder Elbow Surg.* 2023;7:24715492231157659.
47. Stenson JF, Mills ZD, Dasari SP, Whitson AJ, Hsu JE, Matsen III FA. Managing rotator cuff tear arthropathy: a role for cuff tear arthropathy hemiarthroplasty as well as reverse total shoulder arthroplasty. *J Shoulder Elbow Surg.* 2024;33(3):162-74.
48. Imiolczyk JP, Audigé L, Harzbecker V, Moroder P, Scheibel M. Metallic humeral and glenoid lateralized implants in reverse shoulder arthroplasty for cuff tear arthropathy and primary osteoarthritis. *JSES Int.* 2022;6(2):221-8.
49. Skedros JG, Smith JS, Langston TD, Adondakis MG. Reverse Total Shoulder Arthroplasty as Treatment for Rotator Cuff-Tear Arthropathy and Shoulder Dislocations in an Elderly Male with Parkinson's Disease. *Case Rep Orthop.* 2017;2017.
50. Yoon JP, Seo A, Kim JJ, et al. Deltoid muscle volume affects clinical outcome of reverse total shoulder arthroplasty in patients with cuff tear arthropathy or irreparable cuff tears. *PLoS One.* 2017;12(3):e0174361.
51. Huber J, Irlenbusch U, Kääh M, Reuther F, Kohut G, Judge A. Treatment Effects of Reverse Total Shoulder Arthroplasty for Unilateral Cuff Tear Arthropathy—Outcomes at 6, 12, 24 and 60 Months and Confounders. *BMC Musculoskelet Disord.* 2020 Jun 22;21(1):397.
52. Kennedy J, Klifto CS, Ledbetter L, Bullock GS. Reverse total shoulder arthroplasty clinical and patient-reported outcomes and complications stratified by preoperative diagnosis: a systematic review. *J Shoulder Elbow Surg.* 2021;30(4):929-41.
53. Kim JY, Rhee YG, Rhee SM. Clinical outcomes after reverse total shoulder arthroplasty according to primary diagnosis. *Clin Orthop Surg.* 2020;12(4):521.
54. Wanga KY, Agarwal AR, Best MJ, Mawn JG, Kamalopathy P, Sriksman U. A Comparison of Complications and Survivorship after Reverse Total Shoulder Arthroplasty for Proximal Humerus Fracture compared with Cuff Tear Arthropathy. *Arch Bone Jt Surg.* 2023;11(3):166.
55. Frankle M, Siegal S, Pupello D, Saleem A, Mighell M, Vasey M. The reverse shoulder prosthesis for glenohumeral arthritis associated with severe rotator cuff deficiency: a minimum two-year follow-up study of sixty patients. *Bone Joint J.* 2005;87(8):1697-705.
56. Ammitzboell M, Baram A, Brorson S, Olsen BS, Rasmussen JV. Poor patient-reported outcome after shoulder replacement in young patients with cuff-tear arthropathy: a matched-pair analysis from the Danish Shoulder Arthroplasty Registry. *Acta Orthop.* 2019;90(2):119-22.
57. Shah NS, Foote AM, Steele CA, et al. Does preoperative disease severity influence outcomes in reverse shoulder arthroplasty for cuff tear arthropathy? *J Shoulder Elbow Surg.* 2021;30(12):2745-52.
58. Sadoghi P, Vavken P, Leithner A, et al. Impact of previous rotator cuff repair on the outcome of reverse shoulder arthroplasty. *J Shoulder Elbow Surg.* 2011;20(7):1138-46.
59. Valenti P, Sauzieres P, Katz D, Kalouche I, Kilinc AS. Do less medialized reverse shoulder prostheses increase motion and reduce notching? *Clin Orthop Relat Res.* 2011;469(9):2550-7.
60. Chawla SS, Schiffman CJ, Whitson AJ, Matsen III FA, Hsu JE. Drivers of inpatient hospitalization costs, joint-specific patient-reported outcomes, and health-related quality of life in shoulder arthroplasty for cuff tear arthropathy. *J Shoulder Elbow Surg.* 2022;31(12):586-92.
61. Vancolen SY, Elsayi R, Horner NS, Leroux T, Alolabi B, Khan M. Reverse total shoulder arthroplasty in the younger patient ( $\leq 65$  years): a systematic review. *J Shoulder Elbow Surg.* 2020;29(1):202-9.
62. Ichiseki T, Ueda S, Souma D, Shimasaki M, Ueda Y, Kawahara N. Reverse Shoulder Arthroplasty for Primary Synovial Osteochondromatosis of the Shoulder with Massive Rotator Cuff Tear and Marked Degenerative Arthropathy. *J Clin Med.* 2018;7(8):189.
63. Westermann RW, Pugely AJ, Martin CT, Gao Y, Wolf BR, Hettrich CM. Reverse shoulder arthroplasty in the United States: a comparison of national volume, patient demographics, complications, and surgical indications. *Iowa Orthop J.* 2015;35:1.
64. Goutallier D, Postel J, Bernageau J, Lavau L, Voisin M. Fatty infiltration of disrupted rotator cuff muscles. *Rev Rhum Engl Ed.* 1995;62(6):415-22.
65. Berton A, Gulotta LV, Petrillo S, et al. The effect of humeral version on teres minor muscle moment arm, length, and impingement in reverse shoulder arthroplasty during activities of daily living. *J Shoulder and Elbow Surg.* 2015;24(4):578-86.
66. Monir JG, Wagner ER. Tendon Transfers in the Setting of Shoulder Arthroplasty. *JSES Reviews, Reports, and Techniques.* Published online 2024.
67. Rakauskas TR, Hao KA, Cueto RJ, et al. Insertion Sites of Latissimus Dorsi Tendon Transfer Performed During Reverse Shoulder Arthroplasty: A Systematic Review and Meta-Analysis. *Orthop Traumatol Surg Res.* Published online 2024:103873.
68. Boileau P, Watkinson DJ, Hatzidakis AM, Balg F. Grammont reverse prosthesis: design, rationale, and biomechanics. *J Shoulder Elbow Surg.* 2005;14(1):147-61.
69. Aleem AW, Feeley BT, Austin LS, et al. Effect of humeral component version on outcomes in reverse shoulder arthroplasty. *Orthopedics.* 2017;40(3):179-86.
70. Jassim SS, Ernstbrunner L, Ek ET. Does humeral component version affect range of motion and clinical outcomes in reverse total shoulder arthroplasty? A systematic review. *J Clin Med.* 2021;10(24):5745.
71. Rhee YG, Cho NS, Moon SC. Effects of humeral component retroversion on functional outcomes in reverse total shoulder arthroplasty for cuff tear arthropathy. *J Shoulder Elbow Surg.* 2015;24(10):1574-81.
72. Oh JH, Sharma N, Rhee SM, Park JH. Do individualized humeral retroversion and subscapularis repair affect the clinical outcomes of reverse total shoulder arthroplasty? *J Shoulder Elbow Surg.* 2020;29(4):821-9.
73. Shah SS, Gaal BT, Roche AM, et al. The modern reverse shoulder arthroplasty and an updated systematic review for each complication: part I. *JSES Int.* 2020;4(4):929-43.
74. Ascione F, Domos P, Guarrella V, Chelli M, Boileau P, Walch G. Long-term humeral complications after Grammont-style reverse shoulder arthroplasty. *J Shoulder Elbow Surg.* 2018;27(6):1065-71.
75. Kim SC, Kim IS, Jang MC, Yoo JC. Complications of reverse shoulder arthroplasty: a concise review. *Clin Shoulder Elbow.* 2021;24(1):42.
76. Jang YH, Lee JH, Kim SH. Effect of scapular notching on clinical outcomes after reverse total shoulder arthroplasty: a meta-analysis. *Bone Joint J.* 2020;102(11):1438-45.
77. Friedman RJ, Barcel DA, Eichinger JK. Scapular notching in reverse total shoulder arthroplasty. *J Am Acad Orthop Surg.* 2019;27(6):200-9.
78. Mollon B, Mahure SA, Roche CP, Zuckerman JD. Impact of scapular notching on clinical outcomes after reverse total shoulder arthroplasty: an analysis of 476 shoulders. *J Shoulder Elbow Surg.* 2017;26(7):1253-61.
79. Gerber C, Pennington SD, Nyffeler RW. Reverse total shoulder arthroplasty. *J Am Acad Orthop Surg.* 2009;17(5):284-95.