

CASE REPORT

Add-on Erythromycin and Tacrolimus Treatment for Primary Sjogren's Syndrome-Related Immune Thrombocytopenia: A Case Report

Masashi Ohe¹

¹Department of Internal Medicine, JCHO Hokkaido Hospital, Sapporo, Japan

Abstract

A 64-year-old woman with primary Sjogren's syndrome (SjS) was admitted to our hospital for nasal bleeding, oral bleeding, and purpura on her entire body. On this admission, laboratory findings were as follows: white blood cell counts, 8,910 / μ L; hemoglobin, 9.9 g/dL; and platelet (PLT) counts, 0.1×10^4 / μ L. Although the anti-PLT antibodies were positive, other autoimmune antibodies including anti-deoxyribonucleic acid antibodies were negative. No immunoglobulin (Ig)M antibodies for cytomegalovirus and Parvovirus B19, and no IgG antibodies for *Helicobacter pylori*, were detected. No abnormal findings suggestive of infection were identified in the systemic examination. A bone marrow aspiration smear revealed normal bone marrow. Based on these findings, the patient was diagnosed with primary SjS-related immune thrombocytopenia (ITP). The patient initially received intravenous immunoglobulin, methyl prednisolone (PSL) pulse therapy, and subsequent high dose PSL without significant improvement. Therefore, eltrombopag was added. Subsequently, erythromycin (EM) was also added, considering its immunomodulatory effects. After initiating the EM treatment, the PLT counts increased. Therefore, the PSL dosage was reduced. However, the PLT counts gradually decreased. Instead of increasing the PSL dosage again, tacrolimus (TAC) was successfully added. Consequently, the PSL dosage could be successfully reduced. This case suggests that EM and TAC can be effective alternatives when conventional immunosuppressants fail to improve primary SjS-related ITP.

Article Info

Received Date: 27.04.2024

Revision Date : 22.06.2024

Accepted Date: 25.06.2024

Keywords:

Sjogren's syndrome,
Immune thrombocytopenia,
Erythromycin,
Tacrolimus

ORCIDs of the authors:

MO :0000-0002-6684-6688

Correspondence Address: 1-8-3-18 Nakanoshima, Toyohira-ku 062-8 Sapporo - Japan

Phone: +81 11 831 51 51 / **e-mail:** oektsp1218@sweet.ocn.ne.jp



Copyright© 2023. Dey et al. This article is distributed under a Creative Commons Attribution 4.0 International License.

Follow this and additional works at: <https://achmedicaljournal.com>

Introduction

Sjogren's syndrome (SjS) is a systemic autoimmune disease characterized by a wide spectrum of clinical manifestations. Immune thrombocytopenia (ITP) is a common clinical manifestation of SjS and causes hemorrhagic events. The mechanism of ITP in SjS is due to anti-platelet (PLT) autoantibody-induced peripheral PLT destruction and splenic sequestration, as well as reduced PLT production by impaired megakaryocytes caused by anti-PLT autoantibodies.¹ Corticosteroids supplemented with immunoglobulin (Ig) are the first-line treatments for SjS-related ITP, while second-line treatments including danazol, cyclosporin A, azathioprine, eltrombopag (ELT), and rituximab have been proposed. However, clinical trials evaluating their efficacy and safety in patients with SjS-related ITP are not documented.¹ Erythromycin (EM), a macrolide (MAC), provides not only anti-bacterial activities but also immunomodulatory effects. Similarly, tacrolimus (TAC), a calcineurin inhibitor and MAC, also provides immunomodulatory effects. Recently, successful cases of ITP using these two drugs have been reported. Herein, we report a case of refractory primary SjS-related ITP treated using EM and TAC.

Case

A 64-year-old woman with primary SjS which was not treated, was admitted to our hospital for nasal bleeding, oral bleeding, and purpura on her entire body. She was diagnosed with primary SjS at the age of 53 years old, based on xerophthalmia, xerostomia, positive results for the Shirmer test and anti-Sjogren's syndrome antigen A antibodies, and abnormal salivary gland scintigraphy. When she visited our hospital for a routine consultation 3 months ago, her PLT count was $20.7 \times 10^4/\mu\text{L}$. This time, laboratory findings were as follows: white blood cell counts, $8,910/\mu\text{L}$ (basophils, 0.1%; eosinophils, 0.3%; neutrophils, 74.3%; lymphocytes, 22.6%; and monocytes, 2.7%); hemoglobin, 9.9 g/dL; PLT counts, $0.1 \times 10^4/\mu\text{L}$; C-reactive protein, 0.32 mg/dL; IgG, 3,721 mg/dL; IgM, 244 mg/dL; and IgA, 408 mg/dL. Although the anti-PLT antibodies were positive, other autoimmune antibodies such as anti-deoxyribonucleic acid and anti-cardiolipin IgG antibodies were negative. Moreover, no IgM antibodies for cytomegalovirus and Parvovirus B19, and no IgG antibodies for *Helicobacter pylori*, were detected. Prothrombin time, activated partial thromboplastin time, fibrinogen, and fibrin degradation products were all within normal levels. A bone marrow aspiration smear revealed normal bone marrow

with a nucleated cell count of $15.1 \times 10^4/\mu\text{L}$ and a megakaryocyte count of $53/\mu\text{L}$ without dysplasia or hemophagocytosis. Furthermore, the number of megakaryocytes was adequate in the specimen (Figure 1). No abnormal findings suggestive of infection were identified in the systemic examination, including the chest X-ray film and urinalysis. Based on these findings, the patient was diagnosed with primary SjS-related ITP. The clinical course is shown in (Figure 2).

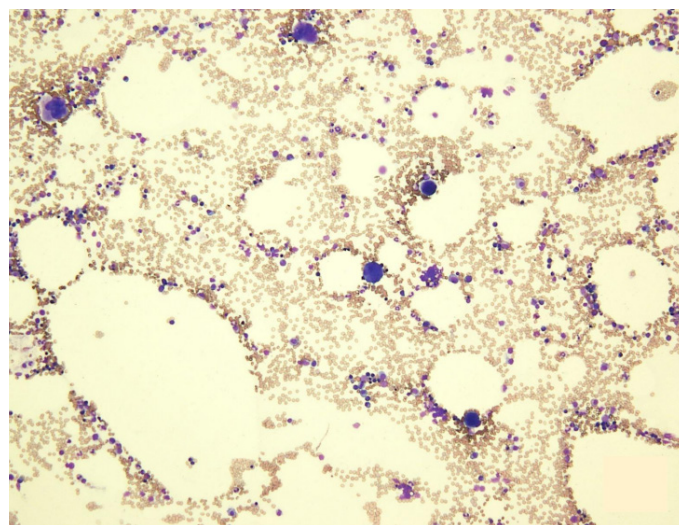


Figure 1. Bone marrow aspiration smear reveals sufficient numbers of megakaryocytes (May-Giemsa stain, magnification $\times 100$).

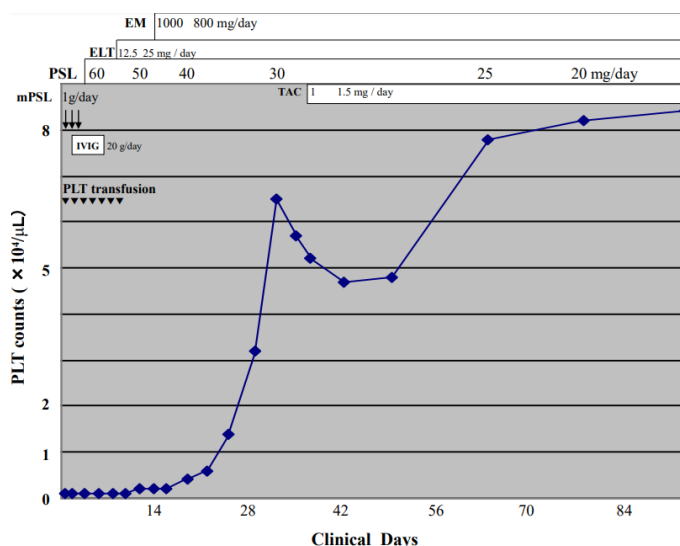


Figure 2. Laboratory data and prescribed agents on clinical days.

PLT: platelet, mPSL: methyl prednisolone, PSL: prednisolone, IVIG: intravenous immunoglobulin, ELT: eltrombopag, EM: erythromycin, TAC: tacrolimus

On the first day of admission, she received PLT transfusion and intravenous methyl prednisolone (PSL) (1,000 mg/day) for 3 days, followed by PSL (60 mg/day) for 7 days, and then PSL (50 mg/day) for 7 days. On the second day, she was treated with intravenous immunoglobulin (IVIG) (20 g/day) for 5 days. During this clinical course, she received PLT transfusions several times. However, the PLT counts did not increase and remained at $0.1\text{--}0.2 \times 10^4/\mu\text{L}$. Seven days after initiating the IVIG treatment, ELT (12.5 mg/day), a thrombopoietin-receptor agonist, was added. However, the PLT counts did not increase; therefore, after 7 days of ELT treatment, the dosage was doubled. Considering the immunomodulatory effects of MACs,² intravenous EM (0.5 g, twice daily) for 7 days and subsequently oral EM (200 mg, four times daily) for the long-term were added after obtaining informed consent. Five days after initiating the EM treatment, the PLT counts increased to $0.4 \times 10^4/\mu\text{L}$. Concurrently, the dosage of PSL was reduced to 40 mg/day. Subsequently, the PLT counts gradually increased. By 18 days after initiating the EM treatment, the PLT counts had increased to $6.5 \times 10^4/\mu\text{L}$. Therefore, the PSL dosage was reduced to 30 mg/day. However, after 6 days of treatment with PSL (30 mg/day), the PLT counts decreased to $5.2 \times 10^4/\mu\text{L}$. Instead of increasing the PSL dosage again, TAC (1 mg/day) was added. However, after 6 days of TAC (1 mg/day) treatment, the PLT counts decreased to $4.7 \times 10^4/\mu\text{L}$. Subsequently, the TAC dosage was increased to 1.5 mg/day. Three weeks after initiating TAC (1.5 mg/day) treatment, the PLT counts increased to $7.8 \times 10^4/\mu\text{L}$. Therefore, the PSL dosage was reduced to 25 mg/day. Two weeks after starting PSL (25 mg/day) treatment, the PLT counts increased $8.2 \times 10^4/\mu\text{L}$. Therefore, the PSL dosage was further reduced to 20 mg/day. The trough levels of TAC (1.5 mg/day) were 6.5 ng/mL.

Discussion

In this current case with hemorrhagic events, the patient initially received IVIG, methyl PSL pulse therapy, and subsequent high dose PSL without significant improvement. Due to the insufficient effectiveness of these combined treatments, ELT was added. Subsequently EM was also added, considering its immunomodulatory effects. The addition of EM treatment was considered effective; however, it takes two weeks to confirm the effectiveness of ELT treatment. Therefore, the improvement in PLT counts observed with PSL (40 mg/day)

may be attributed to the effects of EM and/or ELT. MACs have immunomodulatory and anti-inflammatory effects by increasing the apoptosis of activated lymphocytes, thereby reducing inflammation. MACs, such as clarithromycin and azithromycin have been reported to modulate the function of dendritic cells, which are crucial antigen-presenting cells playing a central role in initiating and regulating immune responses. Additionally, MACs seem to suppress the production of proinflammatory cytokines by T cells.² In our previous reports, we have reported several cases of primary ITP showing increased PLT counts following MACs treatment.³⁻⁵ The improvement of ITP in these cases might be attributed to the immunomodulatory effects of MACs. Based on these findings, the immunomodulatory effects of EM may have contributed to the improvement in PLT counts in this case. During the clinical course, the PLT counts gradually decreased while the patient was on PSL (30 mg/day) in combination with ELT and EM treatment. Instead of increasing the PSL dosage again, TAC was successfully added in this case. As mentioned earlier, TAC is a calcineurin inhibitor and also belongs to the class of MAC. Because calcineurin is a critical phosphatase in T cell receptor signaling, TAC can restrain the activation and differentiation of helper T cells. Additionally, TAC has been proven to inhibit the differentiation of T follicular helper cells and suppress B-cell function.⁶ TAC also inhibits the production and release of tumor necrosis factor- α , interferon (IFN)- γ , and interleukin (IL)-2.⁷ In a study of TAC treatment for primary SjS-related ITP, Xu et al. recruited 23 patients with refractory primary SjS-related ITP and administered 2 or 3 mg/day of TAC in addition to conventional treatments such as glucocorticoids, IVIG, hydroxychloroquine, and others. Four weeks after initiating TAC treatment, 2 patients (8.7%) achieved a complete response showing PLT counts of over $10 \times 10^4/\mu\text{L}$ without bleeding, 15 patients (65.2%) achieved a partial response with PLT counts of over $3 \times 10^4/\mu\text{L}$ but under $10 \times 10^4/\mu\text{L}$ without bleeding or PLT counts at least doubled compared to before treatment, and the remaining 6 patients (26.1%) did not respond to TAC treatment. Additionally, they measured several cytokines, including IL-2, IL-4, and IFN- γ . Consequently, they found that the effect of TAC may be related to reduced expression of T helper cell type 1 cytokine.⁶

In this case, TAC at 1.5 mg/day was sufficiently effective. MACs are known to suppress TAC metabolism by inhibiting cytochrome P450 3A4, the-

reby increasing TAC blood concentrations.⁸ Suzuki et al.⁹ measured TAC blood concentrations in patients with rheumatoid arthritis and observed that the trough levels of TAC in the 1, 2, and 3 mg/day groups were 2.96, 4.29, and 8.32 ng/mL, respectively, although these levels varied widely among individuals within the groups. We regarded the optimal trough levels of TAC as 5.0–10.0 ng/mL. Actually, the trough levels of TAC (1.5 mg/day) in this case were 6.5 ng/mL, indicating that EM may have increased TAC blood concentrations, resulting in the reduction of expensive TAC dosages. However, repeated monitoring of TAC levels is necessary to prevent adverse reactions.

Conclusion

This case suggests that EM and TAC can be effective alternatives when conventional immunosuppressants fail to improve primary SjS-related ITP.

Funding

No funding source was reported for this study.

Declaration of interest

The author declares no conflicts of interest associated with this article.

References

1. Xu L, Zhang Y, Lin N, Song X, Dai Q. Eltrombopag improves refractory thrombocytopenia in patients with Sjögren's syndrome. *Sci Prog.* 2022;105(2). [https://doi: 10.1177/00368504221102786](https://doi.org/10.1177/00368504221102786)
2. Altenburg J, De Graaff CS, Van Der Werf TS, Boersma WG. Immunomodulatory effects of macrolide antibiotics—part 1: biological mechanisms. *Respiration.* 2010 Dec 1;81(1):67-74. [https://doi: 10.1159/000320319](https://doi.org/10.1159/000320319)
3. Ohe M, Hashino S. Successful treatment with erythromycin for idiopathic thrombocytopenic purpura. *Korean J Hematol.* 2011; 46:139-142. [https://doi:10.5045/kjh.2011.46.2.139](https://doi.org/10.5045/kjh.2011.46.2.139)
4. Ohe M, Hashino S. Successful treatment of primary immune thrombocytopenia in aged patients using clarithromycin. *J Formos Med Assoc.* 2014; 113:197-198. [https://doi:10.1016/j.jfma.2011.08.035](https://doi.org/10.1016/j.jfma.2011.08.035)
5. Ohe M, Furuya K, Goudarzi H. Immune Thrombocytopenia Treated with Intravenous Erythromycin. *Gazi Med J.* 2021 Sep 9;32(4):577-579. [https://doi: 10.12996/gmj.2021.129](https://doi.org/10.12996/gmj.2021.129)
6. Xu R, Yan Q, Gong Y, et al. Tacrolimus therapy in primary Sjögren's syndrome with refractory immune thrombocytopenia: a retrospective study. *Clin Exp Rheumatol.* 2022 Dec;40(12):2268-2274. [https://doi: 10.55563/clinexprheumatol/5c7101](https://doi.org/10.55563/clinexprheumatol/5c7101). Epub 2022 Sep 20. PMID: 36135951.
7. Du Y, Yang C, Chen M, et al. Tacrolimus is effective in relapsed/refractory autoimmune cytopenias: results of a single-center retrospective study. *Hematology.* 2020 Jan 1;25(1):478-483. [https://doi: 10.1080/16078454.2020.1852763](https://doi.org/10.1080/16078454.2020.1852763)
8. Ohe M. A Case of Rheumatoid Arthritis accompanied by Organizing Pneumonia Successfully Treated with Prednisolone, Clarithromycin and Tacrolimus. *Korean J Clin Pharm.* 2017 Sep 30;27(3):195-197. [https://doi: 10.24304/kjcp.2017.27.3.195](https://doi.org/10.24304/kjcp.2017.27.3.195)
9. Suzuki K, Kameda H, Amano K, et al. Single center prospective study of tacrolimus efficacy and safety in treatment of rheumatoid arthritis. *Rheumatol Int.* 2009 Feb;29(4):431-436. [https://doi: 10.1007/s00296-008-0833-z](https://doi.org/10.1007/s00296-008-0833-z). Epub 2009 Jan 7. PMID: 19127365.