




## CASE REPORT

# Three-Year Outcomes of Combined Autotransplantation and Regenerative Endodontic Treatment of a Immature Tooth: A Case Report

İdil Özden <sup>1, \*</sup>, Emrah Canbazoglu <sup>2</sup> and Hesna Sazak Öveçoğlu <sup>1</sup>

<sup>1</sup>Marmara University Faculty of Dentistry, Department of Endodontics, Istanbul, Turkey and <sup>2</sup>Private Clinic

\*Corresponding Author; idil.akman94@gmail.com

## Abstract

Autotransplantation and regenerative endodontic treatment are biologically based dental treatment modalities. Autotransplantation may be a more affordable alternative to implants for patients who experience tooth loss at a young age. Regenerative endodontic treatment is also an alternative to routine endodontic treatment as it can allow the regeneration of necrotic or inflamed pulp tissue. The aim of this case is to report a successful 3-year treatment outcome in an immature tooth using a combination of autotransplantation and regenerative endodontic treatment. An 18-year-old female patient with complaints of severe pain and mobility at 37. The patient's medical history revealed no systemic disease. Clinical and radiographic examination revealed that 37 had undergone root canal treatment 3 years ago. Retreatment of the root canal was initiated, but the symptoms did not improve despite interm treatment. After surgical consultation, it was decided to extract 37. For autotransplantation, 38 was extracted atraumatically and autotransplanted into the socket of 37 and splinted for 2 weeks. Regenerative endodontic treatment was planned due to the radiolucency observed in the periapical area of the tooth at the 6-month follow-up. Regenerative endodontic treatment was performed on the autotransplanted tooth using platelet-rich fibrin obtained from the patient's own blood. The tooth remained asymptomatic and functional for 3 years. Root development continued and periapical healing was complete at 6 months. The tooth showed a positive response to pulp sensitivity tests at the 1-year follow-up. The combination of autotransplantation and regenerative endodontic treatment can be considered as a long-term treatment option for immature teeth.

**Key words:** Autotransplantation; Regeneration; Revascularisation; Platelet-rich fibrin; Vital pulp therapy

## Introduction

While the primary goal of conservative dentistry is to preserve natural teeth, tooth extraction may be necessary in some cases. Replacement of lost teeth is essential to restore chewing function and aesthetic appearance. Implant-supported prostheses or autotransplantation may be considered as alternatives to traditional prostheses to replace extracted teeth.<sup>1</sup> Dental implants are not a suitable option before the completion of growth, typically up to the age of 19 years in females and 21 years in males, as they cannot follow craniofacial growth and maintain their position during ongoing development.<sup>2,3</sup> However, tooth loss due to trauma or decay is more common in young adults.<sup>4,5</sup> Therefore, autotransplantation can be an excellent alternative for these patients. Autotransplantation involves the surgical repositioning of a tooth from the same patient to replace a missing tooth. It can be thought of as the controlled extraction of a tooth followed by its reinsertion into the extraction

socket, either naturally or under the control of the dentist. The preservation of the attached gingiva in its natural shape provides better aesthetic results and preservation of proprioception, which are the main advantages of the procedure.<sup>6,7</sup> It also has a lower rate of bone resorption and is relatively less expensive than implants.<sup>8</sup>

The use of dental autotransplantation was first introduced into dentistry by M.L. Hale in 1954, and the basic principles are still used today.<sup>9</sup> Initially, the treatment was not widely accepted due to a success rate of around 50%.<sup>10,11</sup> However, in the last fifteen years, with the recognition of the need for atraumatic extraction and endodontic treatment during the procedure, success rates have increased and the popularity of the procedure has grown. Today, tooth transplantation is considered an alternative treatment to implants for replacing edentulous areas. However, many factors influence the success and survival of the tooth. These include the stage of root completion, tooth type, surgical technique, recipient site preparation, use of perioperative systemic antibiotics, and type and

duration of splinting.<sup>10</sup> It has been reported that open apex teeth may allow neurovascular growth after tooth transplantation, leading to improved vitality and survival rates.<sup>12</sup> Another clinical trial reported survival rates of 94% and 84% in teeth with incomplete and complete root formation, respectively.<sup>13</sup>

Regenerative endodontic treatment, like dental autotransplantation, is a biologically based dental treatment for dental tissue loss in young adults and children.<sup>14</sup> Regenerative endodontic treatment, also known as revascularisation, aims to treat inflamed or necrotic open apex permanent teeth by respecting the biology of the pulp-dentine complex.<sup>15</sup> In open apex permanent teeth, the primary goal of regenerative endodontics is to eliminate symptoms and heal periapical lesions, with the additional goals of maintaining or regaining vitality and promoting root development.<sup>16</sup>

Regenerative endodontics requires three main components: stem cells capable of differentiating into odontoblast-like cells, growth factors that direct the differentiation of stem cells into odontoblast-like cells, and scaffold structures necessary to organise these cells in the right place in three dimensions.<sup>17</sup> Therefore, materials such as calcium hydroxide, MTA, Biodentin and EDTA, which induce the release of growth factors from the root canal, are preferred in regenerative endodontic treatments.<sup>18</sup> The most common method of scaffolding is to induce periapical bleeding with a sterile instrument and form a blood clot in the canal.<sup>19</sup> However, since periapical bleeding may not always be transported into the canal and the erythrocytes in the clot may become necrotic over time, the use of autogenous platelet concentrates obtained by centrifugation of the patient's own blood, such as platelet-rich plasma (PRP) and platelet-rich fibrin (PRF), has become widespread.<sup>20,21</sup>

Variable results have been reported in studies of both regenerative endodontic treatment and autotransplantation procedures.<sup>18,22</sup> However, when reviewing the current literature, the number of studies evaluating the results of regenerative endodontic treatment in immature teeth where autotransplantation procedures have been performed is quite limited.<sup>14,23</sup> The aim of this study is to report the 3-year results of a case where autotransplantation and regenerative endodontic treatment were performed.

## Case Report

An 18-year-old female patient presented to the Endodontics Department of the XX University Faculty of Dentistry with severe pain and mobility in tooth 37. Her medical history revealed that tooth 37 had undergone root canal treatment three years previously. Radiographs showed a large periapical lesion extending to the inferior alveolar nerve associated with the previous root canal treatment (Figures 1–2). It was decided to repeat the root canal treatment due to chronic apical periodontitis. Despite two interim applications of calcium hydroxide over a period of 3 months, no improvement in symptoms was observed. After a surgical consultation, it was decided to extract teeth 37 and 38 and to transplant tooth 38 to replace tooth 37.

Other treatment options recommended to the patient included implant placement and fixed prosthesis. However, after discussing the benefits, risks and long-term outcomes of each option, the patient opted for autotransplantation because she wanted to retain a natural tooth and avoid the need for prosthetics or implants. This decision was influenced by the patient's preference for a biological solution that could restore function and aesthetics with a more natural outcome. After a detailed explanation of the procedure and possible complications, the patient was informed and signed a consent form. For the autotransplantation procedure, tooth 38 was extracted atraumatically under local anaesthesia and preserved in 0.9% isotonic sodium chloride solution to maintain the vitality of the periodontal ligament. The atraumatic tooth extraction was performed by an oral surgeon with more than 5 years of experience, during which time he gained extensive expertise in various

surgical procedures. An inferior alveolar nerve block technique was used for local anaesthesia, and a solution of 4% articaine with epinephrine (1:100,000) was selected for the procedure. Tooth 37 was extracted and after curettage of the extraction socket, the recipient site for the transplanted tooth was prepared with surgical drills. Tooth 38 was placed in the socket and finger pressure was applied for 3 minutes. The occlusal relationship with the opposing arch was then assessed to avoid premature contact. After placement of tooth 38 in the socket, 4/0 non-absorbable monofilament sutures were selected for stabilisation. (Ethicon, Johnson & Johnson, USA) (Fig. 3). Follow-up appointment was scheduled for 2 weeks later.

At the follow-up visit, the sutures were removed and tooth mobility was checked. According to the Miller classification, mobility, which was recorded as class 3 after autotransplantation, was recorded as class 1 at the follow-up visit. Periodontal probing revealed no pockets deeper than 3 mm. As there were no clinical or radiographic problems (no pain or sensitivity to percussion and palpation, absence of periapical radiolucency, normal periodontal ligament width and healthy bone structure observed on radiographs), the patient was scheduled for routine follow-up every 3 months for the first year. At the 6-month follow-up, the patient presented with pain on chewing. Radiographic examination revealed radiolucency in the periapical area of the tooth. Clinically, the tissues surrounding the tooth were assessed by percussion and palpation tests, which revealed mild to moderate tenderness. Thermal tests (application of cold and heat) and electrical pulp tests were performed to assess the vitality of the tooth, and these tests confirmed that the tooth was non-vital. Radiographic examination showed the presence of a periapical radiolucent area at the root apex, indicating chronic apical infection. The diagnosis of chronic apical periodontitis was confirmed based on the combination of clinical and radiographic findings. Considering the patient's age, regenerative endodontic treatment was planned and a consent form was signed after explaining the possible risks.

After cavity preparation under the rubber-dam isolation, the working length was determined radiographically. The root canals were prepared and enlarged up to size 30 with a 0.4 taper with rotary instruments (Smart Gold, EndoArt, Inci Dental, Turkey) under irrigation with 2.5% sodium hypochlorite. (Microvem, Altun Sterilization & Medical, Turkey) Final irrigation with 17% EDTA (Microvem, Altun Sterilization & Medical, Turkey). Calcium hydroxide (Vision, WP Dental, Germany) was placed in the canal and the patient was scheduled for a second appointment three weeks later. (Fig. 4) At the second appointment, the regenerative treatment was started as the patient reported no discomfort. The root canal was irrigated with 10 mL of 2.5% NaOCl and 10 mL of 17% EDTA with sonic activation (EDDY, VDW, Germany) under rubber dam isolation. The canal was then rinsed with distilled water and dried. Ten millilitres of blood was taken from the patient and centrifuged at 2700 rpm for 12 minutes to obtain a PRF membrane. The PRF membrane obtained was placed in the canal as a small strip and compressed. A 3–4 mm layer of mineral trioxide aggregate (MTA) (BioMTA, Cerkamed, Poland) was applied and sealed with glass ionomer cement (RubyLiner, Inci Dental, Turkey) (Fig. 5). The permanent composite restoration was completed one month later. This was due to the patient's location out of town.

The patient was recalled every three months for the first year for radiographic examination and clinical symptom assessment. Initial examinations revealed no pain to percussion or palpation, but the tooth was unresponsive to cold and electrical pulp tests. Healing of the periapical area was observed at three months, with enlargement of the apex at six months (Figs 6–7). Follow-up examinations showed that the tooth was functional and asymptomatic. And no aesthetic discolouration was observed as a result of the MTA application. At one year, radiographs showed complete healing of the apical lesion with continued hard tissue deposition (Fig. 8). In addition, the tooth responded positively to sensitivity testing. After 36 months of follow-up, the tooth remained asymptomatic and

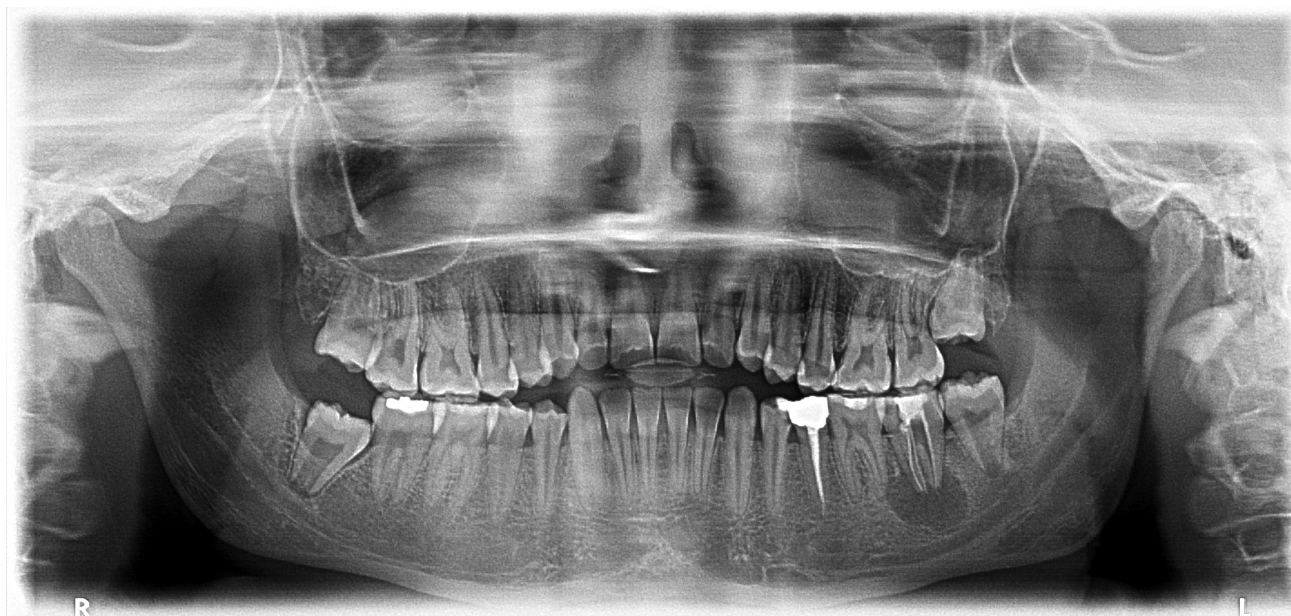

Figure 1. Diagnostic panoramic radiograph

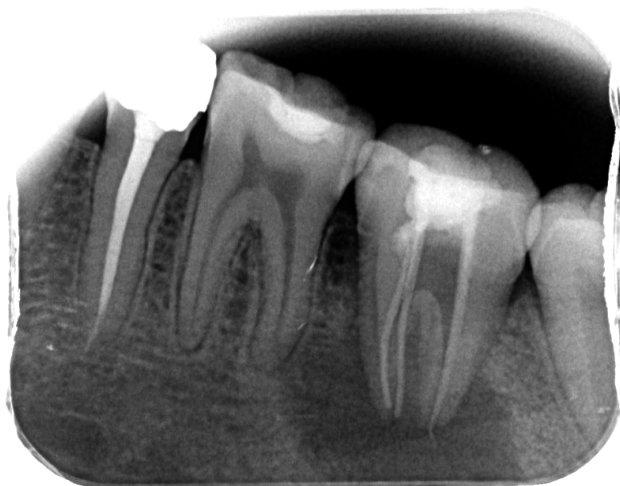

Figure 2. Diagnostic periapical radiograph

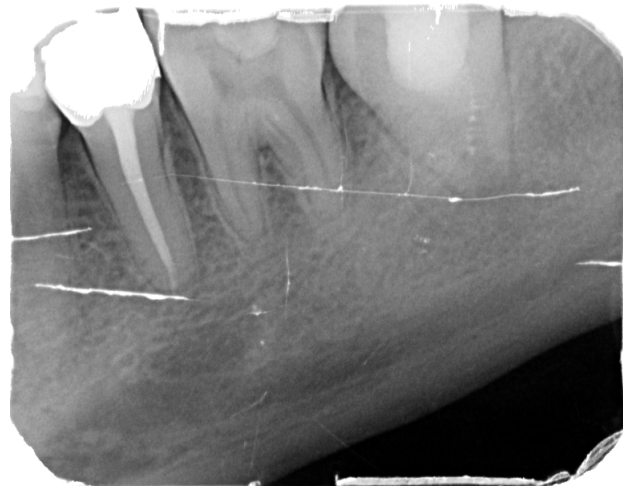

Figure 4. 6-month post-autotransplantation (after the application of calcium hydroxide.)

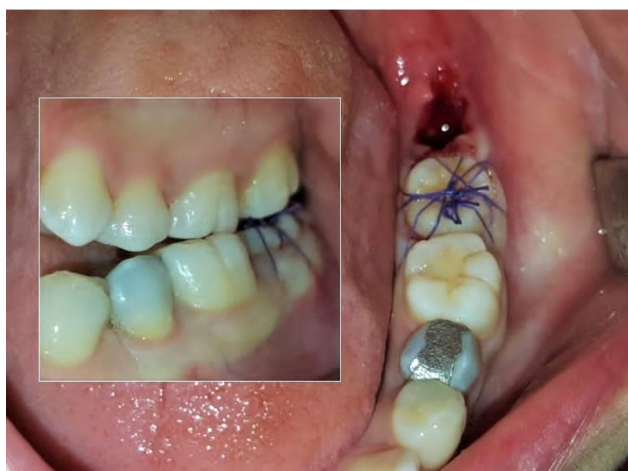


Figure 3. Splinted with sutures for stabilisation

functional in the oral cavity. There was no evidence of pain or sensitivity to percussion, palpation or biting. The tooth continued to respond to thermal and electrical sensitivity testing. Radiographs showed complete healing of the apical lesion and a normal periodontal ligament in all directions of the root (Fig. 9).

## Discussion

Dental autotransplantation and regenerative endodontic treatment are biologically based treatments that are particularly useful for treating tooth loss at a young age.<sup>14</sup> Autotransplantation is a technique that has been continuously developed and supported by valid clinical studies to date.<sup>6,24,25</sup> Although there are many studies on teeth with complete root development, there are not enough studies on teeth with incomplete root development to confirm the success of this technique. However, survival rates reported in recent meta-analyses are over 95%, suggesting that autotransplantation should be considered a predictable long-term technique for open apex teeth.<sup>13,23</sup>



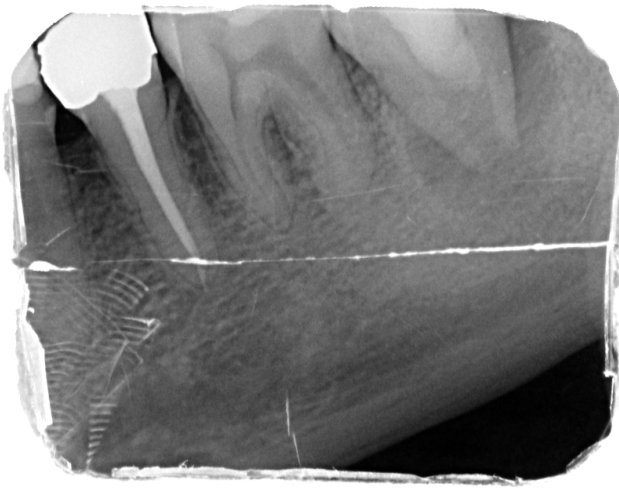

Figure 5. Placement of MTA

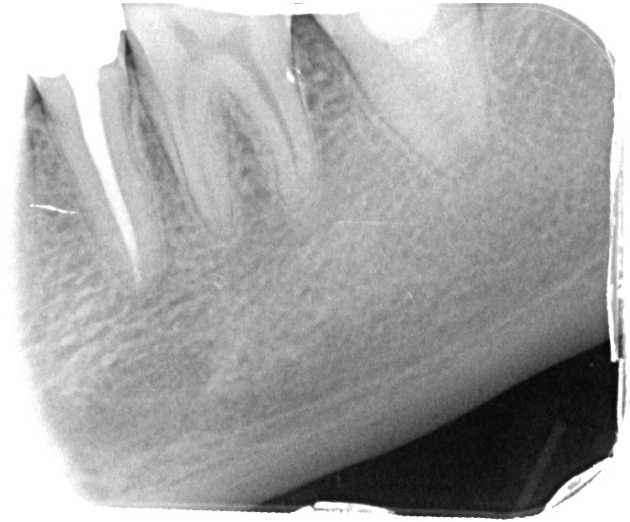

Figure 8. 12-month follow-up radiograph

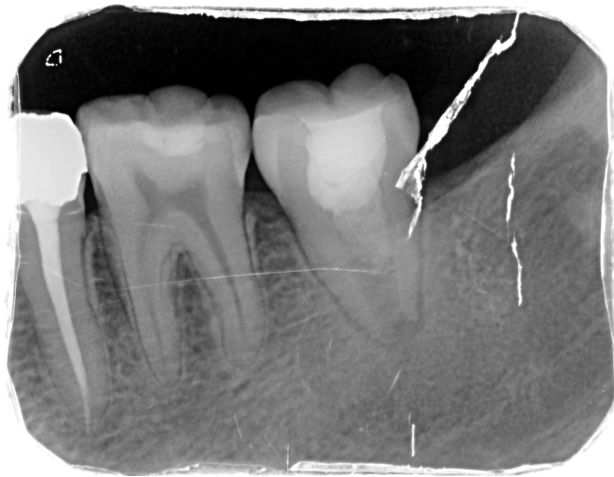

Figure 6. 3-month follow-up radiograph

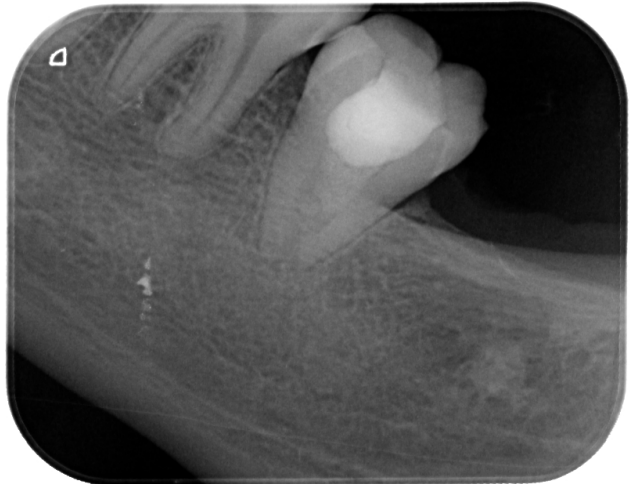

Figure 9. 36-month follow-up radiograph

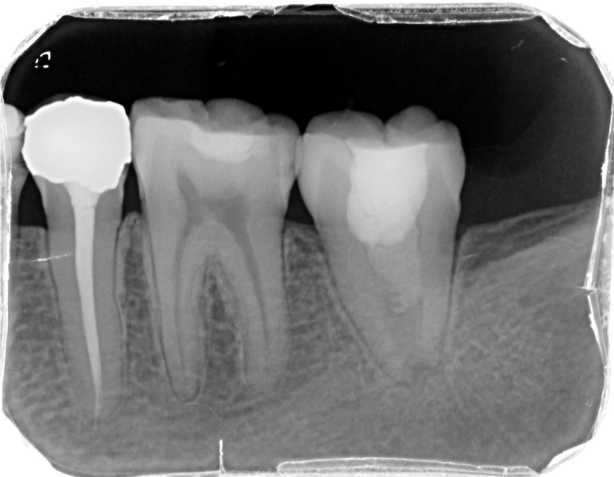

Figure 7. 6-month follow-up radiograph

In this case, tooth 37, which could not be treated despite root canal treatment and application of calcium hydroxide, was extracted and tooth 38, with an open apex, was transplanted in its place, followed by regenerative endodontic therapy. Calcium hydroxide was applied twice over a three-month period to ensure complete disinfection of the infected root canals. The first application aimed

to eliminate most of the bacteria in the canal, while the second application focused on eradicating any remaining bacterial biofilms and infections. The literature suggests that calcium hydroxide has a long-lasting antibacterial effect and is effective in eliminating residual bacteria. In addition, multiple applications improve infection control and aid the healing process.<sup>26</sup> As there was no response to treatment, it was decided to discontinue the root canal treatment and proceed with autotransplantation therapy.

Pulpal vitality is considered one of the key criteria for successful autotransplantation. In their studies, Northway et al.<sup>27</sup> reported that transplanted open apex teeth should respond positively to sensitivity tests within 2 to 4 months. Czochrowska et al.<sup>28</sup> found positive responses to pulp vitality tests in all immature apex teeth they transplanted. Nagori et al.<sup>29</sup> also reported positive responses to electrical pulp tests in transplanted open apex teeth. In this case, the transplanted tooth did not respond to vitality tests and became symptomatic within 6 months. Regenerative treatment was therefore the treatment of choice.

According to the American Association of Endodontics (AAE) guidelines, the primary goal of regenerative endodontic procedures is to treat apical periodontitis. Secondary goals include standardizing root wall thickness and length and achieving vitality.<sup>30,31</sup> Stem cells, growth factors and natural or artificial scaffolds play a role in regenerative treatments. PRF is a potential scaffold that controls inflammatory responses and promotes growth and regen-

eration.<sup>32</sup> By acting as a depot for tissue healing elements, PRF increases the formation of new hard and soft tissue in the canal area.<sup>33</sup> The clinical advantages of MTA placement over PRF, with its excellent coronal sealing and biocompatibility properties, have been demonstrated.<sup>34</sup> In this case, PRF obtained by centrifugation of the patient's blood was used and covered with MTA. The settings chosen to obtain the PRF membrane were optimised to preserve the biocompatibility and coagulation properties of the fibrin structure. PRF was obtained by centrifugation at 2700 rpm for 12 minutes. These settings help to maintain the biological activity and cellular components of the PRF, promoting the formation of an optimal fibrin matrix that supports tissue healing. Similar centrifugation speeds and durations have been reported in the literature to provide the highest biological efficacy of the PRF membrane.<sup>35</sup>

Clinical and radiological evaluations were performed at 3, 6, 12 and 36 months after the regeneration procedure; the tooth was asymptomatic and functional. In addition, complete periapical healing was observed at 6 months and root formation continued. At the 1-year follow-up, the tooth was found to respond positively to pulp sensitivity tests.

No root resorption was observed during the follow-up period. This can be attributed to the use of atraumatic extraction techniques and careful preservation of periodontal ligament cells, which played a crucial role in maintaining the vitality of the transplanted tooth and helping to prevent inflammatory root resorption.<sup>36</sup> During the transplantation process, careful and atraumatic extraction of the tooth, together with preservation of the root surfaces and minimisation of the time before transplantation, helps to maintain the vitality of the periodontal cells. Keeping the tooth in a moist environment and preventing further desiccation of the cells also contributes to the success of the procedure. Similar studies have shown that preserving periodontal ligament cells has a protective effect against root resorption and ankylosis, emphasising the importance of these factors in the long-term success of the graft.<sup>37–39</sup> Additionally, the use of nonabsorbable sutures during the procedure, combined with proper stabilization techniques to avoid excessive force, may have minimized the risk of root resorption. Studies have indicated that applying sutures for stabilization after autotransplantation, especially for short-term use, enhances pulp healing and reduces the risk of inflammatory root resorption when compared to rigid splinting techniques. These findings suggest that less rigid stabilization methods, such as sutures, are beneficial for promoting healing while minimizing complications like root resorption.<sup>40,41</sup> In this case, the tooth was placed with minimal pressure and stabilised with non-resorbable sutures.

In addition, the biocompatible materials used in the root canal treatment, particularly mineral trioxide aggregate (MTA), may have contributed to the prevention of resorption by promoting healing and minimising inflammation. Similar findings have been reported in the existing literature, where the use of biocompatible materials and appropriate stabilisation techniques have been shown to positively influence the healing process and reduce the risk of resorption.<sup>42–44</sup>

The success achieved through the use of appropriate surgical techniques, careful preservation of the periodontal ligament and the use of biocompatible materials is promising for future treatment procedures. This study demonstrates that autotransplantation and regenerative endodontic treatment can be valuable clinical options for managing tooth loss, particularly in young patients. The use of MTA and PRF membranes in this approach optimises infection control and tissue healing, allowing the transplanted tooth to regain functionality. The primary clinical contribution of this study is to demonstrate that biocompatible materials and appropriate stabilisation techniques significantly improve the long-term success of autotransplantation procedures.

However, the study has some limitations. It is a single case report, which limits the generalisability of the findings. Further clinical studies are needed to evaluate factors such as patient age, root

development status and surgical techniques in a broader patient population. In addition, the success rate of autotransplantation and the factors influencing it should be investigated in larger clinical trials and randomised controlled trials to validate these findings.

## Conclusion

Despite its limitations, this study presents a successful three-year follow-up of the autotransplantation technique performed on an immature tooth followed by regenerative endodontic treatment. This technique can be recommended, especially for patients in the growth and development phase; however, in these cases, the combination of success criteria and the determination of the necessary follow-up period are essential, along with a clear surgical protocol to evaluate the effectiveness of the technique.

## Financial Support

There was no financial support from any funding organization.

## Author Contributions

Conception : I.O. , E.C.

Data curation : I.O.

Investigation : I.O. , E.C.

Methodology : I.O. , E.C.

Review : H.S.O.

Manuscript writing : I.O.

Editing the manuscript : H.S.O.

Read and approved the final manuscript : All Authors

## Authors' ORCID(s)

I.O. [0000-0003-0838-4355](https://orcid.org/0000-0003-0838-4355)

E.C. [0000-0002-2830-0166](https://orcid.org/0000-0002-2830-0166)

H.S.O. [0000-0003-4709-422X](https://orcid.org/0000-0003-4709-422X)

## References

1. Srivastava S, Gupta K, Dubey S, Singh A. Guided autotransplantation of tooth: An innovative approach. *Natl J Maxillofac Surg*. 2022;13(Suppl 1):S136–s139. doi:10.4103/njms.NJMS\_169\_20.
2. Gilijamse M, Baart JA, Wolff J, Sándor GK, Forouzanfar T. Tooth autotransplantation in the anterior maxilla and mandible: retrospective results in young patients. *Oral Surg Oral Med Oral Pathol Oral Radiol*. 2016;122(6):e187–e192. doi:10.1016/j.oooo.2016.06.013.
3. Tsukiboshi M. Autotransplantation of teeth: requirements for predictable success. *Dent Traumatol*. 2002;18(4):157–180. doi:10.1034/j.1600-9657.2002.00118.x.
4. Barman J, Kalita C, Baruah R, Choudhury K. Tooth Loss and Its Risk Factors Among the Young Adults in the Kamrup (Metro) District of Assam: An Epidemiological Study. *JIAPHD*. 2022;20(2):159–167. doi:10.4103/jiaphd.jiaphd\_136\_21.
5. Nashkova S, Dimova C. Traumatic dental injuries: etiology, prevalence and possible outcomes. *IJSR*. 2022;1(4):27–29. doi:10.35120/medisij010427n.
6. Ong D, Itskovich Y, Dance G. Autotransplantation: a viable treatment option for adolescent patients with significantly compromised teeth. *Aust Dent J*. 2016;61(4):396–407. doi:10.1111/adj.12420.
7. Srivastava S, Gupta K, Dubey S, Singh A. Guided autotransplan-

- tation of tooth: An innovative approach. *Natl J Maxillofac Surg.* 2022;13(Suppl 1):S136. doi:10.4103/njms.NJMS\_169\_20.
8. Jang Y, Choi YJ, Lee SJ, Roh BD, Park SH, Kim E. Prognostic factors for clinical outcomes in autotransplantation of teeth with complete root formation: survival analysis for up to 12 years. *J Endod.* 2016;42(2):198–205. doi:10.1016/j.joen.2015.10.021.
  9. Verweij J, Jongkees F, Moin DA, Wismeijer D, Van Merkesteyn J. Autotransplantation of teeth using computer-aided rapid prototyping of a three-dimensional replica of the donor tooth: a systematic literature review. *Int J Oral Maxillofac Surg.* 2017;46(11):1466–1474. doi:10.1016/j.ijom.2017.04.008.
  10. Almpani K, Papageorgiou SN, Papadopoulos MA. Auto-transplantation of teeth in humans: a systematic review and meta-analysis. *Clin Oral Investig.* 2015;19:1157–1179. doi:10.1007/s00784-015-1473-9.
  11. Schmidt SK, Cleverly DG. Tooth autotransplantation: an overview and case study. *Northwest Dent.* 2012;91(4):29–34.
  12. Singh AK, Khanal N, Acharya N, Hasan MR, Saito T. What are the complications, success and survival rates for autotransplanted teeth? An overview of systematic reviews and meta-analyses. In: *Healthcare.* vol. 10. MDPI; p. 835. doi:10.3390/healthcare10050835.
  13. Lundberg T, Isaksson S. A clinical follow-up study of 278 autotransplanted teeth. *Br J Oral Maxillofac Surg.* 1996;34(2):181–185. doi:10.1016/s0266-4356(96)90374-5.
  14. EzEldeen M, De Piero MN, Xu L, Driesen RB, Wyatt J, Van Gorp G, et al. Multimodal Imaging of Dental Pulp Healing Patterns following Tooth Autotransplantation And Regenerative Endodontic Treatment. *J Endod.* 2023. doi:10.1016/j.joen.2023.06.003.
  15. Turk T, Cicconetti A, Di Nardo D, Miccoli G, Coppola S, Bhandi S, et al. Nonsurgical retreatment using regenerative endodontic protocols: a case report. *J Contemp Dent Pract.* 2020;21(11):1275–1278. doi:10.5005/jp-journals-10024-2909.
  16. Galler K, Krastl G, Simon S, Van Gorp G, Meschi N, Vahedi B, et al. European Society of Endodontology position statement: Revitalization procedures. *Int Endod J.* 2016;49(8):717–723. doi:10.1111/iej.12629.
  17. Murray PE, Garcia-Godoy F, Hargreaves KM. Regenerative endodontics: a review of current status and a call for action. *J Endod.* 2007;33(4):377–390. doi:10.1016/j.joen.2006.09.013.
  18. Cehreli ZC, Unverdi GE, Ballikaya E. Deciduous tooth pulp autotransplantation for the regenerative endodontic treatment of permanent teeth with pulp necrosis: a case series. *J Endod.* 2022;48(5):669–674. doi:10.1016/j.joen.2022.01.015.
  19. Lovelace TW, Henry MA, Hargreaves KM, Diogenes A. Evaluation of the delivery of mesenchymal stem cells into the root canal space of necrotic immature teeth after clinical regenerative endodontic procedure. *J Endod.* 2011;37(2):133–138. doi:10.1016/j.joen.2010.10.009.
  20. Martin G, Ricucci D, Gibbs JL, Lin LM. Histological findings of revascularized/revitalized immature permanent molar with apical periodontitis using platelet-rich plasma. *J Endod.* 2013;39(1):138–144. doi:10.1016/j.joen.2012.09.015.
  21. Torabinejad M, Milan M, Shabahang S, Wright KR, Faras H. Histologic examination of teeth with necrotic pulps and periapical lesions treated with 2 scaffolds: an animal investigation. *J Endod.* 2015;41(6):846–852. doi:10.1016/j.joen.2015.01.026.
  22. Plotino G, Abella Sans F, Duggal MS, Grande NM, Krastl G, Nagendrababu V, et al. Present status and future directions: Surgical extrusion, intentional replantation and tooth autotransplantation. *Int Endod J.* 2022;55:827–842. doi:10.1111/iej.13723.
  23. Sicilia-Pasos J, Kewalramani N, Pena-Cardelles JF, Salgado-Peralvo AO, Madrigal-Martinez-Pereda C, Lopez-Carpintero A. Autotransplantation of teeth with incomplete root formation: systematic review and meta-analysis. *Clin Oral Investig.* 2022;26(5):3795–3805. doi:10.1007/s00784-022-04435-8.
  24. Park JH, Tai K, Hayashi D. Tooth autotransplantation as a treatment option: a review. *J Clin Pediatr Dent.* 2010;35(2):129–135. doi:10.17796/jcpd.35.2.97816254u214ox88.
  25. Yoshino K, Kariya N, Namura D, Noji I, Mitsuhashi K, Kimura H, et al. A retrospective survey of autotransplantation of teeth in dental clinics. *J Oral Rehabil.* 2012;39(1):37–43. doi:10.1111/j.1365-2842.2011.02234.x.
  26. Bergenholtz G, Torneck C, Kishen A. Inter-appointment medication with calcium hydroxide in routine cases of root canal therapy. *The Root Canal Biofilm.* 2015:303–325. doi:10.1007/978-3-662-47415-0\_10.
  27. Northway W. Autogenic dental transplants. *Am J Orthod Dentofacial Orthop.* 2002;121(6):592–593. doi:10.1067/mod.2002.124795.
  28. Czochrowska EM, Stenvik A, Bjercke B, Zachrisson BU. Outcome of tooth transplantation: survival and success rates 17–41 years posttreatment. *Am J Orthod Dentofacial Orthop.* 2002;121(2):110–119. doi:10.1067/mod.2002.119979.
  29. Nagori SA, Bhutia O, Roychoudhury A, Pandey RM. Immediate autotransplantation of third molars: an experience of 57 cases. *Oral Surg Oral Med Oral Pathol Oral Radiol.* 2014;118(4):400–407. doi:10.1016/j.oooo.2014.05.011.
  30. Arslan H, Ahmed HMA, Şahin Y, Yıldız ED, Gündoğdu EC, Güven Y, et al. Regenerative endodontic procedures in necrotic mature teeth with periapical radiolucencies: a preliminary randomized clinical study. *J Endod.* 2019;45(7):863–872. doi:10.1016/j.joen.2019.04.005.
  31. Geisler TM. Clinical considerations for regenerative endodontic procedures. *Dent Clin North Am.* 2012;56(3):603–626. doi:10.1016/j.cden.2012.05.010.
  32. Das S, Srivastava R, Thosar NR, Khubchandani M, Ragit R, Malviya N. Regenerative Endodontics—Reviving the Pulp the Natural Way: A Case Report. *Cureus.* 2023;15(3). doi:10.7759/cureus.36587.
  33. Lin LM, Shimizu E, Gibbs JL, Loghin S, Ricucci D. Histologic and histobacteriologic observations of failed revascularization/revitalization therapy: a case report. *J Endod.* 2014;40(2):291–295. doi:10.1016/j.joen.2013.08.024.
  34. Torabinejad M, Higa RK, McKendry DJ, Ford TRP. Dye leakage of four root end filling materials: effects of blood contamination. *J Endod.* 1994;20(4):159–163. doi:10.1016/S0099-2399(06)80326-2.
  35. Choukroun J, Adda F, Schoeffer C, Vervelle A. PRF: an opportunity in perio-implantology. *Implantodontie.* 2000;42:55–62.
  36. Galler KM, Grätz EM, Widbiller M, Buchalla W, Knüttel H. Pathophysiological mechanisms of root resorption after dental trauma: a systematic scoping review. *BMC Oral Health.* 2021;21:1–14. doi:10.1186/s12903-021-01510-6.
  37. Martin K, Nathwani S, Bunyan R. Autotransplantation of teeth: an evidence-based approach. *Br Dent J.* 2018;224(11):861–864. doi:10.1038/sj.bdj.2018.432.
  38. Suwanapong T, Waikakul A, Boonsirirath K, Ruangsawasdi N. Pre- and peri-operative factors influence autogenous tooth transplantation healing in insufficient bone sites. *BMC Oral Health.* 2021;21:1–10. doi:10.1186/s12903-021-01686-x.
  39. Zhu W, Zhang Q, Zhang Y, Cen L, Wang J. PDL regeneration via cell homing in delayed replantation of avulsed teeth. *J Transl Med.* 2015;13:1–11. doi:10.1186/s12967-015-0719-2.
  40. Gupta R, Tomer A, Pyasi S. An In Vitro Analysis of Fracture Strength of Various Bulk Fill Flow able Composite Resins. *J Med Sci.* 2018;17(2):40–44.
  41. Krishna Prasada L, Suhas AKP. Splinting of Traumatized Tooth—A Systematic Review. *RGUHS J Dent Sci.* 2023;15(1):17–23. doi:10.26463/rjds.15\_1\_19.
  42. Güzeler I, Uysal S, Cehreli ZC. Management of trauma-induced inflammatory root resorption using mineral trioxide aggregate obturation: two-year follow up. *Dent Traumatol.* 2010;26(6):501–504. doi:10.1111/j.1600-9657.2010.00932.x.
  43. Pace R, Giuliani V, Pagavino G. Mineral trioxide aggregate

in the treatment of external invasive resorption: a case report. *Int Endod J.* 2008;41(3):258–266. doi:10.1111/j.1365-2591.2007.01338.x.

44. Perić T, Marković D, Petrović B. Mineral trioxide aggregate

for the treatment of external root resorption in an avulsed immature tooth—ten years of follow-up. *Srp Arh Celok Lek.* 2020;148(3-4):231–235. doi:10.2298/SARH190111103P.