



Comparative Clinical and Functional Results of Microfracture and Mosaicplasty in Medial Talus Osteochondral Lesions

Sönmez Sağlam^{1*}, Mehmet Arıcan¹, Zekeriya Okan Karaduman¹, Mücahid Osman Yücel¹, Raşit Emin Dalaslan¹

¹ Düzce University, Faculty of Medicine, Department of Orthopaedics and Traumatology, Düzce, Türkiye

dr.sonmezsaglam@gmail.com
ari_can_mehmet@hotmail.com
karadumano@hotmail.com
mucahidosmanyucel@gmail.com
redalaslan@gmail.com

* Corresponding Author



Received:
21.07.2024
Accepted:
13.08.2024
Available Online Date:
24.09.2024

Introduction: This study aims to compare the early clinical and functional outcomes of two surgical interventions, microfracture and mosaicplasty, in the treatment of medial talus osteochondral lesions (OCLs).

Materials and Methods: This retrospective study included patients treated in the Department of Orthopaedics and Traumatology, Faculty of Medicine, Düzce University from January 2016 to January 2022. Patients were divided into two groups as those who underwent arthroscopic microfracture (Group 1, n=20) and those who underwent mosaicplasty (Group 2, n=17). Preoperative and postoperative follow-up data were evaluated with visual analogue scale (VAS) and American Orthopaedic Foot and Ankle Society (AOFAS) scores at baseline, 6 months and 12 months.

Results: The mean age was 37.9±12.5 years in the microfracture group and 38±12.46 years in the mosaicplasty group (p=0.981). Both groups showed significant improvement in VAS scores from baseline to the 6th and 12th months, and pain reduction was more significant in the mosaicplasty group (p<0.001). AOFAS scores improved significantly in both groups and the mosaicplasty group had better functional results at 12 months (p=0.069).

Conclusions: Microfracture and mosaicplasty are effective in the treatment of medial talus OCLs to reduce pain and improve clinical status in the early period.

Keywords: Talus, Osteochondral lesions, Microfracture, Mosaicplasty

1. INTRODUCTION

Medial talus osteochondral lesions (OCLs) are characterized by the separation or degeneration of subchondral bone and articular cartilage ^{1,2}. These lesions typically result from trauma and are most commonly observed in the knee joint, with the ankle joint being the second most frequently affected site. Medial talus osteochondral lesions (OCLs) are disruptions of the cartilage and underlying bone, often resulting from trauma and leading to significant pain and impaired joint function. These lesions can progress to osteoarthritis if not addressed promptly. Timely diagnosis and intervention are essential to avert long-term complications. Early management of

talus OCLs is crucial for maintaining joint function, reducing pain, and halting the progression to osteoarthritis. Various treatment options, both conservative and surgical, are available ³⁻⁵.

Surgical options for treating talus OCLs encompass debridement, bone marrow stimulation (microfracture), scaffold implants, autologous chondrocyte implantation, matrix-associated autologous chondrocyte implantation, autologous osteochondral transplantation (mosaicplasty), and allograft transplantation. Among these, microfracture and mosaicplasty are frequently used procedures ^{5,6}.

In the literature, various methods for treating talus OCLs have been examined. The microfracture

technique involves creating small perforations in the subchondral bone to allow bone marrow elements to access the defect area, thereby promoting the formation of new cartilage tissue ⁷. This method is generally recommended for small- to medium-sized lesions and has shown favorable short-term results. However, newly formed fibrocartilage is less durable than native hyaline cartilage in the long term. According to the current recommendations for 2024, the German Society of Orthopedics and Traumatology reported that while microfracture effectively reduces pain in the short term, it fails to maintain cartilage integrity over time ⁸.

Mosaicplasty, on the other hand, involves the transplantation of healthy cartilage and bone from a non-weight-bearing area to the defect site. This technique is typically preferred for larger and deeper lesions and provides results more comparable to those of natural cartilage ⁹. Solheim et al. demonstrated that mosaicplasty yields better long-term outcomes than microfracture in knee cartilage repair ¹⁰. Kılınçcioğlu and Kalacı reported that mosaicplasty, particularly in young and active patients, is superior to microfracture for treating talus OCLs ¹¹.

Despite these findings, most existing studies have focused on knee joints, and specific data on medial talus OCLs are limited. This study aimed to fill this gap by comparing the early clinical and functional outcomes of microfracture and mosaicplasty in treating medial talus OCLs.

2. MATERIALS AND METHODS

The study design was approved by the Düzce University Clinical Research Ethics Committee (Düzce, Türkiye) (No. 2024/138), and the study was performed in accordance with the principles of the Declaration of Helsinki. Informed consent was obtained from the parents or guardians of the patients included in the study.

Study Design and Participants

This retrospective study was conducted at the Orthopedics and Traumatology Department of Düzce University Medical Faculty. Patients who were diagnosed with medial talus osteochondral lesions between January 2016 and January 2022 were reviewed. The study included patients who underwent either microfracture (Group 1, n=20) or mosaicplasty (Group 2, n=17) procedures. The inclusion criteria included complete preoperative and postoperative follow-up data. Patients with incomplete follow-up data, who were diagnosed with diabetic neuropathy, or who developed posttraumatic ankle arthritis were excluded from the study. Figures 1 and 2 illustrate the anteromedial osteochondral lesion of the medial talus with the perioperative application of microfracture and the preoperative and postoperative application of mosaicplasty for an anteromedial osteochondral lesion of the medial talus, respectively.

Figure 1.

Arthroscopic microfracture of an anteromedial osteochondral lesion of the talus

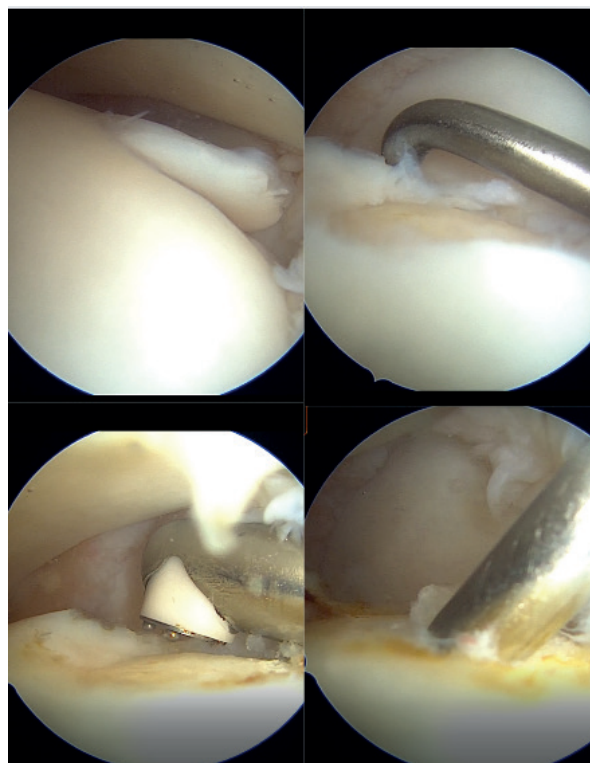
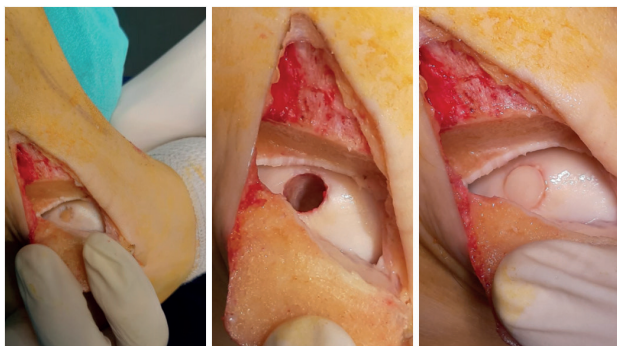


Figure 2.

Mosaicplasty of the anteromedial osteochondroplasty lesion of the talus

**Data collection and evaluation**

Demographic data and clinical outcomes, including visual analog scale (VAS) and American Orthopedic Foot and Ankle Society (AOFAS) scores, were collected at preoperative and postoperative intervals (baseline, 6 months, and 12 months).

VAS score: The VAS score was used to measure pain intensity. It is a 10 cm line anchored by 0 (no pain) and 10 (worst imaginable pain). Patients marked a point on the line that represented their pain level, which was then measured in centimeters.

AOFAS score: The AOFAS score evaluates pain (40 points), function (50 points), and alignment (10 points), with a total possible score of 100. Higher scores indicate better functional status.

Statistical analysis

The statistical analysis was performed using NCSS (Number Cruncher Statistical System) 2007 Statistical Software (Utah, USA). The data distribution was assessed using the Shapiro–Wilk normality test. For normally distributed variables, a paired one-way ANOVA was used for within-group comparisons over time, while the Newman–Keuls multiple comparison test was employed for subgroup analyses. Independent t tests were

utilized for between-group comparisons. For nonnormally distributed variables, the Friedman test was applied for within-group comparisons over time, and Dunn’s multiple comparison test was used for subgroup analyses. The Mann–Whitney U test was used for between-group comparisons. Categorical data were analyzed using the chi-square test. A p value less than 0.05 was considered to indicate statistical significance.

3. RESULTS

The study included 37 patients divided into two groups: the microfracture group (n=20) and the mosaicplasty group (n=17). The demographic and clinical characteristics are summarized in Table 1.

According to Table 2, there were no statistically significant differences in age or sex distributions between the microfracture and mosaicplasty groups (p=0.981, p=0.630). Similarly, no significant differences were observed in terms of side (right/left) or etiology distributions (p=0.666, p=0.302). The mean BMI values were also not significantly different between the two groups (p=0.713). However, the mean symptom duration was significantly greater in the mosaicplasty group than in the microfracture group (p=0.009). The follow-up duration was not significantly different between the two groups (p=0.680).

Table 3 shows that VAS scores at baseline, 6 months, and 12 months were significantly lower in the mosaicplasty group than in the microfracture group (p=0.011, p=0.0001, p=0.001). Both groups showed significant improvements in VAS scores over time (p=0.0001 for both groups). The AOFAS score also improved significantly in both groups, with the mosaicplasty group showing better functional outcomes at the 12-month follow-up (p=0.069).

Table 1.*Demographic and Clinical Characteristics*

Characteristic	Microfracture Group (n=20)	Mosaicplasty Group (n=17)	p value
Age (years)	37.9 ± 12.5	38 ± 12.46	0.981*
Gender			0.630+
Male	11 (55.00%)	8 (47.06%)	
Female	9 (45.00%)	9 (52.94%)	
Side			0.666+
Right	12 (60.00%)	9 (52.94%)	
Left	8 (40.00%)	8 (47.06%)	
Etiology			0.302+
Sprain	4 (20.00%)	2 (11.76%)	
No Trauma	14 (70.00%)	10 (58.82%)	
Sports	2 (10.00%)	5 (29.41%)	
BMI (kg/m ²)	26.65 ± 3.28	27.08 ± 3.68	0.713*
Symptom Duration	9.20 ± 2.55	12.59 ± 4.76	0.009*
Follow-up Duration	28.6 ± 10.89	32 ± 14.35	0.680†
Median (IQR)	25.5 (19.25-35.75)	31 (18.5-47.5)	

*Independent t test, †Mann–Whitney U test, +Chi-square test

Table 2.*VAS and AOFAS Scores*

Score	Microfracture Group (n=20)	Mosaicplasty Group (n=17)	p value
VAS			
Baseline	9.1 ± 0.79	8.12 ± 1.27	0.011†
	Median (IQR)	9 (9-10)	8 (7-9)
6 Months	8.00 ± 1.12	3.82 ± 1.38	0.0001†
	Median (IQR)	8 (7-9)	4 (3-5)
12 Months	3.75 ± 2.25	1.53 ± 1.23	0.001†
	Median (IQR)	4 (2-5)	1 (1-2)
p‡	0.0001	0.0001	
AOFAS			
Baseline	41.3 ± 13.98	38.41 ± 13.13	0.524*
6 Months	75.95 ± 12.1	77.76 ± 13.3	0.667*
12 Months	90.7 ± 7.37	94.59 ± 4.68	0.069*
p*	0.0001	0.0001	

*Independent t test, †Mann–Whitney U test, ‡Friedman test, §Paired one-way ANOVA

Table 3.*Multiple Comparison Tests for VAS and AOFAS Scores*

Comparison	Microfracture Group	Mosaicplasty Group
VAS		
Baseline/6 Months	0.0001	0.0001
Baseline/12 Months	0.0001	0.0001
6 Months/12 Months	0.0001	0.0001
AOFAS		
Baseline/6 Months	0.0001	0.0001
Baseline/12 Months	0.0001	0.0001
6 Months/12 Months	0.0001	0.0001

Table 4.*Changes in the VAS and AOFAS Scores*

Change Difference	Microfracture Group (n=20)	Mosaicplasty Group (n=17)	p value
VAS			
6 Months - Baseline	-1.1 ± 1.02	-4.29 ± 1.11	0.0001
	Median (IQR)	-1 (-2-0)	-4 (-5--3.5)
12 Months - Baseline	-5.35 ± 2.18	-6.59 ± 1.46	0.068
	Median (IQR)	-5 (-7--3.25)	-6 (-7.5--5)
AOFAS			
6 Months - Baseline	34.65 ± 18.45	39.35 ± 16.22	0.432
	Median (IQR)	39 (14-55)	43 (27-55)
12 Months - Baseline	49.4 ± 18.02	56.18 ± 10.68	0.357
	Median (IQR)	54 (29.5-65.25)	59 (53-66)

†Mann–Whitney U test

The Dunn multiple comparison test for VAS scores and the Newman–Keuls multiple comparison test for AOFAS scores indicated significant improvements within both groups over time.

As shown in Table 4, the change in VAS score from baseline to 6 months was significantly greater in the mosaicplasty group than in the microfracture group ($p=0.0001$). However, there was no significant difference between the two groups in terms

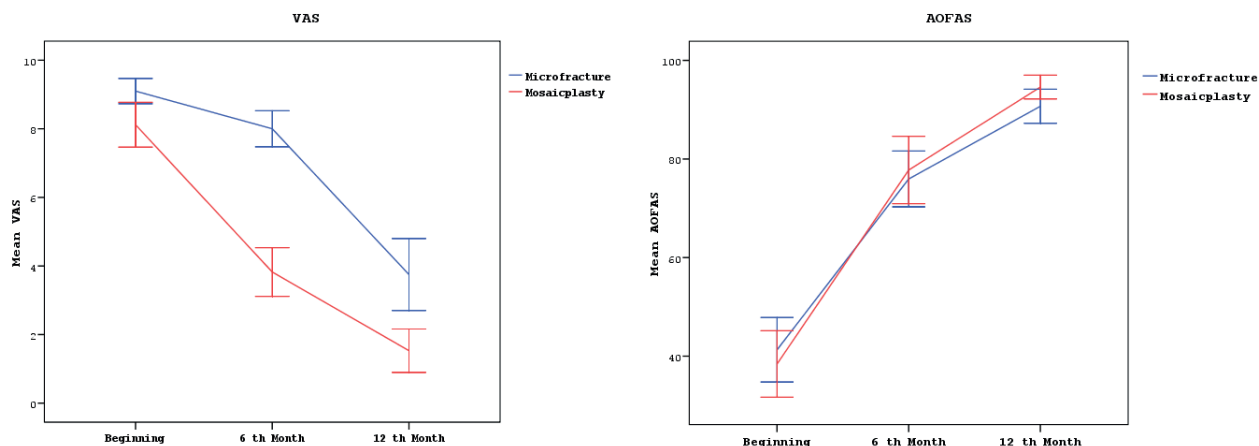
of VAS score change from baseline to 12 months ($p=0.068$). Similarly, there were no significant differences between the groups in the change in AOFAS score from baseline to 6 and 12 months ($p=0.432$, $p=0.357$).

Figure 3 illustrates the changes in the visual analog scale (VAS) and American Orthopedic Foot and Ankle Society (AOFAS) scores over time for the microfracture and mosaicplasty groups. The

graph on the left shows the mean VAS scores at baseline, 6 months, and 12 months, indicating a more significant reduction in pain for the mosaicplasty group than for the microfracture group. The graph on the right presents the mean AOFAS

scores at the same time intervals, demonstrating an improvement in functional outcomes for both groups, with the mosaicplasty group achieving higher scores at 12 months.

Figure 3.
Changes in VAS and AOFAS scores at 6th and 12th months



4. DISCUSSION

The findings of this study provide valuable insights into the comparative effectiveness of microfracture and mosaicplasty in the treatment of medial talus osteochondral lesions (OCLs). Our study highlights the comparative effectiveness of microfracture and mosaicplasty in treating medial talus osteochondral lesions. Both techniques showed significant improvements in pain and function; however, mosaicplasty demonstrated superior outcomes in several areas, suggesting its potential as a more effective long-term treatment, especially for larger lesions. Both surgical interventions demonstrated significant improvements in pain and functional outcomes over time; however, mosaicplasty showed superior results in several key areas, suggesting that it may be a more effective long-term treatment option for certain patients.

in the mosaicplasty group compared to the microfracture group at 6 and 12 months indicates that mosaicplasty may offer better pain relief for patients with medial talus OCLs. Similarly, in the literature, mosaicplasty provides better long-term pain management than does microfracture of the joint ^{12,13}. This finding may be attributed to the ability of mosaicplasty to create a more durable and congruent cartilage surface ¹⁴.

Both groups showed significant improvements in the AOFAS score; however, the mosaicplasty group demonstrated better functional outcomes at 12 months. This suggests that mosaicplasty may be more effective not only for pain management but also for preserving and enhancing joint function. Kılınçcioğlu and Kalacı ¹¹ also noted that mosaicplasty yielded superior outcomes, particularly in young and active patients.

The significant reduction in VAS scores observed

Other studies in the literature support these

findings^{15,16}. Guney et al.¹⁷ indicated that mosaicplasty is more successful for larger and deeper lesions and promotes faster patient recovery. Similarly, Mukai et al. reported that mosaicplasty is more effective than microfracture in maintaining cartilage integrity and improving long-term joint function^{18,19}.

Pallamar et al. evaluated different surgical procedures for treating atraumatic osteochondrosis dissecans in young and adolescent patients²⁰. They found that advanced fixation and reconstruction procedures resulted in lower clinical scores and a greater incidence of joint degeneration than did drilling procedures applied for stable lesions. This highlights the advantages of mosaicplasty in terms of stabilization and functional recovery.

Kim et al. investigated the long-term outcomes of arthroscopic microfracture in talar osteochondral lesions and reported that symptomatic improvement was maintained for up to three years²¹. This suggests that while microfracture is effective initially, its results may stabilize over the long term. Additionally, Rikken et al. emphasized that microfracture is more effective for smaller and superficial lesions, whereas larger and deeper lesions should preferably be treated with mosaicplasty²².

This study has several limitations. First, it was designed as a retrospective study, which does not provide as strong evidence as prospective, randomized controlled trials. Additionally, the sample size was relatively small, limiting the generalizability of the findings. The follow-up period was also short, providing limited information on long-term outcomes. Future studies with larger sample sizes and longer follow-up periods are needed to confirm and expand upon these findings.

5. CONCLUSION

In conclusion, this study demonstrated the comparative effectiveness of microfracture and mosaicplasty in the surgical treatment of medial talus OCLs that do not heal with conservative treatment. Although mosaicplasty provides clinically and functionally better results than microfracture, both treatments have been shown to be beneficial in the early period. However, more research is needed to confirm and extend these findings. Future studies should focus on different patient populations and longer follow-up periods to provide more comprehensive information about the effectiveness of these two methods.

Funding

The authors received no financial support for the research and/or authorship of this article.

Conflict of Interest

The authors declare no conflicts of interest with respect to the authorship and/or publication of this article.

Ethics Committee Approval

The study protocol was approved by the local ethics committee (No: 2024/138). The study was conducted in accordance with the principles of the Declaration of Helsinki.

Author Contributions

SS, MA, MOY and ZOK contributed to the analysis and interpretation of the data and to the writing and revision of the manuscript. SS and MA performed the surgical operations. ZOK, RED, MOY and SS contributed to data analysis, interpretation and writing. RED and MOY contributed to data collection, analysis and methodology. ZOK, MA, SS and RED contributed to experimental design, data collection and data revision.

REFERENCES

- Kekeç AF, Yıldırım A. Mid-term results of autologous matrix-induced chondrogenesis surgery with or without scaffolds for arthroscopic treatment of deep talus osteochondral lesions: A comparative study. *Jt Dis Relat Surg.* 2023;34(3):613-619. doi:10.52312/jdrs.2023.1197
- Butler J, Hartman H, Dhillon R, et al. Outcomes Following the Use of Extracellular Matrix Cartilage Allograft for the Management of Osteochondral Lesions of the Talus: A Systematic Review. *Cureus.* 2024;16(6). doi:10.7759/cureus.62044
- Altomare D, Di Matteo B, Kon E. Conservative Treatment for Ankle Cartilage: Cellular and Acellular Therapies: A Systematic Review. *Foot Ankle Clin.* 2024;29(2):253-263. doi:10.1016/j.fcl.2023.07.003
- van Diepen PR, Smithuis FF, Hollander JJ, et al. Reporting of Morphology, Location, and Size in the Treatment of Osteochondral Lesions of the Talus in 11,785 Patients: A Systematic Review and Meta-Analysis. *Cartilage.* 2024;19476035241229026. doi:10.1177/19476035241229026
- Yasui Y, Miyamoto W, Shimozone Y, Tsukada K, Kawano H, Takao M. Evidence-Based Update on the Surgical Technique and Clinical Outcomes of Retrograde Drilling: A Systematic Review. *Cartilage.* 2024;19476035241239303. doi:10.1177/19476035241239303
- Zhang J, Zheng K, Cai W, Huang X, Li Q. Influence of Subchondral Cysts on the Outcomes of Surgical Treatment for Osteochondral Lesions of the Talus: A Systematic Review and Meta-analysis. *Orthop J Sports Med.* 2024;12(2):23259671241226719. doi:10.1177/23259671241226719
- Chen XQ, Liu J, Wang T, et al. Comparative analysis of short-term efficacy between robot-assisted retrograde drilling and arthroscopic microfracture for osteochondral lesions of the talus. *Front Surg.* 2024;11:1404513. doi:10.3389/fsurg.2024.1404513
- Walther M, Gottschalk O, Aurich M. Operative management of osteochondral lesions of the talus: 2024 recommendations of the working group 'clinical tissue regeneration' of the German Society of Orthopedics and Traumatology (DGOU). *EFORT Open Rev.* 2024;9(3):217-234. doi:10.1530/eor-23-0075
- Merritt G, Epstein J, Roland D, Bell D. Fresh osteochondral allograft transplantation (FOCAT) for definitive management of a 198 square millimeter osteochondral lesion of the talus (OLT): A case report. *Foot (Edinb).* 2021;46:101639. doi:10.1016/j.foot.2019.09.001
- Solheim E, Hegna J, Inderhaug E. Long-Term Survival after Microfracture and Mosaicplasty for Knee Articular Cartilage Repair: A Comparative Study Between Two Treatments Cohorts. *Cartilage.* 2020;11(1):71-76. doi:10.1177/1947603518783482
- Kılınçcioğlu N, Sr., Kalacı A. The Comparison of the Results of Microfracture and Mosaicplasty in Talus Osteochondral Lesions. *Cureus.* 2024;16(5). doi:10.7759/cureus.61217
- Amouyel T, Barbier O, De L'Escalopier N, et al. Higher preoperative range of motion is predictive of good mid-term results in the surgical management of osteochondral lesions of the talus: A prospective multicentric study. *Knee Surg Sports Traumatol Arthrosc.* 2023;31(8):3044-3050. doi:10.1007/s00167-022-06876-w
- Zhang L, Luo Y, Zhou X, Fu S, Wang G. Outcomes from Osteochondral Autograft Transplant or Mosaicplasty in 26 Patients with Type V Osteochondral Lesions of the Talus. *Med Sci Monit.* 2021;27. doi:10.12659/msm.930527
- Matthews JR, Sonnier JH, Paul RW, et al. A systematic review of cartilage procedures for unstable osteochondritis dissecans. *Phys Sportsmed.* 2023;51(6):497-505. doi:10.1080/00913847.2022.2082262
- Lopes R, Amouyel T, Benoist J, et al. Return to sport after surgery for osteochondral lesions of the talar dome. Results of a multicenter prospective study on 58 patients. *Orthop Traumatol Surg Res.* 2023;109(8s):103675. doi:10.1016/j.otsr.2023.103675
- de l'Escalopier N, Amouyel T, Mainard D, et al. Long-term outcome for repair of osteochondral lesions of the talus by osteochondral autograft: A series of 56 Mosaicplasties®. *Orthop Traumatol Surg Res.* 2021;107(8s):103075. doi:10.1016/j.otsr.2021.103075
- Guney A, Yurdakul E, Karaman I, Bilal O, Kafadar IH, Oner M. Medium-term outcomes of mosaicplasty versus arthroscopic microfracture with or without platelet-rich plasma in the treatment of osteochondral lesions of the talus. *Knee Surg Sports Traumatol Arthrosc.* 2016;24(4):1293-8. doi:10.1007/s00167-015-3834-y
- Anders S, Götz J, Grifka J, Baier C. [Ankle cartilage repair: Therapeutic options, results and technical aspects]. *Orthopade.* 2017;46(11):938-946. Knorpelreparative Eingriffe am oberen Sprunggelenk: Therapieoptionen, Ergebnisse und technische Aspekte. doi:10.1007/s00132-017-3470-y
- Mukai S, Nakagawa Y, Nishitani K, Sakai S, Nakamura R, Takahashi M. Mosaicplasty With High Tibial Osteotomy for Knee Subchondral Insufficiency Fracture Had Better Magnetic Resonance Observation of Cartilage Repair Tissue Scores With Less Bone Marrow Edema and Better Plug Union and Less Plug Necrosis Compared With Mosaicplasty Alone. *Arthroscopy.* 2023;39(2):337-346. doi:10.1016/j.arthro.2022.07.020
- Pallamar M, Eder T, Ganger R, Farr S. Surgical treatment of atraumatic osteochondritis dissecans of the immature talus-Clinical results and prevalence of radiographic joint degeneration after a median follow-up of 72.5 months. *Foot Ankle Surg.* 2022;28(5):557-563. doi:10.1016/j.fas.2021.05.007

21. Kim TY, Song SH, Baek JH, Hwang YG, Jeong BO. Analysis of the Changes in the Clinical Outcomes According to Time After Arthroscopic Microfracture of Osteochondral Lesions of the Talus. *Foot Ankle Int.* 2019;40(1):74-79. doi:10.1177/1071100718794944
22. Rikken QGH, Dahmen J, Stufkens SAS, Kerkhoffs G. Satisfactory long-term clinical outcomes after bone marrow stimulation of osteochondral lesions of the talus. *Knee Surg Sports Traumatol Arthrosc.* 2021;29(11):3525-3533. doi:10.1007/s00167-021-06630-8