



Infantile Intraparenchymal Brain Abscess due to *Streptococcus pyogenes*

Streptococcus pyogenes'e Bağlı İnfantil İntraparankimal Beyin Apresi

¹Meltem Kıymaz¹, ¹Gülsüm Alkan¹, ¹Büşra Özyalvaç¹, ¹Ayşe Gül Yücel¹, ¹Mehmet Öztürk²,
³Saime Sündüs Uygun³, ³Murat Konak³, ³Derya Karaoğlu Gündoğdu⁴, ³Melike Emiroğlu¹

¹Selcuk University School of Medicine Department of Pediatrics, Division of Pediatric Infectious Disease, Konya, Türkiye

²Selcuk University School of Medicine Department of Radiology, Division of Pediatric Radiology, Konya, Türkiye

³Selcuk University School of Medicine Department of Pediatrics, Division of Neonatology, Konya, Türkiye

⁴Selcuk University School of Medicine Department of Brain and Nerve Surgery (Neurosurgery), Konya, Türkiye

ABSTRACT

Group A β -hemolytic streptococcus (GABHS) are the most common bacterial cause of tonsillitis, and can cause noninvasive diseases such as pharyngitis and impetigo, as well as more severe invasive diseases. The incidence of invasive disease is 1-3/100,000 per year, and the morbidity and mortality rate is high. GABHS is rarely lead to brain abscesses. Acute phase reactants were found to be high in a 40-day-old patient who presented with fever, irritability and focal seizures. Acute phase reactants were high. Transfontanel ultrasonography showed increased thickness, echo and blood supply in the meninges. Brain magnetic resonance imaging (MRI) and diffusion MRI revealed a thick-walled abscess in the right cerebral hemisphere and parietooccipital parenchyma with diffusion restriction on diffusion-weighted images. Cerebrospinal fluid (CSF) polymerase chain reaction (PCR) test revealed *S. pyogenes*, and *S. pyogenes* grown in CSF culture. Initially, meropenem, vancomycin, metronidazole antibiotherapy was applied. Treatment was revised to cefotaxime and vancomycin after culture antibiogram and was completed for 8 weeks. Seizures regressed. Control brain imaging showed improvement. Restriction in left lower extremity movements remained. Physical therapy and rehabilitation was recommended and he was discharged. GABHS, which is the causative agent of acute tonsillitis, rarely causes invasive disease which has high mortality and morbidity.

Keywords: *Streptococcus pyogenes*, brain abscess, infant, meningitis, encephalitis

ÖZ

A grubu beta hemolitik streptokoklar (AGBHS) tonsillofarenjitin en sık bakteriyel etkenidir, farenjit ve impetigo gibi noninvaziv hastalıklardan, daha ağır seyirli invaziv enfeksiyonlara neden olabilmektedir. İnvaziv hastalık insidansı yılda 1-3/100.000'tür, morbidite ve mortalite oranı yüksektir. AGBHS'lar nadiren beyin apselerine yol açabilir. Ateş, irritabilite ve fokal nöbet ile başvuran 40 günlük hastanın akut faz reaktanları yüksek bulundu. Transfontanel ultrasonografisinde meninkslerde kalınlık, eko ve kanlanma artışı izlendi. Beyin manyetik rezonans görüntüleme (MRG) ve difüzyon MRG'de sağ serebral hemisferde, parietookspital parankimde kalın duvarlı, difüzyon ağırlıklı görüntülerde difüzyon kısıtlılığı bulunan, apse saptandı. Beyin omurilik sıvısı (BOS) polimeraz zincir reaksiyonu testinde *S. pyogenes* saptanırken, BOS kültüründe *S. pyogenes* üredi. Ampirik başlanan meropenem, vankomisin, metronidazol kültür antibiyogram sonrası sefotaksim ve vankomisin olarak 8 haftaya tamamlandı. Nöbetleri geriledi, kontrol beyin görüntülemesinde iyileşme izlendi. Sol alt ekstremitte hareketlerinde kısıtlılık kalan hasta fizik tedavi ve rehabilitasyon önerileri ile taburcu edildi. Akut tonsillofarenjit etkeni olan AGBHS'lar nadiren mortalitesi ve morbiditesi yüksek olan invaziv hastalığa yol açabilmektedir.

Anahtar Kelimeler: *Streptococcus pyogenes*, beyin absesi, infant, menenjit, ensefalit

INTRODUCTION

Group A beta-hemolytic streptococci (GABHS) typically cause tonsillopharyngitis in children aged 5-15 years, presenting with fever, exudate, lymphadenopathy (LAP), crypts, and pharyngeal hyperemia, sometimes accompanied by a scarlatiniform rash. However, in children under three years old, streptococcosis with fever, nasopharyngeal hyperemia, nasal discharge, and anterior cervical LAP is less common (1,2). GABHS tonsillopharyngitis in infants is less frequent due to the

presence of specific transplacental antibodies from the mother and the absence of streptococcal receptors in the pharynx (3,4). The incidence of brain abscesses is quite low, reported as 0.3-1.8/100,000 (5). Generally, about 25% of brain abscesses occur in children (6). It has been reported to be more common in the male population (6).

In this article, with family consent, we will discuss a brain abscess due to GABHS in a 40-day-old infant.

Corresponding Author: Meltem Kıymaz

Address: Selcuk University School of Medicine Department of Pediatrics, Division of Pediatric Infectious Disease, Konya, Turkey

E-mail: mkiymaz91@gmail.com

Başvuru Tarihi/Received: 11.08.2024

Kabul Tarihi/Accepted: 28.10.2024





CASE REPORT

A 40-day-old male patient with no known diseases and no significant features in his prenatal, natal, and postnatal history other than being consistent with 33 weeks gestation, was admitted to the hospital with fever and nasal discharge that had started one day earlier. The patient, who had a bulging fontanelle, was referred to our hospital after receiving a single intravenous dose of ceftriaxone. There was no history of trauma or drug exposure. On initial examination, irritability, "setting sun" eye sign, bulging and tension in the anterior fontanelle were present. Cutis marmoratus and prolonged capillary refill time were observed. Focal seizures in the left arm were noted during follow-up.

The patient's laboratory tests revealed a white blood cell count of 22,960/ μ L (4800-14600/ μ L), absolute lymphocyte count of 5520/ μ L (2500-9000/ μ L), absolute neutrophil count of 16210/ μ L (800-5400/ μ L), C-reactive protein 190 mg/L (0-5 mg/L), erythrocyte sedimentation rate 33 mm/hour (0-18 mm/hour), and procalcitonin 34.4 μ g/L (0-0.5 μ g/L).

Transfontanelle ultrasonography reported normal cerebral, cerebellar, and ventricular systems and midline structures, with no hydrocephalus, hemorrhage, cystic or solid lesions, but increased thickness, echogenicity, and vascularity in the meninges. Due to continuing focal seizures, brain MRI and diffusion MRI were performed. In the supratentorial sections, an intra-axial space-occupying lesion measuring 24×25×55 mm was observed in the right cerebral hemisphere, in the parietooccipital parenchyma, with intense peripheral edema, thick-walled, peripheral contrast enhancement, diffusion restriction in the wall and central part on diffusion-weighted images, opening into the right lateral ventricle (**Figure 1**).

The patient was admitted to the neonatal intensive care unit with a preliminary diagnosis of abscess, and abscess drainage was performed. The cerebrospinal fluid (CSF) taken during surgery was cloudy, with an uncountable number of neutrophils observed. CSF glucose was <2 mg/dL, and CSF microprotein (as this parameter could be studied in our hospital) was 562 mg/dL. The patient was empirically started on meropenem, vancomycin, and metronidazole to cover possible polymicrobial agents in brain abscesses. *S. pyogenes* was detected positive in the viral bacterial meningitis multiplex PCR panel and CSF culture. Although penicillin-sensitive in the culture antibiogram, the treatment was revised to vancomycin and cefotaxime as resistant seizures continued.

Due to residual abscess observed in the brain MRI taken in the 1st month of treatment, intravenous (IV) antibiotherapy was completed to 8 weeks. Despite surgery and IV antibiotherapy, focal seizures were initially resistant, and four antiepileptics were gradually increased in consultation with pediatric neurology.

Until discharge, antiepileptic drugs were gradually reduced following a decrease in seizures. Additionally, persistent lymphocytosis was observed that could not be explained by other causes. The patient was consulted with pediatric immunology. Anti-HIV was negative, immune globulin (Ig) G 695 mg/dL (376-685 mg/dL), IgA 111 mg/dL (9-30 mg/dL), IgM 79 mg/dL (36-77 mg/dL), and peripheral lymphocyte subgroups were normal. Whole exon analysis was sent for natural immune system defects, which has not yet been resulted. Immunoglobulin replacement therapy was given every 21 days for 6 months and then stopped. The patient was discharged with recommendations for physical therapy and rehabilitation due to remaining limitations in left lower extremity movements.

DISCUSSION

GABHS are gram-positive bacteria that can cause noninvasive diseases such as pharyngitis and impetigo, as well as invasive infections and complications such as necrotizing fasciitis, abscess, bacteremia, and toxic shock syndrome (7).

GABHS are the most common bacterial cause of tonsillopharyngitis. It is common in children between 5-15 years old. It can lead to primary suppurative infections in the skin and soft tissue, and late complications such as acute rheumatic fever and acute poststreptococcal glomerulonephritis. Less frequently, it can cause necrotizing fasciitis, bacteremia, streptococcal toxic shock syndrome, puerperal sepsis, pneumonia, and meningitis (2). The incidence of invasive disease is 1-3/100,000 per year (7). In a study including 10 patients with invasive GABHS infection, 40% had bacteremia, 30% had complicated pneumonia, 10% had deep neck abscess, 10% had complicated sinusitis with frontal abscess, and 10% had streptococcal toxic shock syndrome. The pathogen was isolated from blood culture in 50% of patients, throat culture in 30%, abscess culture in 30%, and pleural fluid culture in 20% (7). In our patient, GABHS growth was detected in both CSF and abscess cultures.

Invasive GABHS infections are associated with high morbidity and mortality. Central nervous system involvement is rare, accounting for only 0.2-1% of all childhood bacterial meningitis cases (8). They found the rate of GAS meningitis in the pediatric age group to be 0.06/100,000 (9). Group A streptococcal meningitis is extremely rare in the neonatal period. In one study, GABHS was isolated from both blood and cerebrospinal fluid cultures of a 24-day-old baby presenting with fever, poor feeding, and focal seizures. The patient, treated with penicillin G for 14 days, developed tetraventricular hydrocephalus and hearing loss (10). In our patient, brain abscess accompanied meningitis.

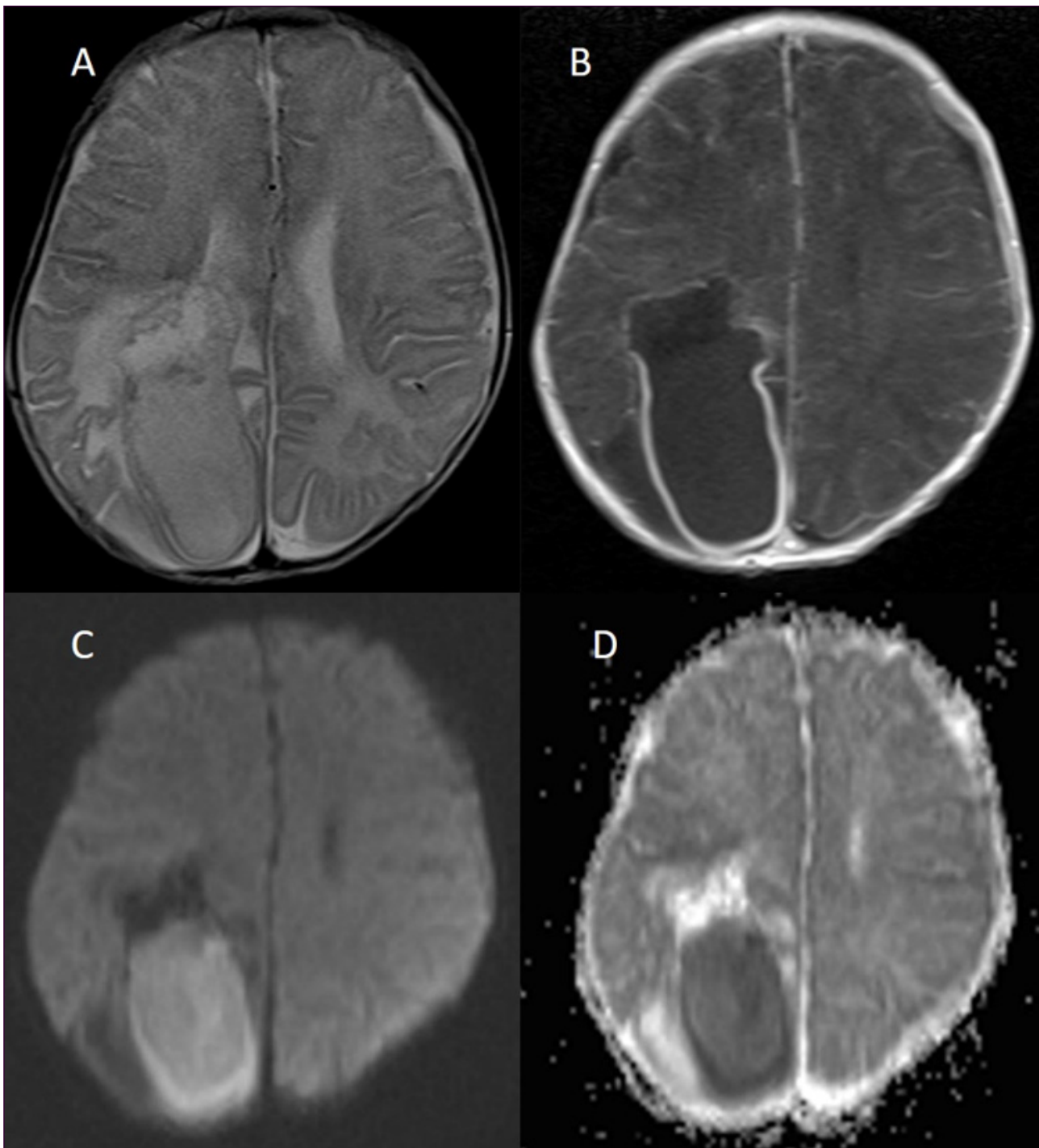


Figure 1. A-D: In the parieto-occipital parenchyma in the right cerebral hemisphere, a thick-walled lesion compatible with an abscess is observed, accompanied by intense peripheral edema located intra-axially, T2W hyperintense (A), showing peripheral contrast enhancement (B), and diffusion restriction on diffusion-weighted images (C, D).

Brain abscesses describe abscesses and empyemas in the brain parenchyma or subdural and epidural spaces (13). They are rare but have high mortality if diagnosis and treatment are delayed (11). The incidence of brain abscesses has been reported as 0.3-1.8/100,000 (5). One study reported a mortality rate of 10.7% (12). Generally, about 25% of brain abscesses occur in children. It has been reported to be more common in the male

population (6). The pathogen reaches the brain through hematogenous spread, direct invasion from adjacent tissues, penetration, or inoculation of the pathogen during surgical procedures (13). Otitis media, mastoiditis, trauma, meningitis due to ventriculoperitoneal shunt are predisposing factors for brain abscesses (11). One study reported previous pneumonia, tetralogy of Fallot, infective endocarditis on the basis of tetralogy of Fallot,



acute lymphoblastic leukemia, orbital cellulitis, and brucellosis as predisposing factors. Primary or secondary immunodeficiency is another risk factor for brain abscess development (14). No predisposing factor was detected in our patient.

Initially, clinical findings may be subtle. Different findings can be detected depending on the location of the abscess. Headache, fever, neurological findings, and vomiting are common (19). The classic triad is headache, fever, and focal neurological findings. These findings can be seen in 9-28% of children (6). Our patient was not old enough to express headache, but had fever, irritability, focal seizures, "setting sun" eye sign, and bulging and tension in the anterior fontanelle.

In our case, *S. pyogenes* was detected positive in CSF-PCR and grew in CSF culture. In a series reporting 107 cases with brain abscesses, 64.7% streptococci (11.8% GABHS), 38.1% *Proteus* spp., 30% *Staphylococcus aureus*, and 4.8% *Citrobacter freundii* were reported as causative agents (12). In another study of 75 cases with brain abscesses, *S. aureus* and *Streptococcus viridans* were isolated from 5 patients each (6.7%), polymicrobial pathogens from 3 patients (4%), *Proteus mirabilis*, *Streptococcus constellatus*, *Streptococcus pneumoniae*, *Peptostreptococci*, and *Peptococcus niger* from 3 patients each (4%), coagulase-negative staphylococci, *Streptococcus anginosus*, *Klebsiella* spp., *Ekinella* spp., *Fusobacterium* spp., *Bacteroides* spp., and *Aspergillus* spp. from 2 patients each (2.7%), and from 1 patient each (1.3%) (20). In a study of 89 children presenting with brain abscess, 14.6% *S. aureus*, 13.5% *S. pneumoniae*, 9% coagulase-negative staphylococci, 6.7% each of *S. viridans* and *Bacteroides* spp., 5.6% each of *Klebsiella pneumoniae* and *P. niger*, 4.5% *Fusobacterium* spp., 3.4% each of *P. mirabilis* and *Peptostreptococcus*, 1.1% MRSA were detected (21). In a study including 41 children with brain abscesses, GABHS was not isolated from either CSF or abscess cultures in any of the patients (22).

GABHS is extremely sensitive to bactericidal beta-lactam antibiotics. However, clinical failures have been reported with penicillin treatment alone in patients with invasive GABHS infections (23,24). Data from observational studies have found treatment with a beta-lactam + clindamycin to be more effective than beta-lactam alone (25,26). However, clindamycin has poor CSF penetration, so a combination of linezolid (CSF/blood ratio approximately 60-70%), which has better CSF penetration, with beta-lactam antibiotics (penicillin or 3rd generation cephalosporins) is recommended (27). There are no clinical studies reporting the optimal duration of antibiotic treatment, and the duration of antibiotic treatment should be determined according to the patient (25). In addition to IV antibiotherapy, surgical intervention also plays an important role in treatment (26). In our patient, who underwent early-stage surgery,

meropenem, vancomycin, and metronidazole treatment were given until the causative agent was identified, and then treatment was completed with cefotaxime and vancomycin. In a case report of a sixteen-year-old patient with a brain abscess, the abscess did not shrink in the second week of cefotaxime, vancomycin and metronidazole treatment, so the treatment was revised to meropenem, vancomycin and metronidazole treatment, and it was reported that the abscess shrank after a total of 9 weeks of treatment (28)

Delays in diagnosis, IV treatment, or surgical intervention cause morbidity and mortality. One study reported reasons for delayed treatment initiation as misinterpretation of images, failure to perform imaging in a timely manner, the need for imaging as an indication for surgical intervention, or clinician preference (29). While only meningeal thickening was noted in our patient's cranial USG, an abscess was detected by MRI.

CONCLUSION

GABHS, which is the causative agent of acute tonsillopharyngitis, can rarely lead to invasive disease with high mortality and morbidity. GABHS should be kept in mind as a causative agent in brain abscesses. Brain MRI and CSF culture play an important role in diagnosis. The total duration of treatment should be determined according to the patient's response to treatment.

ETHICAL DECLARATIONS

Informed Consent: Written informed consent was obtained from all participants who participated in this study.

Referee Evaluation Process: Externally peer-reviewed.

Conflict of Interest Statement: The authors have no conflicts of interest to declare.

Financial Disclosure: The authors declared that this study has received no financial support.

Author Contributions: All of the authors declare that they have all participated in the design, execution, and analysis of the paper, and that they have approved the final version.

REFERENCES

1. Kaplan LE, Krugman S. Streptococcal infections group A. In: Krugman S, Katz LS, Gershon AA, Wilfert MC, editors. Infectious diseases of children. 9th edition St. Louis, Missouri: Mosby;1992. p. 483-94.
2. Kızılyıldırım, S. İnvaziv A grubu streptokok enfeksiyonlarından sorumlu suşlarda emm ve süperantijen genotiplerinin dağılımı, klinik korelasyonu ve filogenetik ilişkilerinin tespiti. [Doktora tezi]. Adana: Çukurova Üniversitesi, Sağlık Bilimleri Enstitüsü, 2017.
3. Committee on infectious diseases, American Academy of Pediatrics. Group A streptococcal infections. In: Peter G, editors. Red book report of the committee on infectious diseases. 24th edition, 1997:483-94.

4. Todd J. Streptococcal infections. In: Nelson WE, Behrman RE, Kliegman RM, Arvin AM, editors. Nelson Textbook of Pediatrics 15th ed. Philadelphia: WB Saunders; 1996:750-4.
5. Mameli C, Genoni T, Madia C et al. Brain abscess in pediatric age: a review. Childs Nerv Syst. 2019;35(7):1117-28.
6. Shachor-Meyouhas Y, Bar-Joseph G, Guilburd JN, et al. Brain abscess in children - epidemiology, predisposing factors and management in the modern medicine era. Acta Paediatr 2010; 99(8):1163-7.
7. Laleoğlu P, Erbaş İ, Özdem Alataş Ş, et al. "İnvaziv Grup A Streptokok Tanılı Çocuk Olgularının Klinik Seyir ve Sonuçlarının Değerlendirilmesi," 16. Çocuk Enfeksiyon Hastalıkları ve Bağışıklama Kongresi, Antalya, Türkiye, pp.1, 2023.
8. Hutton D, Kameda-Smith M, Afshari FT, et al. Intracranial invasive group A streptococcus: a neurosurgical emergency in children. J Neurosurg Pediatr. 2023;32(4):478-87.
9. de Almeida Torres RS, Fedalto LE, de Almeida Torres RF, et al. Group A streptococcus meningitis in children. Pediatr Infect Dis J. 2013;32(2):110-4.
10. Annagür A, Altunhan H, Ertugrul S, et al. A rare cause of neonatal meningitis: Group A streptococci. Dicle Tıp Dergisi. 2013;40(1):118-20.
11. Gezercan Y, Çavuş G, Ökten Aİ, et al. Çocukluk çağı beyin abseleri: tek merkez deneyimi. Cukurova Medical Journal, 2017;42(3):427-35.
12. Auvichayapat N, Auvichayapat P, Aungwarawong S. Brain abscess in infants and children: a retrospective study of 107 patients in northeast Thailand. J Med Assoc Thai. 2007;90(8):1601.
13. Sheehan JP, Jane JA, Ray DK, et al. Brain abscess in children. Neurosurg Focus. 2008; 24(6):E6.
14. Demirören K, Gülşen İ, Ece İ et al. Çocuklarda intrakraniyal apse. Van Tıp Dergisi. 2015;22(2):67-72.
15. Shetty AK, Frankel LR, Maldonado Y, et al. Group A streptococcal meningitis: report of a case and review of literature since 1976. Pediatr Emerg Care. 2001;17:430-4.
16. Akar A, Kuyucu N. Üç yaşından küçük çocuklarda A Grubu B-Hemolitik Streptokok tonsillofarenjiti sıklığı. Mersin Üniversitesi Sağlık Bilimleri Derg. 2018;11(3):332-5.
17. Tamer İ, Fenercioğlu A, Dabak R. İstanbul Kartal bölgesinde Okul Öncesi Çocuklarda Asemptomatik A Grubu Beta Hemolitik Streptokok Taşıyıcılığı. Türk Aile Hek Derg. 2008;12:203-6.
18. Shaikh N, Leonard E, Martin JM. Prevalence of streptococcal pharyngitis and Streptococcal carriage in children: a meta-analysis. Pediatrics. 2010;126:e557-64.
19. Shahzad K, Hamid MH, Khan MA, et al. Brain abscess in children. J Coll Physicians Surg Pak. 2005;15(10):609-11.
20. Özsüreki Y, Kara A, Cengiz AB, et al. Brain abscess in childhood: a 28-year experience. Turk J Pediatr. 2012;54(2):144.
21. Kanu OO, Ojo O, Esezobor C et al. Pediatric brain abscess - etiology, management challenges and outcome in Lagos Nigeria. Surg Neurol Int. 2021;8(12):592.
22. Miniar T, Amel BA, Khalil S, et al. Pyogenic brain abscess in children: a Tunisian multi-center experience. Afr Health Sci. 2018;18(3):560-8.
23. Stevens DL. Invasive group A streptococcus infections. Clin Infect Dis 1992;14:2-13.
24. Zimbelman J, Palmer A, Todd J. Improved outcome of clindamycin compared with beta-lactam antibiotic treatment for invasive *Streptococcus pyogenes* infection. Pediatr Infect Dis J. 1999;18:1096-100.
25. Stevens DL. Invasive group A streptococcal infection and toxic shock syndrome: Treatment and prevention. In: Edwards MS, Wessels MR, Hall KK, editors. Available from: <https://www.uptodate.com/contents/invasive-group-a-streptococcal-infection-and-toxic-shock-syndrome-treatment-and-prevention?> (Accessed date: 02.22.2023).
26. Stevens DL, Kaplan SL. Invasive group A streptococcal infections in children. In: Edwards MS, Armsby C, editors. Available from: <https://www.uptodate.com/contents/invasive-group-a-streptococcal-infections-in-children?> (Accessed date: 02.22.2023).
27. UpToDate. Linezolid: Drug information. Available from: <https://www.uptodate.com/contents/linezolid-drug-information?> (Accessed date: 02.25.2023).
28. Kara Y. A case of pediatric brain abscess secondary to rhinosinusitis. J Contemp Med. 2024;14(4):213-4.
29. Lundy P, Kaufman C, Garcia D, et al. Intracranial subdural empyemas and epidural abscesses in children. J Neurosurg Pediatr. 2019;24(1):14-21