

# A rare case of bilateral Preiser's disease originating from the distal pole of the scaphoid

Shikhali Isgandarli<sup>1</sup>, Cengiz Çabukoğlu<sup>1</sup>, Berk Özer Şensoy<sup>2</sup>

<sup>1</sup>Department of Orthopaedics and Traumatology, Central Hospital Kozyatağı, İstanbul, Türkiye; <sup>2</sup>Okan University, Faculty of Medicine, İstanbul, Türkiye

## ABSTRACT

The scaphoid bone – os naviculare manus – is an important bone in that it is located within the proximal row of carpal bones and articulates with both the radius and other carpal bones. Preiser's disease is a rare entity and is commonly associated with avascular necrosis of the scaphoid without fracture or trauma. This case study describes a 55-year-old female patient who visited our outpatient clinic complaining of five months' worth of pain and swelling on both of her wrists. The patient had no history of trauma or prolonged steroid use. The patient had pain around the thenar region and anatomical snuff box on both wrists. On a 2-directional wrist radiograph, the distal part of the scaphoid bone showed signs of subchondral sclerosis. Magnetic Resonance Imaging (MRI) was performed to verify the diagnosis. MRI of the patient's wrist revealed bone edema at the distal pole of the scaphoid which was associated with Preiser's disease. In this case study, we present a patient who had bilateral Preiser's illness that began at the distal pole.

**Keywords:** Preiser's disease, non-traumatic, bilateral, scaphoid edema, distal pole

Preiser's disease is a rare condition and is commonly associated with avascular necrosis of the scaphoid and repetitive microtraumas are thought to play a role in its pathophysiology [1]. In 1910, Preiser described a "rarefying osteitis" of the scaphoid in a series of 5 cases. He thought that the cause of this condition was an interruption of the scaphoid blood supply at the scaphotrapezium area, which led to central rarefaction, and the fractures were probably secondary [2]. According to radiography and Computerised Tomography (CT) scan pictures, Herbert and Lanzetta [3] classified patients in 1994. Later, Moran [4] *et al.* added signals from MRI images to this categorization, further developing it.

Extrinsic factors such as corticosteroid therapy, al-

coholism, trauma, and repetitive microtrauma along with intrinsic factors like genetics are believed to contribute to the pathogenesis of Preiser's disease, affecting the coagulation and fibrinolysis processes leading to ischemia and consequently a bone infarct [5]. Restoring the wrist joint range of motion, reducing pain, and delaying the onset of arthritis are the main goals of treatment.

Pain in the radial compartment of the wrist, swelling, and decreased range of motion are always present in Preiser's disease [1, 5]. An early diagnosis is challenging with radiographs. Therefore when a diagnosis is suspected, an MRI is performed [5, 6].

When a section of the proximal pole of the scaphoid and the adjacent subchondral bone separates,

**Corresponding author:** Shikhali Isgandarli, MD.,  
Phone: +90 444 7 799, E-mail: [shixali448@gmail.com](mailto:shixali448@gmail.com)

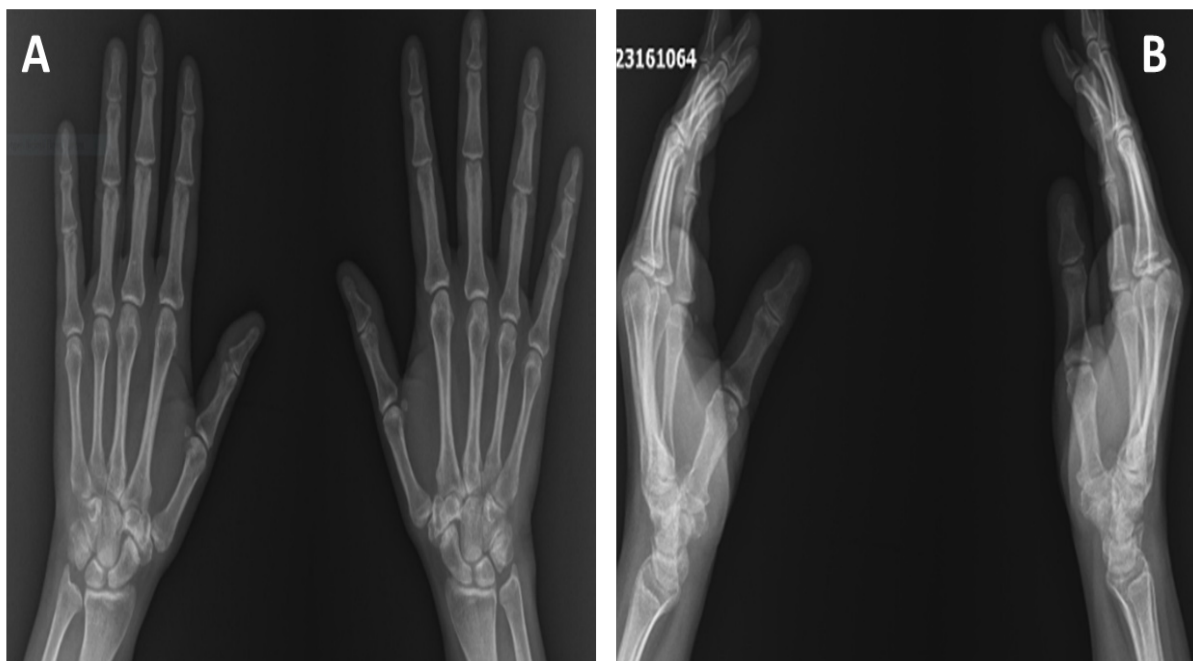**How to cite this article:** Isgandarli S, Çabukoğlu C, Şensoy BÖ. A rare case of bilateral Preiser's disease originating from the distal pole of the scaphoid. Eur Res J. 2025. doi: 10.18621/eurj.1543200

**Received:** September 9, 2024  
**Accepted:** December 22, 2024  
**Published Online:** February 12, 2025

Copyright © 2025 by Prusa Medical Publishing  
Available at <https://dergipark.org.tr/en/pub/eurj>



This is an open access article distributed under the terms of [Creative Commons Attribution-NonCommercial-NoDerivatives 4.0 International License](https://creativecommons.org/licenses/by-nc-nd/4.0/)



**Fig. 1.** Radiographs show bone edema in the distal pole of both scaphoids. Anteroposterior (A) and lateral (B) view.

it is referred to as scaphoid osteochondritis. This condition only affects the proximal pole and is never seen in the distal portion of the bone [7].

### CASE PRESENTATION

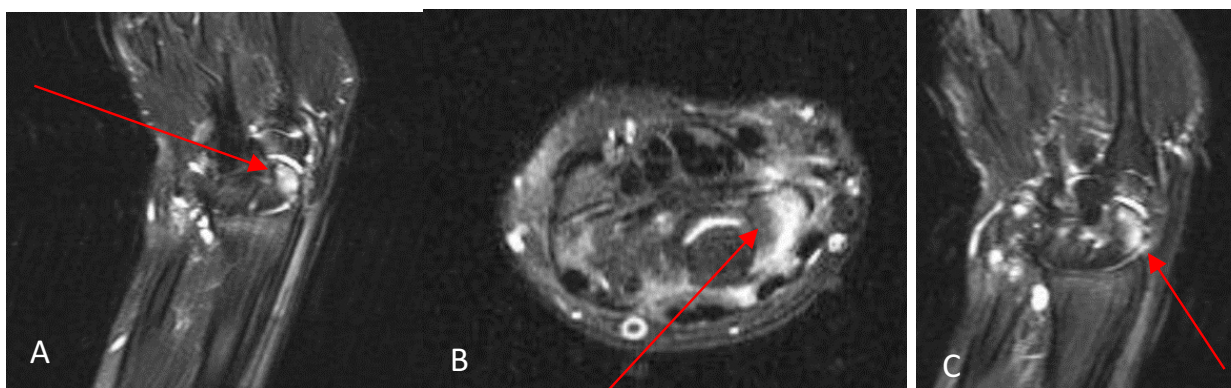
A 55-year-old right-handed female primary school teacher complained of pain that had been present for 5 months in the thenar region of both wrists. The patient did not have any mechanical stress, systemic disease, or trauma history.

Clinically, the patient's range of motion was nor-

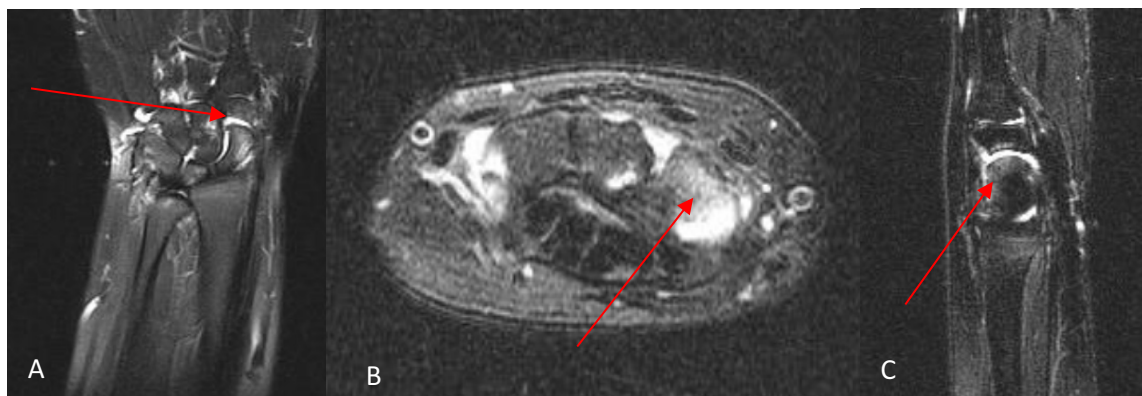
mal but painful, and there was local tenderness over the thenar region bilaterally. Finkelstein's test was negative and there were no physical examination findings supporting de Quervain's tenosynovitis.

At the same time, Tinel sign and Phalen's test were evaluated as negative bilaterally. No findings supporting median nerve entrapment were found in the Electromyography (EMG) study. Watson test, also called the scaphoid shift test, a test for assessing the dynamic stability of the scapholunate ligament was evaluated as negative.

Clinically, the patient had tenderness over the anatomical snuff box on both wrists. Bone edema at



**Fig. 2.** MRI Sections showing effusion at the intercarpal joint (A) and bone edema (B, C) in the distal scaphoid of the right wrist shown with arrows.



**Fig. 3.** MRI sections demonstrating effusion in the intercarpal joint (A) and bone edema (B, C) in the distal scaphoid of the left wrist shown with arrows.

the distal pole of the scaphoid (Figs. 1A and 1B) supporting Preiser's disease was seen on X-rays of both wrists. Because there was no separation in the scaphoid's proximal pole and the pathology was in the distal pole rather than the proximal pole, we were able to distinguish Preiser's disease from scaphoid osteochondritis.

The diagnosis was verified by an MRI showing effusion at the intercarpal joint (Figs. 2A and 3A) and bone edema in the distal scaphoid (Figs. 2B, 2C, 3B and 3C) of both wrists.

The patient underwent bilateral wrist CT to classify the disease. The CT scan showed subchondral sclerosis (Figs. 4A and 5A) and a cyst (Figs. 4B and 5B) at the distal pole of the scaphoid, which was diagnosed as Stage 2.

Due to the patient's early Preiser's disease, history of gastric bleeding, and nonsteroidal anti-inflamma-

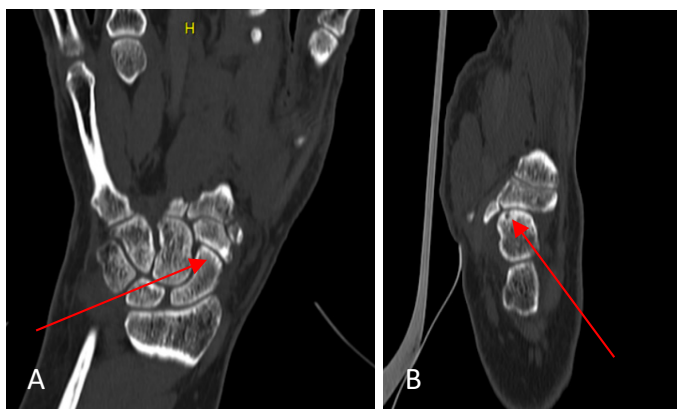
tory drugs (NSAID) allergy, immobilization treatment was performed. (Figs. 6A and 6B).

At the end of the 3rd week, the right wrist cast was removed and a re-examination was performed. Bone edema was found to be reduced by 85% in the MRI of the wrist (Figs. 7A, 7B and 7C) and patients' pain was greatly reduced.

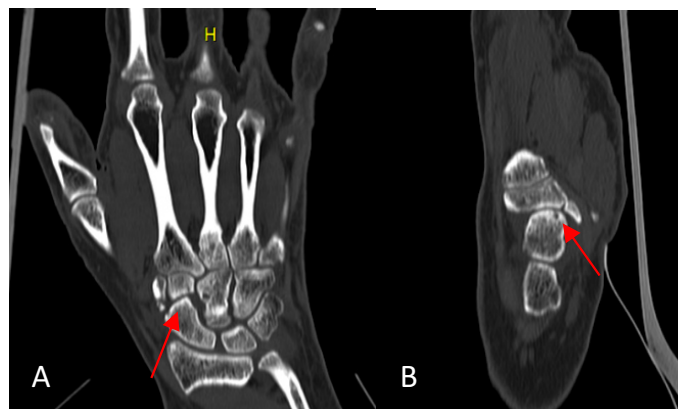
### DISCUSSION

Oxidative stress factors have an effect on diseases based on avascular necrosis bone pathophysiology such as Preiser. Antioxidants have an important role in maintaining a normal bone remodeling process and protecting bone health [8, 9].

There are no prospective, long-term trials evaluating the various therapy options for Preiser illness,

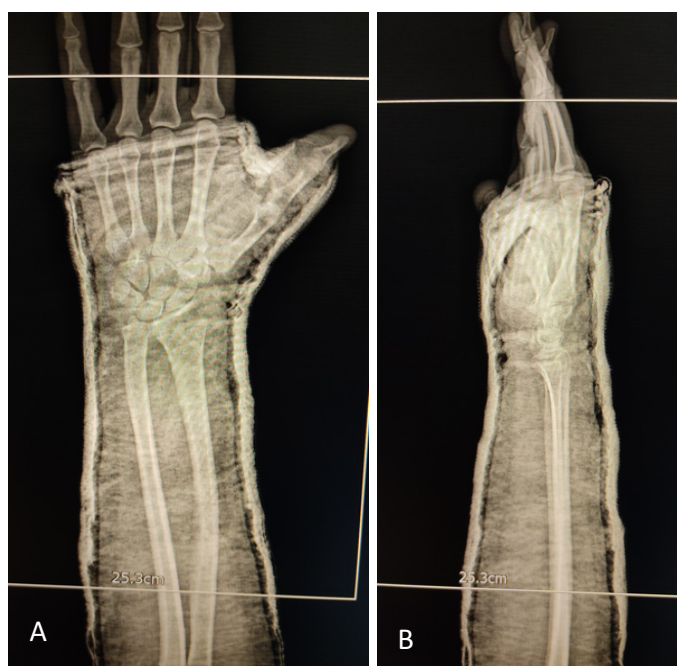

**Fig. 4.** Subchondral sclerosis (A) and cyst (B) of the distal scaphoid of the right wrist are shown with red arrows.



**Fig. 5.** Subchondral sclerosis (A) and cyst (B) of the distal scaphoid of the left wrist are shown with red arrows.





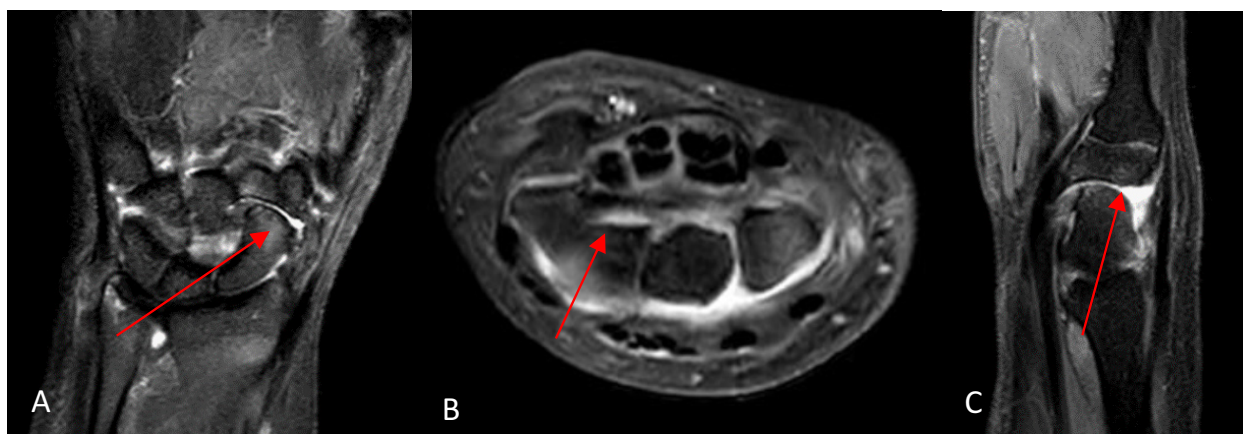**Fig. 4.** Short cast of right arm with thumb support. Antero-posterior (A) and lateral (B) views.

making treatment controversial [10]. Treatment is therefore mostly determined by the surgeon's preference. Electrical stimulation, immobilization, steroid infiltration, and non-steroidal anti-inflammatory medications are examples of conservative or nonoperative treatment [11,12]. Early immobilization and non-operative conservative treatment methods are used in the initial treatment of these patients. In the late stage, a choice has to be made between proximal row carpectomy, four-corner's fusion with scaphoid resection, or

denervation of the wrist [13, 14].

This case report details a 55-year-old female patient who came to our outpatient clinic with complaints of swelling and pain in both of her wrist joints that had persisted for five months. The patient had pain around the thenar region and anatomical snuff box on both wrists. The imaging revealed no signs of a scaphoid fracture, this eliminated the possibility of scaphoid proximal pole avascular necrosis which typically results from a fracture. Once the diagnosis was made, the illness was staged radiologically to determine the treatment plan. Using a plain radiograph as a guide, Herbert and Lanzetta divided Preiser illness into four stages according to the scaphoid area involved [3] Based on the degree of scaphoid involvement in MRI, Kalainov recently classified two categories of Preiser disease [11]. Our patient is classified as type 2 both according to Herbert and Lanzetta classification and the Kalainov classification.

According to Herbert and Lanzetta, the process starts in the proximal pole and moves on to the remaining scaphoid. However, in our patient, the disease onset was in the distal pole and spread proximally. Due to the early stage of the disease and patient compliance, our choice of treatment was immobilization. In the treatment algorithm proposed by Sokolov and Bourcheix vascularized bone grafting is the recommended treatment method for Herbert stages 1 and 2 [7]. However, we were able to obtain satisfactory results with a 3-week plaster treatment on both wrists with stage 2 Preiser's disease according to Herbert's classification [7, 15].



**Fig. 7.** Significant reduction in bone edema of right scaphoid bone after treatment with circular cast splint. The reduction area is shown with red arrows. (A) Coronal, (B) Axial, and (C) Sagittal.

## CONCLUSION

Preiser's disease is a rare condition that lacks a definitive treatment guideline. In this case report we reported a case of bilateral Preiser's disease at stage 2 with unusual presentation that was treated conservatively with immobilization for 3 weeks and reached satisfactory results. This case stands out because disease processes were initially seen at the distal pole and were resolved with a relatively short treatment of only 3 weeks of immobilization, and highlights the potential of conservative treatment options when pain and disturbance to the patient at presentation are manageable and when disease is detected at an early stage.

### Patient's Consent

Patient was informed about the purpose of the case report, and informed consent was obtained from the patient for this publication (Consent date:09/09/2024).

### Authors' Contribution

Study Conception: CÇ; Study Design: BÖŞ; Supervision BÖŞ; Funding: CÇ; Materials: CÇ; Data Collection and/or Processing: SI; Statistical Analysis and/or Data Interpretation: SI; Literature Review: SI; Manuscript Preparation: SI and Critical Review: CÇ.

### Conflict of interest

The authors disclosed no conflict of interest during the preparation or publication of this manuscript.

### Financing

The authors disclosed that they did not receive any grant during conduction or writing of this study.

## REFERENCES

1. Amillo-Garayoa S, Romero-Muñoz LM, Pons-DeVillanueva J. Bilateral Preiser's disease: a case report and review of the literature. *Musculoskelet Surg.* 2011;95(2):131-133. doi: 10.1007/S12306-011-0095-X.
2. Preiser G. Eine typische posttraumatische und zur spontanfraktur führende ostitis des naviculare carpi. *Röntgenfortschritte.* 1910;15(4):189-197.
3. Herbert TJ, Lanzetta M. Idiopathic avascular necrosis of the scaphoid. *J Hand Surg Br.* 1994;19(2):174-182. doi: 10.1016/0266-7681(94)90159-7.
4. Moran SL, Cooney WP, Shin AY. The Use of Vascularized Grafts From the Distal Radius for the Treatment of Preiser's Disease. *J Hand Surg.* 2006;31(5):705-710. doi: 10.1016/J.JHSA.2006.02.002.
5. Ferlic DC, Morin P. Idiopathic avascular necrosis of the scaphoid: Preiser's disease? *J Hand Surg Am.* 1989;14(1):13-16. doi: 10.1016/0363-5023(89)90053-1.
6. Salunkhe R, Abhyankar R, Deshmukh A, Shevate I, Vellanki Sravan Jr. A Rare Case of Preiser Disease Affecting a Young Female. *Cureus.* 2022;14(12):e32955. doi: 10.7759/CUREUS.32955.
7. Sokolow C, Bourcheix L. Preiser's disease. *Hand Surg Rehabil.* 2022;41(5):533-541. doi: 10.1016/J.HANSUR.2022.06.004.
8. Yurteri A, Mercan N, Kılıç M, Çelik M, Doğar F, Yıldırım A. Does vanillic acid affect fracture healing? An experimentstudy in a rat model of femur fracture. *J Appl Biomed.* 2024;22(2):67-73. doi: 10.32725/jab.2024.010.
9. Yurteri A, Mercan N, Çelik M, Doğar F, Kılıç M, Yıldırım A. The effect of caffeic acid on tendon healing in rats with an Achilles tendon injury model. *Jt Dis Relat Surg.* 2023;34(3):669-678. doi: 10.52312/JDRS.2023.1248.
10. Lauder AJ, Trumble TE. Idiopathic avascular necrosis of the scaphoid: Preiser's disease. *Hand Clin.* 2006;22(4):475-484. doi: 10.1016/J.HCL.2006.07.005.
11. Kalainov DM, Cohen MS, Hendrix RW, Sweet S, Culp RW, Osterman AL. Preiser's disease: Identification of two patterns. *Journal of Hand Surgery.* 2003;28(5):767-778. doi: 10.1016/S0363-5023(03)00260-0.
12. Buttermann GR, Putnam MD, Shine JD. Wrist position affects loading of the dorsal scaphoid: possible effect on extrinsic scaphoid blood flow. *J Hand Surg Br.* 2001;26(1):34-40. doi: 10.1054/JHSB.2000.0475.
13. Günel I, Oztuna V, Köse N, Seber S. Avascular necrosis of the scaphoid treated by total excision and radial advancement osteotomy. *J Hand Surg Br.* 1995;20(6):736-740. doi: 10.1016/s0266-7681(95)80037-9.
14. Green DP, Perreira AC, Longhofer LK. Proximal Row Carpectomy. *J Hand Surg Am.* 2015;40(8):1672-1676. doi: 10.1016/j.jhssa.2015.04.033.
15. Claessen FMAP, Schol I, Kolovich GP, Ring D. Avascular Necrosis of the Scaphoid Preiser Disease. *Arch Bone Jt Surg.*