

THE EFFECT OF MANNITOL ON BLOOD-BRAIN BARRIER IN THE UNILATERAL CAROTID ARTERY LIGATED RATS*

S. ÇOBANOĞLU**

T. ERBENĞİ***

SUMMARY

The effect of unilateral carotid artery ligation on the blood-brain barrier (BBB) and also on those secondary alterations the effect of mannitol were observed by electron microscopy which revealed that perivascular swelling occurred in the rats with carotid arteries ligated for different time intervals and also mannitol reduced this perivascular swelling. We discussed the pathophysiology of ischemia to some extent and reported our results with pertinent literature.

INTRODUCTION

Cerebro-vascular endothelial cells comprise the structural basis of the blood-brain barrier (BBB), a term first imposed by German pharmacologists. These cells display a variety of function states and thus potentially play more active roles in different physiological and pathological processes (13, 23, 26).

By electron-microscopic (EM) studies, it has been demonstrated that the BBB consisted of tight junctions between cerebral endothelial cells. Another, but equally important feature of the cerebral endothelial cells, in contrast to those being in most other tissues, is their relative lack of pinocytotic vesicles. The nearest neighbours of the brain microvessels are the fine processes of astrocytes, in which the entire vascular cylinder is ensheathed (13).

Under normal conditions, BBB prevents transport of macromolecules into the brain. This restriction is due to the unique structure of the cerebral

Key words: Rat, Blood-Brain Barrier, Carotid artery, Mannitol, Electron microscopy.

* This research was supported by the Trakya University Research Foundation. and has been presented in the IX. National Electron Microscopy Congress held on 29 - 31 th. of May, 1989 in Istanbul Medical Faculty.

** Trakya University Medical Faculty, Department of Neurosurgery (Yard. Doç. Dr.) -EDİRNE.

*** Istanbul Medical Faculty, Department of Histology and Embryology (Prof. Dr.) -ISTANBUL.

arterioles, capillaries and venüles, all of which have endothelial cells with relatively few pinocytotic vesicles and tight junctions between adjacent cells (30).

BBB is altered by a variety of experimental models; such as ischemia, seizures, hypertension and trauma (26, 27, 28, 30). Ischemia selectively limits entry of substances into brain, unless it progresses to infarction, when, both large molecules, Evans blue–albumin horse–radish peroxidase and small molecules, sucrose penetrate the brain (32).

Cerebral ischemia can be produced, by a variety of vascular occlusion methods including ligation, clipping or embolization, as a global, hemispheric, multifocal or as a focal ischemia (8, 12).

In this study, a common carotid artery ligation was used to produce hemispheric ischemia for the different time durations, since it takes some time for the cellular changes in ischemia (2, 21, 35). Cellular changes in BBB and its perivascular neighbour astrocyte processes, secondary to the carotid artery ligation and upon these changes the effect of mannitol were studied by EM and the results are reported by reviewing the relevant literature. In a separate paper, H₂O and electrolytes changes of the similar model study and the results of the effect of mannitol on those changes were also reported (3).

MATERIALS AND METHODS

This experiment was carried out in Istanbul DETAM on the adult Wistar type male rats weighing 200–300 g and divided into 2/3/6/12 hours (A, B, C, D for respective hours) experimental groups on the basis of unilateral carotid artery ligation duration for hemispheric ischemia and each group was also further subdivided to PREMANNITOL serving as control, MANNITOL–30 and MANNITOL–60, both, serving as two different treated groups (Table–1).

An additional rat group was also studied by EM, of which neither carotid artery ligated or mannitol received, to serve as NORMAL (E) rat group to compare with the experimental groups (Table–1).

GROUP–A: In this experimental group, left common carotid artery was ligated for 2 hours on 9 rats; 3 of these served in the PREMANNITOL (A) control group which received no mannitol treatment, the other 3 in the MANNITOL–30 (A) and the rest of 3 in the MANNITOL–60 (A)

treated groups. Treated groups received mannitol % 20 1 g/kg as an IV bolus through the penis vein at the end of duration of carotid artery ligation.

GROUPS-B/C/D: In these experimental groups, left common carotid artery was ligated for 3/6/12 hours respectively, on 24 rats, employing 9 rats in each B and C groups and the rest 6 rats served in the experimental group of D. Distribution of the rat numbers for both **PREMANNITOL** control and **MANNITOL** treated groups of the each respective experiment were 3 (for detail see Table-1). At the end of respective carotid artery ligation duration the rats in premannitol group (being 3 in each experiment) received no mannitol treatment but the ones in mannitol group received mannitol % 20 1 g/kg as an IV bolus through the penis vein.

In the experiment, all rats inspired normal room air and surgical procedures, that is, carotid artery ligations and decapitations and IV treatments were all carried out under ether anesthesia. Decapitations were performed at the end of the respective carotid artery ligation durations in the **PREMANNITOL (A/B/C/D)** but 30 minutes after mannitol infusion in the **MANNITOL-30 (A/B/C/D)** and 60 minutes after in the **MANNITOL-60 (A/B/C)** treated groups. (Table-1). Ligations were not reopened and arterial pressure was measured in a rat for each experiment group through a cannul in a femoral artery in both premannitol and and postmannitol stages. (Graphic-1). Blood pressure showed a minimal rising in the postmannitol stage, otherwise it was steady.

Additionally, 3 rats were also decapitated under ether anesthesia for normal EM studies, serving in **NORMAL (E)** rat group.

Brain removal of all rats were done following decapitation and it was carried out as quickly as possible to take left fronto-temporal cortical samples by sharp incision for EM studies. The samples were then immediately fixed with phosphate buffered (pH: 7.35) 2.5 % gluteraldehyde and it was followed by postfixation procedure with 1 % osmium tetroxide. After the necessary follow up, samples were embedded in Vestopal -W and then cut into ultra thin sections which were stained with Uranyl acetate and Lead citrate (Reynol's) technics. All sections were studied under JEOL-100 C transmission electron microscopy.

As a blood-brain barrier tracer, 5 ml/kg Evans blue was given through penis vein over 5 minutes time, prior to decapitation. Gross inspection were made following brain removal, prior to the cortical incision. The effected side, namely, left cerebral hemisphere showed more and more swell-

Table 1. All The Experimental Groups Displayed Together (n: Number of Rats)

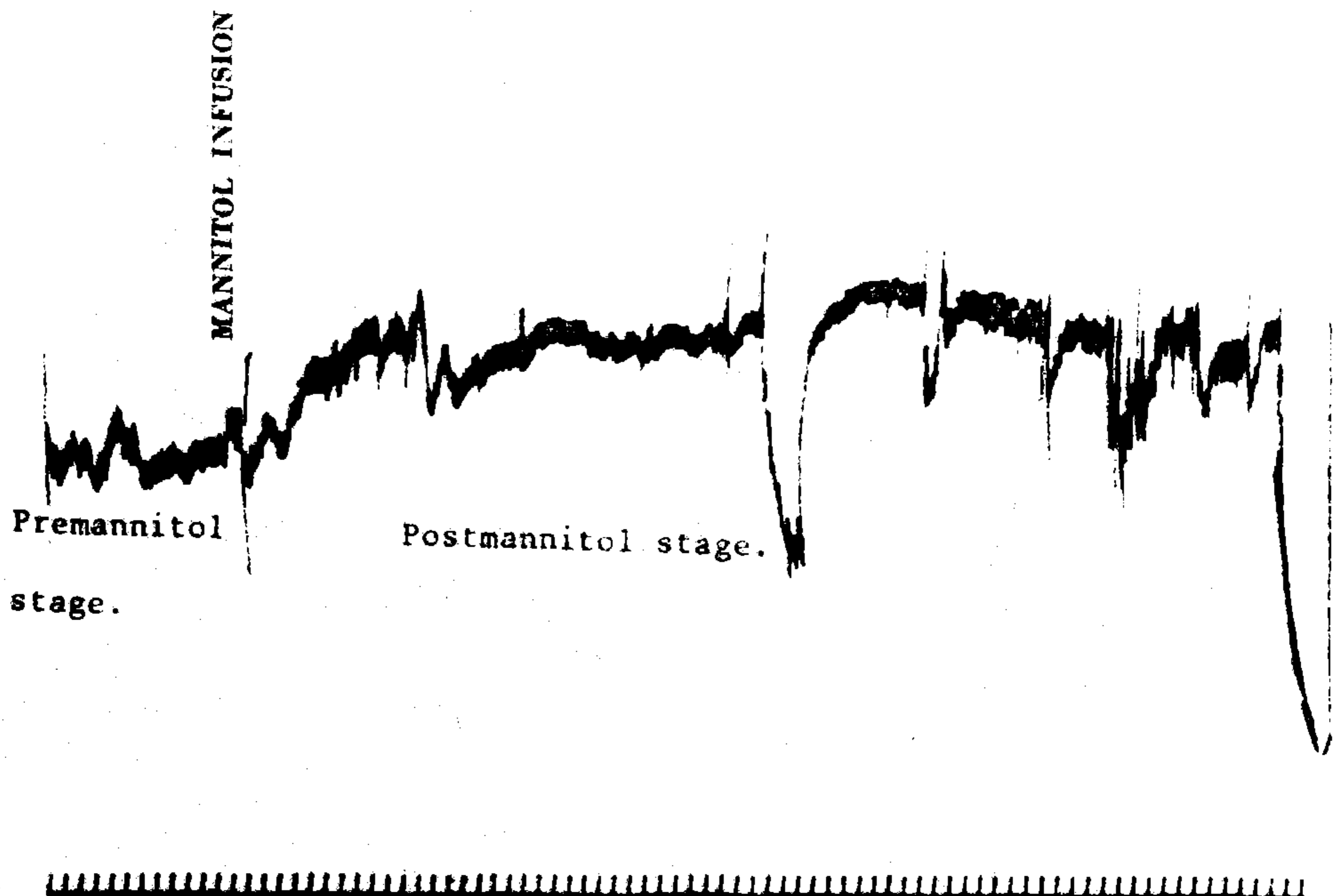
THE PROCEDURE APPLIED IN THE EXPERIMENT	NORMAL (E) n: 3	PREMANNITOL (A, B, C, D) n: 12 (3 rats in each group)	MANNITOL - 30 (A, B, C, D) n: 12 (3 rats in each group)	MANNITOL - 60 (A, B, C) n: 9 (3 rats in each group)
Duration Of Common Carotid Artery Ligation	No ligation.	2, 3, 6, 12 hours respectively	2, 3, 6, 12 hours respectively	2, 3, 6 hours respectively
Mannitol (% 20 1g/kg IV) Treatment Time	No mannitol.	No mannitol	At the end of the respective ligation duration	At the end of the respective ligation duration
Decapitation Time	Decapitated for normal EM study.	At the end of the respective ligation duration	30 minutes after mannitol infusion	60 minutes after mannitol infusion
Electron Microscopy EM figure-	E1 / E2	Premannitol - A1 / A2 / A3 Premannitol - B1 / B2 Premannitol - C1 / C2 Premannitol - D1	Mannitol - 30: A1 Mannitol - 30: B1 Mannitol - 30: C1 / C2 Mannitol - 30: D1 / D2 / D3	Mannitol - 60: A1 Mannitol - 60: B1 Mannitol - 60: C1 —

ing and staining with Evans blue accordingly with prolongation of the carotid artery ligation duration. Staining was graded as 1+, 2+, 3+. No swelling or staining were inspected in the unaffected right hemisphere.

RESULTS

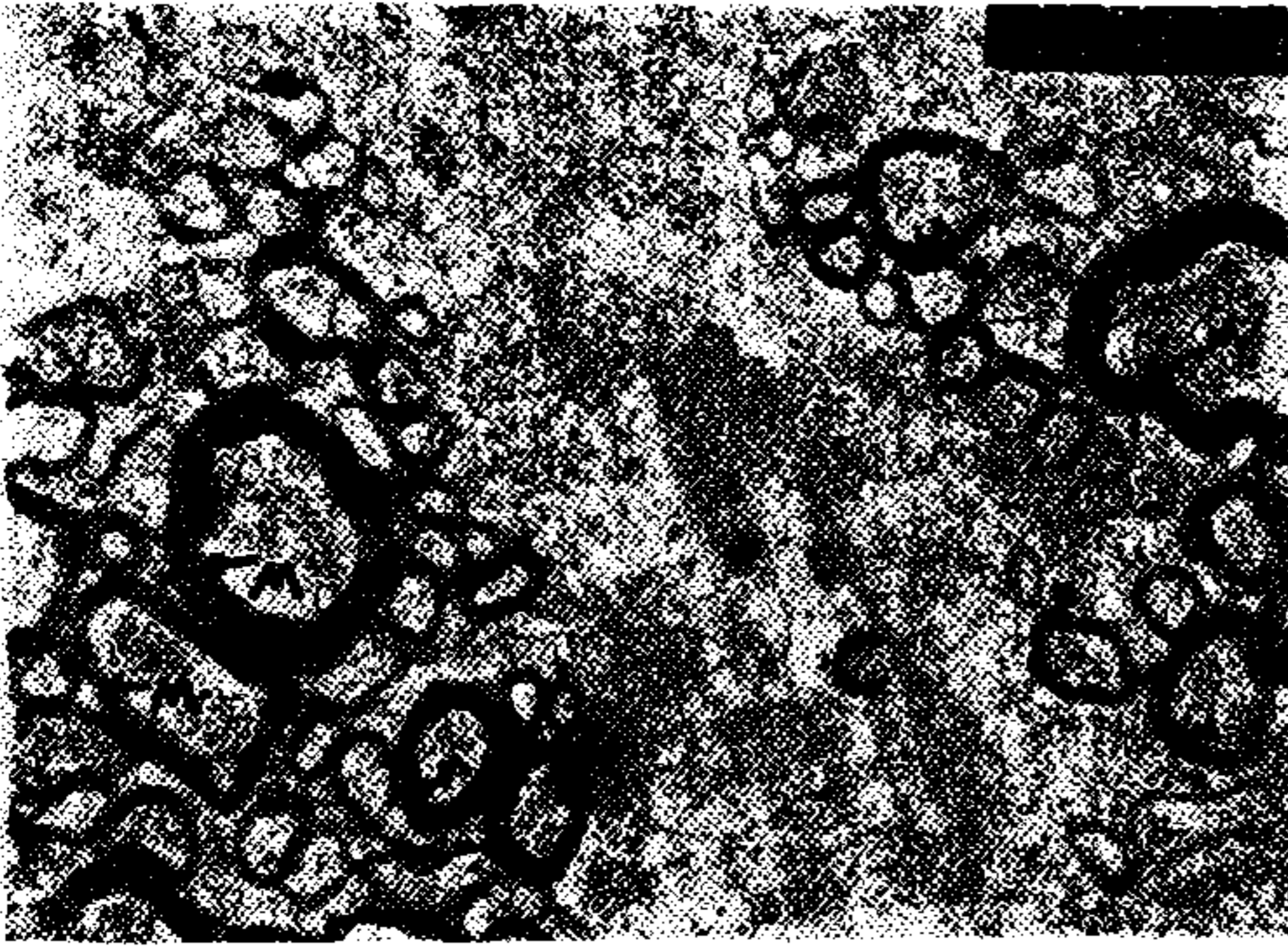
Neurological Findings: All rats inspired normal room air spontaneously and following carotid artery ligation, a permanent left sided Horner syndrome and right sided hemiparesis for 20-30 minutes were observed in all. None of the rats showed any loss of consciousness or epileptic seizures. Blood pressure was a steady recording apart from a minimal rising at the post-mannitol stage. (Graphic-1).

Pathological Findings: Brain swelling was present on the left cerebral hemisphere of all the rats carotid arteries ligated. Swelling became more marked with the prolonged carotid artery ligation duration but it never reached to the herniation degree. The same correlation was present in the



Graphic 1. Arterial pressure measured through a cannule in a femoral artery showed a minimal rising after mannitol infusion.

staining grades. It was difficult to make any comment about lessening of the hemispheric swelling in the treated groups of all experiment by naked eyes. Pathological findings by EM were presented in figures at next pages.



EM figure-E1 (x 12.000)




EM figure-E2 (x 12.000)

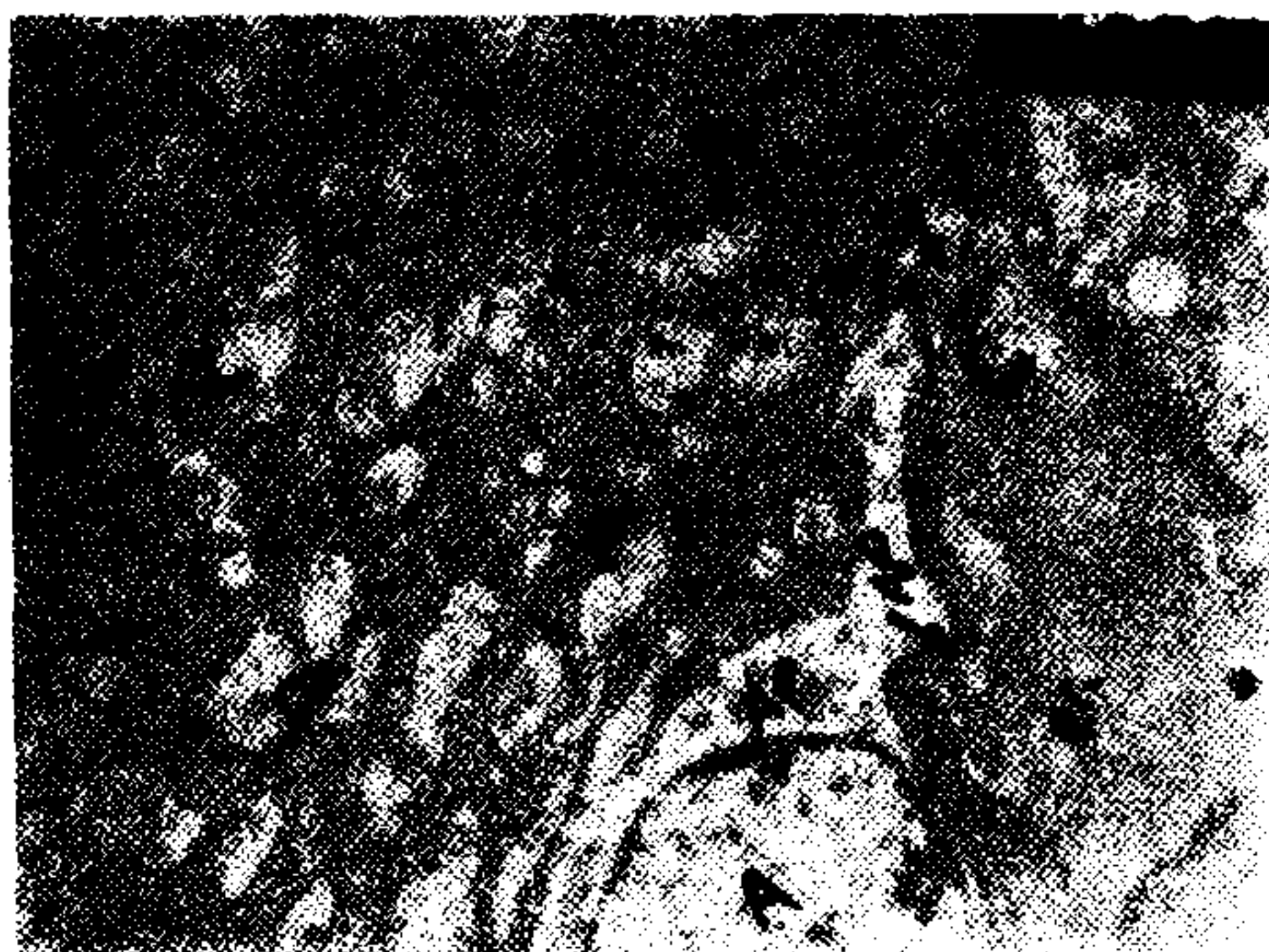
In these EM figures-E1 / E2, normal cortical structure appearances of the rat are seen
(M: myelin tissue; C: capillary; Gl. N: microglial nucleus)



EM figure: PREMANNITOL-A1 (x 10.000)



EM figure: PREMANNITOL-A2 (x 8500)

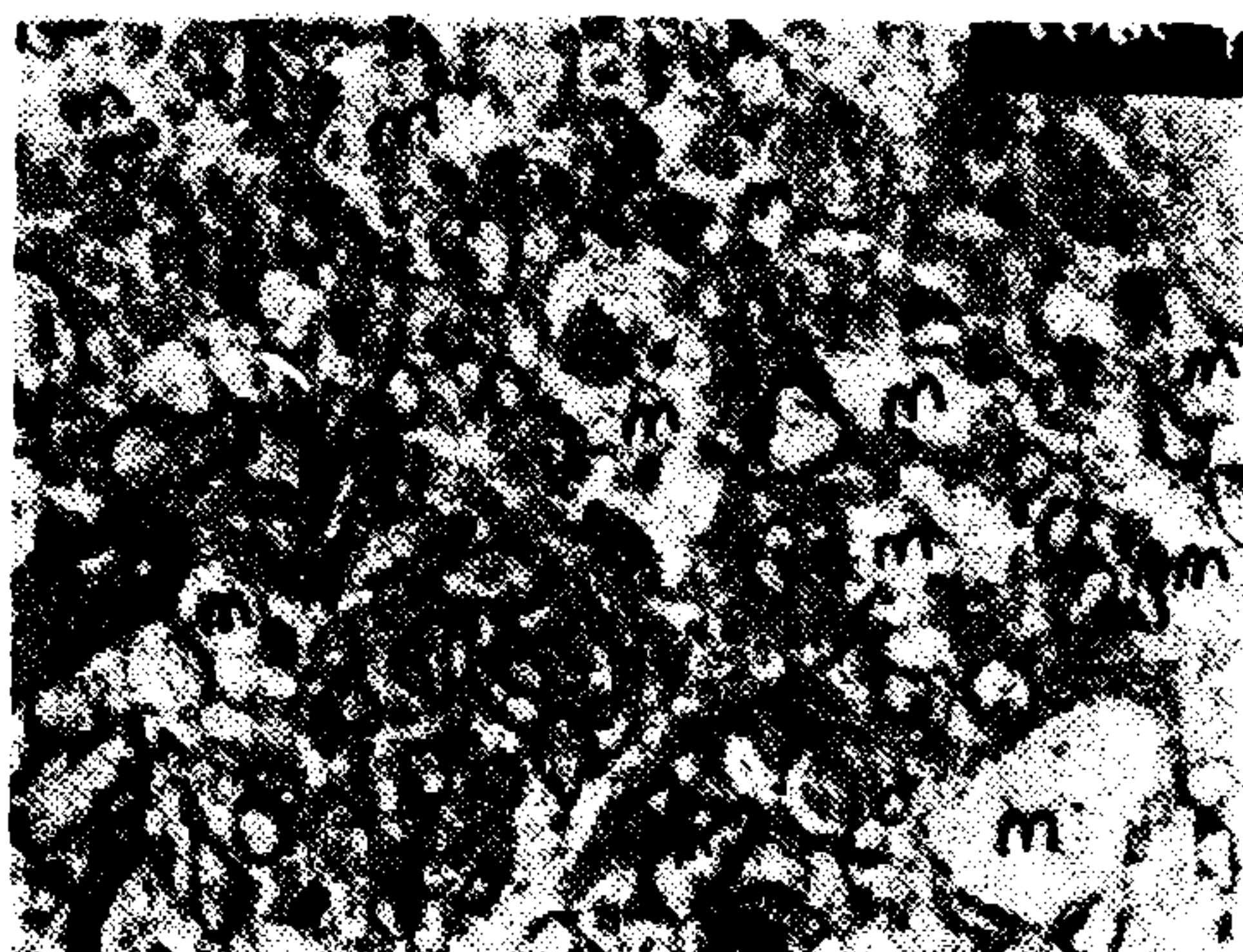


EM figure PREMANNITOL-A3 (x 8500)

In these PREMANNITOL A1-3 figures, widespread swelling of the perivascular astrocyte processes (AP) and also secondary to the swelling, compression of a capillary (arrows, C) are obviously seen. (er: erythrocyte, fbr: nerve fibers without myelin, A: astrocyte, N: neurone, m: microvacuolation).

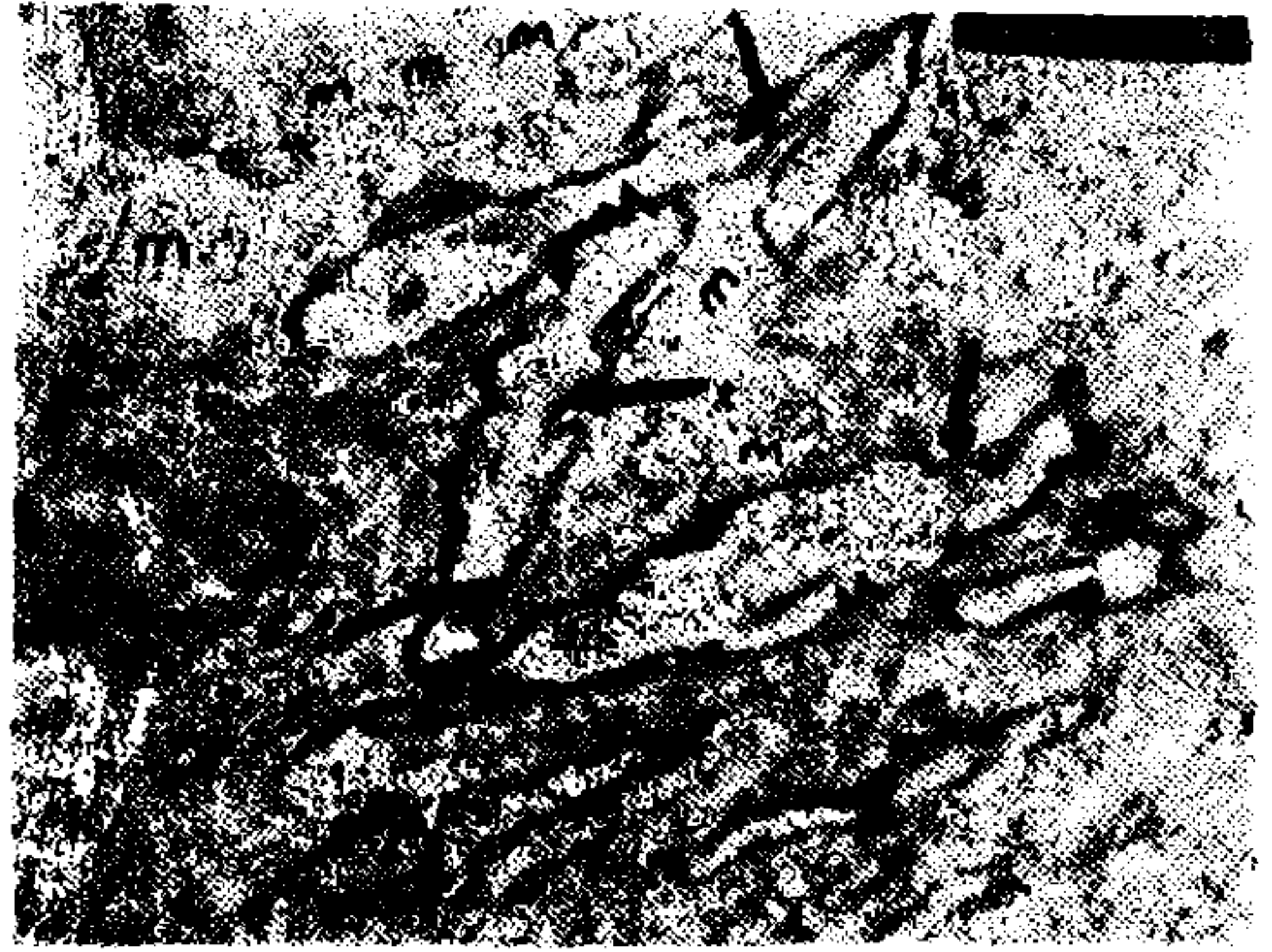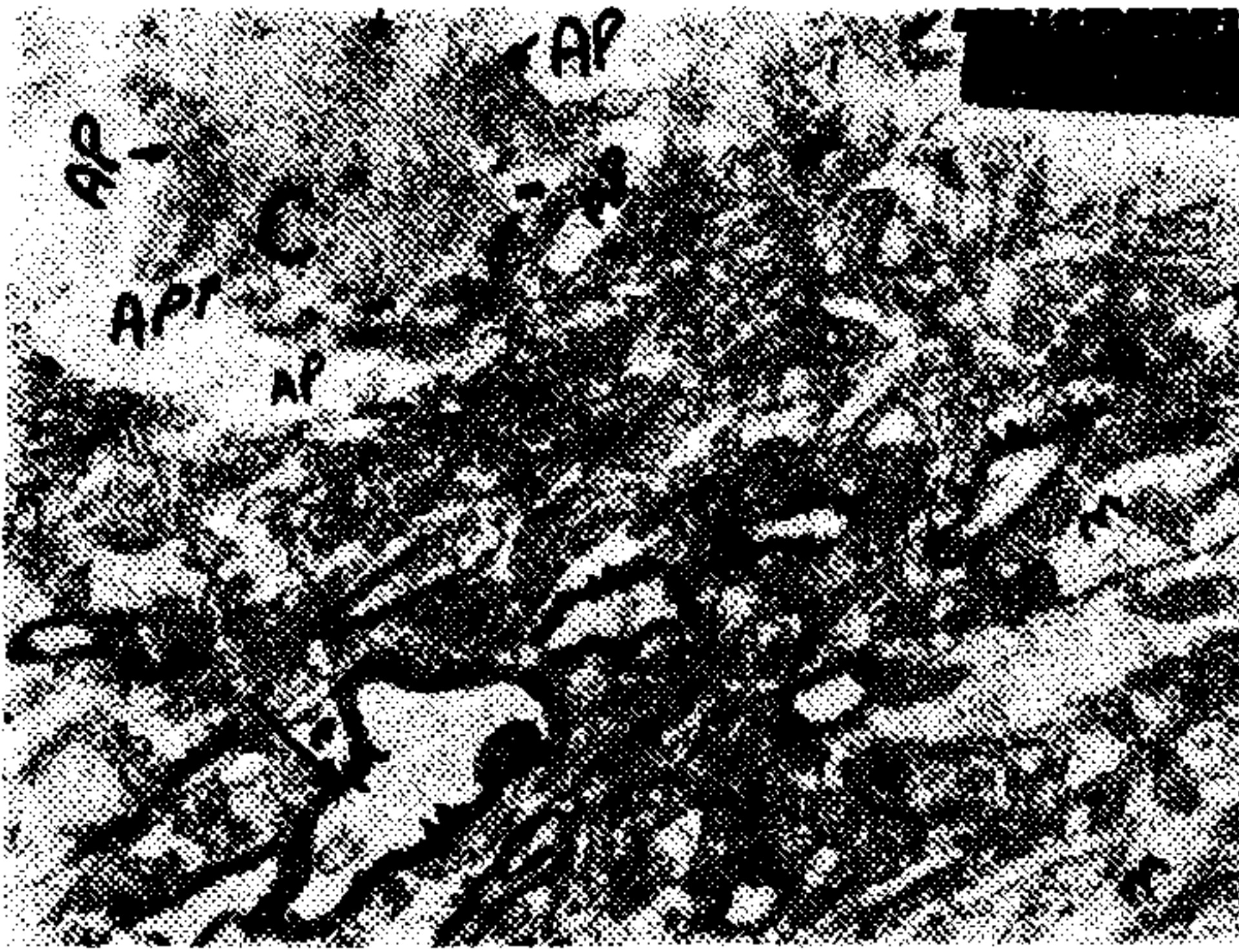


EM figure: MANNITOL 30: A1 (8500)



EM figure: MANNITOL 60: A1 (x 8500)

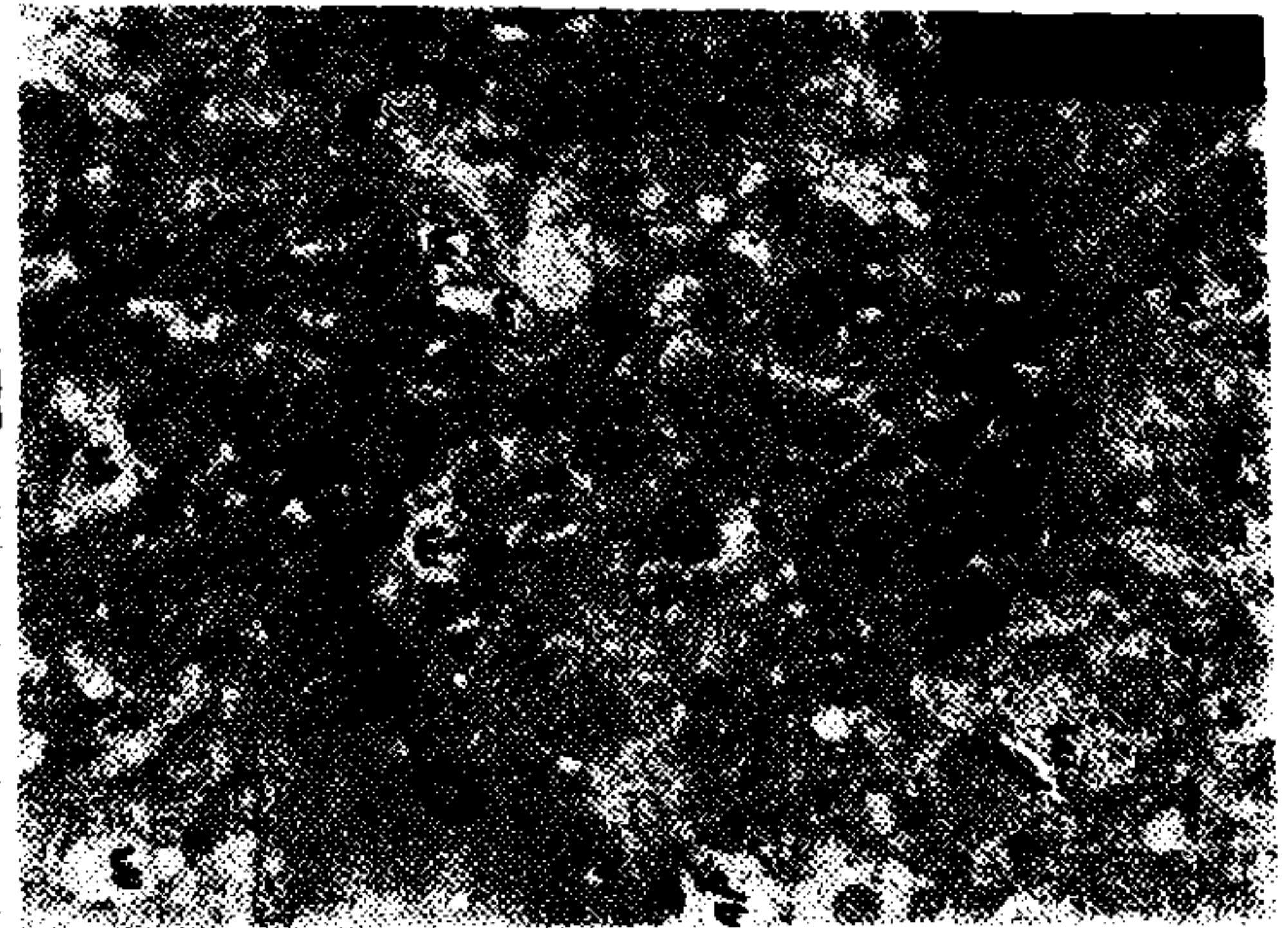
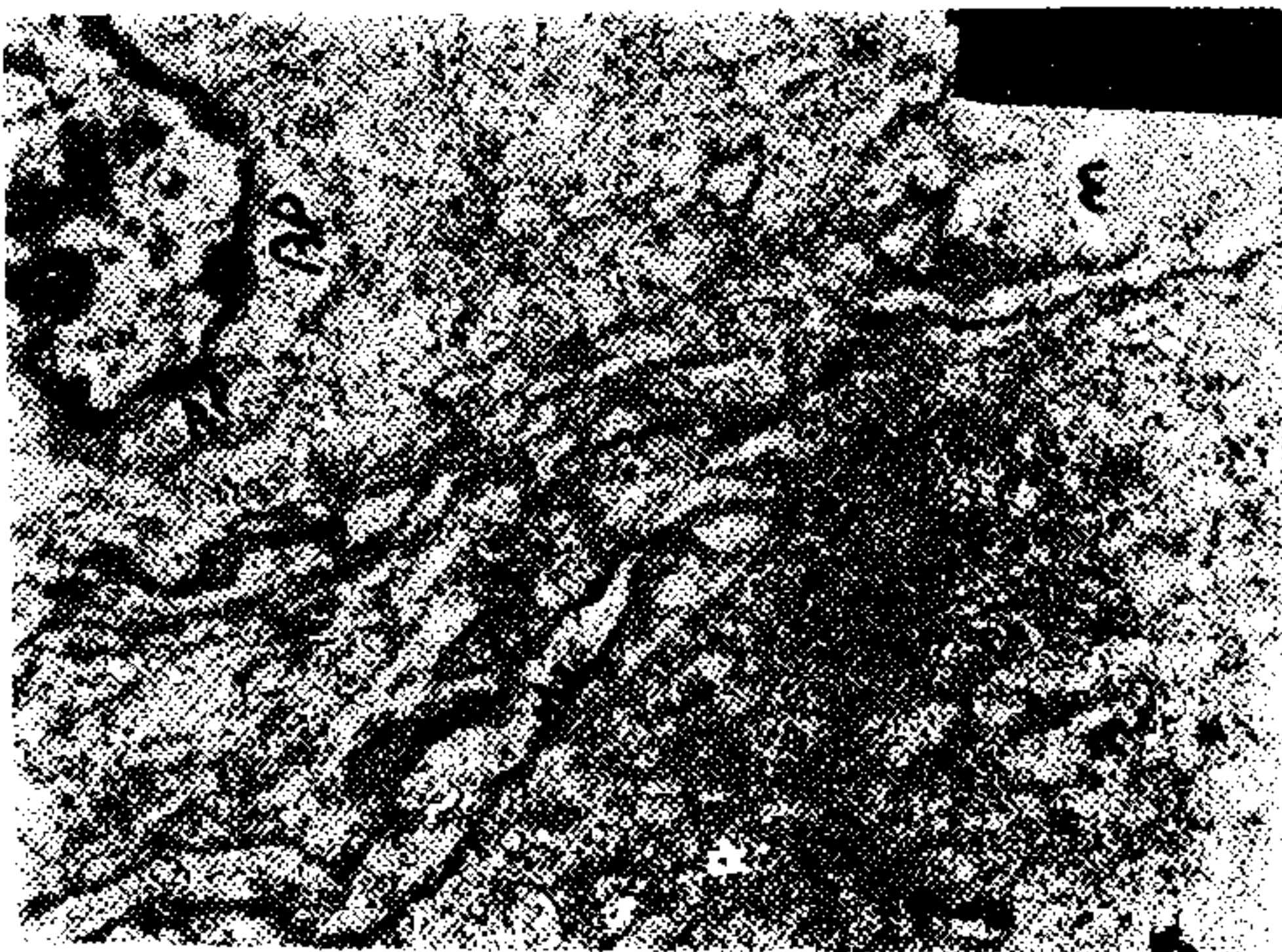
In these MANNITOL 30/ 60 TREATED experimental groups' EM figures, It is obviously seen that mannitol is more effective in reducing perivascular edema in MANNITOL-30 than MANNITOL-60 treated group (AP: astrocyte processes, C: capillary, end: endothel, m: microvacuolation, M: myelin tissue).



EM figure: PREMANNITOL-B1 (x 13.000)

EM figure: PREMANNITOL-B2 (x 13.000)

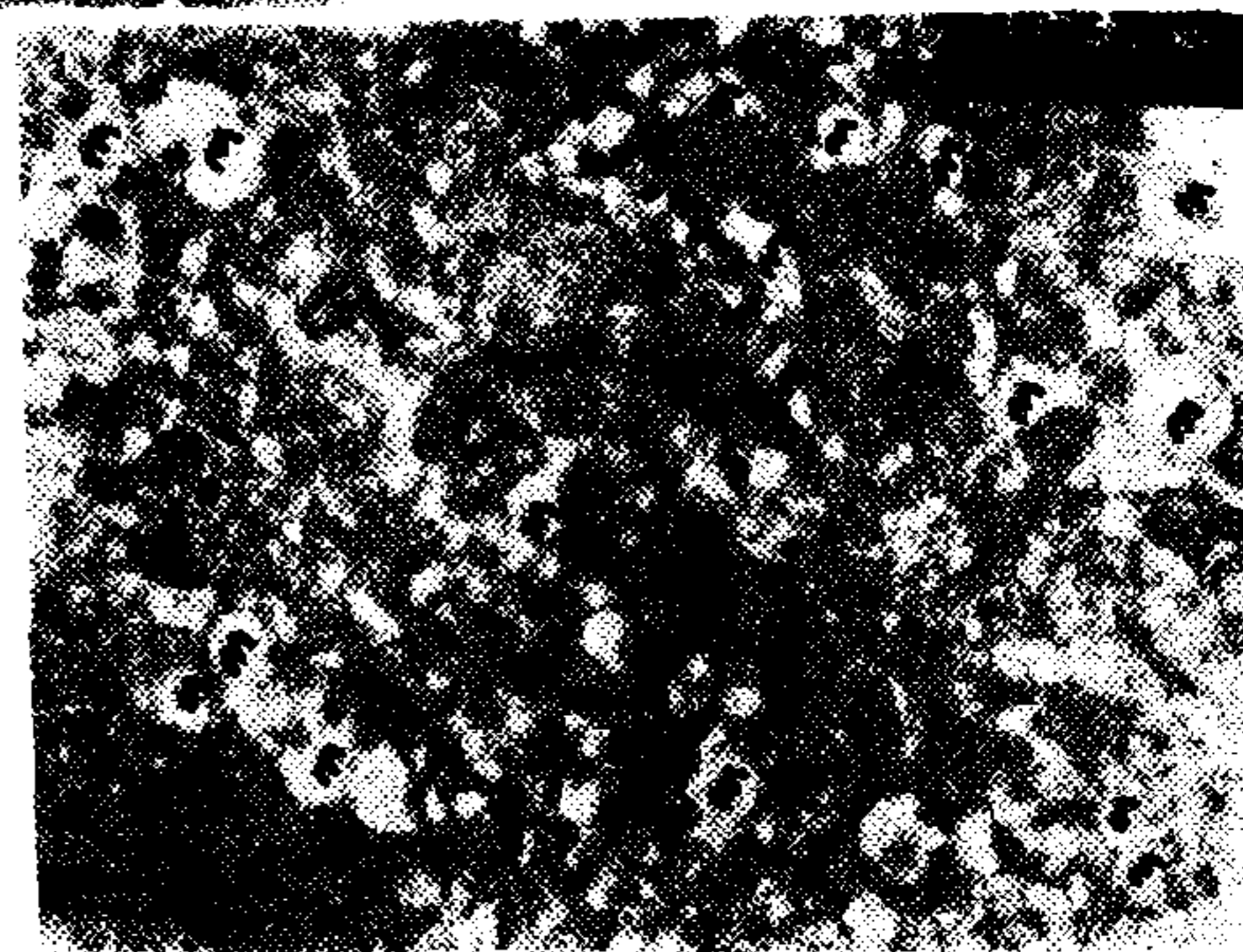

In these PREMANNITOL EM figures of the experimental group of B, perivascular swelling in the astrocyte processes (AP) with compression (small arrows) of a capillary (C), distortion of the myelin tissue (M) around the axons (long arrows) and increased microvacuolations (m) are much more obvious than its counterpart PREMANNITOL-A.



EM figure: MANNITOL-30: B1 (x 8500)

EM figure: MANNITOL-60: B1 (x 8500)

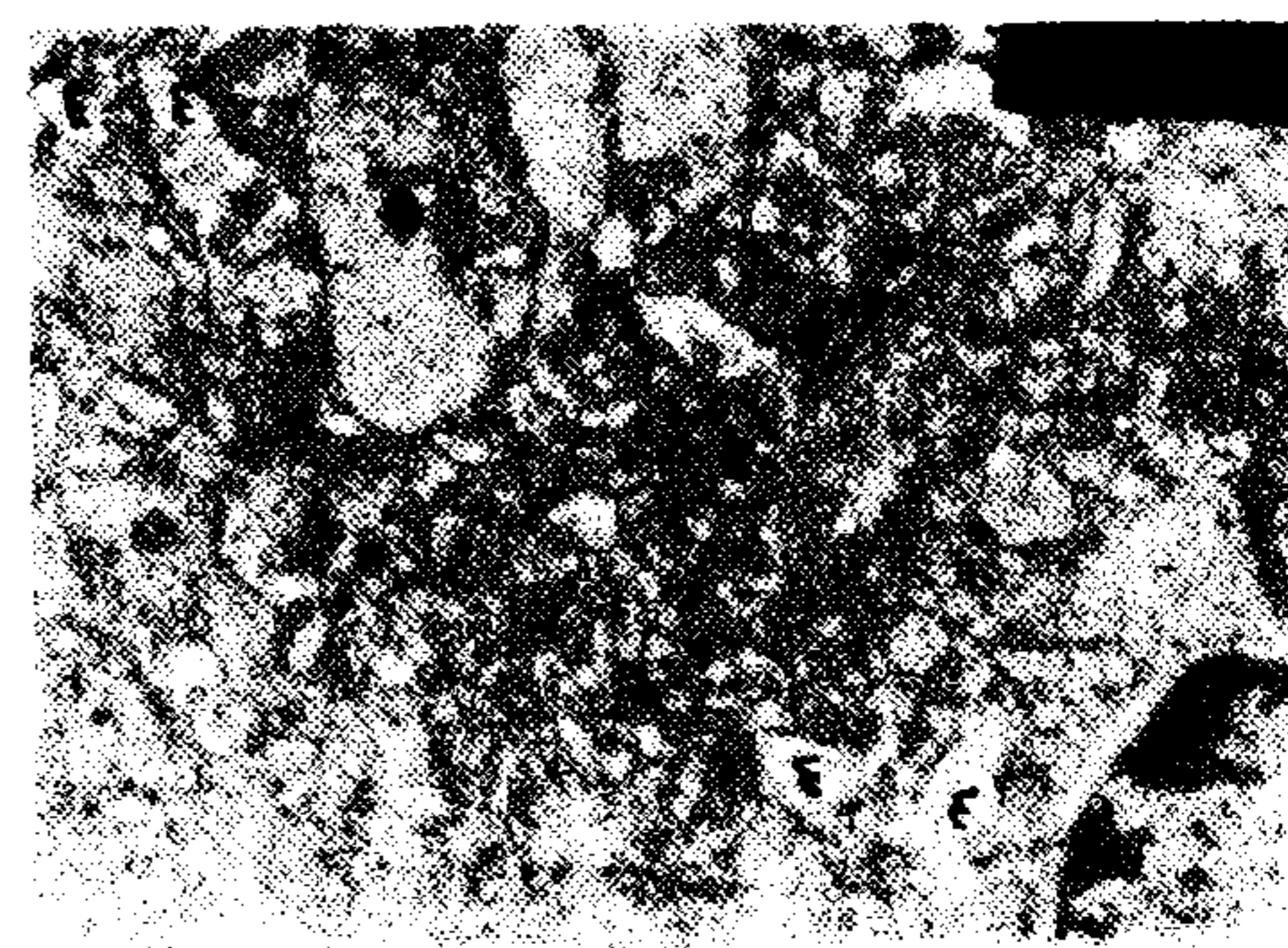

In these MANNITOL 30/ 60 TREATED EM figures of the experimental group of B, It is again seen that edema reducing effect of mannitol is more obvious in MANNITOL 30 than MANNITOL 60 treated group (M: myelin, m: microvacuolation, AP: astrocyte processes, C: capillary).



EM figure: PREMANNITOL-C1 (x 8500)

EM figure: PREMANNITOL-C2 (x 8500)

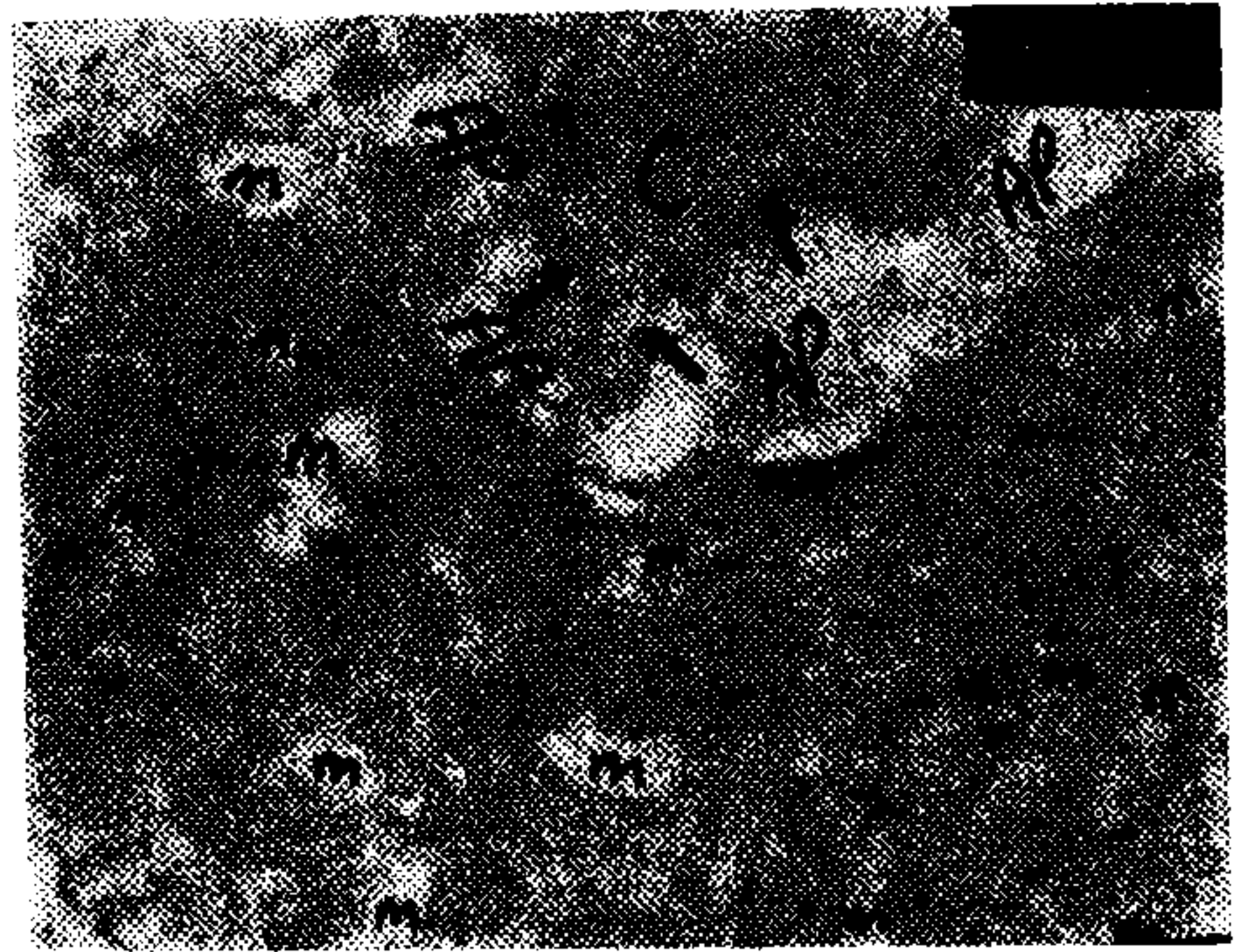
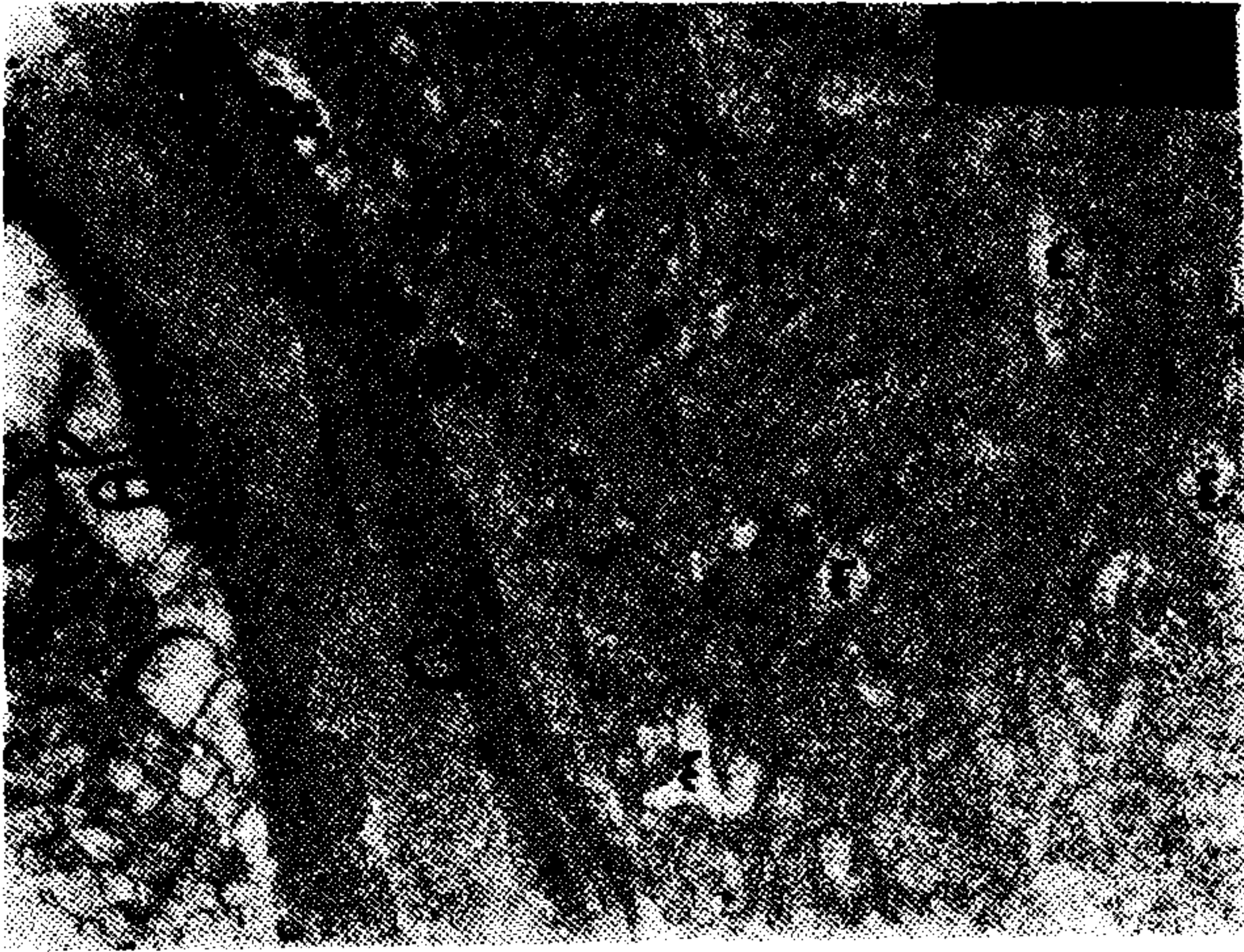
In these PREMANNITOL EM figures of the experimental group of C, swelling in the perivascular structures became more obvious with lessening of myelin tissue around the axons (M) than previous counterparts'. Also neurones (N) appeared to be darkened. (M: myelin tissue, N: neurone, AP: astrocyte processes, m: microvacuolations, C: capillary).





EM figure: MANNITOL-60: C1 (x 11,700)

EM figure: MANNITOL-30: C1 (x 11,700)

In these MANNITOL TREATED experimental group of C, EM figures show again marked reduced swelling of perivascular structures in MANNITOL 30 than MANNIOL 60 group. Compression of a capillary is still obvious in MANNITOL 60: C1 figure (arrows). (C: capillary, AP: astrocyte processes, m: microvacuolations)



EM figure: MANNITOL-30:C2 (x 11.700) EM figure: PREMANNITOL-D1 (x 11.700)
Swelling of perivascular structures (AP: astrocyte processes) being more marked, with compression (arrows) of a capillary (C) and increased microvacuolations (m) are seen in this EM figures of the experimental group of D.



EM figure: MANNITOL-30:D1 (x 11.700) EM figure: MANNITOL-30:D2 (x 11.700)
In these MANNITOL TREATED experimental group of D, EM figures show that mannitol appeared to be less effective in reducing the swelling. Still, microvacuolations (m) and distortions (arrows) of the myelin tissue (M) are obvious.

DISCUSSION

The object of this experiment was to study the effect of unilateral carotid artery ligation in producing neuronal and/or chemical alterations, with mannitol effect on those changes. Threshold of ischemia to produce both neuronal and chemical alterations was shown that on the basis of experimental findings it is not the same (12).

It is reported that experimental neuronal alterations being secondary to the cerebral ischemia usually develop at two stages in which the primary phase is reversible, neuronal structures preserved and the secondary phase is thought to be irreversible with neuronal necrosis and breakdown of the blood - brain barrier (BBB) (1, 10, 16, 17, 18).

The edema developing in perivascular structures (astrocyte processes) in the primary phase is known as ISCHEMIC, CYTOTOXIC but in the secondary phase it is accepted as VASOGENIC type of ischemic edema of which is secondary to the breakdown of BBB. Because of two stages in the ischemic cerebral insults, therapy effect would be different depending on the integrity of the BBB (14, 15, 24, 31, 33). Therefore, we tested the BBB by Evans blue (25, 26, 32), which was infused to the rats having had mannitol infusion, just prior to decapitation; therefore in this experiment hemispheric staining with Evans blue could be due to the mannitol opening effect on the BBB rather than breakdown of it.

In this in-vitro experimental study, our EM observations revealed that the appearances of the alterations in neuronal structures was mainly consistent with the primary phase of ischemia (see the related EM figures).

For the mannitol effect, BBB should at least partially be intact, to open the tight junctions and extract water/Na⁺ from the edema. If BBB extremely damaged mannitol would not be supposed to be effective in the reduction of edema (9, 11, 19, 20, 22, 29, 34, 36).

Although the above experimental suggestions, the results of both clinical and experimental studies on the mannitol effect in cerebral ischemia appear to be conflicting (3, 4, 5, 6, 7, 9, 19, 22, 29, 36).

In this experimental study, it was electron microscopically observed that mannitol was effective especially for short duration (in the first 30 minutes more effective than 60 minutes) rather than longer duration in reducing the edema secondary to the carotid artery ligation in rats. As this experiment was an in-vitro study, we felt that the effect of mannitol was to be confirmed in another model study which was again shown that mannitol is an effective agent in reducing ischemic edema (6, 7).

REFERENCES

1. **Brown, A.W. and Brierley, J.B.:** *Anoxic-ischemic cell change in rat brain. Light microscopic and fine structural observations.* J. Neurol. Sci. 16: 59-84. 1972.
2. **Carter, L.P., Yamagata, S. and Erspamer, R.:** *The limits of reversible cortical ischemia.* Neurosurgery. 12: 620-623. 1983.
3. **Çobanoğlu, S.:** *The effect of mannitol on cerebral water and electrolyte contents in unilateral carotid artery ligated rats.* (In press).
4. **Çobanoğlu, S.:** *Comparison of the effects of mannitol and dexamethasone on the hypoxic-ischemic brain edema (Part-I).* (In press).
5. **Çobanoğlu, S.:** *Comparison of the effects of mannitol and dexamethasone on the hypoxic brain edema (Part-II)* (In press).
6. **Çobanoğlu, S., Erbenli, T.:** *Electron microscopic observations of the effects of dexamethasone and mannitol in the hypoxic-ischemic rat brain (Part-I)* (In Press).
7. **Çobanoğlu, S., Billir A., Erbenli, T.:** *Electron microscopic observations of the effect of dexamethasone and mannitol in the hypoxic rat brain. (Part-II)* (In press).
8. **Diaz, F.G. and Ausman, J.I.:** *Experimental cerebral ischemia.* Neurosurgery. 6: 436-445. 1980.
9. **Hanamura, T., Asano, T. Shigeno, T. and et al.:** *How does mannitol reduce edema water in focal cerebral ischemia..* Intracranial pressure VI. pp: 577-580. Eds: J.D. MILLER, G.M. TEASDALE, J. O. ROWAN, S.L. GALABRAITH and A.D. MENDELOW. Springer-Verlag Berlin/Heidelberg. 1986.
10. **Hills, C.P.:** *Ultrastructural changes in the capillary bed of the rat cerebral cortex, in anoxic-ischemic brain lesion.* Am. J. Pathol. 44 (4): 531-550. 1964.
11. **Hoff, J.T.:** *Cerebral protection.* J. Neurosurg. 65: 579-591. 1986.
12. **Hossmann, K.A.:** *Experimental aspects of stroke.* In *Vascular Disease of the Central Nervous System.* Edt. R.W. ROSE RUSSEL. Churchill-Livingston. Edinburg/London. pp: 73-95. 1983.
13. **Joo, F.:** *Current aspects of the development of the blood-brain barrier.* Int. J. Devl. Neuroscience. 5 (6): 369-372. 1987.
14. **Klatzo I.:** *Presidential address. Neuropathological Apects of brain edema.* J. Neuropathol/ Exper. Neurol. 36: 1-15. 1967.
15. **Klatzo I.:** *Brain edema following brain ischemia and the influence of therapy.* Br. J. Anaesth. 57: 18-22. 1985.
16. **Levine, S.:** *Anoxic-ischemic encephalopathy in rats.* Am. J. Pathol. XXXVI.: 1-15. 1960.
17. **Little, J.R., Sundt, T.M. and Kerr F.W.L.:** *Neuronal alterations in developing cortical infarction. An experimental study in monkeys.* J. Neurosurg. 39: 186-198. 1974.
18. **Little, J.:** *Rmicrovascular alterations and edema in focal cerebral ischemia.* pp: 236-243 In Pappius H, Feindel W (eds). Dynamics of brain edema. New York. Springer-Verlag. 1976.
19. **Little, J.R.:** *Modification of acute focal ischemia by treatment with mannitol.* Stroke 9: 4-9. 1978.

20. **Little, J.R.:** *Treatment of acute cerebral ischemia with intermittent low dose mannitol.* Neurosurgery. 5: 687-691. 1979.
21. **Liu, H.M.:** *Neovasculature and blood-brain barrier in ischemic brain infarct.* Acta Neuropathol (Berl). 75: 422-426. 1988.
22. **Meyer, F.B., Anderson, R.E., Sundt, T.M. and Yaksh, T.L.:** *Treatment of experimental focal cerebral ischemia with mannitol.* J. Neurosurg. 66: 109-115. 1987.
23. **Mollgard, K. and Saunders, N.R.:** *Development of the human blood-brain and blood-CSF barriers.* Neuropathol. and Applied neurobiol. 12: 337-358. 1986.
24. **O'Brien, M.D., Wlatz, A.G., Jordan, M.M.:** *Ischemic cerebral edema. Distribution of water in brains of cats after occlusion of the middle cerebral artery.* Arch. Neurol. 30: 456-460. 1974.
25. **Olsson, Y., Crowell, R.M., Klatzo, I.:** *The blood-brain barrier to protein tracers in focal cerebral ischemia and infarction caused by occlusion of the middle cerebral artery.* Acta Neuropathol. (Berl). 18: 89-102. 1971.
26. **Öztaş, B.:** *Kan-Beyin bariyeri ve etkili faktörler.* T. Kln. Tıp. Bil. Ar. Derg 2 (2): 135-140. 1984.
27. **Öztaş, B., Kaya, M.:** *Konvülsiyonlarda ortaya çıkan hipertansiyon ve kan-beyin bariyeri permeabilitesi üzerine deksametazonun etkisi.* İst. Tıp. Fak. 9. Kur. Bildirileri. 22-25 Eylül. 1987 (75-82).
28. **Öztaş, B., Korkmaz, G.:** *Hipertansiyonun kan-beyin bariyeri permeabilitesine etkisinde tek taraflı A. Karotis bağlanması'nın önemi.* İst. Tıp Fak. 9. Kur. Bildirileri. 22-25 Eylül. 1987 (123-129).
29. **Pena, F. Gaiñel, C., Suess, D. and et al.:** *Effect of mannitol on experimental focal ischemia in awake monkeys.* Neurosurg. 11: 477-481. 1982.
30. **Petito, C.K. and Lev, D.E.:** *The importance of cerebral arterioles in alterations of the blood-brain barrier.* Labr. Invest. 43 (3): 262-268. 1980.
31. **Raichle, M.:** *The pathophysiology of brain ischemia.* Ann. Neurol. 13: 2-10. 1983.
32. **Sage, J.L., Uiter, R.L.V. and Duffy, T.E.:** *Early changes in blood-brain barrier permeability to small molecules after transient cerebral ischemia.* Stroke. 15: 46-50. 1984.
33. **Schuler, F.J., Hossmann, K.A.:** *Experimental brain infarcts. II. Ischemic brain edema in cats.* Stroke 11: 593-601. 1980.
34. **Selman, W.R. and Speltzer, R.:** *Therapeutics for focal cerebral ischemia.* Neurosurgery 6: 446-452. 1980.
35. **Todd, N.V., Picozzi, P., Crockard, A. and et al.:** *Duration of ischemia influences the development and resolution of ischemic brain edema.* Stroke 17: 466-71. 1986.
36. **Watanabe, T., Yoshimoto, T., Ogawa, A. and et al.:** *The effect of mannitol in preventing the development of cerebral infarction. An electron microscopical investigation.* Neurol. Surg (Tokyo): 7: 859-866. 1979.