

## CASTELMAN'S DISEASE - REPORT OF TWO CASES

KULLEP M.\*, BEDİRHAN M.A.\*\* DOĞAN A.\*\*\* GEBİTEKİN C.\*\*\*, TAŞCI O.\*\*\*\*

### SUMMARY

Castelman's Disease is an abnormal lymphoid proliferation of unknown cause. It has not been determined whether it is an autoimmun disorder, a reaction to an unidentified infectious agent, an immunodeficiency disease or an autonomous lymphoproliferative disorder. We herein present two cases of Castelman's disease located in the mediastinum. They found irresectable on exploratrix thoracotomy and pathologic examination revealed plasma cell type in both which are less frequent than hyaline vascular type.

Key Words: Mediastinal tumors, lymph node hyperplasia.

### ÖZET

Castelman Hastalığı-İki Olgunun Takdimi: Castelman Hastalığı, sebebi bilinmeyen bir lenf sistemi proliferasyonudur. Otoimmun bir hastalık mı, enfeksiyöz bir ajana karşı reaksiyon mu, bir immun sistem yetersizliği mi yoksa otonom lenfoproliferatif hastalık mı bilinmemektedir. Bu yazımızda, mediastinal Castelman Hastalığı teşhisi konulan ve eksploratrix torakotomide irrezektabl bulunan iki olgu sunulmaktadır.

Anahtar Kelimeler: Mediasten tümörleri, lenf hiperplazisi.

### INTRODUCTION

Giant lymph node hyperplasia was initially described by Castelman in 1954 (1). Although the mediastinum was the site of disease in the initial report and in most patients, these tumors may develop wherever lymph nodes are present; the retroperitoneal, cervical, axillary and pelvic regions comprise the most frequent non-mediastinal sites (2).

Two distinct histologic entites exist; hyaline vascular entites which are characterised by small hyaline and interfollicular capillary proliferati-

\* Yedikule Göğüs Hastalıkları Hastanesi, Göğüs Kalp Damar Cerrahisi, İstanbul.

\*\* Trakya Tıp Fakültesi, Göğüs Kalp Damar Cerrahisi Yrd. Doçenti, Edirne.

\*\*\* Yedikule Göğüs Hastalıkları Hastanesi, Göğüs Kalp Damar Cerrahisi Araştırma Görevlisi, İstanbul.

\*\*\*\* Yedikule Göğüs hastalıkları Hastanesi, Göğüs Kalp Damar Cerrahisi Doçenti, İstanbul.

on and plasma cell entities; which are characterised by large follicles with intervening sheets of plasma cells.

Surgical excision produces a cure. We herein describe two patients in whom tumor was demonstrating angiofollicular lymph node hyperplasia (Castelman's Disease) which was located in the mediastinum.

CASE 1. A 61-year-old man was admitted to another institution with severe chest pain, shortness of breath, weight loss and fever. Since the patient had no benefit from nonspecific antibiotic therapy and has a high ESR he was referred to our institution.

On admission, the temperature was subfebrile. The blood pressure and heart rate were within normal limits. Pulmonary sounds were also normal. Laboratory data included: ESR: 80 mm / h, RBC: 3.1 M, Hb: 10.1 gr / dl, Htc 33 %. Other routine blood and urine examinations revealed no pathology. The patient was a heavy smoker since 50 years, one pack a day.

X-ray examination and computed tomography revealed a huge mass starting from subcarinal region and extending through the posterior mediastinum up to the diaphragm. It was encapsulated. The mediastinal mass computed 23-42 Hounsfield unit (Figure 1). It was likely to be a solid tumor. Cytologic examination of the sputum was negative in three examina-

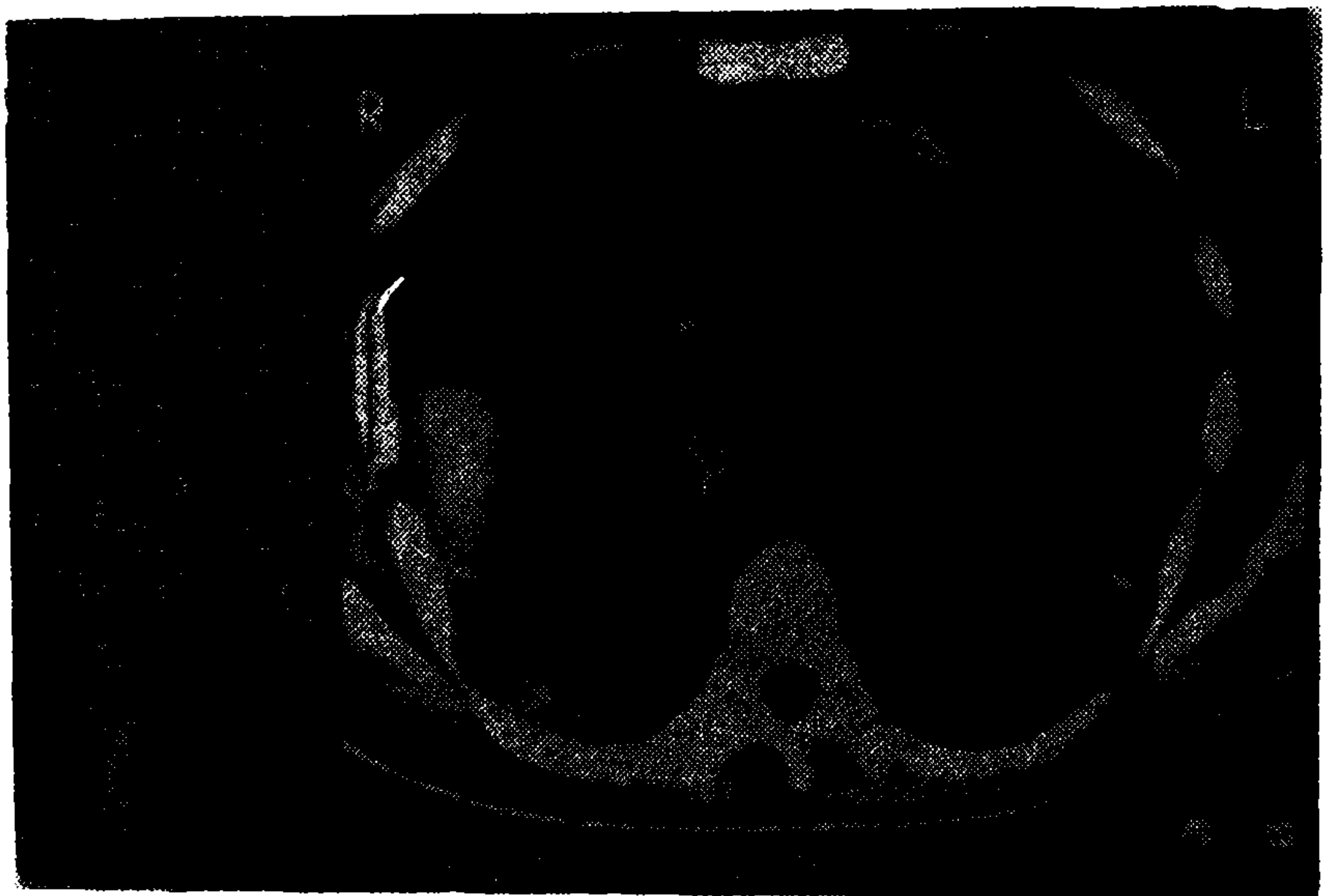


Figure 1. Computed tomographic examination of the patient revealed a huge mass starting from subcarinal region and extending through the posterior mediastinum. It seems to be encapsulated. The mediastinal mass computed 23-42 Hounsfield unit.



tions. Needle biopsy revealed also no pathology. Fiberoptic bronchoscopy showed normal trachea, carina and bronchial system on the right side.

Since the mass was encapsulated and seemed to be resectable by bronchoscopy an exploratory thoracotomy was planned.

A right exploratory thoracotomy through the fifth intercostal space revealed excessive pulmonary adhesions. Further explorations showed a huge mass beginning from azygoesophageal recessus to diaphragm. It was firmly penetrated to the mediastinum and filling the paravertebral sulcus. It seemed to be rubbery on palpation and was grayish-white in colour. Surgical resection was not feasible. Pathologic specimen was also taken.

Postoperative period was uneventful. Pathologic examination disclosed lymph node hyperplasia in plasma cell type (Castelman's disease).

**CASE 2.** A 38-year-old man was admitted to another institution with the complaints of chest pain in his back. The patient referred to our clinic following routine chest x-ray which disclosed a mass at the left hemithorax.

Cardiopulmonary system examinations were normal. The temperature, blood pressure, respiratory rate, and heart rate were within normal limits. The patient was a heavy smoker, two packs a day since 20 years. Laboratory data were as follows: ESR 148 mm/h, RBC 2.8 M, Hb: 8.2 gr / dl, Htc: 29 %, ASO 625 u, CRP: (++++), RF: (+++). Immunoelectrophoresis also revealed polyclonal hypergammaglobulinemia (IgG: 2530, IgA: 627, Ig M: 132).

Routine chest x-ray and computed tomography revealed a mass, ten cm. in diameter, located left to the pulmonary artery and aorta, besides of bronchial bifurcation. It was a solid mass and extending with several lymphadenopathies. There was no pulmonary invasion (Figure 2, 3).

A left exploratory thoracotomy through the fifth intercostal space revealed a round shaped mass 15 cm in diameter and was surrounding pulmonary artery. There were also two subaortic lymphadenopathies near the mass. The tumor was unencapsulated and seemed to be as rubbery. It was thought that resectional surgery is not feasible.

Postoperative period was uneventful and the patient discharged on ninth postoperative day. Pathologic examination revealed giant angiofollicular lymphoid hyperplasia, plasma cell in type (Castelman's disease).

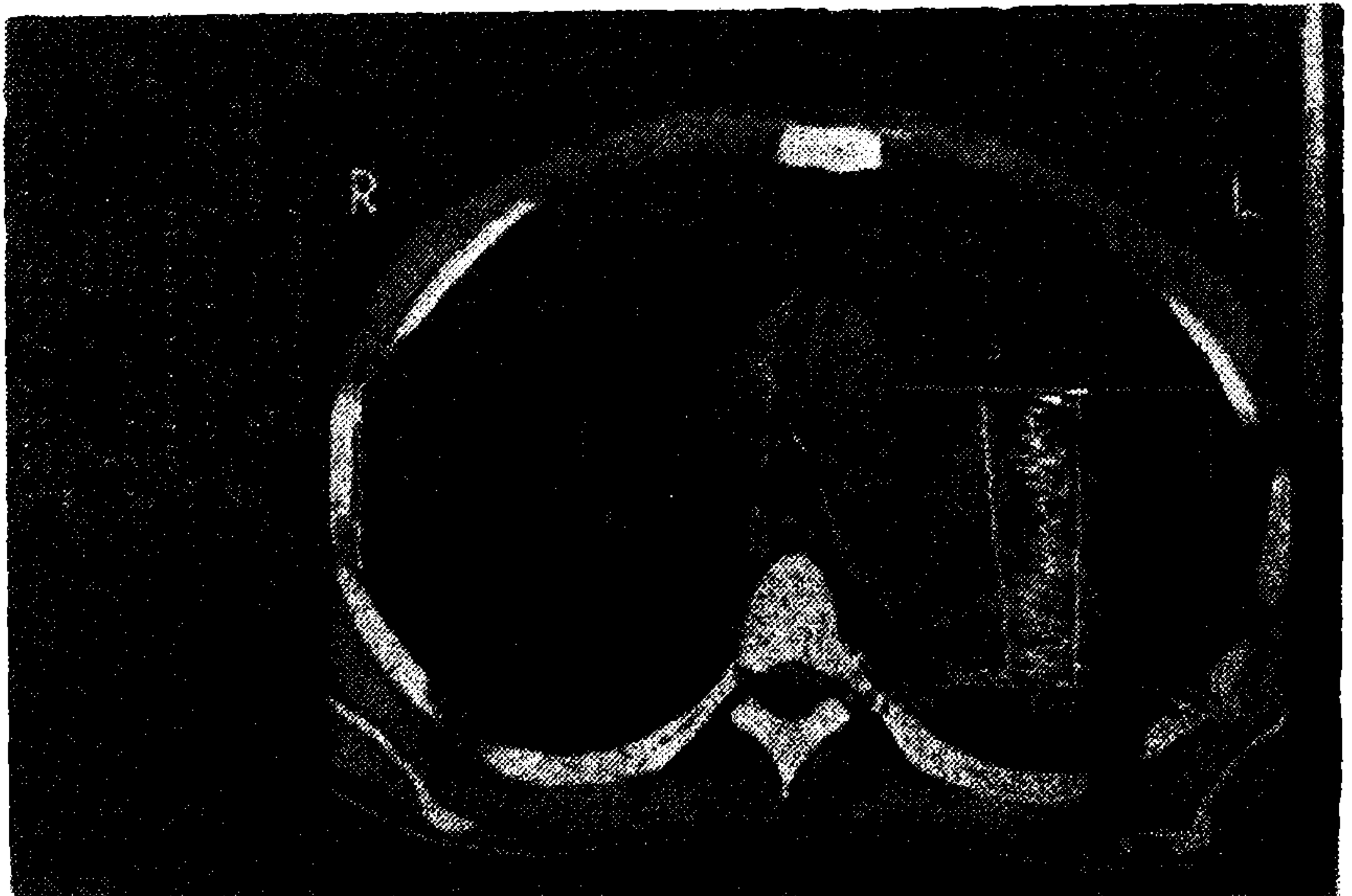
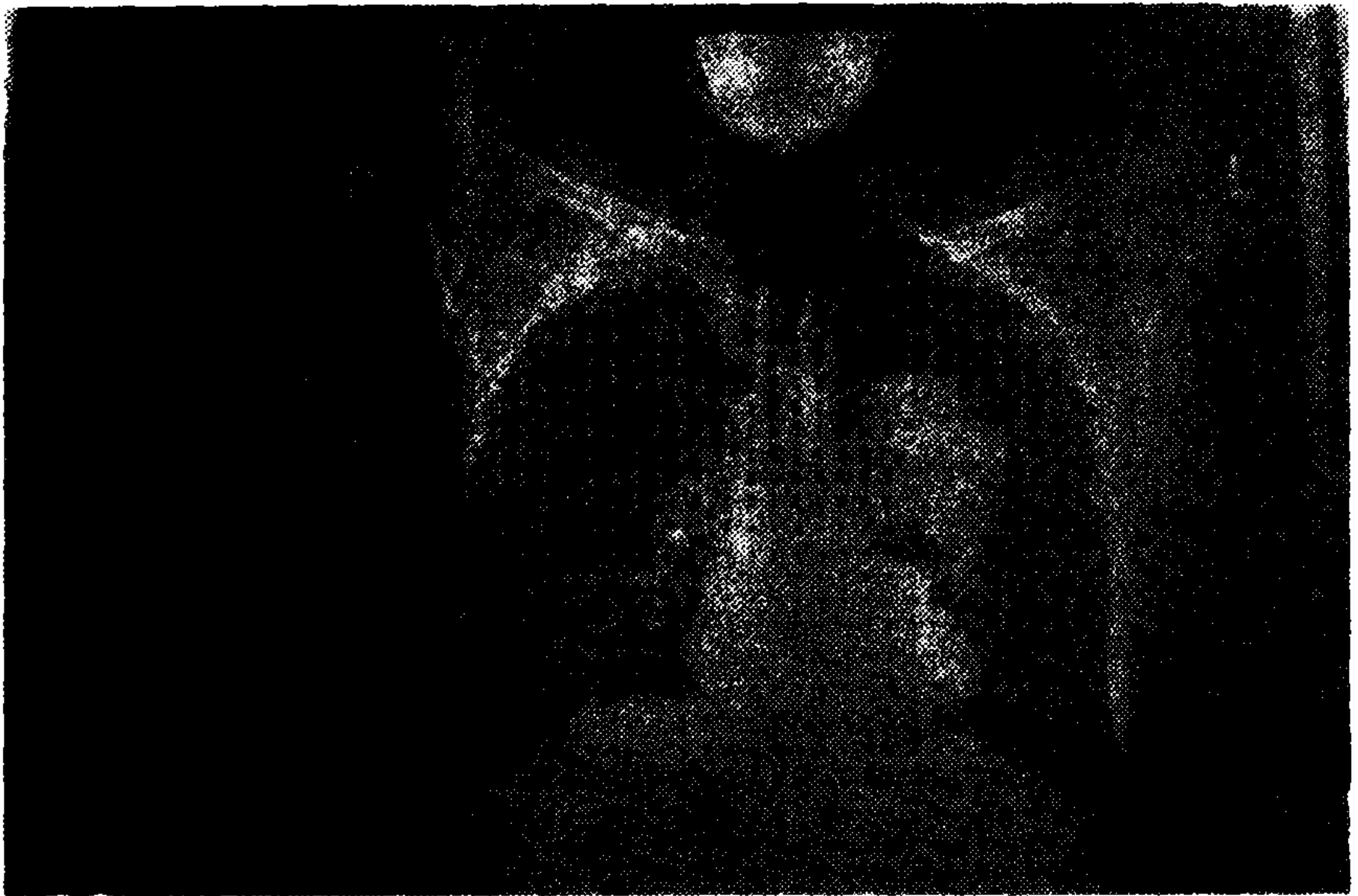

Figure 2, 3. Scanogram of the second patient who has a mass, ten cm in diameter. Computed tomography shows the tumor was located left to the pulmonary artery and aorta, besides the bronchial bifurcation. It was a solid mass with several lymphadenopathies.



## DISCUSSION

In 1956, Castelman discussed a group of patients with asymptomatic benign giant hyperplastic lymph nodes that resembled thymomas (1). Most of the lesions were intrathoracic, predominantly in the posterior mediastinal and paravertebral spaces. In other instances, anterior mediastinal and hilar regions were involved.

Symptomatology of Castelman's disease is well defined which involves general lethargy, anemia, hypoalbuminemia, hypergammaglobulinemia, thrombocytopenia and hypoproteinemia (3, 4, 5). Patients also have symptoms of strategically located tumor itself.

Abel, in 1968 concluded that this tumor was based on the absence of nodal sinuses, the presence of disease in extragonadal locations, lack of symptoms, a high frequency in younger patients and extremely slow growth. These hypothesis were also supported by Lattes and Prachter, later (6).

Recently, additional evidence of an independent blood supply to the lesions proved by angiography and the coexistence of giant lymph nodes and angiolypomatous tissues further suggested a hamartomatous origin (3, 7, 8). Castelman (9) and Kellers (10) favor of inflammatory origin continued the controversy by the clinical and histologic evidence advanced. Slow growth and the occurrence in young patients do not favor a hamartomatous origin but the association of giant lymph nodes with polyneuritis, anterior horn cell degeneration and myasthenia gravis also raises more questions for the etiologic responsibility of hamartomatous theory (11, 12).

But, the associated anemia, increased ESR, hypergammaglobulinemia, hypoalbuminemia, thrombocytopenia, hypervascularity, diffuse follicular hyperplasia and resemblance to rheumatoid and post-vaccinal lymphadenitis provide compelling evidence in favor of an inflammatory etiology (13, 14, 15).

Castelman's disease infrequently occurs in extrathoracic locations and multicentric variants have occasionally been described. Disease usually begins with an asymptomatic single round lesion in the posterior mediastinum, paravertebral or hilar regions.

Histologically, there are two variants, hyaline-vascular and plasma-cell types or type I and type II as described by Flendrig (10, 16, 17). Plasma cell type is the earlier and more acute stage whereas hyaline vascular type is a more chronic form of the same process (3). In a study by Keller, in 1972 (10) hyaline vascular type was found to be more frequent than plasma cell type, 90 % and 10 %, respectively.

Clinically, disease closely parallels the histologic pattern (3). The plasma cell type is often accompanied by hematologic abnormalities and generalized manifestation of an infectious and inflammatory process as in our two cases. The treatment of choice is complete surgical excision and there have been no reports of recurrence (17). Some authors recommend radiotherapy in extrathoracic and multicentric cases and Bargoli reported an advanced case treated with cyclophosphamide and prednisone resulting in remission (15). As previously mentioned our two cases had refused any further treatment.

Unlike the benign clinical course of classical Castelman's disease, multicentric castelman disease is a more malignant one with frequent deaths resulting from infectious complications. This disease have also been reported in association with human immun disease virus infections (2, 4).

Disease also seems to be more frequent than expected and published literature either in English and other language.

#### REFERENCES

1. Castelman B., Towne V.W.: *Case records of the Massachusetts General Hospital: Case 40011*. N. Engl J Med 250: 26-30, 1954.
2. Denis R.D., Oldham H.N., Sabiston D.C.: *Giant Lymph node Hyperplasia (Castelman's Disease)*. In: Sabiston D.C., Spencer F.C., eds. *Surgery of the Chest*. 5 th edit. Philadelphia. W.B. Saunders Company 1984 pp. 528-529.
3. Bhatti M.A.K., Ferrante J.W., Glechinsky I., Norman J.C.: *Giant Lymph Node Hyperplasia of the Mediastinum (Castelman's Disease)*. Texas Heart Institute Journal 11: 378-384, 1984.
4. Delmer A., Kormochkine M., Le Tourneau A et al: *Castelman's Disease (Giant Lymph node Hyperplasia): Clinical, biological and developing polymorphism. Apropos of 4 cases*. Ann med Interna (Paris) 141: 123-128, 1990.
5. Yağın N., Barlas C., Sönmez B. et al.: *Mediastinal Hamartoma*. Solunum Dergisi 11: 383-389, 1987.
6. Lattes R., Prachter M.R.: *Benign lymphoid masses of probable hamartomatous nature*. Cancer 15: 197-214, 1962.
7. Walter J.F., Rottenberg R.W., Cannon W.B. et al.: *Giant Mediastinal Lymph Node Hyperplasia (Castelman's Disease) Angiographic and clinical features*. Am J Roentgenol 130: 447-450, 1978.
8. Al-Jabi M., Tolnai G., McCaughey, W.T.E.: *Angiofollicular lymphoid hyperplasia in an angiolipomatous mass*. Arch Pathol Lab Med. 104: 313-315, 1980.
9. Castelman B., Iversen L., Mendez V.P.: *Localized mediastinal lymph node hyperplasia resembling thymoma*. Cancer 9: 822-830, 1956.

10. Keller R.A., Hochholzer L., Castelman B.: *Hyaline-vascular and plasma-cell types of giant lymph node hyperplasia of mediastinum and other locations.* Cancer 29: 670-683, 1972.
11. Boxer L.A., Boxer G.J., Flair R.C. et al.: *Angiomatous lymphoid hamartoma associated with chronic anemia, hypoferrremia and hypergammaglobulinemia.* J Pediatr 8: 66-70, 1972.
12. Hartsock R.J.: *Postvaccinial lymphadenitis.* Cancer 21: 632-546, 1968.
13. Gaba A.R., Stein R.S., Sweet D.L., Variakojis D.: *Multicentric lymph node hyperplasia.* Am J Clin Pathol 69: 86-90, 1978.
14. Wahner W., Geoliner JR., Hoagland EC.: *Giant lymph node hyperplasia resembling a abscess on Gallium scan.* Clin. Nuc. Med. 3: 19-21, 1978
15. Bartoli E., Masserelli G., Soggia G., et al: *Multi centric giant lymph node hyperplasia.* Am. J. Clin. Pathol. 73: 423-416, 1980.
16. Fisger ER., Sieracki JC., Goldenberg DM.: *Identity and nature isolated lymphoid tumors (so called nodal hyperplasia and hamartoma) as revealed by histologic electron microscopic heterotransplantation studies cancer.* 23: 1288-1300, 1970.
17. Flendrig SA.: *Het benigne ruzen lymfoom (The benign Giant lymphoma).* Proejschrift katholieke Universitat te Nijmegen, N.V. Drukkerij "Helmond", The Neder lands, 1969. J Clin Pathol 69: 86-90, 1978.