

## KUTANÖZ EPİDERMAL KİSTDEN GELİŞEN PİGMENTE BAZAL HÜCRELİ KARSİNOM: OLGU SUNUMU VE LİTERATÜRÜN GÖZDEN GEÇİRİLMESİ

### PIGMENTED BASAL CELL CARCINOMA ARISING IN A CUTANEOUS EPIDERMAL CYST: A CASE REPORT AND REVIEW OF THE LITERATURE

Zafer Teke\*, Hakan ÖÇSEL\*\*, Neşe ÇALLI DEMİRKAN\*\*\*

\*Pamukkale Üniversitesi, Tıp Fakültesi Genel Cerrahi Anabilim Dalı, Denizli

\*\*Özel Denizli Tekden Hastanesi, Plastik ve Rekonstrüktif Cerrahi Bölümü, Denizli

\*\*\*Pamukkale Üniversitesi, Tıp Fakültesi, Patoloji Anabilim Dalı, Denizli

#### Özet

Kutanöz epidermal kistler sıkça görülmesine karşın epidermal kist epitelinin neoplastik dönüşüme uğraması oldukça nadir görülmektedir. Bazal hücreli karsinomlar, melanom dışı tüm deri kanserlerinin yaklaşık olarak %80' ini oluşturmaktadır. Düşük metastaz potansiyeline sahip olduklarından bazal hücreli karsinomun tedavisi lokal kontrole dayanır. Bu yazıda epidermal kist duvarından gelişen pigmente bazal hücreli karsinom olgusu güncel bilgiler ışığında sunulmaktadır. (Pamukkale Tıp Dergisi, 2008;1:32-34).

#### Abstract

Although cutaneous epidermal cysts are frequently seen, neoplastic transformation of their epithelium is quite rare. Basal cell carcinomas constitute approximately 80 percent of all non-melanoma skin cancers. Given its low metastatic potential, treatment of basal cell carcinoma focuses on local control. We herein report a case of pigmented basal cell carcinoma arising in the wall of an epidermal cyst. (Pamukkale Medical Journal, 2008;1:32-34).

#### Introduction

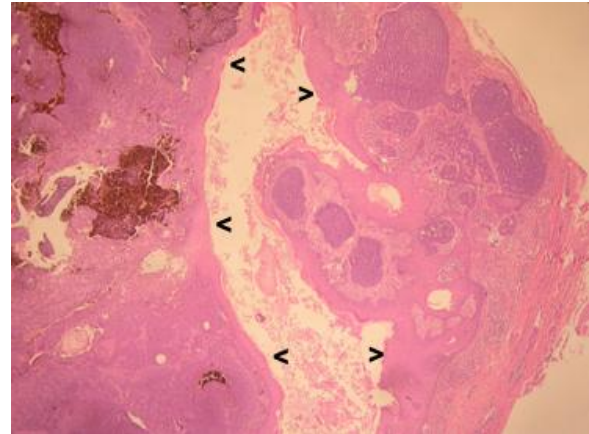
Although histologic examination of epidermal cysts rarely discloses malignancy, isolated cases of premalignant and malignant conditions have been described in their walls. These include Merkel cell carcinoma, basal cell carcinoma, bowenoid papulosis, Bowen's disease, Paget's disease, and mycosis fungoides. Basal cell carcinomas constitute approximately 80 percent of all non-melanoma skin cancers. Given its low metastatic potential, treatment of basal cell carcinoma focuses on local control. Here we report a case of pigmented basal cell carcinoma arising from an epidermal cyst, present in the left popliteal area of a 50-year-old woman.

#### Case Report

A 50-year-old woman presented with a slowly growing mass on her left popliteal area of 3 years duration. Physical examination revealed a round, firm, nontender, grayish in color subcutaneous tumor with multiple black punctates on its surface, approximately 25 mm in diameter. With the provisional diagnosis of sebaceous cyst, an excision was performed under local anesthesia.

The entire biopsy specimen was routinely fixed, processed, and stained with hematoxylin-eosin.

On gross examination, it measured 1x0.8x0.7cm, and its center was occupied with brownish material. Microscopic examination revealed, at scanning magnification, a cyst filled with keratinized material and lined by stratified squamous epithelium, exhibiting keratinization (Figure 1).



**Figure 1.** The cyst wall lined by stratified squamous epithelium, exhibiting keratinization (arrowheads) (H&E, x200).

There was plenty of melanin pigmentation within and around the islands of tumor (Figure 2). An extensive tumoral infiltration in the shape of interrelated bands as well as irregular, widened,

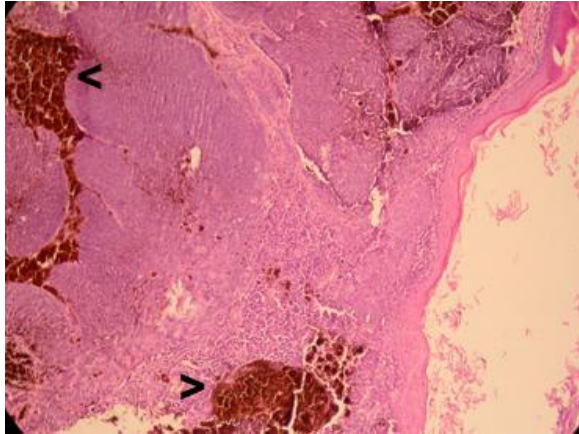
Op.Dr.Zafer Teke

Adres: Pamukkale Üniversitesi, Tıp Fakültesi Genel Cerrahi A.D., 20070 Kınıklı, Denizli

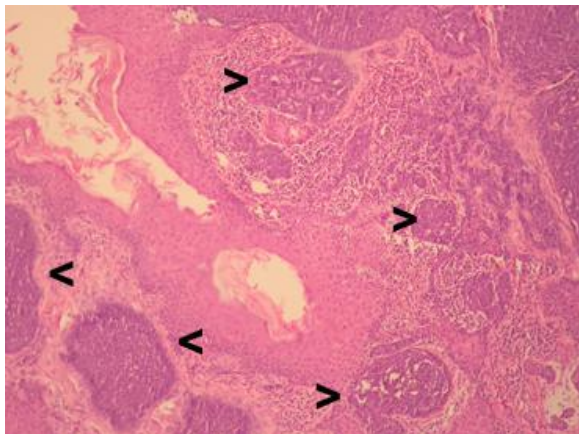
e-posta:zteke\_md@yahoo.com, zteke\_md@hotmail.com

Tel: +90 258 2648991 GSM: +90 542 2644046 Fax: +90 258 2134922

solid islands that composed of atypical basal epithelial cells with oval or round-shaped, mildly hyperchromatic nuclei was seen within the fibrocollagenous tissue in the periphery of the cyst (Figure 3).



**Figure 2.** Melanin pigmentation within and around the islands of tumor (arrowheads) (H&E, x200).



**Figure 3.** Islands of basal cell carcinoma and an extensive tumoral infiltration within the fibrocollagenous tissue in the periphery of the cyst (arrowheads) (H&E, x200).

Also, an infiltration of mononuclear cells was noted between the islands of tumor. Therefore, a diagnosis of pigmented basal cell carcinoma arising in the wall of an epidermal cyst was rendered. Since the margins of resection were positive of tumor, the surgical field was widely reexcised one week later. Eventually, all surgical margins were free of tumor. The patient remains free of disease at last follow-up, 18 months from her initial diagnosis and surgical management.

### Discussion

We herein report a case of basal cell carcinoma arising in the wall of an epidermal cyst. This is a rare report in documenting the occurrence of basal cell carcinoma arising from an epidermal cyst. Documentation of the occurrence of non-squamous carcinoma, namely basal cell

carcinoma of an epidermal cyst other than conventional squamous cell carcinoma, is of paramount importance in the context of skin cancers as this would alert clinicians and specialists to include basal cell carcinoma in their differential diagnosis of ominous skin lesions.

Keratinous cysts are lined by stratified epithelium, which may keratinize either with the formation of keratohyalin, forming a horny material resembling the epidermis, or without the formation of keratohyalin, forming trichilemmal keratin [1]. Furthermore, keratinous cysts are divided into epidermal cysts, which consist of stratified epithelium containing keratohyalin granules, and trichilemmal cysts, which lack keratohyalin granules. Keratinous cysts, especially epidermal cysts, are one of the most common skin lesions to be excised, while trichilemmal cysts are less common. Epidermal cysts are seen frequently, but malignant tumors arising from epidermal cysts are rare. Delacretaz reviewed 77 malignant tumors arising from a keratinous cyst. Among these cases, 18 were basal cell carcinomas. In the basal cell carcinoma cases arising from a keratinous cyst, 8 were from an epidermal cyst [2].

Basal cell carcinoma is the most common malignancy among fair people in the world [3]. Although patients usually present with basal cell carcinoma in the fifth to eighth decades of life, the age range may be much wider, and there are reports of tumors occurring in the second decade of life. In most series there appears to be a male predominance. Basal cell carcinoma most often arises in areas of long-term sun exposure, with a high predilection for the head and neck area [4-8]. However, our patient was a 50-year-old woman and her lesion was in her left popliteal area.

The clinical and histologic presentations of basal cell carcinoma are varied. Clinically, it is usually slowly progressive, presenting as a papule, nodule, plaque, ulcer or cyst. The color is usually red to white but may be blue-black. There is a characteristic pearly translucence to most lesions when placed on the stretch and overlying telangiectases are common. A small percentage of lesions aggressively invade deeper tissues and some rare cases metastasize. Histologically, basal cell carcinoma is composed of islands or nests of basaloid cells with peripheral palisading and frequent mitotic figures [4,9,10]. However, clinically our patient presented with slowly growing mass on her left popliteal area of 3 years duration and physical examination revealed a round, firm, nontender,

grayish in color subcutaneous tumor with multiple black punctates on its surface, approximately 25 mm in diameter. Histologically, an extensive tumoral infiltration was seen within the fibrocollagenous tissue in the periphery of the cyst and it was noted that there was plenty of melanin pigmentation within and around the islands of tumor. Therefore, a diagnosis of pigmented basal cell carcinoma was rendered. Risk factors for extensive subclinical spread include a tumor diameter greater than 2 cm, location on the central part of the face or ears, long-standing duration, incomplete excision, an aggressive histologic pattern of growth, and perineural or perivascular involvement. Tumors with subclinical extension or indistinct borders are more frequently associated with residual positive margins after excision and have a higher recurrence rate than more limited or well-defined tumors. Risk factors for metastasis are similar to those for recurrence. Basal cell carcinoma most often metastasizes to the regional lymph nodes, followed by bone, lung, and liver [9].

Treatment of basal cell carcinoma can be surgical or nonsurgical. Surgical approaches include curettage and electrodesiccation, cryosurgery, surgical excision, and Mohs micrographic surgery. Nonsurgical approaches include radiotherapy, topical and injectable therapy, and photodynamic therapy. Surgical excision has the advantage of including histologic evaluation. Patients with incompletely excised primary lesions should undergo surgical reexcision shortly after the initial procedure to confirm the presence of clear margins; this procedure results in improved cure rates and reduces the subsequent need for more complicated resection of recurrent tumors [11]. In the present case, we preferred performing surgical excision. Since the margins of resection were positive for tumor, the surgical field was

widely reexcised one week later. Eventually, all surgical margins were free of tumor. Our patient was free of recurrent clinical disease at the time of reporting.

This is a rare case report of basal cell carcinoma arising from an epidermal cyst. Although malignant transformation may be a rare event, we recommend histological examination of all epidermal cysts.

## References

1. Mehregan AH. Cysts related to the adnexa. In: Mehregan AH, editor. *Pinkus' Guide to Dermatopathology*. 4th ed. Norwalk, Appleton-Century-Crofts; 1986. p. 483-91.
2. Delacretaz J. Keratotic basal-cell carcinoma arising from an epidermoid cyst. *J Dermatol Surg Oncol* 1977;3:310-1.
3. Wong CSM, Strange RC, Lear JT. Basal cell carcinoma. *BMJ* 2003;327:794-8.
4. Weedon D. Tumors of the epidermis. Basal cell carcinoma. In: Weedon D, editor. *Skin Pathology*. 1st ed. London, Churchill Livingstone, Harcourt Publishers; 1997. p. 647-51.
5. Scrivener Y, Grosshans E, Cribier B. Variations of basal cell carcinomas according to gender, age, location and histopathological subtype. *Br J Dermatol* 2002;147:41-7.
6. Rahbari H, Mehregan AH. Basal cell epithelioma (carcinoma) in children and teenagers. *Cancer* 1982;49:350-3.
7. Bastiaens MT, Hoefnagel JJ, Bruijn JA. Differences in age, site distribution and sex between nodular and superficial basal cell carcinomas indicate different type of tumors. *J Invest Dermatol* 1998;110:880-4.
8. Tran H, Chen K, Shumack S. Epidemiology and aetiology of basal cell carcinoma. *Br J Dermatol* 2003;149:50-2.
9. Walling HW, Fosko SW, Geraminejad PA. Aggressive basal cell carcinoma: presentation, pathogenesis, and management. *Cancer Metastasis Rev* 2004;23:389-402.
10. Sexton M, Jones DB, Maloney ME. Histologic pattern analysis of basal cell carcinoma. Study of a series of 1039 consecutive neoplasms. *J Am Acad Dermatol* 1990;23:1118-26.
11. Rubin AI, Chen EH, Ratner D. Basal-Cell Carcinoma: current concepts. *N Engl J Med* 2005;353:2262-9.