

LIMA as a graft for CABG in polyarteritis nodosa

Polyarteritis nodoza da CABG için LIMA grefti kullanımı

Funda Yıldırım, Tolga Onur Badak, Adnan Taner Kurdal, İhsan İşkesen, Bekir Hayrettin Şirin

Celal Bayar Üniversitesi, Tıp Fakültesi, Kalp ve Damar Cerrahisi AD, Manisa

Abstract

A 54-year-old male patient with polyarteritis nodosa, treated with percutaneous coronary interventions and three stent implantations because of repeated myocardial infarctions presented again with ST-elevated myocardial infarction. The last coronary angiography revealed critical LAD instent stenosis and also Cx lesions. The patient underwent two-vessel coronary artery bypass graft and discharged without any problem. LIMA is used as a conduit for coronary artery bypass for the treatment of this patient and the surgical management of this patient is discussed here.

Pam Med J 2012;5(3):143-145

Key words: Polyarteritis nodosa, LIMA, coroner artery bypass.

Özet

54 yaşında, erkek, poliarteritis nodosa tanılı, tekrarlayan myokard enfarktüsü nedeniyle perkütan koroner girişim ve 3 kez stent implantasyonu uygulanmış hasta, tekrar ST eleve myokard enfarktüsü nedeniyle kabul edildi. Yapılan koroner anjiyografisinde kritik LAD instent stenoz ve Cx lezyonları saptandı. Hastaya 2 damar koroner arter bypass cerrahisi uygulandı ve sorunsuz olarak taburcu edildi. Bu hastada LİMA kondüit olarak kullanıldı ve burada bu hastanın cerrahi tedavisi tartışıldı.

Pam Tıp Derg 2012;5(3):143-145

Anahtar sözcükler: Poliarteritis nodosa, LİMA, koroner arter bypass.

Introduction

Polyarteritis nodosa (PAN) is a segmental necrotizing inflammation of medium and small sized arteries, with secondary ischemia of tissue supplied by affected vessels [1]. Renal, hepatic, cardiac, gastrointestinal tract, skin, nerves, joints and muscles are the ones that are affected most frequently.

This uncommon disease typically presents with fever, generalized fatigue, symptoms of peripheral neuropathy, weakness, weight loss, myalgia, and arthralgia, renal and mesenteric ischemia. The annual incidence of PAN is 2.4 per million [2]. The average onset age is generally between 40 and 50 years old and affects men more compared to women, male:female ratio 3:1. The proposed mechanism of PAN is the

antigen-immune complex deposition on the arterial walls [3]. The pathologic process most commonly occurs at points of vessel bifurcation, beginning in the media and extending into the intima and adventitia of medium-size arteries, often disrupting the internal elastic membrane. Lesions are seen in all stages of development and healing. Immunoglobulin, complement component and fibrinogen are deposited in the lesions. Intimal proliferation with secondary thrombosis and occlusion leads to organ and tissue infarction. Weakening of the muscular vessel wall may cause small aneurysms and arterial dissection. Since no serologic tests for polyarteritis are specific, diagnosis depends on demonstrating necrotizing arteritis on biopsy of typical lesions or angiographic display of typical aneurysm on medium-sized vessels. The

Funda Yıldırım

Yazışma Adresi: Celal Bayar Üniversitesi, Tıp Fakültesi, Kalp ve Damar Cerrahisi AD, Manisa
e-mail: fundanizamoglu@yahoo.com

Gönderilme tarihi: 04.05.2012

Kabul tarihi: 03.07.2012

knowledge about the choice of bypass grafting of patients with PAN is limited in literature. Hence, in this text we discussed the management of the treatment and also whether the graft choice of a patient with PAN who presented with ST elevated myocardial infarction referred to the surgical intervention.

Case

A 54-year-old man who had previously been diagnosed with coronary artery disease was admitted to the emergency service with a 30 minute-lasting typical resting chest pain. His first cardiac event was 3 years ago and 1 year ago stent implantation in proximal LAD (left anterior descending coronary artery) had been performed. His cardiac risk factors are detected as hypertension, diabetes mellitus and polyarteritis nodosa. The patient had also hepatitis B infection without delta agent and was treated with tenofovir disoproksil fumarat.

In this patient PAN was diagnosed clinically 4 years ago with the complaints of arthralgia, weight loss and swelling of legs. Detailed examinations showed that millimeter sized aneurysms were detected in intrarenal arteries (Figure 1) and distal superior mesenteric artery branches (Figure 2) and these were evaluated as PAN lesions. The patient has used oral prednisolon treatment for 4 years and because of steroid usage diabetes mellitus has been seen for the last 1 year. The patient had been operated due to lumbar disc herniation 12 years ago, had cerebrovascular event 3 years ago and has had hepatitis B infection for 4 years. The patient was a heavy smoker for 15 years smoking 1,5 packet per day and he has spent the last 17 years without smoking and had chronic changes for emphysema which were observed on thorax computerized tomography.

3 months ago the patient had right hip prosthesis operation at orthopedia clinic because of aseptic necrosis of right femur head.

At this visit, coronary angiography was repeated and new lesions on Cx (circumflex coronary artery) artery and in-stent restenosis on LAD were detected. Coronary lesions were LAD 95% in-stent restenosis, Cx 60% and ejection fraction is 50%. Coronary artery bypass grafting (CABG) was performed with left internal mammary artery (LIMA) to LAD and saphenous vein graft to obtuse marginal branch of Cx artery. Neither any aneurysm of the coronary arteries nor aneurysm of the LIMA could be detected intraoperatively. For this reason, we prefer to use LIMA for LAD revascularization. There were no problems in the postoperative course and the patient was discharged from the hospital 6 days later.

Discussion

Premature coronary artery disease is an important predictor of overall morbidity and mortality in patients with vasculitis syndromes [4]. The coronary involvement of PAN include atherosclerosis, diffuse coronary aneurysm, acute coronary dissection and rupture, thrombosis and arteritis of coronaries [5]. PAN affects the coronary arteries in 50% of the patients and, microscopically, all layers of the arterial wall are involved [3]. Signs and symptoms of coronary arteritis are generally composed of hypertension (most common), tachycardia, congestive heart failure, murmurs, cardiomegaly, pericardial friction rubs and arrhythmias [3]. Our patient had undergone percutaneous coronary intervention and, after all, was referred to our clinic for surgical revascularization.

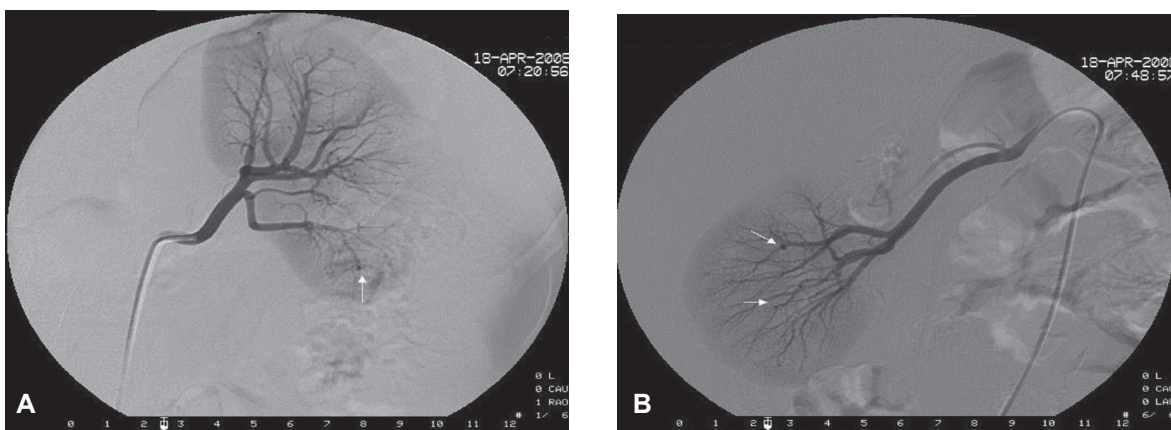


Figure 1. Angiographic views of the left kidney indicate small aneurysms (arrows).

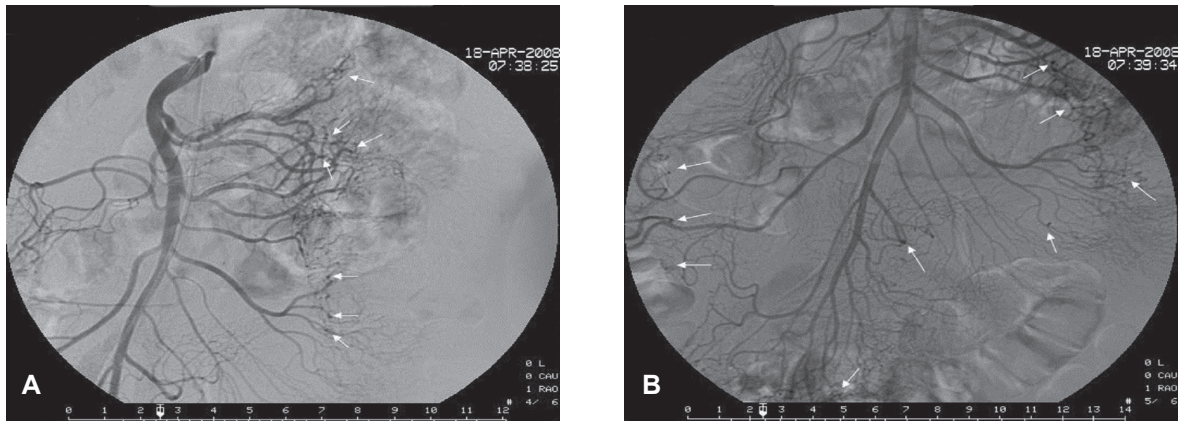


Figure 2. Angiographic views of the superior mesenteric artery indicate small aneurysms (arrows).

The discussion about the choice of bypass grafting of patients with PAN is limited in English literature. Only three case reports can be found describing CABG in a patient with PAN [3,6,7]. The first patient underwent quadruple SVGs (saphenous vein graft) bypass. The rationale for graft choice was not discussed in the context.

Identified patient could not be weaned from cardiopulmonary bypass and died secondary to ventricular fibrillatory arrest. For the second patient, the SVGs were used for two aortocoronary bypass grafts to the left anterior descending coronary artery and to the right coronary artery, and the authors stated the importance of using vein and not the arterial grafts. The third patient underwent four-vessel coronary artery bypass grafts. LIMA was used for LAD revascularization and SVGs were used for diagonal, obtuse marginal and posterior descending coronary artery revascularization. The authors explained LIMA preference as without being free of any vasculitic process according to the intraoperative appearance. In our case, we also observed no aneurysmal changes during LIMA harvesting and coronary artery exposure in the surgical intervention.

In our case the LIMA and SVG were used for coronary revascularization. So far, 10 cases of mammary artery involvement of PAN have been described in the literature, interestingly all in women [8]. Generally the demonstrated long-term patency with the use of internal mammary artery bypass graft outweighs the potential risk of arteritis development. However, angiographic imaging of the LIMA to rule out the stenosis or aneurysm development may be more reliable.

It is recommended that vasculitis should be controlled medically until the time of surgery by supplying normal erythrocyte sedimentation rate and C-reactive protein levels. However, in the existence of the active arteritic process,

clinical judgement should be used to weigh the risks and benefits of delaying coronary revascularization versus operating in an active inflammatory course.

Both our patient and one of the case report patients had previously PTCA and stent implantation at vascular laboratory. Early occlusion and repeated myocardial infarctions were seen and this leads to more myocardial damage. Because of this possibility we recommended that instead of stent implantation, primary surgical revascularization with the usage of LIMA graft should be performed.

Conflict of interest: The authors declared no conflict of interest.

References

1. Berkow R (Editor in chief). The MERCK MANUAL of diagnosis and therapy. Bondy P, Dilts P, Douglas R et al. Musculoskeletal diseases. 16th ed. Merck & Co. Inc, Rahway New Jersey USA: 1992;1327-1330.
2. Watts RA, Jolliffe VA, Carruthers DM, Lockwood M, Scott DG. Effect of classification on the incidence of polyarteritis nodosa and microscopic polyangiitis. *Arthritis Rheum* 1996;39:1208-1212.
3. Guillevin L, Lhote F, Cohen P, et al. Polyarteritis nodosa related to hepatitis B virus. A prospective study with long term observation of 41 patients. *Medicine (Baltimore)* 1995;74:238-253.
4. Uçar HI, Oç M, Tok M, Ozyüksel A, Oç B, Farsak B. Coronary artery bypass with saphenous vein graft in the middle-aged patient with polyarteritis nodosa. *Anadolu Kardiyol Derg* 2007;7:231-232.
5. Chu KH, Menapace FJ, Blankenship JC, Hausch R, Harrington T. Polyarteritis nodosa presenting as acute myocardial infarction with coronary dissection. *Cathet Cardiovasc Diagn* 1998;44:320-324.
6. Cassling RS, Lortz JB, Olson DR, Hubbard TF, McManus BM. Fatal vasculitis of the coronary arteries: angiographic ambiguities and absence of aneurysm at autopsy. *J Am Coll Cardiol* 1985;6:707-714.
7. Yanagawa B, Kumar P, Tsuneyoshi H, et al. Coronary artery bypass in the context of polyarteritis nodosa. *Ann Thorac Surg* 2010;89:623-625.
8. Trüeb RM, Scheidegger EP, Pericin M, et al. Periarteritis nodosa presenting as a breast lesion: report of a case and review of the literature. *Br J Dermatol* 1999;141:1117-1121.