

Evaluation Of The Effect Of Autologous Dermis Graft On Rat Achilles Tendon Healing

Otolog Dermis Greftinin Rat Aşıl Tendonu İyileşmesi Üzerindeki Etkisinin Değerlendirilmesi

Muhammet Doğan^{1*}, Mehmet Mesut İnan², İkrâm Esen³, Mehmet Bayram⁴, Serkan Erbatur⁵

1. Plastic, Reconstructive and Aesthetic Surgery, Alanya Training and Research Hospital, Antalya, Türkiye

2. Plastic, Reconstructive and Aesthetic Surgery, Şanlıurfa Training and Research Hospital, Şanlıurfa, Türkiye

3. Plastic, Reconstructive and Aesthetic Surgery, Göztepe Süleyman Yalçın City Hospital, İstanbul, Türkiye

4. Plastic, Reconstructive and Aesthetic Surgery, Mehmet Akif İnan Training and Research Hospital, Şanlıurfa, Türkiye

5. Plastic, Reconstructive and Aesthetic Surgery, Dicle University Faculty of Medicine Hospital, Diyarbakır, Türkiye

ABSTRACT

Aim: The Achilles tendon is one of the most frequently injured tendons. It is more common in young and middle-aged individuals who are particularly active in sports. Re-surgery or permanent disabilities may occur as a result of tendon rupture after tendon repair. Various methods to enhance Achilles tendon healing have been described in the literature. However, there is limited data on the use of dermis grafts for tendon augmentation. Dermis grafts; Since they are core tissue, they have less foreign body reaction, can be obtained in a short time, and can be an alternative due to less donor area morbidity. The aim of our study is to reduce the risk of re-rupture by strengthening tendon healing in Achilles tendon injuries and to determine the effectiveness of autologous dermis grafts on healing for strong healing.

Methods: In our study, 20 male rats were randomly divided into two groups as Control and Experimental groups. All rats underwent tendon repair after an atraumatic, full-thickness, straight incision was applied to the right Achilles tendon. After tendon repair in the rats in the experimental group; dermis grafts taken from the back were wrapped around the tendon repair area and sutured. The other rats constituted the control group. Rats were sacrificed at week 4 and their Achilles tendons were removed and examined histopathologically, immunohistochemically and biomechanically.

Results: Tendons were intact and no rupture was observed in all samples. Positive results were observed in favor of the experimental group in type I collagen and type I/type III collagen density and biomechanical examinations in rats repaired with dermis grafts.

Conclusion: As a result of our study; it was shown that dermis grafts can positively contribute to tendon healing. Tendon repair with dermis grafts can be a good alternative to other methods for tendon augmentation or strengthening.

Keywords: Achilles tendon, Tendon healing, Dermis graft

ÖZ

Amaç: Aşıl tendon sık yaralanan tendonlardan, özellikle aktif spor uğraşı olan genç-orta yaşta bireylerde daha sık görülmektedir. Tendon tamiri sonrası tendonun tekrar kopması sonucunda tekrar ameliyat veya kalıcı sakatlıklar gelişebilmektedir. Literatürde aşıl tendon iyileşmesini artırıcı çeşitli yöntemler tarif edilmiştir. Ancak, dermis greftin tendon augmentasyonu amacıyla kullanımına dair kısıtlı veri mevcuttur. Dermis greftleri; öz doku olduğundan yabancı cisim reaksiyonu az, kısa zamanda alınabilen ve daha az donör alan morbiditesi nedeniyle alternatif olabilecek niteliktedir. Çalışmamızdaki amaç, aşıl tendon yaralanmalarında tendon iyileştirmesini güçlendirirerek tekrar kopma riskini azaltmak ve güçlü iyileşme için otolog dermis greftinin iyileşme üzerinde etkinliğini belirlemektir.

Yöntem: Çalışmamızda 20 erkek rat Kontrol ve Deney grubu olarak rastgele iki gruba ayrıldı. Tüm ratların sağ aşıl tendonuna atravmatik, tam kat, düz kesi uygulandıktan tendon onarımı yapıldı. Deney grubundaki ratlara tendon onarımı sonrasında; sırttan alınan dermis grefti tendon onarım bölgesine sarılarak sütüre edildi. Diğer ratlar kontrol grubunu oluşturdu. Ratlar 4. haftada sakrifiye edilerek aşıl tendonları çıkartılarak histopatolojik, immünohistokimyasal ve biyomekanik olarak incelendi.

Bulgular: Bütün numunelerde tendon intakt ve rüptür gözlenmedi. Dermis grefti ile onarım yapılan ratlarda tip I kollajen ve tip I/tip III kollajen yoğunluğunda ve biyomekanik incelemelerde deney grubu lehine olumlu sonuçlar izlendi.

Sonuç: Çalışmamız sonucunda; dermis greftinin tendon iyileşmesine olumlu katkı sağlayabileceğini gösterdi. Dermis grefti ile tendon onarımı; tendon augmentasyonu veya güçlendirmesi için diğer yöntemlere göre iyi bir alternatif olabilir.

Anahtar Kelimeler: Aşıl tendon, Tendon iyileşmesi, Dermis grefti

Received: 23/10/2024 Accepted: 23/02/2025 Published (Online): 01/04/2025

*Corresponding Author: Muhammet Doğan, MD. Alanya Eğitim ve Araştırma Hastanesi, Oba mah., Fidanlık cad., 07400, Alanya, Antalya, Türkiye. Phone: +905333097578 / mail: drdoganmuhammet@gmail.com

Orcid: 0000-0002-0692-6854

To cited: Doğan M, İnan MM, Esen İ, Bayram M, Erbatur S. Evaluation Of The Effect Of Autologous Dermis Graft On Rat Achilles Tendon Healing. Acta Med. Alanya 2025;9(1): 19-28 doi: 10.30565/medalanya.1557602

Introduction

Tendon injuries are an important reason for emergency room visits in daily life. Achilles tendon is one of the most frequently injured tendons, and most commonly occurs in the form of injuries with sharp objects, firearms, crushing, and closed injuries. It is especially seen in young-middle-aged men, and its annual incidence in the society is reported as 7-40/100,000 [1].

Degeneration and inadequate perfusion in the Achilles tendon over time pose a risk for rupture. Although conservative and surgical options are available in treatment options, surgical repair of the tendon has become more popular in recent years [2]. While the immobilization period is found to be shorter in patients who undergo surgery compared to conservative treatment, the risks of re-rupture are found to be lower in open technique tendon repair. Especially in athletes, the return to work times in Achilles ruptures seriously affect the athlete's career.

Complications such as re-rupture are frequently encountered in patient follow-ups after tendon repair is performed surgically. This situation may cause negative situations such as partial or complete disability of limb function in patients, in addition to repeated surgeries.

Various methods have been tried in the literature to strengthen the Achilles tendon, which has a problematic healing due to insufficient perfusion. Various biological materials such as pantaris tendon graft, fascial flaps, synthetic grafts and acellular dermal matrix have been used for tendon strengthening [2-4]. In addition, various injections such as stem cells, PRP, autologous serum, growth factors, hydrogels have been made to the repair area to strengthen tendon healing [3,4]. Some studies have shown that the re-rupture rate of repair with skin-equivalent biological material is lower [5]. In this field, where many different materials are investigated, a complete solution for reinforced tendon repair has not been produced.

In our study, in order to prevent these complications that we frequently encounter after tendon repair; We planned to use the dermis graft, which is a subunit of the skin tissue that is currently used in many operations such as dorsum in rhinoplasty

[6] and philtral column augmentation in cleft lip surgery and scar revision. When the skin and tendon are examined histologically, they have common cellular content in terms of type 1 collagen and fibroblasts. Therefore, the dermal layer of the skin can be used to strengthen the repair after tendon repair. Although there are experimental studies on dermis grafts in rats in the literature [7], no study on dermis grafts on tendon healing was found. In our study, it was aimed to use dermis grafts for tendon strengthening following the repair after atraumatic full-thickness Achilles tendon transection.

Materials and Methods

Our study was conducted with the approval of the Local Animal Experiments Ethics Committee using 20 male Sprague Dawley rats aged 2-3 months and weighing between 300-350 g. The rats were randomly divided into 2 groups, each consisting of 10 rats in the control and experimental groups. The right Achilles tendons of all rats were cut in full thickness approximately 0.5 cm proximal to the calcaneus attachment and repaired with the modified Kessler method in the same session. Dermis grafts taken from the backs of 10 rats were placed in the tendon repair area in the same session and this group constituted the experimental group, while the other 10 rats remained as the control group. All rats were sacrificed at the end of the 28th day and Achilles tendon samples were taken. All surgical procedures were performed under aseptic conditions and general anesthesia with 50 mg/kg ketamine hydrochloride and 5 mg/kg xylazine hydrochloride administered intramuscularly. After anesthesia was provided, the right hind legs of all rats were shaved, in addition to the back region of the rats in the experimental group. The surgical areas were painted with povidone-iodine solution. The skin was passed through the Achilles tendon with a 2 cm incision using the classic posteromedial longitudinal approach. The incision was made sharply up to the tendon sheath. The Achilles tendon and plantaris tendon were explored. The Achilles tendon was thoroughly stripped from the nearby soft tissues with the help of a clamp. The Achilles tendons of all rats were cut in full thickness with a scalpel blade number 11 approximately 5 mm proximal to the attachment point to the calcaneus (Figure

1). The cut tendon ends were repaired end-to-end with the modified Kessler method using 4/0 Propylene suture (Figure 2).

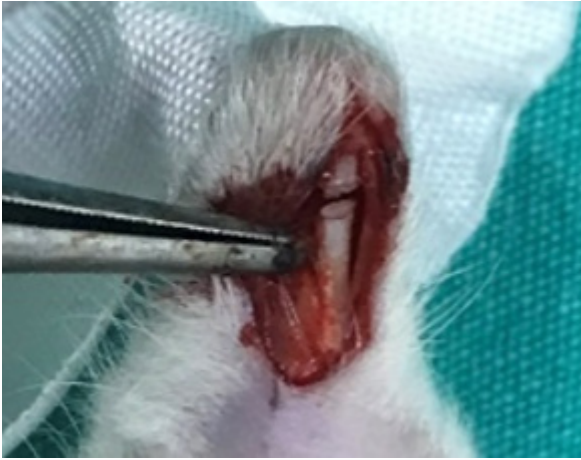

Figure 1. Incised tendon

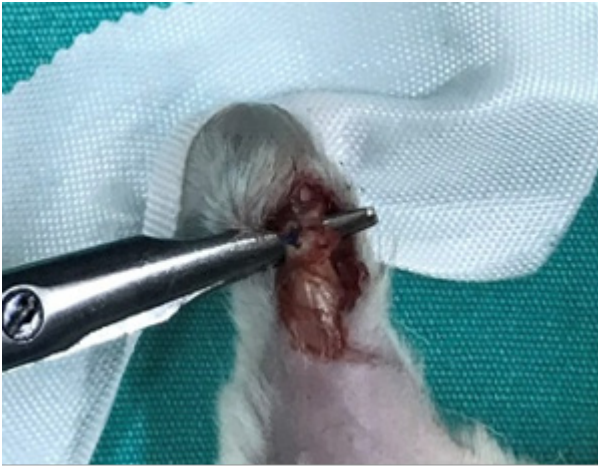

Figure 2. End-to-end repair using the modified Kessler method

The skin sutures of the rats in the control group were closed with 3/0 silk sutures without any additional surgical procedures. In the experimental group, a 1x2 cm elliptical skin island was marked on the back with a surgical pen after tendon repairs. The epidermis in the uppermost layer was de-epithelialized using a scalpel No. 10 on the marked skin island. Then, the incisions were completed and the dermis graft was taken (Figure 3). After the graft was taken, it was placed in a container containing physiological serum so that it would not retract and shrink. Then, the donor area where the graft was taken was closed by primary suturing without tension with 3/0 sharp silk suture. The dermis graft taken was placed so that it would completely surround the tendon repair area (Figure 4). Then, the ends of the dermis graft that surrounded the tendon and

became a tube were sewn end-to-end with 6/0 Tekmon sutures. Skin sutures were placed. All surgical areas were dressed with povidone-iodine solution. Immobilization was not applied to all rats. Tramadol at a dose of 5 mg/kg was administered intraperitoneally for postoperative pain control.

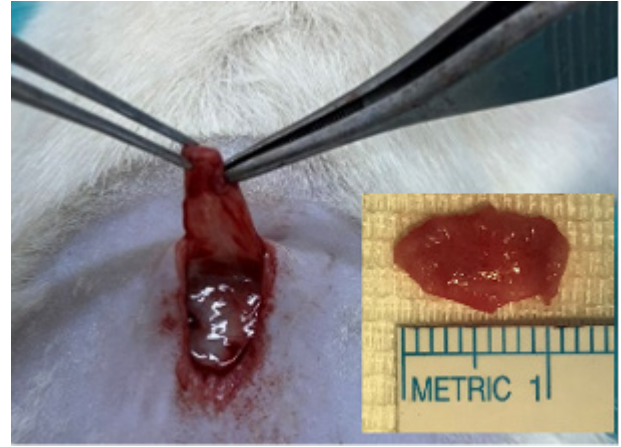


Figure 3. De-epithelialization and dermis graft

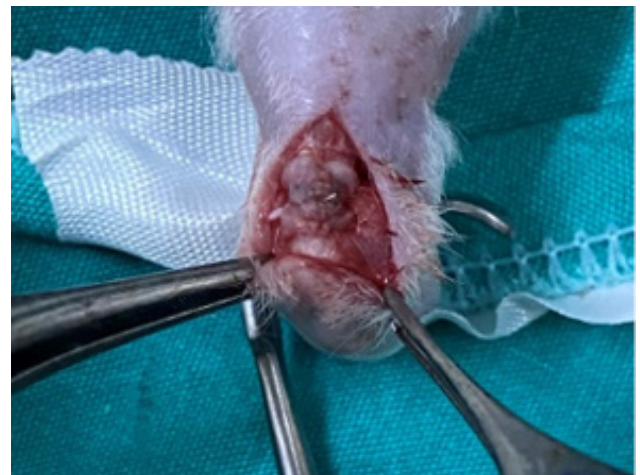

Figure 4. Tendon reconstruction with dermis graft

No loss of rats was observed in any group during the follow-up period. At the end of the 28th day, all rats were sacrificed with high-dose anesthesia. Achilles tendon samples of every 10 rats in the control and experimental groups were randomly divided into two groups of 5. 5 from each group were separated for histopathological and immunohistochemical examinations, and 5 were separated for biomechanical examinations. Samples taken for histopathological and immunohistochemical examinations were taken from the muscle-tendon junction proximally, and from the calcaneus attachment point distally below the repair site (Figure 5). For biomechanical

examinations, the muscle tissue above the muscle-tendon junction was included proximally, and the entire foot was included distally (Figure 6).

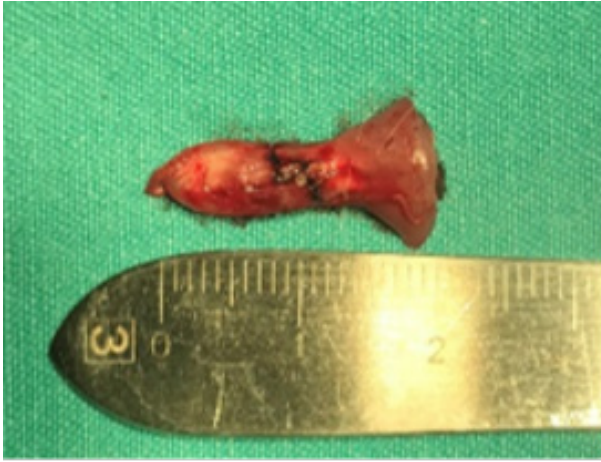

Figure 5. Histopathological sample

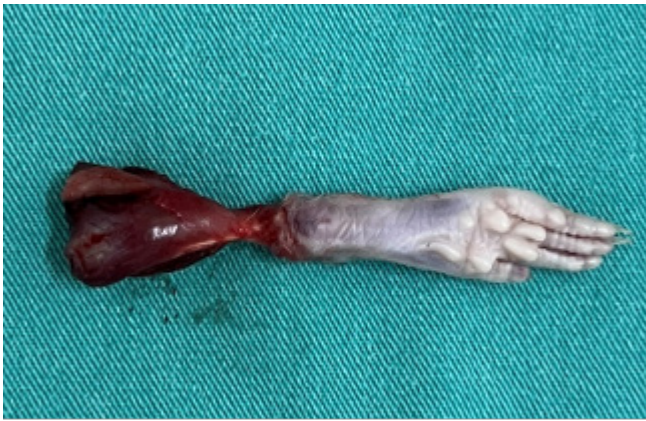

Figure 6. Biomechanical examination sample

The samples taken for histopathological and immunohistochemical examination were placed in containers containing formaldehyde and delivered to the Pathology and Biophysics Department Laboratories for examination. After routine histological follow-up procedures, 4 µm thick sections were taken from the obtained paraffin blocks with a microtome (Minux S700A Rotary Microtome) for histochemical and immunohistochemical methods. Movin scoring is based on 8 histological parameters and scores each parameter between 0-3 and then a total score is obtained [8]. A high score here indicates histopathological abnormality. On the other hand, in the Bonar design; Stage 0-3 is scored in 4 histological parameters and a total score is obtained [9]. Here, high scores indicate histopathological abnormality. Then, the samples

were stained with Hematoxylin-Eosin (HE), Alcian Blue (AB), Masson Trichrome (MT) dyes and examined with Bonar and Movin semiquantitative scores [8, 9] (Figure 7, Figure 8).

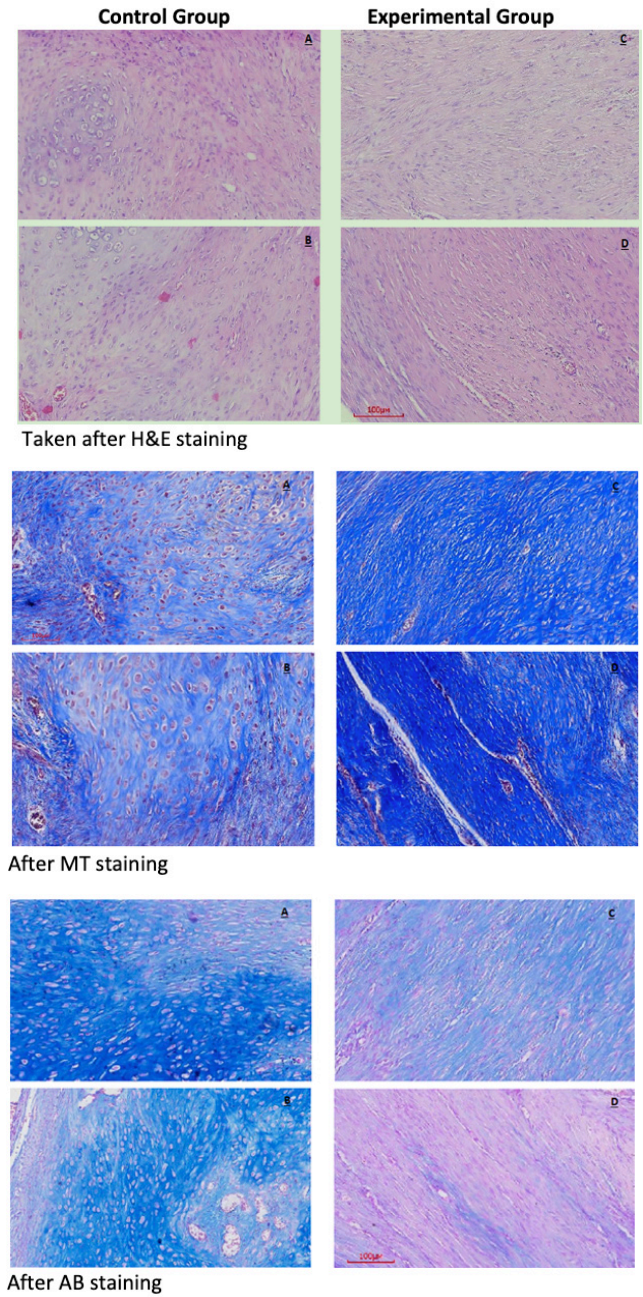


Figure 7. Histological sections

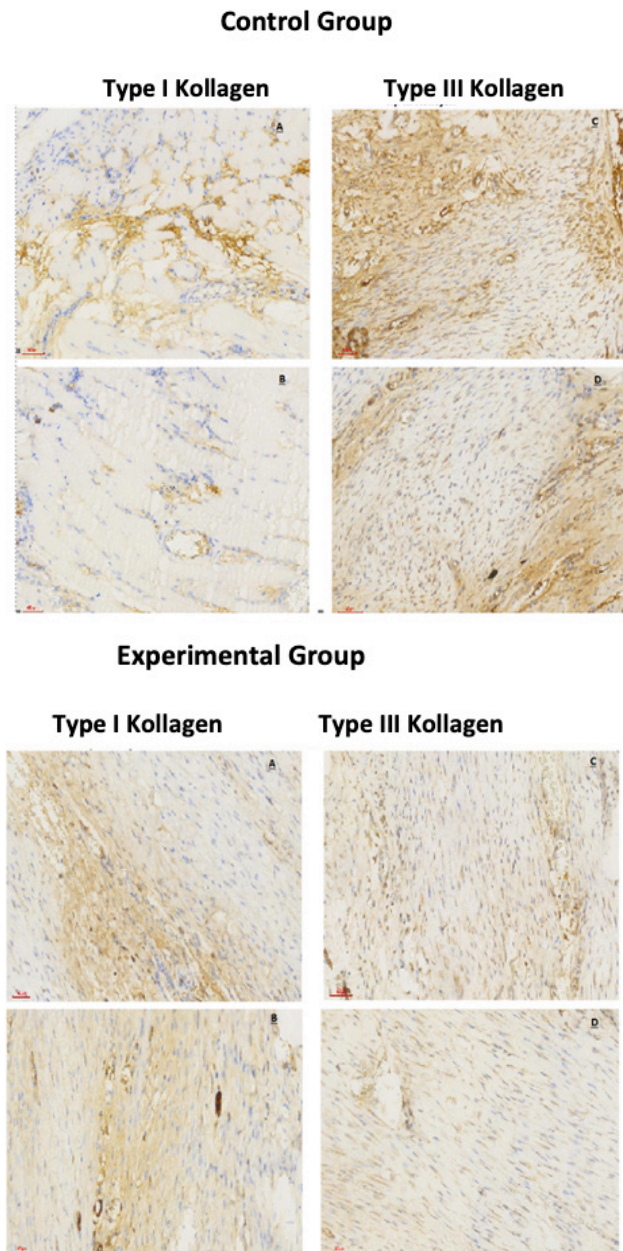


Figure 8. Collagen densities in histological sections after collagen staining.

At the end of routine immunohistochemical procedures, the preparations were examined with a light microscope. Type I and Type III collagen immunoreactivity density in tendon sections was evaluated using the Image J program. The Achilles tendons isolated for biomechanical measurement were performed with the Tension Test Device (İlfa Elektronik San. Tic. Ltd. Şti) located in the Biophysics Department Laboratory, which has a tension speed of 0-250 mm/min and a load cell capable of measuring up to a maximum of 1000 N. Before starting the biomechanical test, the initial lengths of the tendons were measured ($L \sim 8-9$

mm). Width (D ; mm), thickness (T ; mm) and initial lengths (L ; mm) were measured with a digital caliper. Then, aluminum powder was sprinkled on both ends of the tendon in order to ensure that the tendon adheres more tightly to the clamps and to prevent it from stretching. The tendons were placed in the Tension Test device with the gastrocnemius muscle tip on the lower clamps and the calcaneus tip (attached to the clamps with the foot and bones) on the upper clamps. Then, based on the literature, the distance between the clamps was set to be equal and 17 ± 3 mm, and the tension speed was set to be 25 mm/min [10]. At the end of the tensile test, the Load-Deformation data recorded on the device were transferred to the LoggerPro software (V 3.8.3, Vernier Software & Technology, Orlando, FL, USA) and evaluated. At the end of the test, the load-deformation curve was drawn and the maximum force (F_U ; N), maximum deformation (d_U ; mm), energy stored until rupture (U ; mj) and hardness (S ; N/mm) parameters were obtained directly. In addition, the maximum breaking strength (σ_U ; MPa), maximum strain (ϵ_U ; mm/mm), maximum stress (maximum tensile strength, σ_U ; MPa), elasticity modulus (E ; MPa) and durability (u ; MPa) parameters were calculated by obtaining the Stress-Strain curve [11].

Results

No rats were lost in the 28th day of follow-up after tendon repair performed on rats. The analyses of the study were performed using the SPSS 25.0 package program. Continuous numerical variables were summarized with mean \pm standard deviation, median (minimum - maximum) values. The conformity of continuous numerical variables to normal distribution was checked with the Shapiro Wilk test. It was determined that the numerical data between the groups were not normally distributed. The Mann Whitney U test was used to compare continuous numerical variables between the groups. A p value of less than 0.05 was accepted as the statistical significance limit.

The comparison of biomechanical measurement values and results of the groups is shown in Table 1. When the biomechanical measurement values were compared according to the groups; it was found that the stored energy, hardness, breaking

force, maximum deformation, Young's modulus, durability, maximum stress and maximum strain values were statistically significantly higher in the Experimental group than in the Control group ($p < 0.05$).

Comparison of Bonar scoring results of the groups is shown in Table 2. When Bonar scoring results were compared according to the groups; collagen, vascularity and Bonar score were found to be statistically significantly lower in the experimental group than in the control group ($p < 0.05$), while there was no statistically significant difference between the groups in terms of tenocyte and ground substance values ($p > 0.05$).

The comparison of Movin scoring results of the groups is shown in Table 3. When Movin scoring results were compared according to the groups; fibril structure, fibril level, nucleus roundness, increased vascularity, GAG content and Movin score were found to be statistically significantly lower in the experimental group compared to the control group ($p < 0.05$), while there was no statistically significant difference between the groups in terms of cellular change, decrease in collagen staining and hyalinization values ($p > 0.05$).

Comparison of collagen densities between groups is shown in Table 4. When collagen densities were

Table 1. Comparison of biomechanical results between groups

Parameter	Control (n = 5)		Experiment (n = 5)		p*
	Ort± SS	Med (Min-Maks)	Ort± SS	Med (Min-Maks)	
Stored energy (mj)	75,53±12,77	69,02(64,88-90,98)	132,5±38,39	116,1(104,6-198,5)	0,008
Hardness (N/mm)	19,61±4,34	20,51(14,52-25,38)	30,87±4,95	30,64(25,74-38,6)	0,008
Break force (N)	41,89±9,61	37,74(33,1-52,75)	60,82±7,72	65,17(49,65-67,24)	0,032
Max. deformation (mm)	4,11±0,78	3,7(3,4-5,19)	6,41±2,03	5,59(4,79-9,89)	0,016
Young modulus (MPa)	1,92±0,57	1,72(1,37-2,58)	3,27±0,67	3,32(2,59-4,24)	0,008
Toughness (MPa)	8,5±1,05	8,85(6,79-9,33)	13,39±1,98	13,24(11,2-16,53)	0,008
Max. stress (MPa)	4,95±1,01	5,32(3,8-5,88)	7,85±0,42	7,98(7,29-8,33)	0,008
Max. strain (mm/mm)	3,98±1,1	3,67(3,11-5,78)	7,36±1,19	7,89(5,43-8,33)	0,016

* Mann-Whitney U test, $p < 0.05$ statistically significant

Table 2. Comparison of Bonar scoring results between groups

Parameter	Control (n = 5)		Experiment (n = 5)		p*
	Ort± SS	Med (Min-Maks)	Ort± SS	Med (Min-Maks)	
Tenocyte	2,2±0,84	2(1-3)	0,8±0,84	1(0-2)	0,056
Ground material	1,8±0,84	2(1-3)	0,8±0,45	1(0-1)	0,095
Collagen	2,6±0,55	3(2-3)	1±0	1(1-1)	0,008
Vascularity	2,8±0,45	3(2-3)	1,4±0,55	1(1-2)	0,016
Bonar score	9,4±0,89	10(8-10)	4±1	4(3-5)	0,008

* Mann-Whitney U test, $p < 0.05$ statistically significant

Table 3. Comparison of Movin scoring results

Parameter	Control (n = 5)		Experiment (n = 5)		p*
	Ort± SS	Med (Min-Maks)	Ort± SS	Med (Min-Maks)	
Fibril structure	2,2 ± 0,45	2 (2 - 3)	1 ± 0	1 (1 - 1)	0,008
Fibril arrangement	2,4 ± 0,55	2 (2 - 3)	1 ± 0,71	1 (0 - 2)	0,016
Nucleus roundness	2 ± 0,71	2 (1 - 3)	1 ± 0	1 (1 - 1)	0,032
Cellular change	2,2 ± 0,84	2 (1 - 3)	1 ± 0,71	1 (0 - 2)	0,056
Increased vascularity	2,8 ± 0,45	3 (2 - 3)	1,4 ± 0,55	1 (1 - 2)	0,016
Decreased collagen staining	1,8 ± 0,84	2 (1 - 3)	0,8 ± 0,45	1 (0 - 1)	0,095
Hyalinization	1,8 ± 0,84	2 (1 - 3)	0,6 ± 0,55	1 (0 - 1)	0,056
Movin GAG content	2 ± 0,71	2 (1 - 3)	0,6 ± 0,55	1 (0 - 1)	0,016
Movin score	17,2 ± 2,39	16 (15 - 21)	7,4 ± 1,82	8 (5 - 9)	0,008

Table 4. Comparison of collagen densities between groups

Parameter	Control (n = 5)		Experiment (n = 5)		p*
	Ort± SS	Med (Min-Maks)	Ort± SS	Med (Min-Maks)	
Tip I	8,5±2,74	7,1(6,1-12,1)	18,9±5,95	19,6(11,6-24,7)	0,016
Tip III	21,7±6,71	23,1(13,6-2876)	15,7±5,25	13,2(10,8-21,5)	0,095
Tip I / Tip III	0,4±0,05	0,4(0,31-0,45)	1,3±0,7	0,98(0,67-2,29)	0,008

* Mann-Whitney U test, p<0.05 statistically significant

compared according to groups; type I collagen density and type I collagen/type III collagen ratio were found to be statistically significantly higher in the experimental group than in the control group (p<0.05), while no statistically significant difference was found between the groups in terms of type III collagen density (p>0.05).

Discussion

In this study, where the effect of autologous dermis graft on tendon healing in a rat Achilles tendon injury model was examined; histopathological, immunohistochemical and biomechanical positive results were obtained and the working hypothesis was confirmed. Since there was no study examining the effects of autologous dermis graft on tendon healing in Achilles tendon repair in detailed literature searches, this study is an original study.

Tendons are intermediate structures in the musculoskeletal system that transfer the energy received from the muscle to the bones. The Achilles tendon, which is the strongest and thickest tendon in the body, is the main plantar flexor of the foot. Achilles tendon, one of the most frequently injured tendons in the body, has acute and chronic injury types. Chronic degeneration theory is one of the basic mechanisms accused in ruptures in Achilles tendon, where ruptures are observed mostly in areas with poor vascularization [12].

Tendon healing consists of 3 phases that are not separated by sharp boundaries; inflammation, proliferation and remodeling phase. While Type III collagen is dominant at the beginning of the healing process, Type I collagen continues to dominate collagen in later periods, especially in the remodeling phase. Type III collagen, which is mostly in the healing phase, has a larger cross-sectional area compared to the healthy tendon and tends to elongate. Therefore, it cannot fulfill its functional properties biomechanically [13].

Therefore, tendons tend to rupture again in the pre-remodeling period and their tensile strength may remain lower than in the healthy tendon. Conservative and surgical treatment options are available among treatment methods. There are discussions about which treatment to use. Khan et al. [12] reported in their study that while surgical treatment had a significantly lower recurrence rate, conservative treatment had a lower complication rate. Holm et al. [14] reported that there was no significant difference in terms of complication and recurrence rates between the two treatment types. These studies show that surgical treatment is the preferred option, but alternative techniques are needed to further reduce both recurrence and complication rates.

Augmentation has been used in tendon repair to strengthen the repair site and reduce the risk of re-rupture. Although augmentation has been used in tendon repair types, particularly rotator cuff repair [15], fewer studies have been reported on its use, including randomized controlled trials in Achilles tendon treatment [16]. Different types of tendon augmentation materials are available, including autografts, xenografts, and allografts. While autografts do not carry the risk of cellular rejection, these grafts potentially increase the duration of surgery and may also cause morbidity and pain at the donor site. Although xenografts have no donor morbidity, the foreign material can cause hypersensitivity reactions in human patients, and poor clinical results have led some researchers to abandon their use for tendon augmentation [17]. Dermis grafts, a subunit of skin tissue used in many operations such as dorsum augmentation in rhinoplasty surgeries [6], philtral column augmentation in cleft lip surgeries, and scar revision, have been used successfully. There are two main problems with the use of dermis grafts; resorption and cyst formation [18,19]. Thompson reported that he obtained very good results with dermal grafts in facial reconstruction,

but a resorption rate of more than 20%. In addition, he stated that small epidermoid cysts developed from hair follicles and sebaceous glands, but these were phagocytosed over time and replaced by fibrous tissue [20]. Peer and Paddock [21] showed in their study that epidermal components remained in dermis grafts, small cavitations formed in the early period due to these, but these disappeared over time. They also reported that the epidermis, hair follicles and sebaceous glands disappeared within ten weeks; sweat glands persisted but did not show activity and there was no cyst formation. In our study, no cyst cases were encountered, similar to the literature [21].

Philip et al. [22] examined the effect of amniotic-derived multipotent progenitor cells on tendon healing in a study conducted on 126 rat Achilles tendons. The group administered amniotic-derived multipotent progenitor cells and the control group of 48 were statistically compared in terms of maximum load, but no significant difference was observed between the two groups.

Genç et al. [4] found no significant difference in maximum force comparisons between the control and PRP groups on the 15th and 30th days in their study. It was found that the values on the 15th day were lower in the control group than on the 30th day. No significant difference was found in the PRP group between the 15th and 30th days. Kim et al. [5] compared the biomechanical data between the saline and hydrogel groups on the 2nd, 4th and 8th weeks in their experimental study. In light of the data, no significant results were found in the data other than the maximum load obtained on the 4th week.

Barber et al. [23] found that the repair strength and stiffness of Achilles tendons augmented using GraftJacket matrix (Acellular dermal matrix) were statistically significant in the experimental group in their biomechanical study. Preliminary studies support the idea that these biomaterials have the ability to provide an alternative for tendon augmentation. However, there is a lack of available data that would allow definitive conclusions regarding the use of biomaterials for tendon augmentation [15]. The difficult accessibility and high costs of biomaterials, on which there is no clear consensus, should be considered regarding

their use in tendon augmentation. When we look at the biomechanical results of our study, statistically significant results were obtained in all parameters, including maximum load, in the light of the data obtained at the end of the 4th week. These results suggest that in rats subjected to equal stress under standardized conditions, the dermis graft may have a positive effect on the tendon healing process with statistically significant high maximum force values in the experimental group.

Devana et al. [24] showed that stem cell injection improved the biomechanical properties of early Achilles tendon healing after transection of the tendon using stem cells, not the histological properties. The reason why the histological properties did not change may be that the tendon injury model was performed with transection. In our study, we performed our tendon injury model by incision of the tendon. In our study, histopathological examination was performed separately according to semiquantitative Movin and semiquantitative Bonar scores. In the Movin score, fibrillar arrangement, fibrillar structure, nucleus roundness, neovascularization and GAG content were found to be statistically significantly lower in the experimental group. In the Bonar score, collagen and vascularity increase were found to be statistically significantly lower in the experimental group. Also, In our study, we investigated the effect on healing by evaluating type 1 and type 3 collagen densities with immunohistochemical evaluation using a computer program. At the beginning of the healing period, type 3 collagen synthesis is more intense in the proliferation period. Collagen densities may vary during the proliferation and remodeling period. While both type 1 and type 3 collagen synthesis increases at the beginning of the healing period, type 3 collagen synthesis is more intense. In the late healing period along with the healing process, type 1 collagen density increases in the remodeling phase, type 3 collagen density decreases, and the type 1/type 3 collagen density ratio increases [13]. In our study, we found that type I collagen density and type I/type III collagen density ratio were significantly higher in the experimental group compared to the control group. In light of the data, it can be said that the dermis graft transitioned from the proliferation phase to the remodeling phase earlier at the end of the 4-week follow-up.

Limitation

There are some limitations in our study. The limitations such as the small number of animals, the follow-up period being limited to only 4 weeks, and the lack of genetic/molecular evaluations may create some limitations on the generalizability of the study. However, due to ethical concerns, the local ethics committee recommended that the number of animals should not be too high, and on the other hand, the difficulties such as the inability to conduct genetic/molecular studies due to budget constraints were some of the possible reasons for the limitations. The limited number of animals may have affected some results. The study could have been made stronger by evaluating the tendon section diameter, adhesion and genetic studies. The follow-up period of the animals could have been longer in order to see the long-term effect. Since it was an experimental study, clinical results could not be evaluated. Further experimental studies are needed for clinical use. Future studies can be designed with greater scope in terms of sample size and follow-up duration. Furthermore, genetic and molecular studies can be added to these comprehensive designs.

Conclusion

The results of this study show that dermis grafts can contribute positively to tendon healing. Tendon repair with dermis grafts may be a good alternative to other methods for tendon augmentation or strengthening. Because of There is no standardized protocol yet for tendon augmentation after Achilles tendon injuries. The biomaterials, drugs and other methods used for augmentation are not easily accessible and their high costs limit their use. Donor site morbidity and surgical extraction can be considered disadvantages in autologous grafts. The experience of the surgeon and studies in the literature are important in terms of the materials and techniques to be used. According to the data we obtained in this study, dermis grafts can be used for tendon augmentation. However, further experimental studies are needed for clinical use.

Conflict of Interest: No conflict of interest was declared by the authors.

Financial Disclosure: The authors declared that this study has received no financial support.

Ethics Committee Approval: Permission for this study was obtained by the Dicle University Animal Experiments Local Ethics Committee (DÜHADEK) with the protocol number 2022/41 dated 30.06.2022.

Aknowlegment: This study was produced from the thesis of the first and responsible author. This research was supported by Dicle University Scientific Research Projects Coordination Office with project number TIP.22.029.

ORCID and Author contribution: **M.D.(0000-0002-0692-6854):** Consept and Design, Manuscript Writing **M.M.İ.(000-0002-0433-357X):** Data collection, Analysis and İnterpreation **İ.E.(0009-0004-6543-275X):** Data collection, Analysis and İnterpreation **M.B.(0000-0001-6868-3619):** Literature search, Manuscript Writing **S.E.(0000-0001-8739-7474):** Critical Review

Peer-review: Externally peer reviewed

REFERENCES

- Lemme NJ, Li NY, DeFroda SF, Kleiner J, Owens BD. Epidemiology of Achilles Tendon Ruptures in the United States: Athletic and Nonathletic Injuries From 2012 to 2016. *Orthop J Sports Med* 2018;6(11):2325967118808238. doi: 10.1177/2325967118808238.
- Rosenzweig S, Azar FM. Open repair of acute Achilles tendon ruptures. *Foot Ankle Clin* 2009 ;14(4):699-709. doi: 10.1016/j.fcl.2009.07.002
- González-Quevedo D, Díaz-Ramos M, Chato-Astrain J, Sánchez-Porras D, Tamimi I, Campos A, et al. Improving the regenerative microenvironment during tendon healing by using nanostructured fibrin/agarose-based hydrogels in a rat Achilles tendon injury model. *Bone Joint J* 2020;102-B(8):1095-106. doi: 10.1302/0301-620X.102B8.BJJ-2019-1143.R2.
- Genç E, Yüksel S, Çağlar A, Beytemur O, Güleç MA. Comparison on effects of platelet-rich plasma versus autologous conditioned serum on Achilles tendon healing in a rat model. *Acta Orthop Traumatol Turc* 2020;54(4):438-44. doi: 10.5152/j.aott.2020.18498.
- Kim MY, Famebo S, Woon CYL, Schmitt T, Pham H, Chang J. Augmentation of tendon healing with an injectable tendon hydrogel in a rat Achilles tendon model. *Plast Reconstr Surg* 2014;133(5):645e-53e. doi: 10.1097/PRS.0000000000000106.
- Suh MK. Dorsal Augmentation Using Autogenous Tissues. *Facial Plast Surg Clin North Am* 2018;26(3):295-310. doi: 10.1016/j.fsc.2018.03.004.
- Fatemi MJ, Foroutan KS, Ashtiani AK, Mansoori MJ, Vaghardoost R, Pedram S, et al. Comparison of divided sciatic nerve growth within dermis, venous and nerve graft conduit in rat. *J Res Med Sci* 2010;15(4):208-13. PMID: 21526083
- Movin T, Gad A, Reinholt FP, Rolf C. Tendon pathology in long-standing achillogdynia. Biopsy findings in 40 patients. *Acta Orthop Scand* 1997;68(2):170-5. doi: 10.3109/17453679709004002.
- Maffulli N, Longo UG, Franceschi F, Rabitti C, Denaro V. Movin and Bonar scores assess the same characteristics of tendon histology. *Clin Orthop Relat Res*. 2008;466(7):1605–11. doi: 10.1007/s11999-008-0261-0.
- Koc M, Yucens M, Aydemir N, Yorukoglu AC, Guvenc K, Uzun C, et al. Do adipofascial flaps affect the mechanical properties of a repaired tendon? A biomechanical rat model study. *Hand Surgery and Rehabilitation* 2019;38(5):323-7. doi: 10.1016/j.hansur.2019.07.003.
- Liao JL, Chen J, Xu JQ, Cheng Y, Xie HJ, He G, et al. Viability and biomechanics of bare diced cartilage grafts in experimental study. *J Craniofac Surg* 2017;28(6):1445-50. doi: 10.1097/SCS.0000000000003561.
- Khan RJK, Fick D, Keogh A, Crawford J, Brammar T, Parker M. Treatment of acute achilles tendon ruptures. A meta-analysis of randomized, controlled trials. *J Bone Joint Surg Am* 2005 Oct;87(10):2202-10. doi: 10.2106/JBJS.D.03049. PMID: 16203884.
- Müller SA, Dürselen L, Heisterbach P, Evans C, Majewski M. Effect of a Simple Collagen Type I Sponge for Achilles Tendon Repair in a Rat Model. *Am J Sports Med* 2016;44(8):1998-2004. doi: 10.1177/0363546516641942.
- Holm C, Kjaer M, Eliasson P. Achilles tendon rupture--treatment and complications: a

- systematic review. *Scand J Med Sci Sports* 2015;25(1):e1-10. doi: 10.1111/sms.12209.
15. Longo UG, Lamberti A, Maffulli N, Denaro V. Tendon augmentation grafts: a systematic review. *Br Med Bull* 2010;94:165-88. doi: 10.1093/bmb/ldp051.
 16. Cole W, Samsell B, Moore MA. Achilles Tendon Augmented Repair Using Human Acellular Dermal Matrix: A Case Series. *J Foot Ankle Surg* 2018;57(6):1225-9. doi: 10.1053/j.jfas.2018.03.006.
 17. Iannotti JP, Codsi MJ, Kwon YW, Derwin K, Ciccone J, Brems JJ. Porcine small intestine submucosa augmentation of surgical repair of chronic two-tendon rotator cuff tears. A randomized, controlled trial. *J Bone Joint Surg Am* 2006;88(6):1238-44. doi: 10.2106/JBJS.E.00524.
 18. Tarhan E, Cakmak O, Ozdemir BH, Akdogan V, Suren D. Comparison of AlloDerm, fat, fascia, cartilage, and dermal grafts in rabbits. *Arch Facial Plast Surg* 2008;10(3):187-93. doi: 10.1001/archfaci.10.3.187.
 19. Reich J. The application of dermis grafts in deformities of the nose. *Plast Reconstr Surg* 1983 ;71(6):772-82. doi: 10.1097/00006534-198306000-00005.
 20. Thomson N. The subcutaneous dermis graft. A clinical and histologic study in man. *Plast Reconstr Surg Transplant Bull* 1960;26:1-22. doi: 10.1097/00006534-196007000-00001.
 21. Peer LA. Fate of buried skin grafts in man. *Archives of Surgery* 1939;39(1):131-44. doi: 10.1001/archsurg.1939.01200130134012
 22. Philip J, Hackl F, Canseco JA, Kamel RA, Kiwanuka E, Diaz-Siso JR, et al. Amni-on-derived multipotent progenitor cells improve achilles tendon repair in rats. *Eplasty* 2013;13. PMID: 23814634
 23. Barber FA, McGarry JE, Herbert MA, Anderson RB. A biomechanical study of Achilles tendon repair augmentation using GraftJacket matrix. *Foot Ankle Int* 2008;29(3):329-33. doi: 10.3113/FAI.2008.0329.
 24. Devana SK, Kelley BV, McBride OJ, Kabir N, Jensen AR, Park SJ, et al. Adipose-derived Human Perivascular Stem Cells May Improve Achilles Tendon Healing in Rats. *Clin Orthop Relat Res* 2018;476(10):2091-100. doi: 10.1097/CORR.0000000000000461.