

**Case Report / Olgu Sunumu**

## Bilateral Giant Morgagni Hernia Causing Cardiac Shifting

### *Kardiak İtilmeye Neden Olan Bilateral Dev Morgagni Hernisi*

Alper AVCI, Sadullah GİRGIN<sup>1</sup>, Ercan GEDİK<sup>1</sup>, Serdar ONAT

*Departments of Thoracic Surgery and <sup>1</sup>General Surgery, Medical Faculty of Dicle University, Diyarbakır*

**Submitted / Başvuru tarihi:** 08.06.2008 **Accepted / Kabul tarihi:** 02.07.2008

A 76-year-old woman weighing 114 kg presented with shortness of breath and worsening chest pain for 2-year duration. There was no history of trauma. Plain and cross-sectional imaging identified a giant anterior diaphragmatic hernia which caused cardiac posterior shifting. She was transferred to general surgery department for further investigations and treatment. Reduction of herniated contents and repairing of bilaterally diaphragmatic defect were performed via laparotomy. Bilateral, giant Morgagni hernia which causes cardiac shifting to the backward is extremely rare.

**Key words:** Diaphragmatic hernia; Morgagni; cardiac shift; surgery; repair.

Yetmiş altı yaşında, 114 kg ağırlığında bayan hasta iki yıldır kötüleşen göğüs ağrısı ve efor ile nefes darlığı şikayetleri ile başvurdu. Öyküsünde travma yoktu. Düz ve kesitsel görüntülemelerde kardiyak posterior itilmeye neden olan dev anterior diyafragmatik herni saptandı. İleri tetkik ve tedavi için genel cerrahi bölümüne sevk edildi. Herniye bölümlerin redüksiyonu ve bilateral diyafragmatik defektin onarımı laparotomi kullanılarak yapıldı. Posterior kardiyak itilmeye neden olan bilateral dev Morgagni hernisi çok nadir bir olgudur.

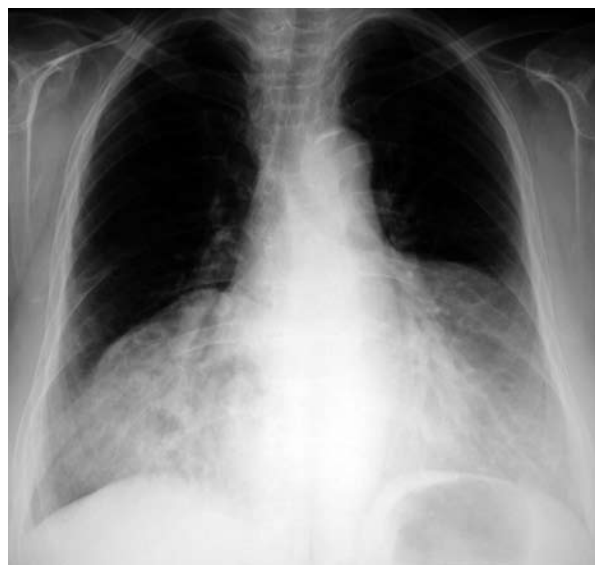**Anahtar sözcükler:** Diafragmatik herni; Morgagni; kardiyak itilme; cerrahi; onarım.

In 1769, Morgagni first described the substernal herniation of abdominal contents into the thoracic cavity based on observations made during autopsy examinations.<sup>[1]</sup> The diaphragmatic defect is a triangular space between the muscle fibers of the diaphragm that originate from the xiphisternum and the costal margin and insert on the central tendon of the diaphragm. This potential space is called as the foramen of Morgagni or space of Larrey. Foramen of

Morgagni hernias are rare entities in the general population. Morgagni hernia is the rarest type of congenital diaphragmatic hernia. Most of the patients are female and 92% of the hernias have hernia sac.<sup>[2]</sup> The majority of Morgagni hernias are right-sided with only rare left-sided and bilateral occurrences because of the protection provided by the pericardial sac.<sup>[3]</sup> In this report, diagnosis and repair of a giant, bilateral Morgagni hernia is described.

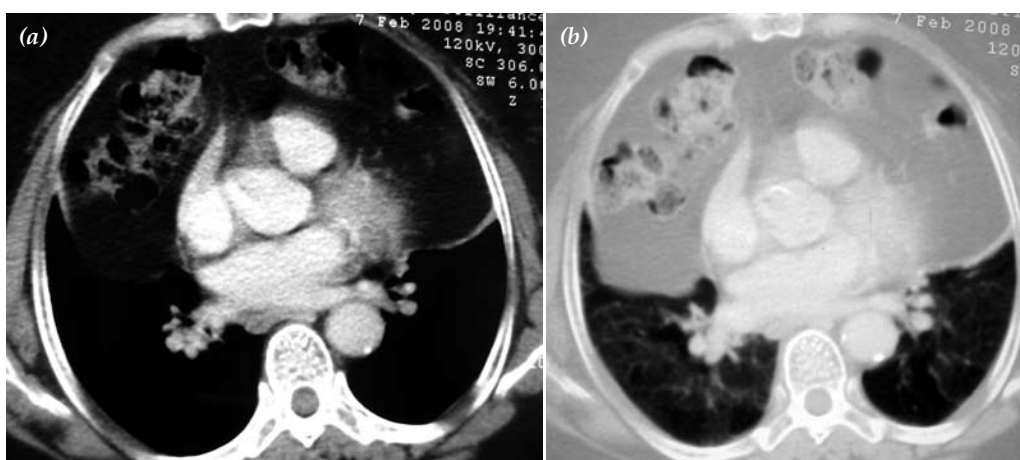
## CASE REPORT

A 76-year-old woman weighing 114 kg presented to the emergency room with worsening chest pain and shortness of breath on physical exertion for two years. There was no significant past medical history or trauma. Auscultation revealed no audible breath sounds in the bilateral lower sites of the chest. Physical examinations revealed stable vital signs. The laboratory results were in normal limits. In electrocardiography (ECG); T wave negativity in D2, D3, aVF, and low voltage were determined in all derivations. Echocardiogram measured normal cardiac chamber volumes and ejection fraction. She had no abdominal symptoms of pain, food intolerance, emesis, nausea, vomiting, cramping and distension. A posteroanterior chest radiography showed right paracardiac mass, bilateral lower lobe atelectasis and radiopacity (Fig. 1). Computed chest tomography (CT) revealed an anterior diaphragmatic hernia through Morgagni defect, transverse colon and omentum in the anterior mediastinum, compressed bilateral lung parenchyma and cardiac shifting to backward (Figs. 2a, b). The patient was diagnosed as bilateral, giant Morgagni hernia. She was transferred to the general surgery department for elective laparotomy. Laparotomy was planned for reducing abdominal contents into peritoneal cavity and repairing diaphragmatic defect. An elective transabdominal surgical repair via



*Fig. 1. Posteroanterior chest radiography of the patient at admission shows right paracardiac mass, bilateral lower lobe atelectasis and radiopacity.*

laparotomy was performed at the fourth day. During operation; bilateral, anterior, two diaphragmatic defects which measured 3 and 2.5 cm were seen, there were hernia sacs, transverse colon and omentum were in the mediastinum, visceral complications of Morgagni hernia such as obstruction or strangulation were not revealed. After reduction of the herniated contents into peritoneal cavity, primary repair of the diaphragmatic defects were performed with nonabsorbable mattress sutures. The patient



*Fig. 2. Chest CT of the patient shows anterior diaphragmatic hernia through Morgagni defect, transverse colon and omentum in the anterior mediastinum, compressed bilateral lung parenchyma and cardiac shifting to backward.*

made an uneventful recovery. The patient was discharged on the 10th day. She was well at six-month follow-up.

## DISCUSSION

Foramen Morgagni hernias account for 3% of all surgically treated diaphragmatic hernias.<sup>[3]</sup> Although Morgagni hernia usually lies on the right side and slightly posterior to the xiphoid process, it may rarely be found on the left side or bilateral. The presence of the pericardium has been proposed as a barrier against the occurrence of the left-sided and bilateral Morgagni hernias.<sup>[4]</sup> We herein report a case of bilateral Morgagni hernia.

Most of the Morgagni hernias have a hernia sac. Hernia sac frequently contains the omentum, transverse colon and rarely stomach or liver.<sup>[5]</sup> Also the present case had a hernia sac that contained omentum and transverse colon.

Patients with Morgagni hernia are usually asymptomatic. Among symptomatic patients, the complaints included shortness of breath, thoracic pain, food intolerance, emesis, gastroesophageal reflux, nausea, vomiting, abdominal cramping and distension, dysphagia and abdominal pain. The present case presented with the symptoms of shortness of breath and thoracic pain for two years.

The use of the computed thoracoabdominal tomography as a diagnostic tool for Morgagni hernia has increased the reliability of preoperative diagnosis. CT scans can help to further characterize anterior mediastinal masses that are detected on the chest radiographs and aid in preoperative diagnosis and operative planning.<sup>[3-5]</sup> Bilateral, giant Morgagni hernia of the present case was diagnosed with chest radiography and CT scanning. With CT scans facilitating correct diagnosis, the surgical repair was performed through the preferred transabdominal approach instead of the potentially more morbid transthoracic approach in the case.

Repair of the Morgagni hernia is indicated immediately after diagnosis because of the risk of visceral complications such as obstruction or strangulation. The treatment of a Morgagni

hernia is surgical and includes reducing the abdominal contents and repairing diaphragmatic defect.

Both transabdominal and transthoracic approaches are recommended in surgical repair of Morgagni hernia. Transthoracic repair has been used by Kilic et al.<sup>[6]</sup> with favorable results. They recommended transthoracic approach because it provides sufficient exposure, easy repair of the hernia sac and facilitates the release of pericardial adhesions. But, they also reported that transabdominal approach should be preferred, particularly in cases with bilateral hernia sac as in our patient. Transabdominal approach via laparotomy is superior in recognition and management of malrotation and for dealing with visceral complications than transthoracic approach.<sup>[7]</sup> The present case was treated with an elective laparotomy and there was no postoperative complication.

After reduction of herniated contents into peritoneal cavity, diaphragmatic defects are repaired with nonabsorbable sutures as in the present case. Extensive defects may not be repaired with primary suture. Nonabsorbable or absorbable prosthetic materials to achieve durable repair may be needed.

Postoperative complications are infrequent in the Morgagni hernia repair operations. The present case made an uneventful recovery.

In Conclusion, foramen of Morgagni hernia is a rare surgical disease. Bilateral Morgagni hernia is even more uncommon. Patients are usually asymptomatic. The preoperative diagnosis may be aided by CT scans. The current treatment of a Morgagni hernia is surgical repair even in asymptomatic cases because of the risk of visceral herniation and strangulation. Transabdominal approach is the preferred technique for reduction and dealing with visceral complications. Nonabsorbable sutures remain as the preferred method for diaphragmatic defect repairing.

## REFERENCES

1. Morgagni G, Alexander B. The seats and causes of diseases. London: Printed for A Millar, T Cadell, and Johnson and Payne; 1769. p. 205.
2. Comer TP, Clagett OT. Surgical treatment of hernia of

- the foramen of Morgagni. *J Thorac Cardiovasc Surg* 1966;52:461-8.
3. Minneci PC, Deans KJ, Kim P, Mathisen DJ. Foramen of Morgagni hernia: changes in diagnosis and treatment. *Ann Thorac Surg* 2004;77:1956-9.
  4. Eren S, Ciriş F. Diaphragmatic hernia: diagnostic approaches with review of the literature. *Eur J Radiol* 2005;54:448-59.
  5. Nursal TZ, Atli M, Kaynaroglu V. Morgagni hernia in a patient with Morquio syndrome. *Hernia* 2000;4:37-9.
  6. Kiliç D, Nadir A, Döner E, Kavukçu S, Akal M, Özdemir N, et al. Transthoracic approach in surgical management of Morgagni hernia. *Eur J Cardiothorac Surg* 2001;20:1016-9.
  7. Fingerhut A, Baillet P, Oberlin P, Ronat R. More on congenital diaphragmatic hernia in the adult. *Int Surg* 1984;69:182-3.