

## Intrathoracic Extrapulmonary Hydatid Cysts: Review of 33 Cases

### *İntratorasik Ekstrapulmoner Kist Hidatik: 33 Olgunun Analizi*

Mehmet DAKAK, Orhan YÜCEL, Kuthan KAVAKLI, Hasan ÇAYLAK, Alper GÖZÜBÜYÜK,  
Ersin SAPMAZ, Sezai ÇUBUK, Sedat GÜRKÖK, Mehmet Ali ŞAHİN,<sup>1</sup> Onur GENÇ

*Departments of Thoracic Surgery and <sup>1</sup>Cardiovascular Surgery, Gülhane Military Medical School, Ankara*

**Submitted / Başvuru tarihi:** 20.09.2008 **Accepted / Kabul tarihi:** 27.09.2008

**Objectives:** In this study, we aimed to present our clinical and surgical experience in intrathoracic extrapulmonary hydatid cysts, a complicated form of hydatid disease.

**Patients and Methods:** The age, sex, history, symptoms, localization of hydatid cysts and surgical treatment methods, complication, hospitalization time, recurrence, morbidity and mortality were recorded for 33 patients (28 females, 5 males; mean age 26.9 years; range 22 to 64 years) who had intrathoracic extrapulmonary cysts.

**Results:** The most common symptoms were cough and chest pain. The localization of the hydatid cysts were pleural space, chest wall, extrapleural region, mediastinum and diaphragm. The hydatid cysts were removed by the extirpation technique via thoracotomy in 29 patients and via sternotomy in four patients. The mean time of hospitalization was 7.2 days (3-17 days). The most common postoperative complication was pulmonary atelectasis. There was no mortality.

**Conclusion:** It should be considered that hydatid cysts may occur in many different sites as well as intrathoracic but extrapulmonary.

**Key words:** Hydatid cyst; intrathoracic extrapulmonary hydatid cyst; thoracic hydatid cyst.

**Amaç:** Bu çalışmada amacımız kist hidatiklerin komplike bir formu olan intratorasik ekstrapulmoner kist hidatiklerle ilgili klinik ve cerrahi tecrübelerimizi sunmaktır.

**Hastalar ve Yöntemler:** İntratorasik ekstrapulmoner yerleşimli hidatik kistli 33 hastanın (28 kadın, 5 erkek; ort. yaş 26.9; dağılım 22-64) yaş, cinsiyet, semptom, kistlerin yerleşimi ve uygulanan cerrahi yöntem, komplikasyon, hastanede kalış süresi, rekürrens olup olmadığı, morbidite ve mortalite ile ilgili verileri kaydedildi.

**Bulgular:** En sık görülen semptomlar öksürük ve göğüs ağrısıydı. Hidatik kistlerin yerleşim yerleri plevral boşluk, göğüs duvarı, ekstraplevral bölge, mediasten ve diafragmaydı. Hidatik kistler ekstirpasyon tekniği ile 29 hastada torakotomi aracılığıyla, dört hastada ise sternotomi aracılığıyla çıkarıldı. Ortalama hastanede kalış süresi 7.2 gündü (3-17 gün). En sık izlenen ameliyat sonrası komplikasyon pulmoner ateletaziydi. Mortalite izlenmedi.

**Sonuç:** Hidatik kistlerin intratorasik ancak ekstrapulmoner gibi birçok farklı bölgede oluşabileceği akılda bulundurulmalıdır.

**Anahtar sözcükler:** Hidatik kist; intratorasik ekstrapulmoner hidatik kist; torasik hidatik kist.

Hydatid cyst diseases are caused by larval form of *Echinococcus granulosus* or *Echinococcus multilocularis*. This parasitic infestation is also a very important health problem in endemic areas (i.e; Turkey, Middle East countries and

South America).<sup>[1,2]</sup> It can be found in any part of the body except hair, teeth and fingernails.<sup>[3]</sup> Lung and liver are the most common sites of the hydatidosis.<sup>[4]</sup> We reviewed 586 patients who were treated surgically for thoracic hydatid

disease in our clinic between January 1980 and February 2008. Thirty-three of them were located extrapulmonary. Herein, we presented our experience, clinical features and the operative technique in extrapulmonary hydatid cysts.

**PATIENTS AND METHODS**

We reviewed the clinical records of 586 patients who underwent surgical treatment for hydatidosis between January 1980 and February 2008, and retrospectively evaluated how many of these patients had intrathoracic extrapulmonary hydatid cysts. We recorded the age, sex, history, symptoms, localization of intrathoracic extrapulmonary hydatid cysts and surgical treatment methods, complications, morbidity, mortality, hospitalization time after operation and recurrence for each patient. Preoperative diagnosis was based primarily on chest radiography and computed tomography (CT). Computed tomography of the chest and upper abdomen were used as preoperative diagnostic tools. They allowed precise localization, measurement and confirmation of hydatid cysts. In addition, magnetic resonance imaging (MRI), ultrasonography and echocardiography were used in selected patients. Furthermore, indirect hemagglutination test was used in all patients. The extrapulmonary cysts were removed by cyst extirpation. The antihelminthic agent (albendazole, 10 mg/kg/day for 28 days) was given to selected patients postoperatively.

**RESULTS**

A total of 586 patients were operated on for thoracic hydatid disease in our department. Intrathoracic extrapulmonary hydatid cysts were found in 33 (5%) patients (28 females, 5 males; mean age 26.9 years; range 22 to 64 years). Seventeen men and three women were from rural area and had a history of contact with either sheep, cow and carnivores. Two patients had a history of surgery for pulmonary hydatid cyst and one patient had a history of surgery for liver hydatid cyst. The presenting symptoms of patients were summarized in Table 1. Two patients were asymptomatic.

The chest radiography was sufficient to establish correct diagnosis in six (18%) patients.

**Table 1. Symptoms of patients at the time of admission**

Symptom	n	%
Cough	16	48
Chest pain	14	42
Sputum	4	16
Fever	4	16
Dyspnea	4	16
Hemoptysis	3	9
Weakness	2	6
Back pain	2	6

In addition, CT of the chest and upper abdomen in 22 (66%) patients, MRI in six (18%) patients, echocardiography in eight (24%) patients and ultrasonography in two (6%) patients were required to establish correct diagnosis. The diagnosis was established intraoperatively in six (16%) patients. In five patients the cysts were concomitant with the liver. In our series, mediastinal cysts were the most common intrathoracic extrapulmonary hydatid cysts. Extrapulmonary hydatid cysts localizations are summarized in Table 2. We performed an indirect hemagglutination test to all patients with extrapulmonary hydatid cysts and the results were positive in 26 patients (78%).

Total excision of the cysts was carried out via thoracotomy or sternotomy in all cases. Thoracotomy and sternotomy were performed in 29 cases and in four cases respectively. Mediastinal hydatid cysts were involved with pericardial, outer myocardial wall and phrenic nerve. Heart hydatid cysts are involved with left ventricle, interventricular septum and right atrium. Total excision of the cyst was performed in heart cyst cases via median sternotomy and

**Table 2. Location of the cysts**

Location	n	%
Mediastinum	14	42
Chest wall	9	27
On the diaphragm	8	24
Pleural space	2	6
Total	33	100

under extracorporeal circulation. Chest wall hydatid cysts were involved with ribs, muscles, subcutaneous tissue or paravertebral region. Because of bone destruction, two patients underwent rib debridement and curettage. Diaphragmatic involvement was seen in eight cases and six of them required diaphragmatic reconstruction. We achieved all reconstructions with prolene mesh.

The most common postoperative complication was pulmonary atelectasis. Rethoracotomy was achieved in four patients for the control of postoperative hemorrhage in one patient, the repair of vena cava superior rupture in one patient, and the control of prolonged air leak in two patients. There was no mortality. Mean duration of hospitalization after operation was 7.2 days (3-17 days). The mean follow-up period was 14.3 years (28 years to 3 months). Albendazole treatment was given to six patients after operation, due to suspicion of uncontrolled spilling out of vital cyst's fluid into pleural cavity intraoperatively. However, no recurrence was observed in these patients after surgery.

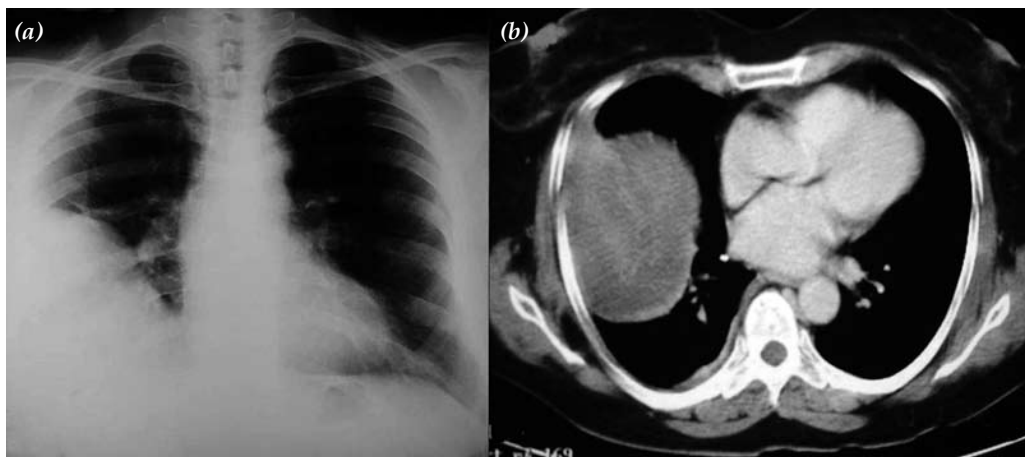
## DISCUSSION

It should be remembered that hydatid cysts have been reported in many different locations, but the disease rarely presents extrapulmonary in the thorax. Intrathoracic extrapulmonary cyst should be suspected whenever another organ is

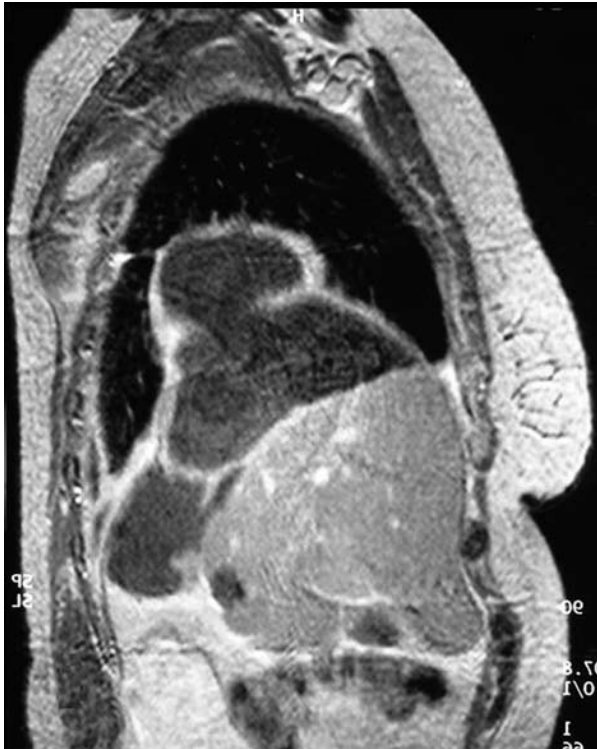involved with hydatid cysts. Intrathoracic extrapulmonary hydatid cyst may be found in chest wall, mediastinum, lobar fissure, diaphragm and pleura.<sup>[5]</sup> Isitmangil et al.<sup>[6]</sup> reported an intrathoracic extrapulmonary hydatid cyst rate of 6.2% in 207 cases with intrathoracic hydatid cyst. In our intrathoracic hydatid cyst series, this rate was 5%.

Intrathoracic but extrapulmonary hydatid cysts may cause compression symptoms in adjacent organs and most of these symptoms are similar to other cystic lesions. Radiological imaging studies revealed that it may even be impossible to differentiate some of them from each other. Extrapulmonary intrathoracic cysts are very difficult to diagnose and treat, especially when the hydatid cyst is complicated.<sup>[7,8]</sup> Isitmangil et al.<sup>[6]</sup> reported that the most common clinical symptom was cough (51%). In another study, Dakak et al.<sup>[9]</sup> reported that the common clinical symptoms were cough (56%), chest pain (52%) and fever (34%). In our study, the incidence of the symptoms was similar.

Distinguishing hydatid disease from other problems may be extremely difficult for extrapulmonary hydatid cyst disease. Dakak et al.<sup>[9]</sup> stated that they made the diagnosis in 347 (82%) of their cases with a simple chest radiography. We use radiography, CT and MRI in order to assist in diagnosis. Chest radiography and CT are our main diagnostic method (Fig. 1). There is



**Fig. 1.** (a) A consolidation in the right costophrenic angle and phrenic counter is not determined on the lesion side. (b) Computerized thorax tomography of well-defined mass having variegated soft tissue attenuation in the right hemithorax.



*Fig. 2. Sagittal plane of magnetic resonance imaging showed lobulated cystic mass not originating from liver and lung parenchyma.*

provided useful information about the anatomic location of the cyst. Chest radiography and CT were also helpful, providing information about the morphologic characteristics of cysts (i.e., a smooth, round, dense opacity) and their exact location in the thorax. Computed tomography may demonstrate germinative membrane but is otherwise not diagnostic. It may be visible by CT. Computerized tomography is helpful in showing the water density in intact cysts, but in complicated cysts it can be confused with mass lesions. Echocardiography should be used for myocardial and pericardial hydatid cysts. Magnetic resonance imaging is a useful diagnostic tool for extensions of primary diaphragmatic hydatid cysts (Fig. 2). It is clearly said that CT is necessary for all intrathoracic extrapulmonary cysts and should also be used in patients with extrapulmonary hydatid cysts, especially in complicated cysts (i.e., perforated or infected). Indirect hemagglutination tests can be used for exact diagnosis but one must remain aware of their tendency toward false-positive results.

The effective treatment of hydatid cyst is complete excision of the cyst without delay. Dakak et al.<sup>[9]</sup> and Isitmangil et al.<sup>[6]</sup> emphasized that the most effective treatment for hydatid cysts is complete excision of the cyst with maximum preservation of the lung parenchyma. They used thoracotomy or sternotomy for cyst resection. In our study, either thoracotomy or sternotomy were used in all cases and extrapulmonary cyst lesions were removed. While the cyst is extirpating from surrounding tissue, the surgeon must be careful in order not to seal the cyst containing. Also the surgeon must watch out for unexpected extrapulmonary hydatid cyst.

The complications of pulmonary hydatid cyst include atelectasis, hemorrhage, prolonged air leak, inflammatory reaction and destruction of nearby tissues by expanding. The complicated cysts can cause pleural thickening due to severe inflammatory reaction. Therefore, pleural decortication, wide parenchymal resection, diaphragmatic repair and rib debridement or resection may be required. In some studies, approximately 70% of the patients needed decortications.<sup>[7,8]</sup> Due to dense pleural thickening we performed decortications in one patient. Pleural space was the least commonly involved site by the hydatid cysts in our series. Pleural space involvement was seen in two cases.

In our series, the distribution of chest wall hydatid cysts were paravertebral structures in one patient, subcutaneous soft tissue in two patients, supraclavicular region in one patient and lateral chest wall subcutaneous tissue in five patients. Two cases of them required debridement and curettage because of rib destructions.

Ulku et al.<sup>[10]</sup> reported that the diaphragm is the least common area of involvement with hydatid cyst and repair must be done after cyst resection. In our study, diaphragmatic involvement was more common than the study of Ulku et al. and primary diaphragmatic repair was required in four patients because of diaphragmatic defects.

Mediastinal involvement was seen in 14 patients. Pericardial sacs and outer myocardial wall were affected in seven patients and in two

patients respectively. Dense adhesion to the epicardium by surrounding tissues was seen in one patient and erosion of outer myocardial wall by complicated hydatid cyst was seen in the other patient. All of them were excised without any complication.

Albendazole treatment was applied to patients who had perforated cysts or pericardial hydatid cyst postoperatively. It is important that perforation of a cyst as a complication usually occurs due to medical treatment. According to our previous study, albendazole treatment should be applied to the patients who had high risk of recurrence (i.e., multiple hydatid cysts in thoracic cavity, multiple organ hydatid cysts, patients with ruptured hydatid cyst).<sup>[6]</sup> In our series, albendazole treatment was applied to patients who were in the high risk group. There was no recurrence during postoperative period in any of the 33 patients.

Lots of studies reported no mortality perioperatively and there was no mortality in our studies either. In some series, mean postoperative hospitalization time was 10 days except complicated cases, but in our series mean duration time after operation was 7.2 (3-17) days in all cases.

We conclude that surgical treatment for intrathoracic extrapulmonary hydatid cyst can be performed with acceptable morbidity and mortality at any age. Intrathoracic extrapulmo-

nary hydatid cyst should be resected completely for the optimum control of symptoms.

## REFERENCES

1. Burgos R, Varela A, Castedo E, Roda J, Montero CG, Serrano S, et al. Pulmonary hydatidosis: surgical treatment and follow-up of 240 cases. *Eur J Cardiothorac Surg* 1999;16:628-34.
2. Dhaliwal RS, Kalkat MS. One-stage surgical procedure for bilateral lung and liver hydatid cysts. *Ann Thorac Surg* 1997;64:338-41.
3. Gupta RK, Kakkar AK, Bhagat R, Pant K. Phrenodiastinal echinococcosis. *Chest* 1990;98:1528-30.
4. Doğan R, Yüksel M, Cetin G, Süzer K, Alp M, Kaya S, et al. Surgical treatment of hydatid cysts of the lung: report on 1055 patients. *Thorax* 1989;44:192-9.
5. Oğuzkaya F, Akçali Y, Kahraman C, Emiroğullari N, Bilgin M, Sahin A. Unusually located hydatid cysts: intrathoracic but extrapulmonary. *Ann Thorac Surg* 1997;64:334-7.
6. Isitmangil T, Sebit S, Tunc H, Gorur R, Erdik O, Kunter E, et al. Clinical experience of surgical therapy in 207 patients with thoracic hydatidosis over a 12-year-period. *Swiss Med Wkly* 2002;132:548-52.
7. Kuzucu A, Soysal O, Ozgel M, Yologlu S. Complicated hydatid cysts of the lung: clinical and therapeutic issues. *Ann Thorac Surg* 2004;77:1200-4.
8. Ozvaran MK, Ersoy Y, Uskul B, Unver E, Yalcin E, Baran R, et al. Pleural complications of pulmonary hydatid disease. *Respirology* 2004;9:115-9.
9. Dakak M, Genç O, Gürkök S, Gözübüyük A, Balkanlı K. Surgical treatment for pulmonary hydatidosis (a review of 422 cases). *J R Coll Surg Edinb* 2002;47:689-92.
10. Ulkü R, Eren N, Cakir O, Balci A, Onat S. Extrapulmonary intrathoracic hydatid cysts. *Can J Surg* 2004;47:95-8.