

Case Report / Olgu Sunumu

Retroperitoneal Ganglioneuroma

Retroperitoneal Ganglionörom

Tevfik AKTOZ, Mustafa KAPLAN, Ufuk USTA,¹ İrfan Hüseyin ATAĞAN, Osman İNCİ

Departments of Urology and ¹Pathology, Medical Faculty of Trakya University, Edirne

Submitted / Başvuru tarihi: 30.07.2008 **Accepted / Kabul tarihi:** 10.09.2008

Neuroblastoma, ganglioneuroblastoma and ganglioneuroma are tumors of varying maturity derived from the primordial neural crest cells that form the sympathetic nervous system. A primary extra-adrenal retroperitoneal ganglioneuroma was found incidentally in a 12-year-old boy during a series of examinations for abdominal distension, left upper quadrant pain and diarrhoea.

Key words: Ganglioneuroma; retroperitoneum; sympathetic nervous system.

Nöroblastom, ganglionöroblastom ve ganglionörom sempatik sinir sistemini oluşturan, değişik derecelerde olgunlaşmış, primordial nöral krest hücrelerinden köken alan heterojen bir grup tümördür. Abdominal distansiyon, sol üst kadranda ağrı ve daire şikayetleriyle başvuran 12 yaşındaki erkek hastaya yapılan tetkikler sonucu rastlantısal olarak primer retroperitoneal ganglionörom saptanmıştır.

Anahtar sözcükler: Ganglionörom, retroperiton, sempatik sinir sistemi.

Neuroblastoma, ganglioneuroblastoma and ganglioneuroma arise wherever sympathetic tissue exists and may be seen in the neck, posterior mediastinum, adrenal gland, retroperitoneum and pelvis.^[1] The ganglioneuroma is a very rare disease and affects newborns and infants more often than adolescents and adults.^[2] Ganglioneuroma is benign, slow-growing tumor and difficult to distinguish from other tumors due to lack of image findings specific for ganglioneuromas.^[3,4]

CASE REPORT

A 12-year-old boy presented with a 18-month history of abdominal distension, left upper quadrant pain and diarrhoea. The patient was

referred to our clinic for further investigation of left retroperitoneal mass incidentally discovered by ultrasonography. Abdominal computed tomography (CT) revealed a 70x54x53 mm solid tumor between the upper pole of the left kidney and aorta (Fig. 1). Hormonal studies were insignificant. Intraoperatively, no abnormality was observed in the left kidney. The excised tumor was well-demarcated. The tumor specimen was noncystic, weighing 82 g and measuring 7.4x5.8x5 cm (Fig. 2).

Histologically, hematoxylin-eosin-stained slides revealed a tumor composed of two major components. Spindle cells, which hosted groups of mature ganglion cells with plenty cytoplasm, big nuclei and prominent nucleoli, did not

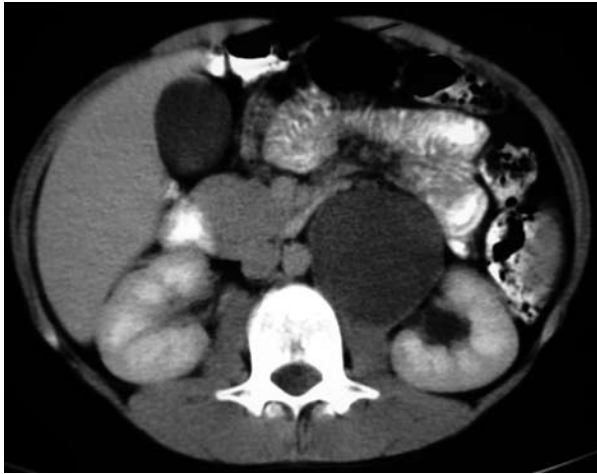

Fig. 1. Computed tomography scan shows a mass arising in the retroperitoneum.

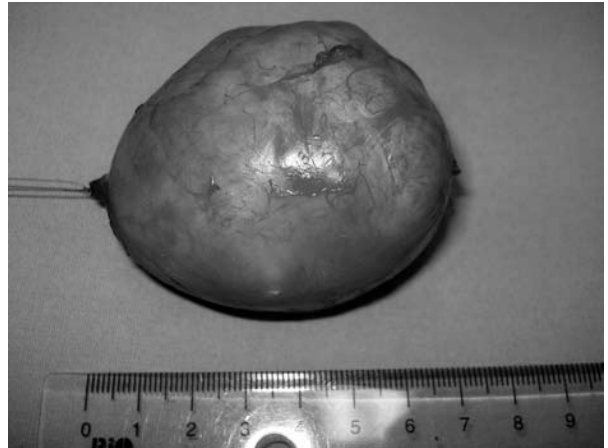

Fig. 2. Postoperative photograph of ganglioneuroma.

show any atypia (Fig. 3). The spindled tumor cells showed strong positive reaction for S-100 protein and were negative for synaptophysin, desmin and α smooth muscle actin immunohistochemically (Fig. 4).

DISCUSSION

Neuroblastoma, ganglioneuroblastoma and ganglioneuroma are three tumors that differ in their degree of cellular and extracellular maturation; immature tumors tend to be aggressive and occur in younger patients (median age, just under 2 years), whereas mature tumors occur in older children (median age, approximately 7 years).^[1]

Ganglioneuroma is relatively rare and difficult to distinguish from other tumors due to lack of image findings specific for ganglioneuromas.^[4] Ultrasonography reveals a homogeneous, hypoechoic mass with well-defined borders. Computed tomography is the most commonly used imaging modality for assessment of neuroblastic tumors, because it reveals extent of tumor, organ of origin, regional invasion, vascular encasement, adenopathy and calcification.^[1]

In this case report we point out that the correct evaluation of this lesion is of crucial importance, as there are some malignant neoplasms that have similar clinical presentations.^[5]

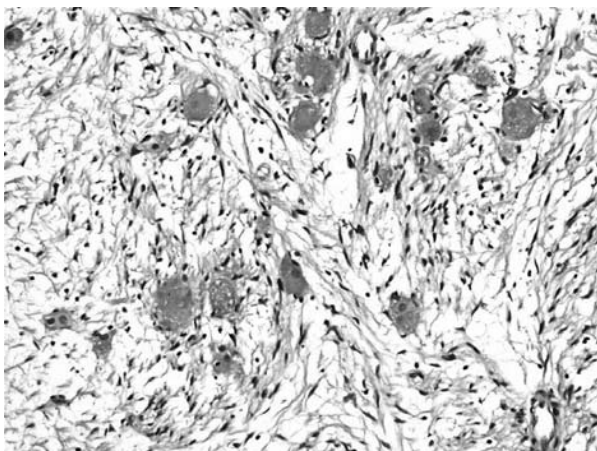


Fig. 3. Mature ganglion cells embedded in a loose stroma composed of benign spindle cells (H-E x 100).

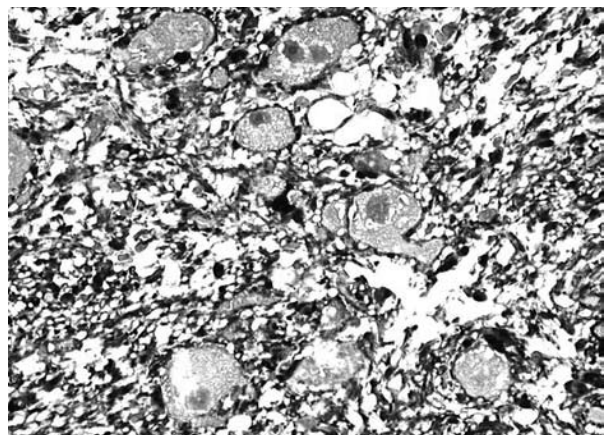


Fig. 4. Stromal cells show strong positive cytoplasmic reaction for S-100 protein while there is no immunohistochemical reaction for ganglion cells (S-100 x 200).

However, ganglioneuromas can cause symptoms due to local expansion and pressure on adjacent structures.^[6] In our case, informed consent must include the possibility of nephrectomy to avoid any medicolegal complications because a tight adhesion of the tumor to the left kidney can necessitate an en bloc resection. Treatment consists of complete surgical resection of tumor when possible.

Increasing numbers of these tumors are being found incidentally by ultrasonography or CT. Ganglioneuroma is a benign tumor with symptoms depending on location and can be surgically dissected with favorable prognosis. Local recurrence has been reported, so periodic radiologic surveillance is performed after resection.

REFERENCES

1. Lonergan GJ, Schwab CM, Suarez ES, Carlson CL. Neuroblastoma, ganglioneuroblastoma, and ganglioneuroma: radiologic-pathologic correlation. *Radiographics* 2002;22:911-34.
2. Zugar V, Amann K, Schrott KM, Schott GE. Retroperitoneal ganglioneuroma. *Aktuelle Urol* 2005;36:349-52. [Abstract]
3. Chang CY, Hsieh YL, Hung GY, Pan CC, Hwang B. Ganglioneuroma presenting as an asymptomatic huge posterior mediastinal and retroperitoneal tumor. *J Chin Med Assoc* 2003;66:370-4.
4. Fujita T, Maru N, Iwamura M, Tojo T, Yoshida K, Baba S. Two cases of ganglioneuroma. *Hinyokika Kyo* 2003;49:107-10. [Abstract]
5. Domanski HA. Fine-needle aspiration of ganglioneuroma. *Diagn Cytopathol* 2005;32:363-6.
6. Kaplan O, Cohen Z, Lelcuk S, Rozin R. Retroperitoneal ganglioneuroma. *Harefuah* 1989;117:302-4. [Abstract]