

**Case Report / Olgu Sunumu**

## Recurrent Functional Pituitary Adenoma Presenting as Oculomotor Nerve Infiltration: Case Report

*Okülomotor Sinir İnfiltrasyonu Gösteren Rekürren Fonksiyonel Hipofiz Adenomu: Olgu Sunumu*

Salih GÜLSEN, Cem YILMAZ, Hakan CANER, Nur ALTINÖRS

*Department of Neurosurgery, Medical Faculty of Başkent University, Ankara*

**Submitted / Başvuru tarihi:** 10.08.2008 **Accepted / Kabul tarihi:** 15.09.2008

It is estimated that pituitary tumors account for 10% to 15% of all primary brain tumors. Patients with pituitary adenoma and cranial nerve involvement should be evaluated regarding possible oculomotor nerve infiltration. We present this case to emphasize the importance of diagnosing infiltration to the oculomotor nerve in patients with pituitary adenoma. Evacuation of the tumor can be beneficial to decrease the level of hormone secreted and its clinical consequences, and also for the recovery of oculomotor nerve function in cases with pressure effect on the oculomotor nerve, but it is not effective for such recovery in cases with direct infiltration to the nerve by the tumor as in the present case.

**Key words:** Cushing's disease; Gamma Knife surgery; pituitary adenoma; oculomotor nerve infiltration.

Hipofiz tümörleri primer beyin tümörlerinin %10-15'ini oluşturur. Hipofiz adenomu olan hastalar okülomotor sinir infiltrasyonu açısından değerlendirilmelidir. Sunulan olguda okülomotor sinir infiltrasyonunun hipofiz adenomu gibi benign bir patolojinin sonucunda da gelişebileceği vurgulanmıştır. Hormon sekresyonunun azaltılması ve baskı altında kalmış olan okülomotor sinir fonksiyonunun geri dönüşümü için cerrahi dekompresyon etkili olmaktadır, ancak; okülomotor sinirin tümör ile infiltr olduğu durumda okülomotor sinir fonksiyonunun geri dönüşümü mümkün olmamaktadır. Sunulan olguda da ameliyat sonrası dönemde okülomotor sinir fonksiyonu geri dönmemiştir.

**Anahtar sözcükler:** Cushing hastalığı; Gamma Knife cerrahisi; hipofiz adenomu; okülomotor sinir tutulumu.

Pituitary tumors cause two sets of symptoms due either to endocrine disturbances or mass effect and arise primarily from the anterior pituitary gland. Pituitary tumors expand into the sphenoid sinus by eroding the floor of the sella, or expand into the third ventricle or parasellar region and other tissues adjacent to the pituitary gland. Pituitary tumors progress mostly by pushing or by wrapping around adjacent tissues

and the cranial nerves rather than infiltration.<sup>[1,2]</sup> In this report, we describe the clinical and operative features of pituitary adenoma infiltrating the oculomotor nerve.

### CASE REPORT

A 75-year-old female with a history of hypothyroidism, hypertension and diabetes presented with a five-month history of headache, diplo-

pia, ptosis and loss of vision. She had undergone transcranial pituitary adenoma excision seven years before. In addition, gamma knife surgery had been performed (Fig. 1) after the surgery. Her medical history revealed that her vision had decreased gradually, and she complained of diplopia and ptosis on the right side. Neurological examination showed complete third cranial palsy on the right, with ptosis, mydriasis and outward positioning of the right eye. Visual field examination showed bitemporal heteronymous hemianopia. Her diabetes, hypertension and hypothyroidism were regulated. The baseline blood pressure was 130/85 mmHg. Hormonal evaluation showed TSH suppression with low levels of T3 and T4. The basal cortisol level was 75 ug/dl (Normal level: 5-25 ug/dl) and ACTH level was 377 pg/ml before the suppression test. The dexamethasone suppression test performed with 1 mg and 2 mg revealed no suppression and the ACTH level after the suppression was 188 pg/ml and 129 pg/ml, respectively (normal ACTH value: 0-120 pg/ml). MRI demonstrated a heterogeneous soft-tissue lesion occupying the right side of the sphenoid sinus. The right cavernous sinus, pituitary stalk and optic chiasm were under compression because of the tumoral invasion, and the lesion was heterogeneously enhanced by Gadolinium injection, with no intradural extension of the tumor noted (Fig. 2a, b). The dexamethasone suppression test clearly showed Cushing's disease. The patient underwent a right pterional craniotomy seven years after the first transcranial pituitary surgery. The right frontal lobe was retracted and the proximal portion of the sylvian fissure opened to observe the right carotid artery,

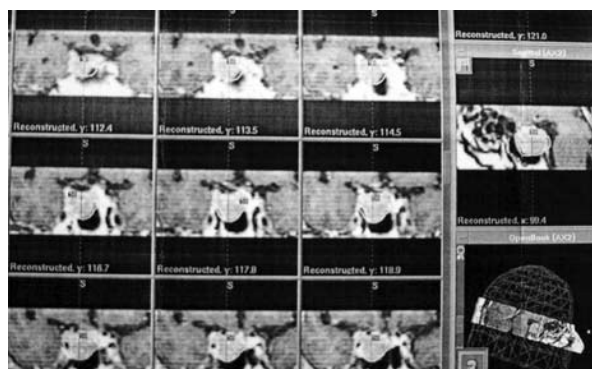

Fig. 1. Gamma Knife surgery planning chart for the patient.

right optic nerve and right oculomotor nerve. The right oculomotor nerve at the oculomotor trigone, which is the entry point to the cavernous sinus, appeared larger than typical due to tumoral infiltration (Fig. 3a, b). The cavernous sinus was opened and the tumor partly evacuated for decompression. The values of cortisol and ACTH decreased to 9.7 ug/dl and 39.4 pg/ml, respectively, at the postoperative period. Histological examination showed typical features of pituitary adenoma. The postoperative course was uneventful with no improvement in the oculomotor nerve palsy. The patient was discharged to be followed-up regularly by the endocrinology and neurosurgery departments. She was re-hospitalized a month later with a complaint of dyspnea. Lobar pneumonia was diagnosed and the patient was lost due to lung infection and sepsis after 48 days.

## DISCUSSION

About one fourth of pituitary adenomas have no clinical or biochemical signs of hormone hypersecretion.<sup>[1]</sup> Basically, pituitary tumors can

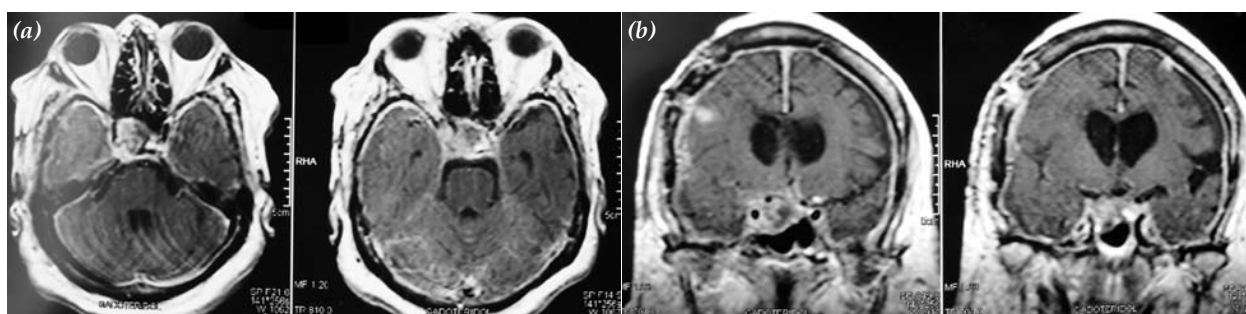
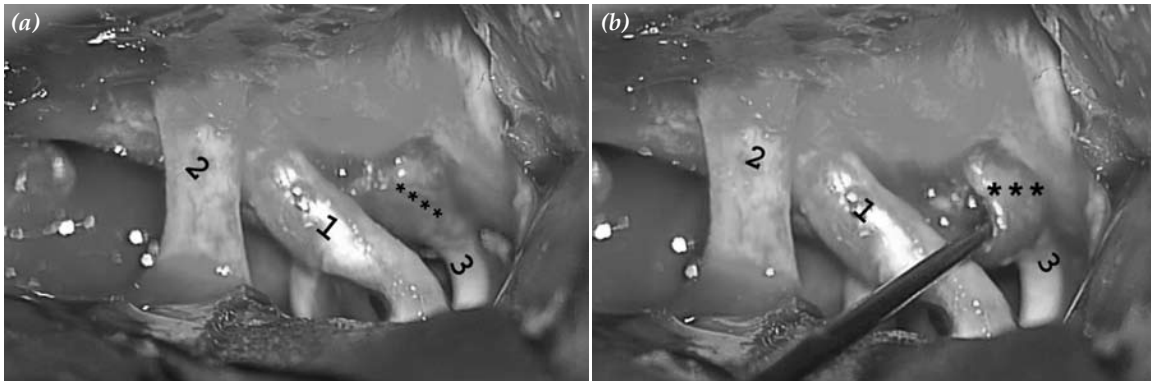


Fig. 2. (a) Gadolinium-enhanced T1-weighted axial MRI view showing enhancing mass within the oculomotor cistern located in the right cavernous sinus. (b) Gadolinium-enhanced T1-weighted coronal MRI view showing enhancing mass around the right cavernous sinus.



**Fig. 3.** (a, b) The right oculomotor nerve was completely involved with the tumor at the entrance to the cavernous sinus. 1: Right carotid artery, 2: Right optic nerve, 3: Right oculomotor nerve \*\*\*: Stars showing tumoral infiltration part of the oculomotor nerve at the entrance to the cavernous sinus.

be classified into two types regarding their hormonal secretion as functional (endocrine active tumors) and nonfunctional (endocrine inactive tumors).<sup>[2]</sup> Gamma knife radiosurgery, stereotactic radiation and radiotherapy are effective ways of stopping the growth of pituitary adenomas, and they are also effective for residual tumors after adenoma excision. Oculomotor palsy is seen in the acute period of pituitary apoplexy due to expansion of a pituitary adenoma by hemorrhage or necrosis and direct hemorrhage or infarction of the pituitary gland.<sup>[3,4]</sup> Pituitary tumor expansion causes direct compression of the nerve or transmission of the pressure on the cavernous sinus wall from tumour expansion. The most common cranial nerve palsy due to a pituitary tumor is third cranial nerve palsy, followed by sixth, fourth and fifth cranial nerve palsies in that order.<sup>[3,4]</sup> Various authors have postulated the reason for the third cranial nerve palsy as its horizontal location in the same plane with the pituitary gland with the lateral growth of the pituitary tumor compressing the cavernous sinus being relatively easily transmitted to the third cranial nerve. This leads to compression of the third cranial nerve between the tumor and the interclinoid ligament, and brings about the common development of third cranial nerve palsy.<sup>[3,4]</sup> Park et al.<sup>[5]</sup> reported a patient with isolated oculomotor palsy where the diagnosis was non-Hodgkin's lymphoma of the sphenoid sinus with involvement of the oculomotor nerve. Her oculomotor palsy resolved after chemotherapy. Itshayek et al.<sup>[6]</sup> reported a cavernous hemangio-

ma involving the third cranial nerve. In this case, the patient had no neurological deficit, but had facial neuralgia. The patient underwent surgical evacuation of the lesion, and had an uneventful postoperative period. Kim et al.<sup>[7]</sup> showed that early surgical intervention in a patient with pituitary apoplexy associated with pituitary tumor resulted in rapid recovery of cranial nerve function including the third, fourth and sixth cranial nerves. About one fourth of all pituitary carcinomas are clinically nonfunctioning and the clinical course of many patients with benign pituitary adenoma is indistinguishable from that of patients with pituitary carcinoma.<sup>[8]</sup> Pituitary microadenoma has not been demonstrated as a cause of metastasis, but macroadenomas showing metastatic dissemination have been found. Progression of macroadenomas into the metastatic form of the tumor develop over time ranging from months to many years (mean duration about seven years),<sup>[9]</sup> but the effect of the radiotherapy on this malignant transformation has not been shown yet.<sup>[10,11]</sup> Pituitary carcinomas disseminate along the CSF axis including all parts of the cranium and the spine. In addition to neural involvement, extraneural involvement occurs to the bone, liver, lymph nodes, lung, kidney and heart.<sup>[8,9]</sup> Our case showed oculomotor infiltration, compression of the optic chiasm and also low TSH level and increased ACTH level that was not suppressed after the dexamethasone test. The patient was accepted as Cushing's disease. According to our intraoperative observation, we believe that the oculomotor nerve

infiltration ensued within the cavernous sinus (Fig. 3a, b). The other symptoms and findings regarding pituitary tumor compression were as usual. The histological specimen showed nothing other than typical pituitary adenoma. The question is how this infiltration occurred. Was this a sporadic case or an overlooked feature of benign pituitary adenoma in the elderly population?

In summary, one should remember that pituitary tumors with benign histological appearances can infiltrate the oculomotor nerve, especially in elder patients. Decompression of the cavernous sinus cannot ensure recovery of the oculomotor palsy in patients with oculomotor nerve infiltration, but it is an effective way to decrease the ACTH level as in our presented case. In addition, the late period effect of Gamma Knife therapy on pituitary tumors should be evaluated regarding oculomotor nerve infiltration.

## REFERENCES

1. Ebersold MJ, Quast LM, Laws ER Jr, Scheithauer B, Randall RV. Long-term results in transsphenoidal removal of nonfunctioning pituitary adenomas. *J Neurosurg* 1986;64:713-9.
2. Jagannathan J, Kanter AS, Sheehan JP, Jane JA Jr, Laws ER Jr. Benign brain tumors: sellar/parasellar tumors. *Neurol Clin* 2007;25:1231-49.
3. Kontorinis N, Holthouse DJ, Carroll WM, Newman M. Third nerve palsy after coronary artery bypass surgery. *J Thorac Cardiovasc Surg* 2001;122:400-1.
4. Chen Z, Murray AW, Quinlan JJ. Pituitary apoplexy presenting as unilateral third cranial nerve palsy after coronary artery bypass surgery. *Anesth Analg* 2004;98:46-8.
5. Park YM, Cho JH, Cho JY, Huh JS, Ahn JY. Non-Hodgkin's lymphoma of the sphenoid sinus presenting as isolated oculomotor nerve palsy. *World J Surg Oncol* 2007;5:86.
6. Itshayek E, Perez-Sanchez X, Cohen JE, Umansky F, Spektor S. Cavernous hemangioma of the third cranial nerve: case report. *Neurosurgery* 2007;61:E653.
7. Kim SH, Lee KC, Kim SH. Cranial nerve palsies accompanying pituitary tumour. *J Clin Neurosci* 2007;14:1158-62.
8. Mixson AJ, Friedman TC, Katz DA, Feuerstein IM, Taubenberger JK, Colandrea JM, et al. Thyrotropin-secreting pituitary carcinoma. *J Clin Endocrinol Metab* 1993;76:529-33.
9. Pernicone PJ, Scheithauer BW, Sebo TJ, Kovacs KT, Horvath E, Young WF Jr, et al. Pituitary carcinoma: a clinicopathologic study of 15 cases. *Cancer* 1997;79:804-12.
10. Pamir MN, Kiliç T, Belirgen M, Abacioğlu U, Karabekiroğlu N. Pituitary adenomas treated with gamma knife radiosurgery: volumetric analysis of 100 cases with minimum 3 year follow-up. *Neurosurgery* 2007;61:270-80.
11. Minniti G, Brada M. Radiotherapy and radiosurgery for Cushing's disease. *Arq Bras Endocrinol Metabol* 2007;51:1373-80.