

The Importance of Metallic Residues on Teeth to Determine the Entrance Hole of Shotgun Wounds

Ateşli Silah Yaralanmalarında Giriş Deliğinin Belirlenmesinde Diş Üzerindeki Metalik Kalıntıların Önemi

Çetin Lütfi BAYDAR

Department of Forensic Medicine, Medical Faculty of Süleyman Demirel University, Isparta

Submitted / Başvuru tarihi: 18.11.2008 **Accepted / Kabul tarihi:** 17.12.2008

Objectives: Determination of the entrance and exit sites in wounds caused by firearms can sometimes be the most important evidence to help procurement of justice. This study was carried out to see if metallic residues from the bullet core can be found on teeth and if the entrance and exit sites can be determined by examining their localization in firearm bullet core injuries with tooth involvement.

Study Design: 30 teeth, which were pulled with orders 1, 2 and 3 for orthodontic and prosthetic reasons, were used. A specially designed constant shot contrivance was used for firearm shots. The shots were performed with standard shotgun and full metal jacket cartridges. Shots were made from 40 cm distance and with front to back direction. The teeth were examined with stereomicroscope.

Results: Metallic residue traces were found in 47.8% on the front of fractured teeth by microscopic examination. The amount of metallic residues was low in five (21.7%) teeth, moderate in three (13%) and excessive in three teeth (13%).

Conclusion: If there is indecision about the shooting direction in cases with teeth involvement, microscopic evaluation should necessarily be made. Thereby, it will be possible to determine the entrance and exit sites by evaluating the localization of metallic residues or particles.

Key words: Tooth; entrance and exit sites; gunshot residue; metallic residue; forensic medicine.

Amaç: Ateşli silah yaralanmalarında giriş ve çıkış deliklerinin tayini bazen adaletin sağlanmasına yardımcı olacak en önemli delil olabilir. Bu çalışma; diş yaralanması da bulunan olgularda, diş üzerindeki mermi çekirdeğine ait olası metalik izlerin lokalizasyonundan giriş ve çıkış deliklerinin tespit edilebileceği düşüncesiyle planlandı.

Çalışma Planı: Çalışmada ortodontik ve prostetik nedenlerle çekilmiş 30 adet, 1, 2 ve 3 numaralı dişler kullanıldı. Atışlarda özel olarak tasarlanmış bir düzenek kullanıldı. Atışlarda standart tabanca ve fişekler kullanıldı. Atışlar 40 cm mesafeden ve önden arkaya doğru yapıldı. Kırık dişler stereomikroskopta incelendi.

Bulgular: Mikroskopik inceleme sonucunda kırık dişlerin %47.8'inde ön kısımlarında metalik iz tespit edildi. Metalik izlerin miktarı beş (%21.7) dişte az, üç (%13) dişte orta ve üç (%13) dişte çok olarak sınıflandırıldı.

Sonuç: Diş yaralanması da bulunan olguların giriş çıkış delikleri tayininde kararsızlık varsa mikroskopik inceleme mutlaka yapılmalıdır. Böylece metalik kalıntı veya partiküllerin lokalizasyonu ile giriş ve çıkış deliklerinin tayini mümkün olabilecektir.

Anahtar sözcükler: Diş; giriş ve çıkış delikleri; atış artığı; metalik kalıntı; adli tıp.

Short story

A couple was working in a police station and the woman had some psychological problems. There were often arguments between them and the woman had tried to commit suicide several times. During such an argument, a gun has fired. Her husband claimed that his wife committed suicide and shot herself through the mouth, although he attempted to stop her. He also stated that he called the emergency service and asked for an ambulance. Despite all efforts in the intensive care unit, his wife died three days later. After the crime and judicial investigations, the man was arrested for suspected homicide. There were some gunshot residues on the hands of the man and his wife. But it was not possible to determine the shot direction because of the surgical debridement. The characteristic properties of the entrance and exit sites could not be defined, because the woman was buried without any autopsy examination.

During the lawsuit, all of the medical evidence which supported the man's claims nullified. The court decided to send the file to the National Institute of Forensic Medicine for further investigation. The Institute asked for the remaining parts of the body. It was reported that the right transverse segments of the neck vertebrae were broken at the C2-3 level, the tooth number 1 on upper left side was fractured at the crown level, tooth ordered number 2 was broken in a half moon shape facing right and down. During the court session, the vertebrae broken at the C2-3 level was accepted as a remarkable proof and it was concluded that the shot was made from the back to front direction. After this fact was approved, the man was found guilty of causing his wife's death by shooting her through the neck and he was convicted to lifetime imprisonment for the homicide offence. He is still in prison now.

Determination of the entrance and exit sites in wounds caused by firearm sometimes can be the most important evidence that may help procurement of justice. Entrance and exit sites can not be identified in some wounds localized near the mouth or mandible regions. Surgical interven-

tions can lead to degeneration of the characteristics of the bullet holes located in mouth-neck regions, which may result in removal of evidence to be used in determination of entrance and exit sites.^[1] When the wounded person dies and a crime investigation is needed to find out the main cause of death, murder, accident and suicide are within the bounds of possibility in shots directed from mouth to the neck, whereas in shots directed from the neck to mouth, murder and accident possibilities are still highly present, however, suicide seems to be nearly impossible. Furthermore, no such suicide has been reported in the literature so far. Accurate determination of shot direction is crucial in order to elucidate similar cases of suspected suicide and this can even be the only evidence. There may be some crash fractures in the front teeth in firearm injuries to the mouth region. Entrance site can be estimated by examining the tooth fragments in projectile pattern on tongue. Evaluation of the resident teeth fracture shapes in alveolar bone does not necessarily give true results every time.^[2] In a case that is known to be in anterior-posterior direction, it has been reported that there was more fracture loss in frontal site of the tooth, although a fracture in projectile pattern concordant with the shot direction was expected.^[2] In previous studies, it has been reported that residual metallic pieces of bullet core found on the front side of the fractured bone fragments were identified by using proton-induced X-ray emission (PIXE) assay.^[3,4] This study is planned in the light of the thought that there might be metallic residues of bullet core in teeth and entrance hole can be determined by examining their localization in firearm bullet core injuries with tooth involvement. There is no such study in the literature.

MATERIALS AND METHODS

Thirty teeth, which were pulled from upper and lower right and left sides with orders 1, 2 and 3 for orthodontic and prosthetic reasons, were used in this study. No gender difference was regarded during material collection because fracture types were out of scope of this study, in which determination of metal residues was the main issue. Collected teeth were kept in




Fig. 1. Shot contrivance.

serum physiological and afterwards, they were fixed on cylindrical blocks made from horn-beam wood by using hot silicone. A specially designed constant shot contrivance was used for firearm shots (Fig. 1). The shots were performed via using Kırıkkale brand gun (Mechanical and Chemical Industry Corporation, MCIC, Ankara, Turkey) with 7.65 mm diameter and standard MCIC brand full metal jacket cartridges. The experiment was conducted in a shooting range. Shots were made to 30 teeth from 40 cm distance and from a front to back direction. A paperboard was placed between the gun and the target. Height alignment was made after each shot in order to target the one-half upper site of the tooth crown. Fractured teeth were subsequently examined with the naked eye and also using an Olympus S2 X-TB1 (S2X12) model stereomicroscope. Photographs of the samples were taken by using Olympus Camedia C-5060 digital camera. Front sites of the wood blocks were marked. Fracture types were not evaluated.

RESULTS

As this study included old teeth and seven of them had already been smashed from the root

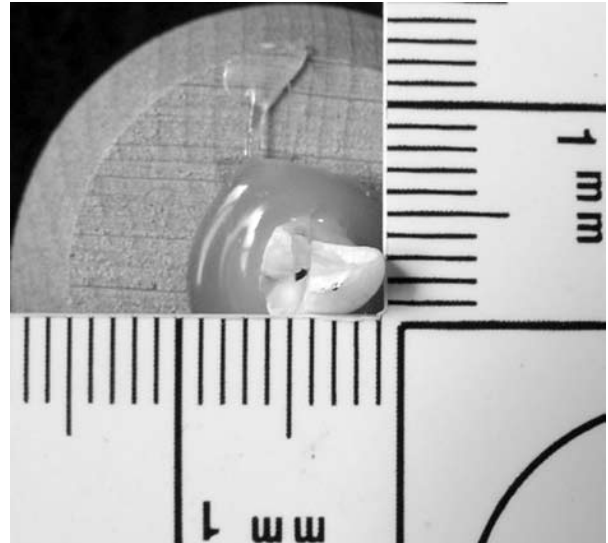


Fig. 2. Very remarkable metal residue (with naked eye).

site, we could not examine these samples. On examination of the remaining 23 teeth with the naked eye, dirt traces of possible gunpowder or soot residues in 11 teeth (47.82%) and yellow metallic residue of bullet core cartridge cover in six teeth (26.08%) with very remarkable degree in one tooth (Fig. 2) were observed in the front sites of enamel and dentin layers of the broken teeth placed in blocks. Microscopic examination of the fractured teeth with stereomicroscope showed dirt traces of possible gunpowder or soot residue in 22 teeth (95.65%), whereas metallic residue traces were found in 11 teeth (47.82%). Metallic residues found during microscopic examination were graded as low (+), moderate (++) and excessive (+++). According to this classification, there was low metallic




Fig. 3. (a) (+) Metallic residue; (b) (++) metallic residue; (c) (+++) metallic residue.

Table 1. Physical evaluation of specimens

Tooth number	Naked eye		Microscopic	
	Soot on fore side	Metal mark/paring on fore side	Soot on fore side	Metal mark/paring on fore side
1	+	-	+	+
2	-	-	-	-
3	+	-	+	+
4	+	+	+	+++
5	-	-	-	-
6	+	+	+	+++
7	-	-	+	-
8	-	-	-	-
9	+	-	+	+
10	-	-	+	-
11	-	-	-	-
12	+	-	+	-
13	-	+	+	+++
14	-	-	+	-
15	+	+	+	++
16	+	-	+	-
17	-	+	+	++
18	-	+	+	++
19	+	-	+	+
20	-	-	+	-
21	+	-	+	-
22	-	-	-	-
23	-	-	+	-
24	-	-	+	-
25	+	-	+	+
26	-	-	+	-
27	-	-	-	-
28	-	-	-	-
29	-	-	+	-
30	-	-	-	-

residue in five (21.74%) teeth (Fig. 3a), moderate in three (13.04%) teeth (Fig. 3b) and excessive in three (13.04%) teeth (Fig. 3c). The findings are shown in Table 1.

DISCUSSION

It may sometimes be very important to determine the entrance and exit holes in firearm injuries with involvement of fragments. In shots with a neck to mouth direction, the cause of death is generally regarded as homicide (intentionally or accidentally). The characteristic properties of the entrance and exit sites of firearm bullet core can be missing as a result of surgical

interventions like debridement. In numerous studies, it has been reported that urgent surgical debridement could affect the treatment course in favorable sense in firearm injuries to maxillofacial region.^[5,6] When the soft tissue lesions that can constitute important evidence to reveal the entrance and exit sites are removed by surgical interventions and if there is also a teeth involvement, then shot direction can be determined by making a detailed examination of the fragmented pieces. In tooth tissue which has a compact and hard structure like bone, the bullet core impacts to the tissue with high kinetic energy and causes fragmented fractures.

As tooth enamel is denser than dentin and pulp, its response to high kinetic energy may be different. Sometimes enamel may be broken more than the dentin layer.^[2] As inanimate teeth were used in our study, seven teeth were broken from the fixation sites to the blocks, making it impossible to examine the metallic residues or other traces like gunpowder. For the same reason, we did not make a fracture type evaluation. Since the teeth were shot in an artificial model, which does not exactly resemble the normal anatomical structures, it may seem unfamiliar. However, as this is the first study evaluating whether metallic residues on teeth may help in determining the entrance hole, our results have merit to report. This study was performed on inanimate (approximately one week from collecting) teeth, however, future studies with freshly removed teeth, in which shots were performed in the very first hours, may give more accurate results.

Performing shots with only front to back direction and absence of any tissue or bone barrier between the gun and the teeth can be regarded as other limitations of this study. In decayed or body remains, some environmental, physical and chemical factors might also affect these kinds of traces. Tissue or bone-type barriers decrease the kinetic energy of the bullet and

this prevents the soot or oil residues reaching the teeth, especially in shots with a back to front direction. For this reason, it seems that it is nearly impossible to use soot or gunpowder traces to determine the entrance hole of the shot.

As a result, if there is indecision about the entrance and exit sites in cases with teeth involvement, microscopic evaluation should necessarily be made. Thereby, it will be possible to determine entrance hole by evaluating the localization of metallic residues.

REFERENCES

1. Prahlow JA, Barnard JJ. Contact gunshot wound of the head: diagnosis after surgical debridement of the wound. *J Clin Forensic Med* 1999;6:156-8.
2. Özaslan A, Uysal C, Baydar ÇL, Afşin H. Atış yönü tayininde dişteki mermi çekirdeği lezyonunun değerlendirilmesi. *Adli Tıp Dergisi* 2002;15:17-20.
3. Fischbeck HJ, Ryan SR, Snow CC. Detection of bullet residue in bone using proton-induced X-ray emission (PIXE) analysis. *J Forensic Sci* 1986;31:79-85.
4. Warren MW, Falsetti AB, Kravchenko II, Dunnam FE, Van Rinsvelt HA, Maples WR. Elemental analysis of bone: proton-induced X-ray emission testing in forensic cases. *Forensic Sci Int* 2002;125:37-41.
5. Kassan AH, Lalloo R, Kariem G. A retrospective analysis of gunshot injuries to the maxillo-facial region. *SADJ* 2000;55:359-63.
6. Motamedi MH. Primary management of maxillofacial hard and soft tissue gunshot and shrapnel injuries. *J Oral Maxillofac Surg* 2003;61:1390-8.